

Patient ID 321904
Patient Name Mrs. SHILPA MUKESH SAXENA
Gender/Age Female/38
Ref Doctor

Dt : 26/11/2022

Rx

	Drug Name	Generic Name	Morning	Afternoon	Evening	Night	Duration
Tab.	FOLIMAX new	FOLIC ACID	1	0	0	0	2 Month(s)

Dr. Rashmi Chovatia



HEALTH CHECKUP REPORT

Patient Name: SHILPA SAXENA
Age/Gender: 38/F
Reg. No: 390592
Package: MEDIWHEEL

DATE: 26/11/2022

COMPLAINTS (IF ANY):

- Burnig in genital parts

HISTORY OF HEALTH STATUS: No

PRESENT MEDICATIONS: No

HYPERSENSITIVITY TO ANY DRUG: No

PERSONAL HISTORY:

- Bowel : Regular
- Micturition : Normal
- Sleep : Adequate
- Appetite : Adequate

Diet : Veg
Habits : No
Physical Activity/Exercise: Activity

HISTORY OF ILLNESS (WITH PAST MEDICATIONS):

- Lmp :- 10/11/2022

FAMILY HISTORY:

- Mother :- hyperthyroidism , hypertension

VITAL SIGNS:

- Height : 157 cms
- Weight : 54.6 Kgs

Pulse : 80/min.
B.P: 140/80mmHg



PHYSICIAN CONSULTATION:

1) **Clinical Impression**
Reports within normal limits

2) **Recommendations**
Healthy life style

(Dr. Rshmi chovatia)

OPHTHALMO CONSULTATION:

Best corrected visual acuity

RE

LE

6/6

6/6

(Dr. Jlgresh Shah)

DENTAL CONSULTATION:

Adv:

- Cleaning

(Dr. Parvin Chandarana)

GYNEC CONSULTATION:

M/H: PMP- regular

LMP: 15th days

O/E: - AML -

1 FFLSCS

H/O: TL

P/H : Any other surgeries -

O/E: P/A - Soft

P/S - Cx. NAD

P/V - UT, RV, NS, FMR, Fx. Clear

Adv: USG Pelvis/FVS

Mammography

Pap Smear

} Follow up with reports

(Dr. Devang patel)

Please take regular medicine as prescribed by the Doctor. (If given)

Plot No 67/1, Opp. Panchamrut Bungalows, Near Shukan Mall, Off Science City Road, Sola, Ahmedabad - 380050, Gujarat

1800 309 9999 CIN No. U85110GJ2001PTCC39962

CIMS HOSP/2021/



**Marengo CIMS
Hospital**

CIMS

Reg. No : CIMS/A/2022/390592	Visit No : HC/261122/9 [HCV]
Patient Name : Mrs. SHILPA MUKESH SAXENA	Age(Y-M-D)/Sex : 38 Y 3 M 13 D. / Female
Referring Doctor : Dr. CIMS DOCTOR	Doctor Bed
Ward/Room	
ORD/261122/356 Lab No : 2022174602 LSN : 937198 (Whole Blood) Sample Quality : Normal	Validation Time : 26/11/2022 12:15:25PM
Collection Time : 26/11/2022 8:55:00	Arrival : 26/11/2022 9:37:25

Rh

POSITIVE

*** END OF REPORT ***

Dr. Manisha Shah
 MD (Path & Bact)
 Consultant Pathologist
 Reg. No. : G-15496

Dr. Manisha Shah
MD (Path & Bact)
Consultant Pathologist
Reg. No. : G-15496

Dr. Jitendra Nayak
MD (Path)
Consultant Pathologist
Reg. No. : G-14786

Sh

Dr. Shreya Patel
MD (Path)
Consultant Pathologist



CIMS Hospital Private Limited

Plot No 67/1, Opp. Panchamrut Bungalows, Near Shukan Mall, Off Science City Road, Sola, Ahmedabad - 380060, Gujarat

1800 409 9999 CIN No. U85110GJ2001P1C039962

Print By : ankita raidut

Print Date/Time : 26/11/2022 13:18:50

Page 2 of 4



**Marengo CIMS
Hospital**

cims.org

Reg. No : CIMS/A/2022/390592	VisitNo : HC/261122/9 [HCV]
Patient Name : Mrs. SHILPA MUKESH SAXENA	Age(Y-M-D)/Sex : 38 Y 3 M 13 D. / Female
Referring Doctor : Dr. CIMS DOCTOR	Doctor
Ward/Room	Bed

ORD/261122/356 Lab No : 2022174602 LSN : 937193 (Whole Blood) Sample Quality: Normal
 Collection Time : 26/11/2022 8:55:00 Arrival : 26/11/2022 9:37:25 Validation Time: 26/11/2022 1:11:03PM

	Result	Unit	Reference Range
HbA1c (Glycosylated Haemoglobin)			
TEST			
HbA1c (Glyco Hb) (Immuno Turbidimetric)	5.38	%	4.8-5.9% Normal 5.9-7.0% Good diabetic control 7.0-10.0% Fair diabetic control >10.0% Poor diabetic control
Mean Plasma Glucose	114.2	mg/dL	80 - 140 mg/dL

(Signature)

Dr. Kazumi Gondalia
M.D. (Path)
Consultant Pathologist
Reg. No. : G-21729

Dr. Manisha Shah
MD (Path & Bact)
Consultant Pathologist
Reg. No. : G-15496

Dr. Jitendra Nayak
MD (Path)
Consultant Pathologist
Reg. No. : G-14786



CIMS Hospital Private Limited


Plot No 67/1, Opp. Panchamrut Bungalows, Near Shukan Mall, Off Science City Road, Soia, Ahmedabad - 380060, Gujarat
 ☎ 1800 309 9999 CIN No. U8510GJ2001PTC039962

Reg. No : CIMS/A/2022/390592	Visit No : HC/261122/9 [HCV]
Patient Name : Mrs. SHILPA MUKESH SAXENA	Age(Y-M-D)/Sex : 38 Y 3 M 13 D. / Female
Referring Doctor : Dr. CIMS DOCTOR	Doctor Bed
Ward/Room	
ORD/261122/356 Lab No : 2022174603 LSN : 937198 (SERUM) Sample Quality : Normal	Validation Time : 26/11/2022 12:41:40PM
Collection Time : 26/11/2022 8:55:00	Arrival : 26/11/2022 9:37:25

Liver Function Test	Result	Unit	Reference Range
Alkaline Phosphatase <i>(PNPP, AMP Buffer Method, Colorimetric)</i>	47.1	U/L	35 - 104 U/L
Bilirubin			
Total Bilirubin <i>(Diazo special Iazontum Iron with Blank)</i>	0.25	mg/dL	0.0 - 1.0 mg/dL
Direct Bilirubin <i>(Diazo, Evelyn Malloy) with Blank J</i>	0.12	mg/dL	0.0 - 0.2 mg/dL
Indirect Bilirubin <i>(Calculated from Total and Direct Bilirubin)</i>	0.13	mg/dL	0.0 - 0.8 mg/dL
SGPT (ALT) <i>(FCC without pyridoxal phosphate)</i>	9.7	U/L	0 - 33 U/L
SGOT (AST) <i>(FCC without pyridoxal 5 phosphate)</i>	13.1	U/L	0 - 32 U/L
Total Protein			
Total Proteins <i>(Biuret Method)</i>	7.23	gm/dl	6.4 - 8.3 gm/dl
Albumin <i>(Bromocresol Green Colorimetric)</i>	4.72	gm/dl	3.97 - 4.95 gm/dl
Globulin	2.51	gm/dl	2.2 - 3.5 gm/dl
A/G Ratio	1.86		0.9 - 2.1

Dr. Manisha Shah
MD (Path & Bact)
Consultant Pathologist
Reg. No. : G-15496

Dr. Jitendra Nayak
MD (Path)
Consultant Pathologist
Reg. No. : G-14786



Dr. Shreya Patel
MD (Path)
Consultant Pathologist





Reg. No : CIMS/A/2022/390592	Visit No : HC/261122/9 [HCV]
Patient Name : Mrs. SHILPA MUKESH SAXENA	Age(Y-M-D)/Sex : 38 Y 3 M 13 D. /Female
Referring Doctor : Dr. CIMS DOCTOR	Doctor Bed
Ward/Room	


ORD/261122/356 Lab No : 2022174603 LSN : 937198 (SERUM) Sample Quality : Normal
 Collection Time : 26/11/2022 8:55:00 Arrival : 26/11/2022 9:37:25 Validation Time: 26/11/2022 12:41:39PM

	Result	Unit	Reference Range
Creatinine (Buffered Jaffe Reaction Kinetic Compensated)	0.64	mg/dL	0.5 - 0.9 mg/dL
Estimated GFR	101.6	mL/min/1.73m ²	71 - 121 mL/min/1.73m ²
Fasting Glucose (Hexokinase)	85.7	mg/dL	70 - 100 mg/dL
Thyroid Function Test			
TOTAL T3 (T3) * (Electrochemiluminescence Assay)	1.1	ng/ml	0.846 - 2.02 ng/ml
TOTAL T4 (T4) * (Electrochemiluminescence Assay)	7.8	µg/dl	5.13 - 14.06 µg/dl
TSH (Electrochemiluminescence Assay)	2.79	µIU/ml	0.27 - 4.20 µIU/ml
Uric Acid (Uricase Colorimetric Enzymatic)	2.08	mg/dL	2.4 - 5.7 mg/dL

*** END OF REPORT ***

Dr. Manisha Shah
MD (Path & Bact)
Consultant Pathologist
Reg. No. : G-15/196

Dr. Jitendra Nayak
MD (Path)
Consultant Pathologist
Reg. No. : G-14786


Dr. Shreya Patel
MD (Path)
Consultant Pathologist




Reg. No : CIMS/A/2022/390592	Visit No : HC/261122/9 [HCV]
Patient Name : Mrs. SHILPA MUKESH SAXENA	Age(Y-M-D)/Sex : 38 Y 3 M 13 D. / Female
Referring Doctor : Dr. CIMS DOCTOR	Doctor :
Ward/Room :	Bed :

ORD/261122/356 Lab No : 2022174603 LSN : 937198 (SERUM) Sample Quality : Normal
 Collection : 26/11/2022 8:55:00AM Arrival: 28/11/2022 9:47:42 Validation Time: 26/11/2022 11:44:55

<u>Lipid Profile (With Direct LDL)</u>	<u>Result</u>	<u>Unit</u>	<u>Reference Range</u>
Type of Sample	: Fasting		
Cholesterol <i>(Enzymatic/Colorimetric, Cholesterol Oxidase, Esterase, Peroxidase Gen. 2)</i>	: 189.9	mg/dL	Less than 160 mg/dl Excellent Less than 200 mg/dl Desirable 200-239 mg/dl Borderline High 240 mg/dl & over High
Triglyceride <i>(Enzymatic Colorimetric without Glycerol Blank without Serum Blank)</i>	: 74	mg/dL	Less than 150 mg/dl Normal 150 - 199 mg/dl Borderline High 200-499 mg/dl High 500 mg/dl or greater Very High
HDL Cholesterol <i>(Direct Measure Homogenous Technique Modified Enzymatic Colorimetric Gen. 3)</i>	: 68.6	mg/dL	Less than 40 mg/dl Low 60 mg/dl or above Excellent
LDL Cholesterol (DIRECT) <i>(Homogenous Enzymatic colorimetric Assay)</i>	: 113.0	mg/dL	Less than 80 mg/dl Excellent Less than 100 mg/dl Optimal 100 - 129 mg/dl Near or above optimal 130 - 159 mg/dl Borderline High 160 - 189 mg/dl High 190 mg/dl & above Very High
VLDL Cholesterol <i>(Calculated)</i>	: 14.8	mg/dL	15 - 30 mg/dl
Cholesterol/HDL Ratio <i>(Calculated)</i>	: 2.77		Normal upto 4.5
LDL/HDL Ratio <i>(Calculated)</i>	: 1.65		Less than 3.5

Remarks :


Dr. Shreya Patel
 MD(Path)
 Consultant Pathologist

Dr. Manisha Shah
 MD (Path & Bact)
 Consultant Pathologist
 Reg. No. : G-15496

Dr. Jitendra Nayak
 MD (Path)
 Consultant Pathologist
 Reg. No. : G-14786





**Marengo CIMS
Hospital**

Reg. No : CIMS/A/2022/390592	Visit No : 11C/261122/9 [HCV]
Patient Name : Mrs. SHILPA MUKESH SAXENA	Age(Y-M-D)/Sex : 38 Y 3 M 13 D. / Female
Referring Doctor : Dr. CIMS DOCTOR	Doctor Bed
Ward/Room	


ORD/261122/356 Lab No : 2022174632 LSN : 937198 (Urine) Sample Quality : Normal
 Collection Time : 26/11/2022 10:10:00 Arrival : 26/11/2022 10:15:57 Validation Time : 26/11/2022 11:16:07AM

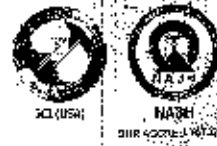	Result	Unit	Reference Range
Urine R & M			
PHYSICAL EXAMINATION			
Quantity	20 cc		
Colour	Pale Yellow		
Transparency	Clear		
Reaction (QDS-10 Strip)	6.0		
Sp. Gravity (QDS-10 Strip)	1.015		1.005 - 1.035
CHEMICAL EXAMINATION			
U. Albumin (QDS-10 Strip/Manual)	Nil		
U. Glucose (QDS-10 Strip/Manual)	Nil		
U. Acetone (QDS-10 Strip/Manual)	Absent		
BS/BP (QDS-10 Strip/Manual)	Absent		
MICROSCOPIC EXAMINATION			
Pus Cell	Occasional	/H.P.F.	/H.P.F.
Red Blood Cell	Nil	/H.P.F.	/H.P.F.
Epithelial Cell	1-2	/H.P.F.	/H.P.F.
Cast	Not Seen		
Crystals	Not Seen		
Amorphous	Absent		
Monilia	Absent		

*** END OF REPORT ***

Dr. Manisha Shah
MD (Path & Bac)
Consultant Pathologist
Reg. No. : G-15496

Dr. Jitendra Nayak
MD (Path)
Consultant Pathologist
Reg. No. : G-14786


Dr. Shreya Patel
MD (Path)
Consultant Pathologist



CIMS Hospital Private Limited

Plot No 67/i, Opp. Panchamrut Bungalows, Near Shukan Mali, Off Science City Road, Sula, Ahmedabad - 380060, Gujarat
 © 1800 309 9999 CIN No. U85100GJ2001PTC039962

Name : Mrs. SHILPA MUKESH
SAXENA

Reg No : CIMS/A/2022/390592

DoB / Sex: 13/08/1984 / Female

ECHO Report

Dt : 26/11/2022

Patient Details

Patient ID 321904
Name Mrs. SHILPA MUKESH SAXENA
Age 38 Years
Gender Female
Blood Group
Referral Doctor

ECHO Identification Detail

Doctor Incharge Dr. VIPUL KAPOOR

Clinical Status Of Patient

ECHO Code RP

Finding Description

1. Normal cardiac chambers dimensions.
2. Normal LV systolic function, LVEF: 60%.
3. No RWMA.
4. Normal LV diastolic function.
6. MV: AMVL long and redundant, other cardiac valves are structurally normal.
7. Trivial MR, Trivial TR, Trivial PR, No AR.
8. No PAH.
9. Normal RV systolic function.
10. No clot/vegetation/pericardial effusion.

Dr. VIPUL KAPOOR



ISE (ISAE)



MABH



MCS-3049

REGISTRATION NO.

CIMS Hospital Private Limited

Plot No 67/1, Opposite Panchmurti Bunglows Near Shakun Mall, Off Science City Road, Sola, Ahmedabad, Gujarat 380060

© 1800 309 9999 CIN No. U85110GJ2003PTC039962

ID: 095
Years

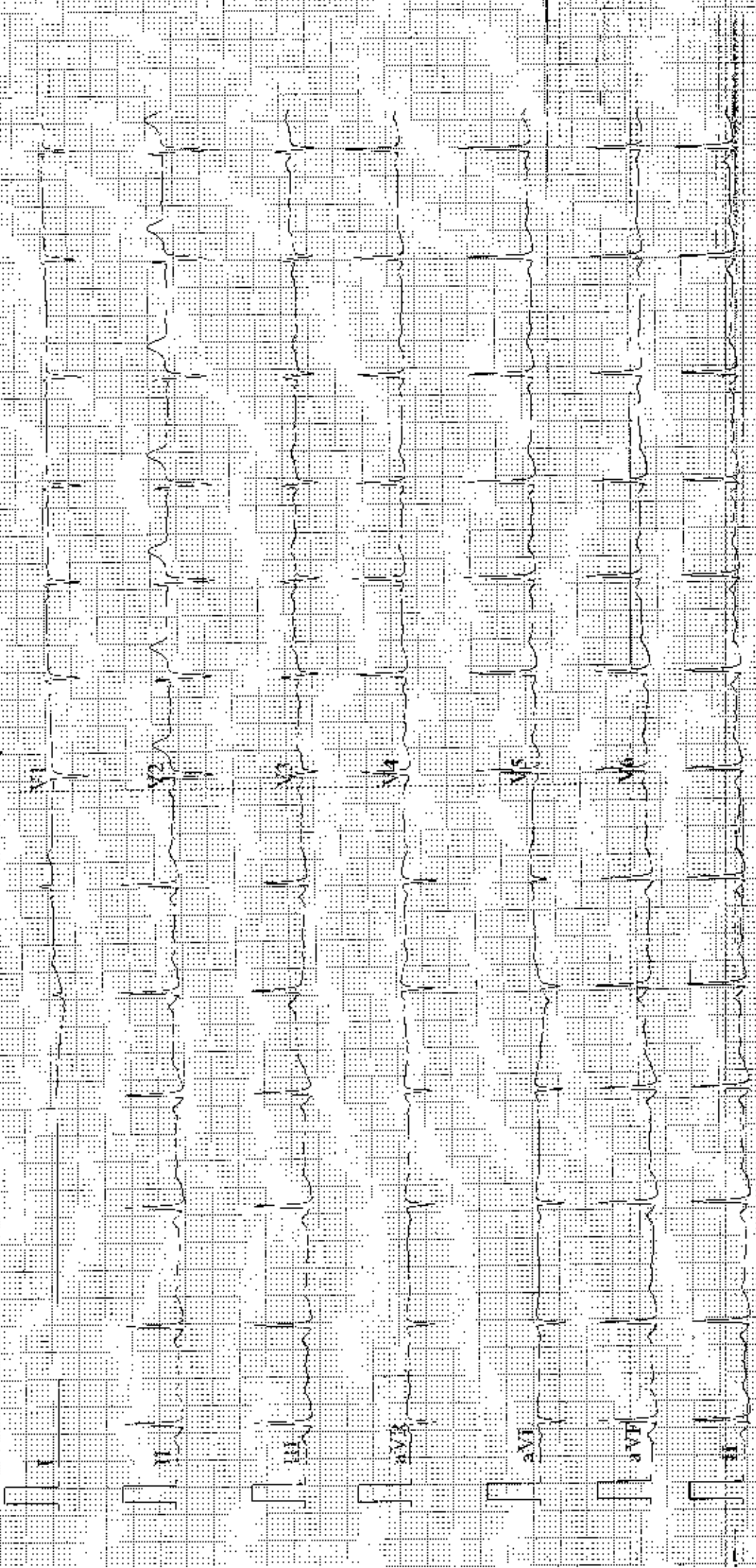
HR 78 bpm
P 103 ms
PR 124 ms
QRS 80 ms
QT/QTc 350/400 ms
P/QRS/T 90.83/43.1°
RV5/SV1 1.2/1.0/0.622 mV

Diagnosis Information

Name : Mrs. SHILPA MUKESH SAXENA
Reg No : CIMS/A/2022/390692
DoB /Sex : 13/08/1984 / Female

NSR (Normal)

Report Confirmed by





Patient's Name : SHILPA MUKESH SAXENA
Reg. No. (IP/OP): HC-390592
Referred By Dr. : CIMS

Age, Sex : 38Y/F
Date : 26/11/2022

Plain Skiagram of Chest PA Standing View:
(Serial No-B-6751)

Both lung fields appear normal.

No evidence of pleural effusion or pneumothorax is seen on either side.

Mediastinal shadow appears normal.

Heart size and aorta appear normal.

Domes of diaphragm appear normal.

Bones under view appears normal.

Kindly correlate clinically.

DR KIRAN SHAH M.D., RADIOLOGIST CONS. RADIOLOGIST	DR DEEPA SHAH M.D., D.M.R.E CONS. RADIOLOGIST	DR UMA MEHTA D.M.R.D. F.R.C.R CONS. RADIOLOGIST	DR NIMISH SHARMA D.M.R.D. (D.N.B.) CONS. RADIOLOGIST	DR RAVINA CHAUHAN M.D., RADIOLOGIST CONS. RADIOLOGIST	DR YASH PATEL M.D., D.N.B. CONS. RADIOLOGIST	DR SUNALI DESAI MD, DNB, DM, FRCR NEURORADIOLOGIST
---	---	---	--	---	--	--

Note: This is only a radiological impression and not the final diagnosis. All diagnostic modalities have their own limitations. Therefore radiological modality report should be interpreted in correlation with clinical and pathological findings.

FOR RADIOLOGY REPORTS ONLY



Patient's Name : SHILPA MUKESH SAXENA	Age, Sex : 38Y/F
Reg. No. (IP/OP): HC-390592	Date : 26/11/2022
Referred By Dr. : CIMS	

USG OF ABDOMEN & PELVIS

LIVER: Liver is normal in size and echotexture. No evidence of focal SOL or dilatation of IHBV seen. Porta hepatis appear normal.

GALLBLADDER: Gallbladder appeared normal. No calculus or mass lesion seen.

PANCREAS: Visualised pancreas appeared normal in size and echotexture. No focal lesion, mass or pancreatitis.

SPLEEN: Spleen appears normal in size and echotexture.

PARAAORTIC REGION: Aorta grossly appeared normal. No paraaortic lymphnodes seen.

KIDNEYS: Both kidneys appear normal in size, shape and in position. Cortex and collecting system of both kidneys appeared normal. No evidence of calculus or obstructive uropathy on either side. Right kidney: 101x41mm. Left kidney: 96x52mm.

URINARY BLADDER: Bladder appeared normal. No calculus or mass lesion is seen.

UTERUS: Uterus appears normal in size. Uterus shows homogenous endometrial and myometrial echotexture. Endometrial thickness appears normal and measures 11mm. No fibroid or GS seen.

OVARIES: App. 32x22x25mm size with vol.: 9cc cyst is seen in right ovary with no evidence of calcification or septa in cyst.

Left ovary measures 30x14mm and appear normal. No adnexal mass lesion seen on left side.

No evidence of free fluid or collection is seen in peritoneal spaces. Normal small bowel peristalsis noted.

COMMENTS: Appearance suggests

- Right ovarian cyst with no evidence of calcification or septa in cyst.

Kindly correlate clinically.

DR KIRTIK SHAH M.D. RADIOLOG. CONS. RADIOLOGIST
 DR DEEPA SHAH M.D., D.M.R.E. CONS. RADIOLOGIST
 DR UMA MEHTA D.M.R.D. F.R.C.R. CONS. RADIOLOGIST
 DR NIMISH SHARMA D.M.R.D. (D.M.B.) CONS. RADIOLOGIST
 DR RAVINA CHAUHAN M.D. RADIOLOG. CONS. RADIOLOGIST
 DR YASH PATEL M.D., D.N.B. CONS. RADIOLOGIST
 DR SUMALI DESAI M.D., D.N.B., D.M. FRCR NEURORADIOLOGIST

Note: This is only a radiological impression and not the final diagnosis. All diagnostic modalities have their own limitations. Therefore radiological modality report should be interpreted in correlation with clinical and pathological findings.



FOR RADIOLOGY REPORTS ONLY