

ID: 1111 CASE: 1  
AGE: 30Y 0M 08D  
170Cms 80KG

RANDHIR KUMAR  
MALE  
16/04/2022 10:12:34  
ALC ADVANCE IMAGING DIAGNOSTICS  
E95 PC COLONY KANKARBAGH PATNA

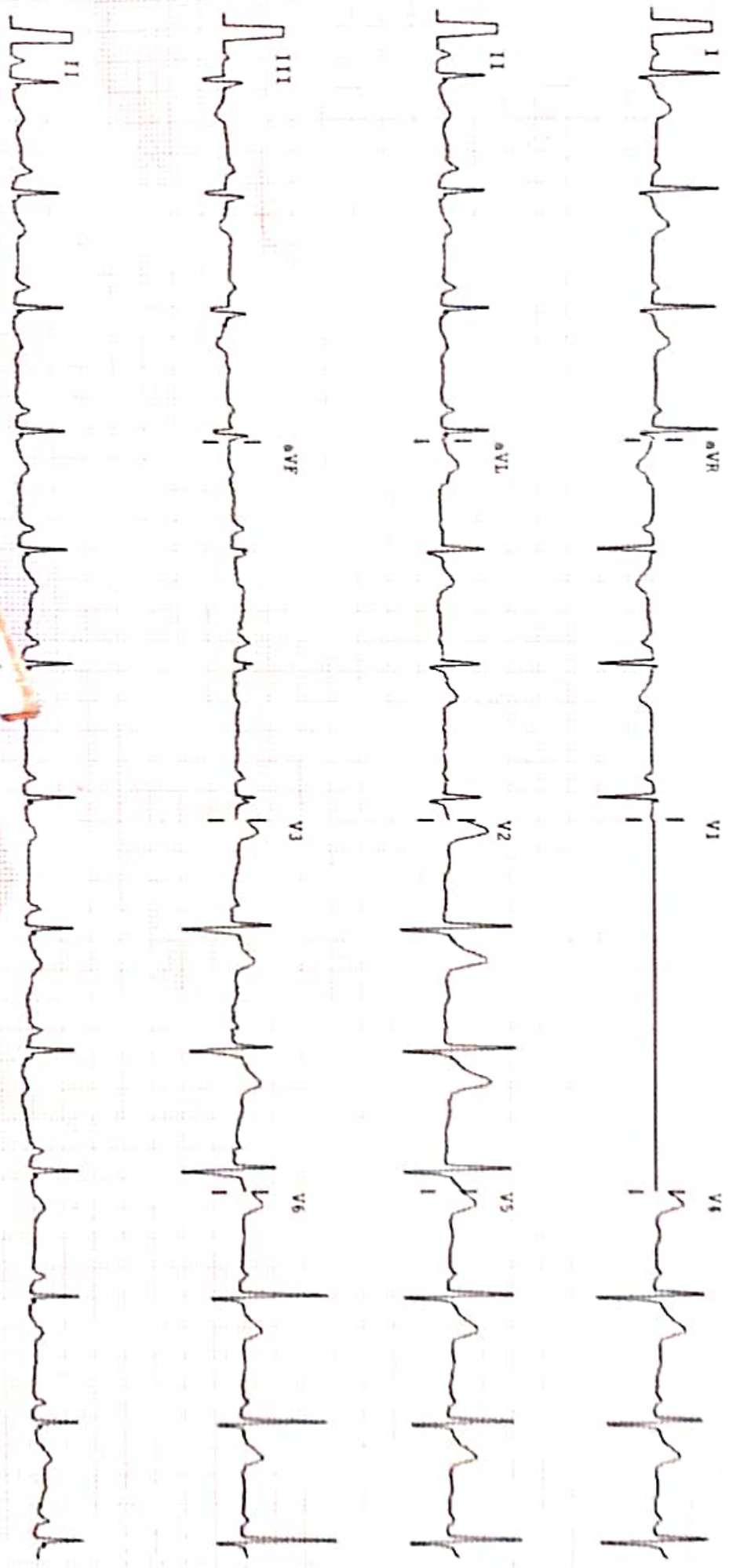
RATE : 73 bpm SINUS ARRHYTHMIA  
R-R : 820 ms LEAD(S) UNSUITABLE FOR ANALYSIS: V1  
P-R : 148 ms  
QRS : 94 ms  
QT : 360 ms  
QTc : 383 ms

..AXIS..  
P : 61°  
QRS : 29°  
T : 04°  
NORMAL ECG BASED ON AVAILABLE LEADS

12 SL. REPORT FORMAT JKL+1L.S0 REF. DR. NEDIMWHEEL



Dr. Abhinav Kumar  
MBBS, MD  
Dr. DR. ABHINAV KUMAR MD



25mm/sec 10mm/mV Notch: ON

ALLENGERS PISCES 1012(VER. 1.1.8) CLINICALLY CORRELATE THE FINDINGS.

4041 / RANDHIR KUMAR / 32 Yrs / M / 170 Cms / 80 Kg Date: 16-Apr-2022 Technician : MR TRILLOKI

Stage	Time	Duration	Belt Speed (mph)	Elevation	METS	Rate	% THR Achieved	BP	RPP	PVC	Comments
Standing	00:13	0:01	00.0	00.0	01.0	85	45 %	---/---	000	00	
Warm Up	00:58	0:01	01.0	00.0	01.0	87	46 %	---/---	000	00	
ExStart	03:01	0:08	01.7	10.0	01.2	118	63 %	120/80	141	00	
BRUCE Stage 1	06:01	3:00	01.7	10.0	04.7	132	70 %	130/80	171	00	
BRUCE Stage 2	09:01	3:00	02.5	12.0	07.1	160	85 %	132/85	211	00	
PeakEx	10:17	1:17	03.4	14.0	08.4	175	93 %	132/85	231	00	
Recovery	10:41	0:25	00.0	00.0	04.6	174	93 %	132/85	229	00	

**Findings :**

Exercise Time : 07:17  
 Max HR Attained : 175 bpm 93% of Target 188  
 Max BP Attained : (Sys) 132/85  
 Max Workload Attained : 8.4 Fair response to induced stress  
 Max ST Dep Lead & Value : Max ST Dep Lead & Value  
 Test End Reasons : Test Complete

**Report :**

Dr. Ranjeet Kumar  
 MBBS, MD, CCEBDM  
 Consultant Cardiologist  
 Reg. No. 48722



Doctor : ALC DIAGNOSTIC



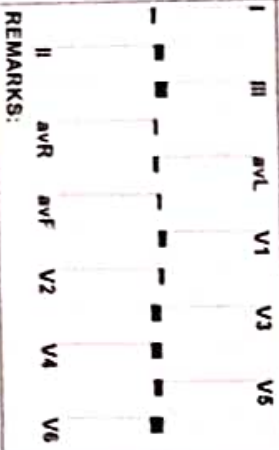
4041 / RANDEHIR KUMAR / 32 Yrs / M / 170 Cms / 80 Kg / HR : 175

Date: 16-Apr-2022 10:46:55 AM METS: 8.4/175 bpm 93% of THR BP: 132/86 mmHg Raw ECG/ BLC On/ Notch On/ HF 0.05 Hz/LF 20 Hz

ExTime: 07:16 3.4 mph, 14.0%

4X 60 ms Post J

25 mm/Sec. 1.0 Cm/mV



REMARKS:

(GEM213180726)(A)Allengers





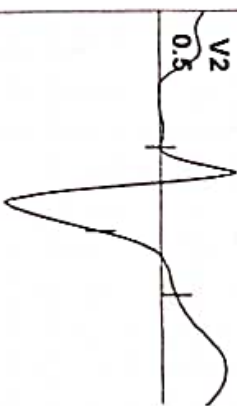
4041 / RANDHIR KUMAR / 32 Yrs / M / 170 Cms / 80 Kg / HR : 160

Date: 16-Apr-2022 10:46:55 AM METS: 7.1/ 160 bpm 85% of THR BP: 132/85 mmHg Raw ECG/ BLC On/ Notch On/ HF 0.05 HZ/LF 20 HZ

ETime: 06:00 2.5 mph, 12.0%

4X 60 ms Post J

25 mm/sec. 1.0 Cm/mV



I	III	aVL	V1	V3	V5
II	aVR	aVF	V2	V4	V6

REMARKS:





4041 / RANDEHIR KUMAR / 32 Yrs / M / 170 Cms / 80 Kg / HR : 132

Date: 16-Apr-2022 10:46:55 AM METS: 4.7/ 132 bpm 70% of THR BP: 130/80 mmHg Raw ECG/ BLC On/ Notch On/ HF 0.05 Hz/LF 20 Hz

ExTime: 03:00 1.7 mph, 10.0%

4X 60 ms Post J

25 mm/Sec. 1.0 Cm/mv



REMARKS:

(GEM213180726)(A)Allengers




4041 / RANDEHIR KUMAR / 32 Yrs / M / 170 Cms / 80 Kg / HR : 118

Date: 16-Apr-2022 10:46:55 AM METS: 1.0/ 118 bpm 62% of THR BP: 120/80 mmHg Raw ECG/ BLC On/ Notch On/ HF 0.05 Hz/LF 20 Hz

ExTime: 00:00 0.0 mph, 0.0%

4X 80 ms Post J

28 mm/Sec. 1.0 Cm/mV



REMARKS:

(GEM213100726)(A)Allengers


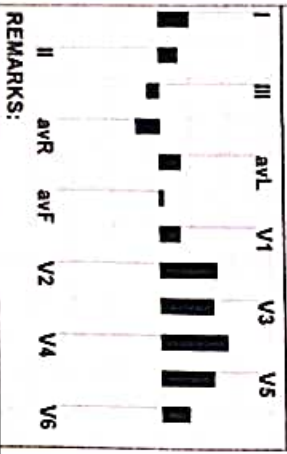
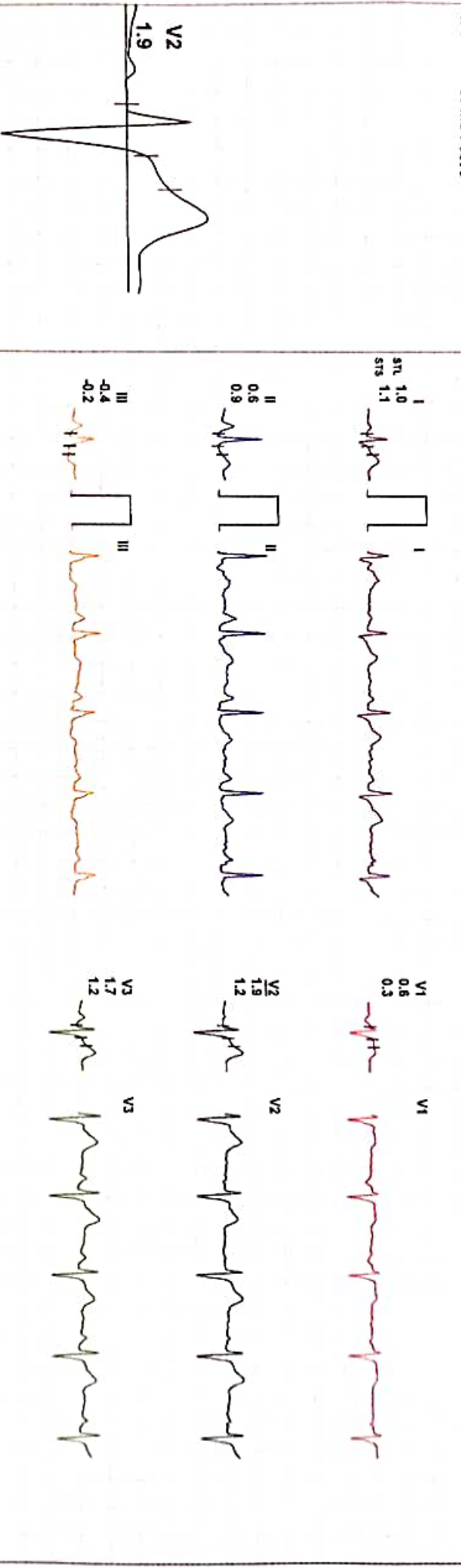


4041 / RANNDHIR KUMAR / 32 Yrs / M / 170 Cms / 80 Kg / HR : 87

Date: 16-Apr-2022 10:46:55 AM METS: 1.0/ 87 bpm 46% of THR BP:  $\frac{1}{1}$  mmHg Raw ECG/ BLC On/ Notch On/ HF 0.05 HZLF 20 Hz

ExTime: 00:57 1.0 mph, 0.0%  
25 mm/Sec. 1.0 Cm/mV

4X 80 ms Post J



(GEM213180726)(A)Allengers



Date: 16-Apr-2022 10:46:55 AM

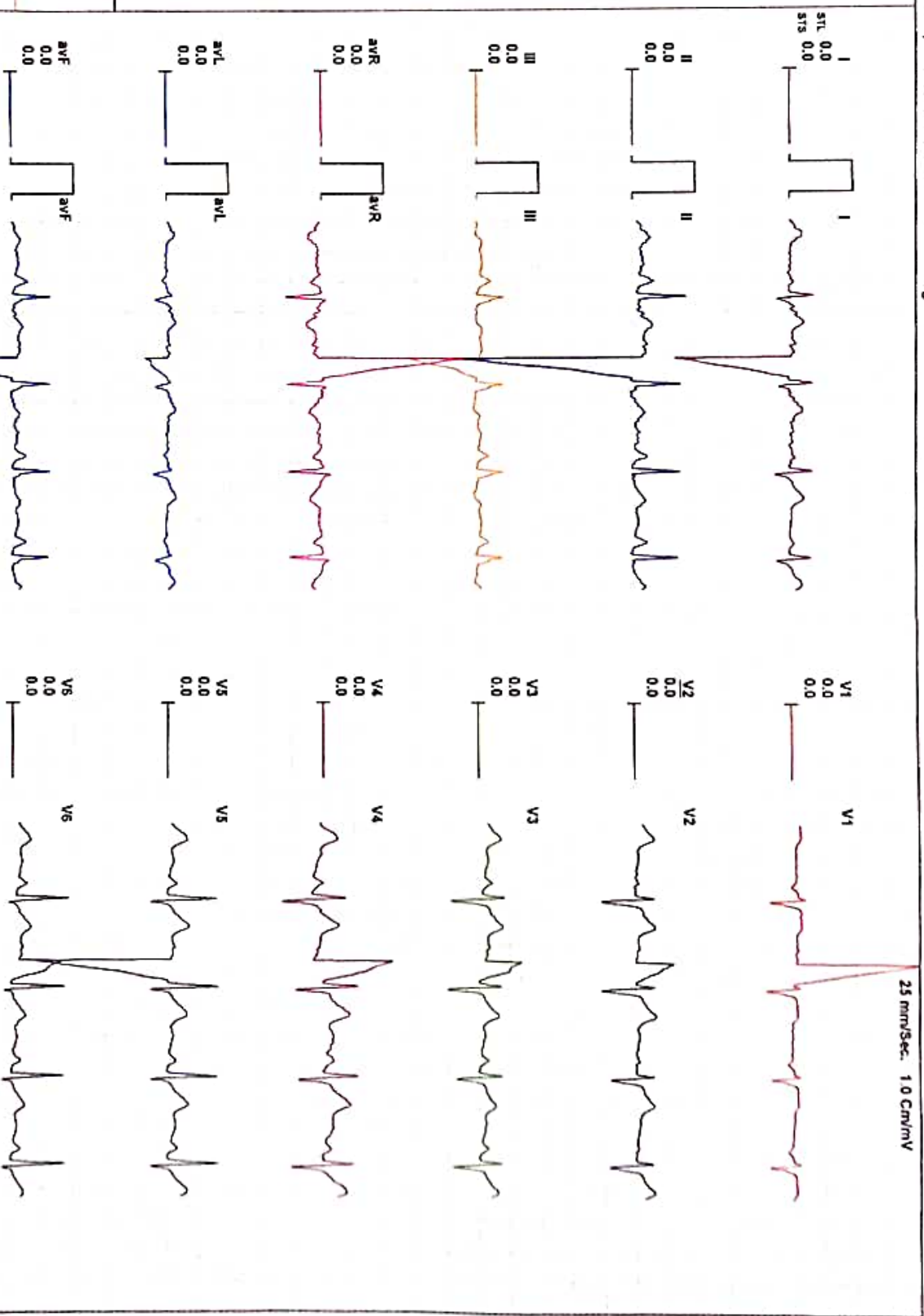
METS: 1.0/ 57 bpm 30% of THR BP:  $\downarrow$  mmHg Raw ECG/ BLC On/ Notch On/ HF 0.05 Hz/LF 20 Hz

ExTime: 00:12 0.0 mph, 0.0%

4X 60 ms Post J

25 mm/Sec. 1.0 Cm/mV

V2  
0.0



I	III	aVL	V1	V3	V5
II	aVR	aVF	V2	V4	V6

REMARKS:





# A.L.C. Advance Imaging Diagnostics

ISO 9001:2015 Certified center

(A Unit of P.K.Arogyam Health & Wellness Center)

E-95, P.C. Colony, Near Sai Netryalaya Transformer, Kankarbagh, Patna - 20

alcdiagnostics@gmail.com

www.pkarogyamhealthcheckup.com

7050037694, 8271206196

OPINION MUST BE CORRELATES WITH CLINICALLY & OTHER INVESTIGATION FOR FINAL DIAGNOSIS. NOT FOR MEDICO LEGAL PURPOSE

PATIENT NAME : Mr. KUMAR RANDHIR

PATIENT ID : 151

COL DATE : 16/04/2022 REPORTING DATE: 16/04/2022 AGE SEX:- 30 YRS/M

REF.BY : DR / MEDIWHEAL

TEST NAME	RESULT	Unit	REF.RANGE
Total Triiodothyronin T3	1.21 ng/mL		0.80 - 2.00 ng/mL
Total Thyroxin T4	8.04 µg/dL		5.10 - 14.10 µg/dL
Serum TSH	2.19 µIU/mL		0.27 - 4.20 µIU/mL

THYROID DISORDER (>: Increase: < Decrease: n Normal

1. T3(n) T4(n) TSH(n) :EUTHYROID STATE:
  2. T3(>) T4(>) TSH(<): HYPERTHYROIDISM:
  3. T3(<)T4(<) TSH(>): HYPOTHYROIDISM:
  4. T3(n)T4(n) TSH(>) : SUB-CLINICAL HYPO-THYROIDISM:
  5. T3(n)T4(n) TSH(<): SUB-CLINICAL HYPER-THYROIDISM:
  6. T3(>) T4(n) TSH(<): T3 THYROTOXICOSIS:
- Total T3/T4 level is dependent on Level:

So determination of free T3/T4is a better MARKER of Thyroid Function.

Dr. Ankur Kumar  
MBBS, MD  
Consultant Pathologist  
Reg No 39540

Consultant Radiologist

ESTB BY:-

Dr. P. K. Tiwari  
MD, M.Sc (Radio Imaging)  
Ph D (Ait Nuclear Medicine)  
Consultant Imagonologist & Sonologist

Dr. S. Kumar  
MD (Pat)  
Consultant Pathologist

Dr. Abhishek Kumar  
MBBS, MD  
Consultant Neuropatho Physiologist

Dr. Anjali  
MBBS, MD  
Consultant (TMT, EEG Specialist)

Dr. Kumari Suman  
MBBS, DGO, MD  
Consultant (TVS & HSG Specialist)

PRINTING MISTAKE SHOULD BE REPORTED BACK IMMEDIATELY/ यहाँ जन्म से पहले भुण का लिंग जाँच नहीं होता है ।



# A.L.C. Advance Imaging Diagnostics

ISO 9001:2015 Certified center

(A Unit of P.K.Arogyam Health & Wellness Center)

E-95, P.C. Colony, Near Sai Netryalaya Transformer, Kankarbagh, Patna - 20

alcdiagnostics@gmail.com

www.pkarogyamhealthcheckup.com

7050037694, 8271206196

OPINION MUST BE CORRELATES WITH CLINICALLY & OTHER INVESTIGATION FOR FINAL DIAGNOSIS. NOT FOR MEDICO LEGAL PURPOSE

PATIENT NAME : Mr. KUMAR RANDHIR

PATIENT ID: 151

COL DATE : 16/04/2022 REPORTING DATE: 16/04/2022 AGE SEX : 30 YRS/M

REF.BY : DR. /MEDIWHEEL.

TEST NAME	RESULT	Unit	REF.RANGE
BLOOD SUGAR ( F )	90.0 mg/dl		70 - 110 mg/dl

## LIPID PROFILE:-

TOTAL CHOLESTROL	153.8 mg/dl		130 -250 mg/dl
TRIGLYCERIDE	147.2 mg/dl		50 -160 mg/dl
HDL CHOLESTROL	41.0 mg/dl		30 - 60 mg/dl
LDL CHOLESTROL	83.4 mg/dl		80 -130 mg/dl
VLDL CHOLESTROL	29.4 mg/dl		15 - 40 mg/dl
T.CH./HDL RATIO	3.7:1		Upto 5:1
LDL./HDL RATIO	2.0:1		2 - 4:1

Dr. Ankur Kumar  
MBBS, MD  
Consultant Radiologist  
Reg No 59540

Consultant Radiologist

ESTB BY:-

Dr. P. K. Tiwari  
MD, M.Sc (Radio Imaging)  
Ph.D (Atr Nuclear Medicine)  
Consultant Imagonologist & Sonologist

Dr. S. Kumar  
MD (Pat)  
Consultant Pathologist

Dr. Abhishek Kumar  
MBBS, MD  
Consultant Neuropatho Physiologist

Dr. Anjali  
MBBS, MD  
Consultant(TMT,EEG Specialist)

Dr. Kumari Suman  
MBBS, DGO, MD  
Consultant (TVS & HSG Specialist)

PRINTING MISTAKE SHOULD BE REPORTED BACK IMMEDIATELY/ यहाँ जन्म से पहले भुण का लिंग जाँच नहीं होता है ।



# A.L.C. Advance Imaging Dignostics

ISO 9001:2015 Certified center

(A Unit of P.K.Arogyam Health & Wellness Center)

E-95, P.C. Colony, Near Sai Netryalaya Transformer, Kankarbagh, Patna - 20

alcdiagnostics@gmail.com

www.pkarogayamhealthcheckup.com

7050037694, 8271206196

OPINION MUST BE CORRELATES WITH CLINICALLY & OTHER INVESTIGATION FOR FINAL DIAGNOSIS. NOT FOR MEDICO LEGAL PURPOSE

PATIENT NAME : Mr . KUMAR RANDHIR

PATIENT ID: 151

COL DATE : 16/04/2022 REPORTING DATE: 16/04/2022 AGE SEX:- 30 YRS/M

REF.BY : DR. / MEDIWHEEL.

## ROUTINE EXAMINATION OF URINE

### PHYSICAL EXAMINATION

Quantity ....	30 ml	Colour....	Straw
Appearance...	Clear	Sediment ...	Nil
Specific gravity....	1.010		

### CHEMICAL EXAMINATION

Reaction ....	6.0	Nitrite.....	Not done
Sugar ....	Nil	Bile Pigment ....	Not done
Albumin ....	Nil	Urobilinogen....	Not done
Excess of Phosphate....	Nil	Chile.....	Not done
Bile Salt	Not Done	Acetone...	Not done

### MICROSCOPIC EXAMINATION

Erythrocytes....	Nil	Casts ....	Nil
Leucocytes ....	1-4 / HPE	Crystals... .	Nil
Epith. Cell ....	A, Few	Others ....	Nil

**Dr. Ankur Kumar**  
MBBS, MD  
Consultant Pathologist  
Reg. No. 39540

Consultant Radiologist

ESTB BY:-

**Dr. P. K. Tiwari**  
MD, M.Sc (Radio Imaging)  
Ph.D (AI Nuclear Medicine)  
Consultant Imagiologist & Sonologist

**Dr. S. Kumar**  
MD (Pat)  
Consultant Pathologist

**Dr. Abhishek Kumar**  
MBBS, MD  
Consultant Neuropathology Physiologist

**Dr. Anjali**  
MBBS, MD  
Consultant (TMT, EEG Specialist)

**Dr. Kumari Suman**  
MBBS, DGO, MD  
Consultant (TVS & HSG Specialist)

PRINTING MISTAKE SHOULD BE REPORTED BACK IMMEDIATELY/ यहाँ जन्म से पहले भ्रूण का लिंग जाँच नहीं होता है ।



# A.L.C. Advance Imaging Dignostics

ISO 9001:2015 Certified center

(A Unit of P.K.Arogyam Health & Wellness Center)

E-95, P.C. Colony, Near Sai Netryalaya Transformer, Kankarbagh, Patna - 20

alcdiagnostics@gmail.com

www.pkarogyamhealthcheckup.com

7050037694, 8271206196

OPINION MUST BE CORRELATES WITH CLINICALLY & OTHER INVESTIGATION FOR FINAL DIAGNOSIS. NOT FOR MEDICO LEGAL PURPOSE

PATIENT NAME : Mr. KUMAR RANDHIR

PATIENT ID: 151

COL DATE : 16/04/2022 REPORTING DATE: 16/04/2022 AGE SEX:- 30 YRS/M

REF.BY : DR./ MEDIWHEEL.

TEST NAME	RESULT	Unit	REF.RANGE
<b>LFT:-</b>			
SGPT	26.1 IU/L		5 - 48 IU/L
S G O T	20.5 IU/L		5 - 40 IU/L
ALKALINE PHOSPHATASE	92.2 IU/L		25 - 147 IU/L
TOTAL PROTIN	7.8 g/dl		6.0 - 8.7 g/dl
SERUM ALBUMIN	4.8 g/dl		3.5 - 5.4 g/dl
SERIUM GLUBLINE	3.0 g/dl		2.3 - 3.6 g/dl
AG RATIO	1.6 : 1		1.0 - 2.3 g/dl
<b>BILIRUBIN</b>			
TOTAL	0.54 mg/dl		0.1 - 1.1 mg/dl
IRECT	0.22 mg/dl		0.0 - 0.32 mg/dl
INDIRECT	0.32 mg/dl		0.0 - 0.78 mg/dl
<b>KFT/RFT</b>			
URIC ACID	4.9 mg/dl		3.2 - 7.0 mg/dl
SERUM CREATNINE	1.0 mg/dl		0.6 - 1.5 mg/dl
BLOOD URIA	32.4 mg/dl		5 - 45 mg/dl
BLOOD URIA NITROZEN(BUN).	15.1 mg/dl		13 - 39 mg/dl

Dr. Ankur Kumar  
MBBS, MD  
Consultant Pathologist  
Reg No 49540

Consultant Radiologist

ESTB BY:-

**Dr. P. K. Tiwari**

MD, M.Sc (Radio Imaging)

Ph.D (AIr Nuclear Medicine)

Consultant Imagonologist & Sonologist

**Dr. S. Kumar**

MD (Pat)

Consultant Pathologist

**Dr. Abhishek Kumar**

MBBS, MD

Consultant Neuropatho Physiologist

**Dr. Anjali**

MBBS, MD

Consultant(TMT,EEG Specialist)

**Dr. Kumari Suman**

MBBS, DGO, MD

Consultant (TVS & HSG Specialist)

PRINTING MISTAKE SHOULD BE REPORTED BACK IMMEDIATELY/ यहाँ जन्म से पहले भुण का लिंग जाँच नहीं होता है ।



# A.L.C. Advance Imaging Dignostics

ISO 9001:2015 Certified center

(A Unit of P.K.Arogyam Health & Wellness Center)

E-95, P.C. Colony, Near Sai Netryalaya Transformer, Kankarbagh, Patna - 20

alcdiagnostics@gmail.com

www.pkarogyamhealthcheckup.com

7050037694, 8271206196

OPINION MUST BE CORRELATES WITH CLINICALLY & OTHER INVESTIGATION FOR FINAL DIAGNOSIS. NOT FOR MEDICO LEGAL PURPOSE

PATIENT NAME : Mr. KUMAR RANDHIR

PATIENT ID: 151

COL DATE : 16/04/2022 REPORTING DATE: 16/04/2022 AGE SEX:- 30 YRS/M

REF.BY : DR. / MEDIWHEEL.

TEST NAME	RESULT	Unit	REF.RANGE
ESR	12 mm/hr		<20 mm/hr
CBC			
Total W.B.C. Count	8,600 /cumm		4000 -11,000 /cumm
R B C COUNT	4.50 Million/ CUmm		4 - 7 Million/ CUmm
Platelets count	1.65 Lakh/ cumm		1.5-5.0 Lakh/ cumm
Differential Count of W.B.C.			
Neutrophils	59 %		40-70%
Lymphocytes	36 %		25-40%
Eosinophils	04 %		01-05%
Mnonocytes	01 %		00-02%
Basophiles	00 %		00-0%
HAEMOGLOBIN	14.5 gm/dl ( 99.3 % )		14.6 gm/dl = 100%
PCV	43.8 %		35-47 %
MCV	97.2 fl		76-96 fl
MCH	32.3 pg		29-35 pg
MCHC	33.2 %		30-38 %

Dr. Ankur Kumar  
MBBS, MD  
Consultant Pathologist  
Reg No 39540

ESTB BY:-

Dr. P. K. Tiwari  
MD, M.Sc (Radio Imaging)  
Ph D (Al Nuclear Medicine)  
Consultant Imagiologist & Sonologist

Dr. S. Kumar  
MD (Pat)  
Consultant Pathologist

Dr. Abhishek Kumar  
MBBS, MD  
Consultant Neuropatho Physiologist

Dr. Anjali  
MBBS, MD  
Consultant(TMT,EEG Specialist)

Dr. Kumari Suman  
MBBS, DGO, MD  
Consultant (TVS & HSG Specialist)

Consultant Radiologist

PRINTING MISTAKE SHOULD BE REPORTED BACK IMMEDIATELY/ यहाँ जन्म से पहले भ्रुण का लिंग जाँच नहीं होता है ।



# A.L.C. Advance Imaging Diagnostics

ISO 9001:2015 Certified center

(A Unit of P.K.Arogyam Health & Wellness Center)

E-95, P.C. Colony, Near Sai Netryalaya Transformer, Kankarbagh, Patna - 20

alcdiagnostics@gmail.com

www.pkarogayamhealthcheckup.com

7050037694, 8271206196

OPINION MUST BE CORRELATES WITH CLINICALLY & OTHER INVESTIGATION FOR FINAL DIAGNOSIS. NOT FOR MEDICO LEGAL PURPOSE

PATIENT NAME : Mr. KUMAR RANDHIR

PATIENT ID : 151

COL DATE : 16/04/2022 REPORTING DATE: 16/04/2022 AGE SEX : 30 YRS/M

REF.BY : DR./ MEDIWHEEL.

## GLYCOSYLATED HEMOGLOBIN

TEST NAME	RESULT	Unit	REF.RANGE
HbA1c	3.9 %		Below 5.7 % : Normal 5.7 – 6.4 % : Prediabetic > = 6.5 % : Diabetic
AVERAGE PLASMA GLUCOSE	90.0 mg/dl		90 – 120 mg/dl : Good Control 121 – 150 mg/dl : Fair Control 151- 180 mg/dl: Unsatisfactory Control >180 mg/dl : Poor Control

Dr. Ankur Kumar  
MBBS, MD  
Consultant Pathologist  
Reg No 59540

Consultant Radiologist

ESTD BY:-

**Dr. P. K. Tiwari**  
MD, M.Sc (Radio Imaging)  
Ph.D (AI Nuclear Medicine)  
Consultant Imacionologist & Sonologist

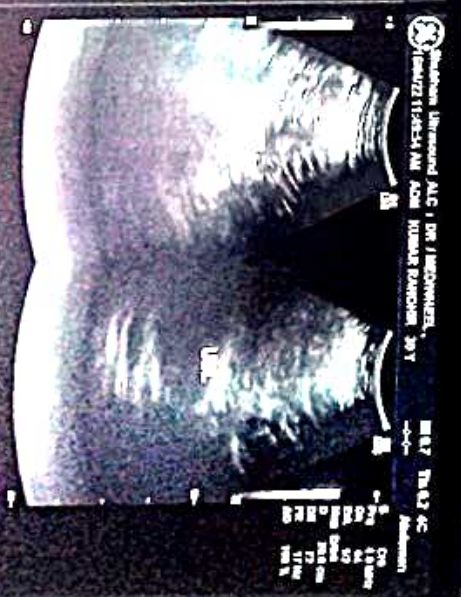
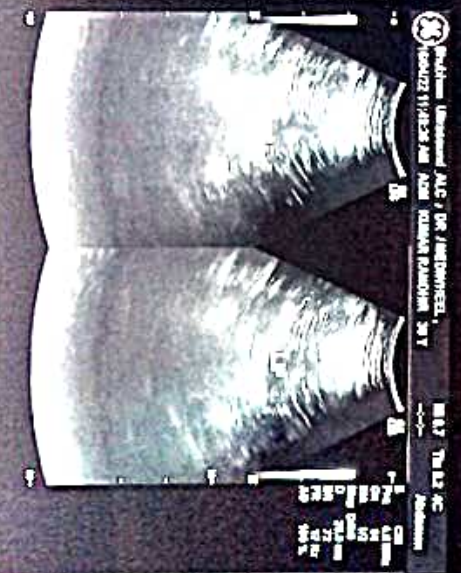
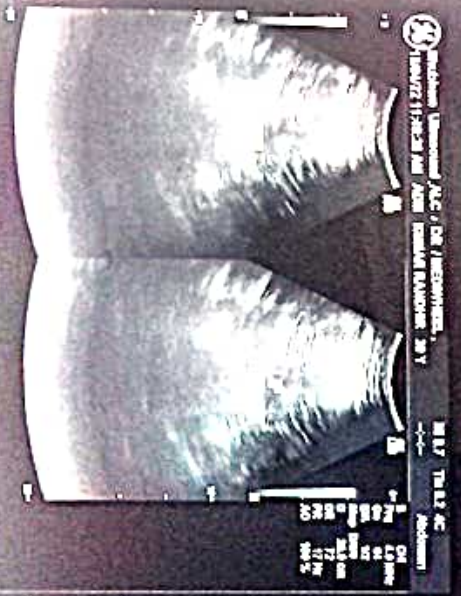
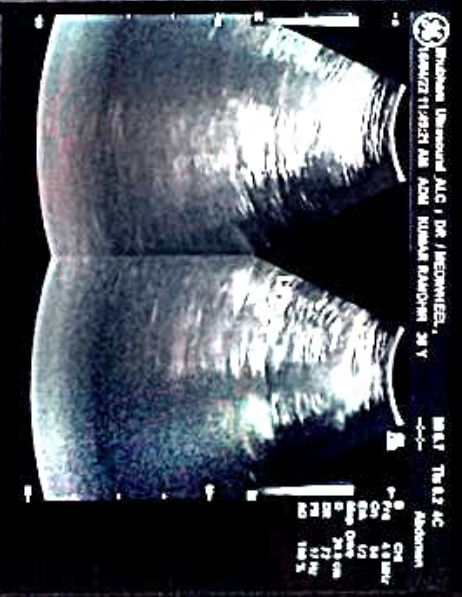
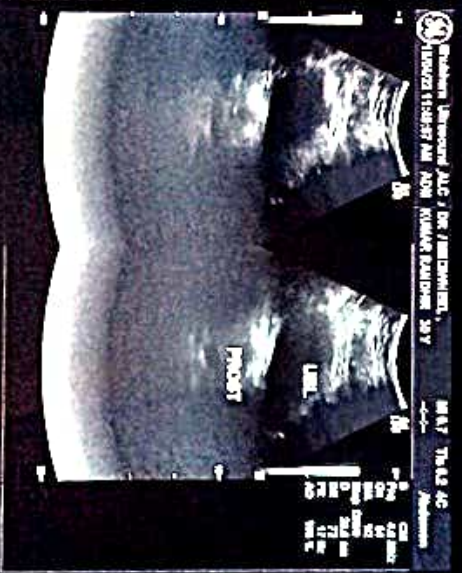
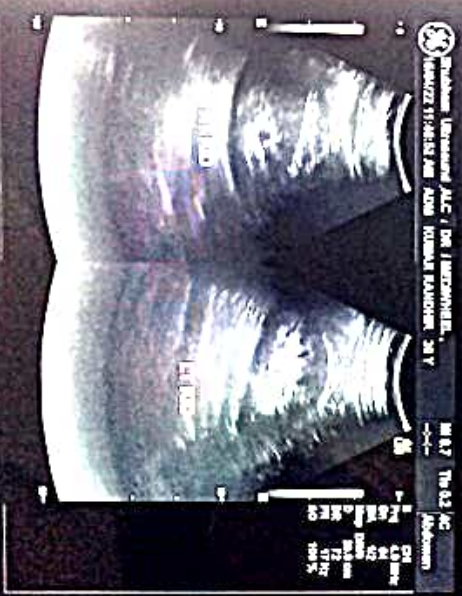
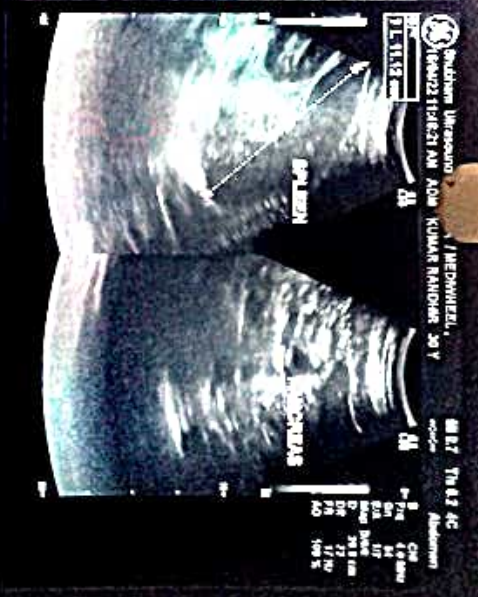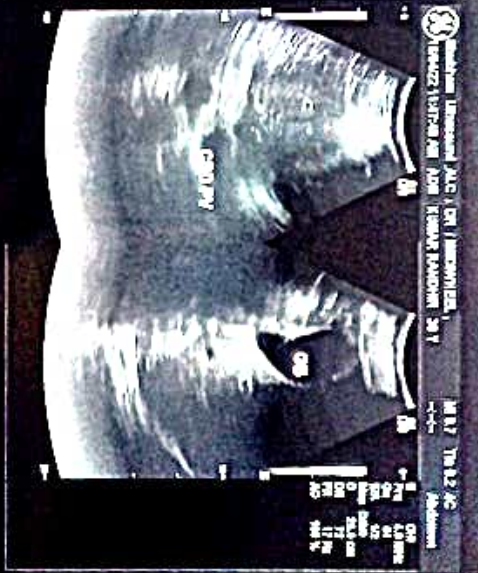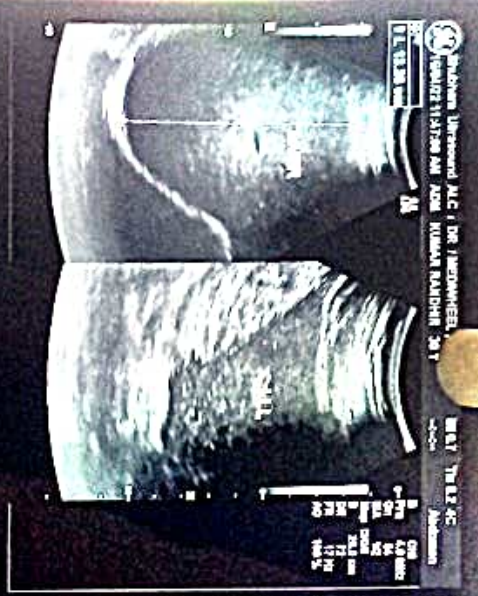**Dr. S. Kumar**  
MD (Pat)  
Consultant Pathologist

**Dr. Abhishek Kumar**  
MBBS, MD  
Consultant Neuropatho Physiologist

**Dr. Anjali**  
MBBS, MD  
Consultant(TMT,EEG Specialist)

**Dr. Kumari Suman**  
MBBS, DGO, MD  
Consultant (TVS & HSG Specialist)

PRINTING MISTAKE SHOULD BE REPORTED BACK IMMEDIATELY/ यहाँ जन्म से पहले भुण का लिंग जाँच नहीं होता है ।



ALC Advance Imaging Diagnostics Centro PAVIA-20



# A.L.C. Advance Imaging Dignostics

ISO 9001:2015 Certified center

(A Unit of P.K.Arogyam Health & Wellness Center)

E-95, P.C. Colony, Near Sai Netryalaya Transformer, Kankarbagh, Patna - 20

alcdiagnostics@gmail.com

www.pkarogyamhealthcheckup.com

7050037694, 8271206196

OPINION MUST BE CORRELATES WITH CLINICALLY & OTHER INVESTIGATION FOR FINAL DIAGNOSIS. NOT FOR MEDICO LEGAL PURPOSE

Pt. Name :- KUMAR RANDHIR

Ref. By :- DR. / MEDIWHEEL

Date:- 16-Apr-22

Age / Sex - 30 Yrs. M.

## REAL TIME U.S.G. OF WHOLE ABDOMEN

Thanks for your kind referral

### ( Report.)

- LIVER** :- Measures 13.26 cm. Normal in shape, size and echo texture. I.H.B.R. are not dilated. Hepatic veins are normal. No SOL seen.
- G.BL.** :- Lumen is echo free. Wall thickness appears normal.
- C.B.D.** :- Measures 3.3 mm in diameter with echo free lumen. No calculi or mass seen.
- P.V.** :- Measures 7.2 mm in diameter. Appears normal. No thrombus seen.
- PANCREAS** :- Normal in shape, size and echo texture. No calcification mass seen.
- SPLEEN** :- Measures 11.12 cm. Normal in shape, size and echo texture. No SOL seen.
- KIDNEY** :- Both kidney shows normal shape, size & echotexture. C.M.D.intact. P.C.S.is not dilated. No calculi, cyst or hydronephrosis seen on either side.  
*Right Kidney :- Measures 10.47 X 4.1 cm.*  
*Left Kidney :- Measures 10.51 X 4.2 cm.*
- URETER** :- Not dilated. No apparent calculi seen.
- U.BLADDER**:- Shows normal in outline with echo free lumen. No calculi or mass seen.  
*Pre void - 280 ml. Post void - is in significant*
- PROSTATE** :- Measures 15 gms (approx). Appears Normal in size, shape, and echo texture. No calcification, mass, growth seen. capsule is intact.
- R.I.F.** :- Son graphically no appendicular mass or collection seen.
- OTHERS** :- No Ascites, no Lymph Adenopathy. No pleural effusion seen on either side.

## IMPRESSION

➤ *Son graphically normal scan no detectable lesion seen*

ESTD BY:-

**Dr. P. K. Tiwari**  
MD, M.Sc (Radio Imaging)  
Ph.D (Art Nuclear Medicine)  
Consultant Imaginologist & Sonologist

**Dr. S. Kumar**  
MD (Pat)  
Consultant Pathologist

**Dr. Abhishek Kumar**  
MBBS, MD  
Consultant Neuropathologist

**Dr. Anjali**  
MBBS, MD  
Consultant (TMT, EEG Specialist)

**Dr. Kumari Suman**  
MBBS, DGO, MD  
Consultant (TVS & HSG Specialist)

PRINTING MISTAKE SHOULD BE REPORTED BACK IMMEDIATELY/ यहाँ जन्म से पहले भ्रुण का लिंग जाँच नहीं होता है ।





# A.L.C. Advance Imaging Dignostics

ISO 9001:2015 Certified center

(A Unit of P.K.Arogyam Health & Wellness Center)

E-95, P.C. Colony, Near Sai Netryalaya Transformer, Kankarbagh, Patna - 20

alcdiagnostics@gmail.com

www.pkarogyamhealthcheckup.com

7050037694, 8271206196

OPINION MUST BE CORRELATES WITH CLINICALLY & OTHER INVESTIGATION FOR FINAL DIAGNOSIS. NOT FOR MEDICO LEGAL PURPOSE

Pt. Name :- **RANDHIR KUMAR**  
Ref. By :- **DR. MEDIWHEEL**

Date:- **16-Apr-22**  
Age / Sex - **30 Yrs. M.**

Thanks for your kind referral

## X-RAYCHEST (P.A.VIEW)

The lungs on the either side show equal translucency.

The peripheral pulmonary vasculature is normal.

No focal lung lesion is seen.

The pleural spaces are normal.

Both hila are normal in size, have equal density and bear normal relationship.

The heart and trachea are central in position and no mediastinal abnormality is visible.

The cardiac size is normal.

The domes of the diaphragms are normal in position, and show smooth outline.

## IMPRESSION

- NO EVIDENCE OF PULMONARY OR CARDIAC PATHOLOGY IS NOTED.

  
Ranjiv Kumar  
MBBS, PCET, DCCBDM  
Consultant Cardiologist  
Consultant Radiologist

ESTD BY:-

**Dr. P. K. Tiwari**  
MD, M.Sc (Radio Imaging)  
Ph D (Ait Nuclear Medicine)  
Consultant Imaginologist & Sonologist

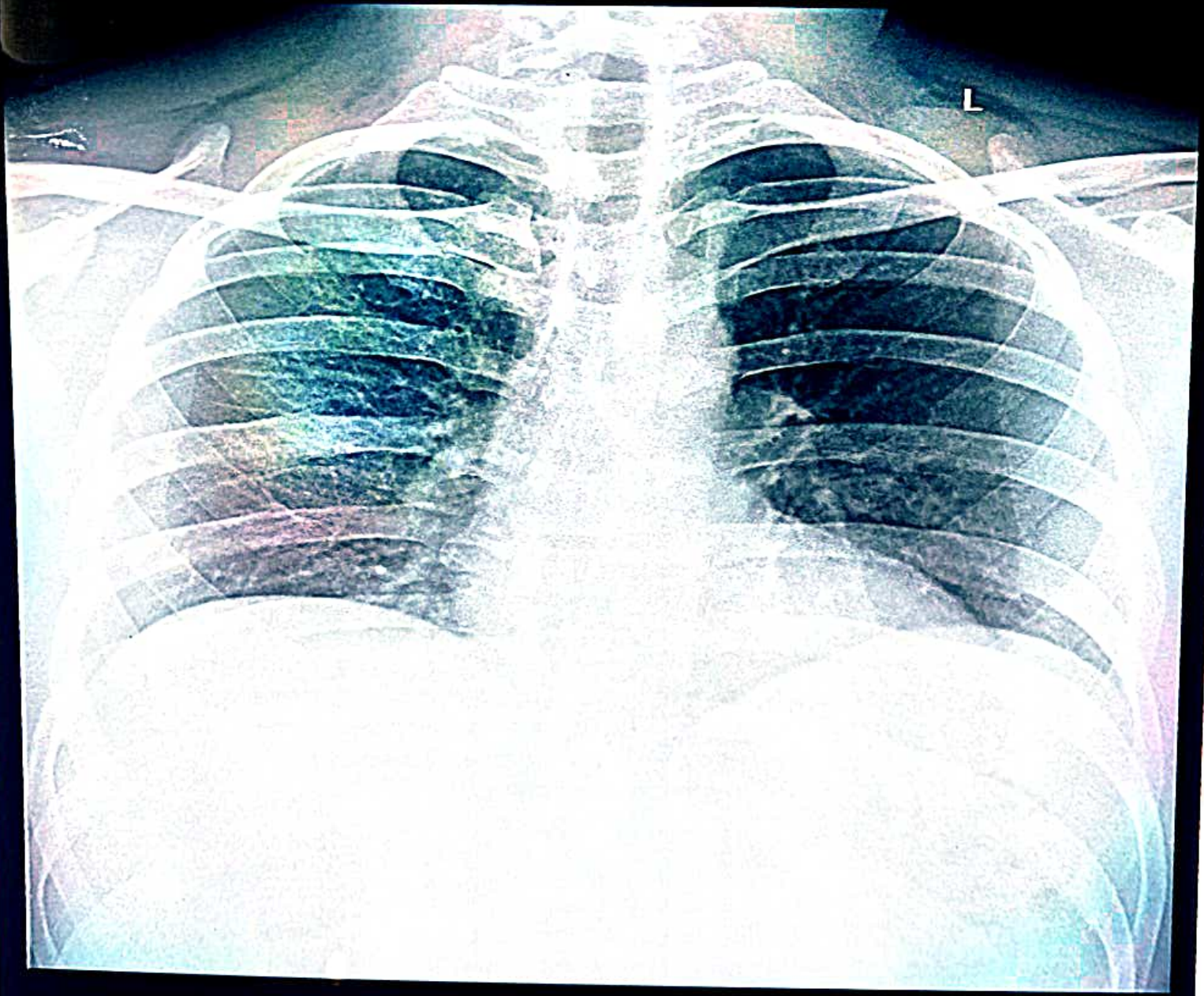
**Dr. S. Kumar**  
MD (Pat)  
Consultant Pathologist

**Dr. Abhishek Kumar**  
MBBS, MD  
Consultant Neuropatho Physiologist

**Dr. Anjali**  
MBBS, MD  
Consultant(TMT,EEG Specialist)

**Dr. Kumari Suman**  
MBBS, DGO, MD  
Consultant (TVS & HSG Specialist)

PRINTING MISTAKE SHOULD BE REPORTED BACK IMMEDIATELY/यहाँ जन्म से पहले भुण का लिग जाँच नहीं होता है ।



RANDHIR KUMAR AGE 30 YEARS 151 MEDIWHEEL CHEST,FRN P->A 4/16/2022  
A.L.C. Advance Imaging Diagnostics Centre PATNA - 20