



Mittal Hospital

For Appointment PH: 01679-237777
For Emergency M: 99142-16070
mittal_parshant@yahoo.com

ਮਿੱਤਲ ਹਸਪਤਾਲ

ਡਾ. ਪ੍ਰਸ਼ਾਂਤ ਮਿੱਤਲ

ਨੇੜੇ ਪਨਸਪ ਗੈਸ ਏਜੰਸੀ, ਨੇੜੇ ਆਰੀਆ ਮਹਿਲਾ ਕਾਲਜ, ਰਾਮ ਬਾਗ ਰੋਡ, ਬਰਨਾਲਾ

ਐਮ.ਡੀ. ਮੈਡੀਸਨ (ਡੀ.ਐਮ.ਸੀ. ਲੁਧਿਆਣਾ)
ਐਕਸ ਮੈਡੀਕਲ ਅਫਸਰ, ਸਿਵਲ ਹਸਪਤਾਲ, ਬਰਨਾਲਾ
ਐਕਸ ਸੀਨੀਅਰ ਰਜਿਸਟਰਾਰ, ਫੋਰਟੀਜ਼ ਹਸਪਤਾਲ, ਮੁਹਾਲੀ
ਐਕਸ ਸਪੈਸ਼ਲਿਸਟ, ਰਾਧਾ ਸੁਆਮੀ ਹਸਪਤਾਲ, ਬਿਆਸ
(ਦਿਲ, ਪੇਟ, ਛਾਤੀ, ਸ਼ੁਗਰ ਅਤੇ ਕਾਲੇ ਪੀਲੀਏ ਦੇ ਮਾਹਿਰ)
PMC Regd. No. 37514

Near Pansup Gas Agency, Near LBS College,
Ram Bagh Road, BARNALA-148101 (Pb.)

ਡਾ: ਪ੍ਰੀਆ ਗਰਗ

ਐਮ.ਡੀ. ਐਨਸਥੀਜ਼ੀਆ (ਡੀ.ਐਮ.ਸੀ. ਲੁਧਿਆਣਾ)
ਐਕਸ ਸੀਨੀਅਰ ਰਜਿਸਟਰਾਰ ਡੀ ਐਮ ਸੀ, ਲੁਧਿਆਣਾ
ਐਕਸ ਸੀਨੀਅਰ ਰਜਿਸਟਰਾਰ ਪੀ ਜੀ ਆਈ, ਚੰਡੀਗੜ੍ਹ
ਐਕਸ ਕਨਸਲਟੈਂਟ ਰਾਧਾ ਸੁਆਮੀ ਹਸਪਤਾਲ, ਬਿਆਸ
(ਆਈ.ਸੀ.ਯੂ. ਅਤੇ ਕਰੀਟੀਕਲ ਕੇਅਰ ਸਪੈਸ਼ਲਿਸਟ)
PMC Regd. No. 36677

Name..... Age..... Sex..... Dated.....


X-RAY REPORT

Name: GAURAV GUPTA 36/M
Dr.: PARSHANT MITTAL

Date: 11/02/23

X- Ray Report: Chest pa view:

Bony cage and ribs are unremarkable.
Trachea is central.
Both CP angles are clear.
Cardiac silhouette and size are normal.
Lungs show normal parenchyma with no other active lesion.
No scar mark present.


DR. PARSHANT MITTAL
M. D. MEDICINE

Dr. Parshant Mittal
M.D. Medicine
PMC Regd. No. 37514
Mittal Hospital, Barnala



MITTAL HOSPITAL

Near Pansup Gas Agency, Near LBS College, Ram Bagh Road, BARNALA-148101 (Pb.)

For Appointment
FH 01679-237777
For Emergency
M: 99142-16070

Dr. Parshant Mittal

mittal_parshant@yahoo.com

M.D. Medicine (D.M.C. Ludhiana)
Ex. Medical Officer, Civil Hospital, Barnala
Ex. Sen. Registrar, Fortis Hospital, Mohali
Ex. Specialist, Radha Soami Hospital, Beas
PMC Regd. No. 37514

Dr. Priya Garg

M.D. Anaesthesiology
Consultant Anaesthesiology
Ex. Registrar DMC, Ludhiana
Ex. Sr. Registrar PGI, Chandigarh
Ex. Consultant Radha Soami Hospital, Beas
PMC Regd. No. 36677

ECHOCARDIOGRAPHY REPORT

Name: GAURAV GUPTA

Date: 11.02.2023

AGE: 34 YEARS

Sex: MALE

Done by: Dr. Parshant Mittal

	<u>MEASUREMENT</u>	<u>NORMAL ADULT VALUES</u>
AORTIC ROOT	: 39.3	(22 – 37 mm)
LEFT ATRIUM	: 30.7	(20 – 40 mm)
RVID (D)	: 12.1	(10 – 20 mm)
IVST (D)	: 10.0	(07 – 11 mm)
IVST (S)	: 11.4	(07 – 11 mm)
LVID (D)	: 57.9	(35 – 55 mm)
LVID (S)	: 37.9	(25 – 42 mm)
LVPW (D)	: 08.6	(07 – 11 mm)
LVPW (S)	: 11.4	(07 – 11 mm)
	<u>L.V. FUNCTION</u>	
EJECTION FRACTION	: 64.29%	(50 – 80%) (mod. simpson)
FRACTIONAL SHORTENING	: 34.57%	(28 – 40%)

Mitral Valve : Thin, opens normally. No regurgitation present.
MVA=3.04cm², EPSS=0.50, MAPSE=11mm. "E" wave more than "A".
E/A ratio=1.14

Aortic Valve : Thin, tricuspid, opens normally.
No aortic regurgitation present.

Tricuspid Valve : Thin, opens normally.
No tricuspid regurgitation present.

Pulmonary Valve : Thin, opens normally.

Pericardium : No pericardial effusion present.

Wall Motion Abnormalities: No regional wall motion abnormalities present.

Cardiac Chambers : All the cardiac chambers are normal in size.

DOPPLER EVALUATION

VELOCITY (GRADIENT)		(GRADE)
MV : E=93 A=81	cm/sec.	MR : NIL
AV : 111	cm/sec.	AR : NIL
TV :	cm/sec.	TR : NIL
PV :	cm/sec	PR : NIL

> **NO REGIONAL WALL MOTION ABNORMALITIES PRESENT WITH NORMAL LV SYSTOLIC FUNCTION (EF=64.29%).**

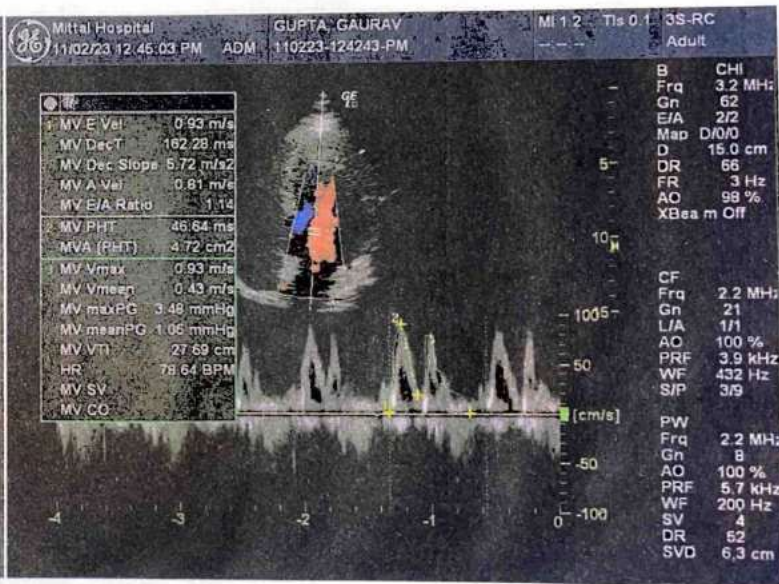
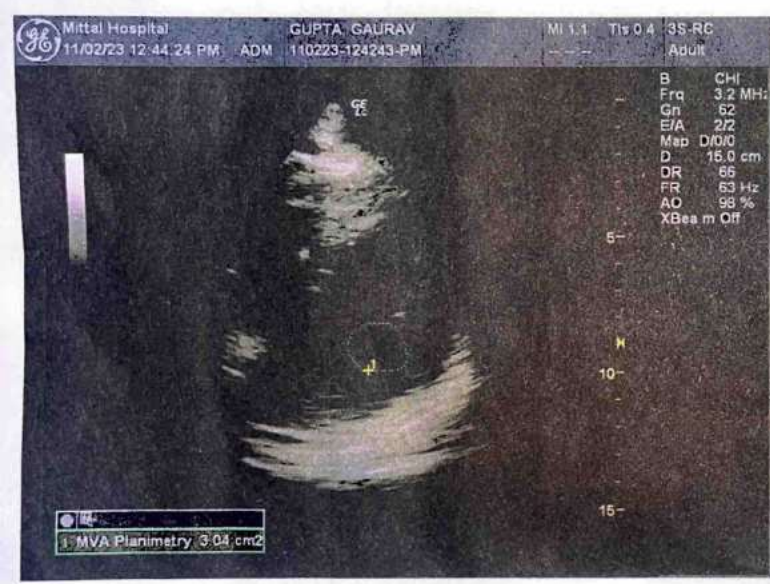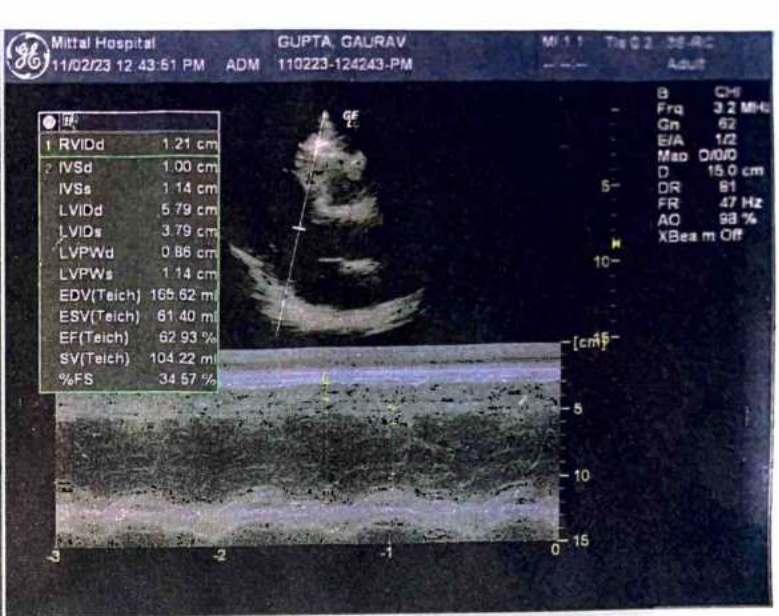
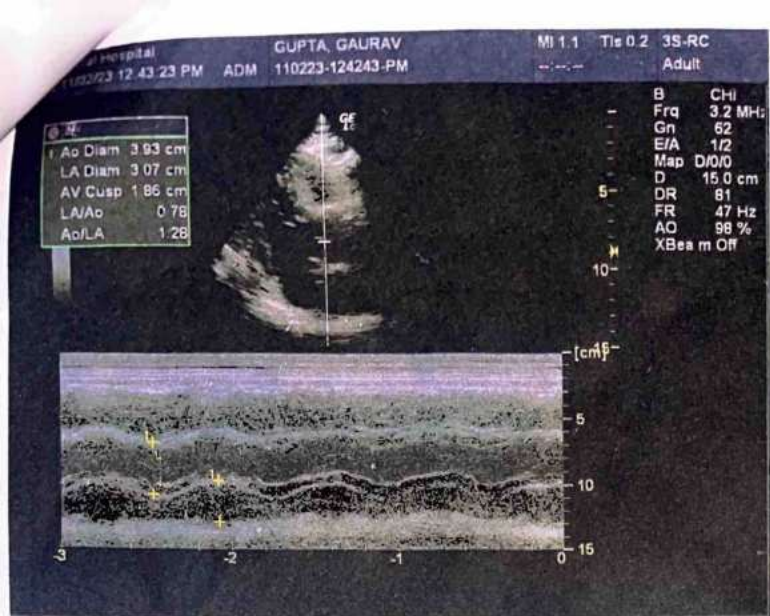


DR. PARSHANT MITTAL

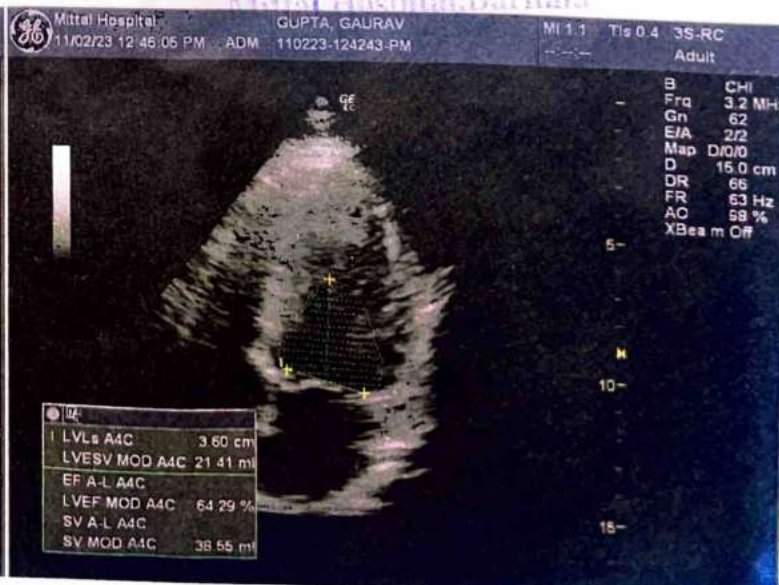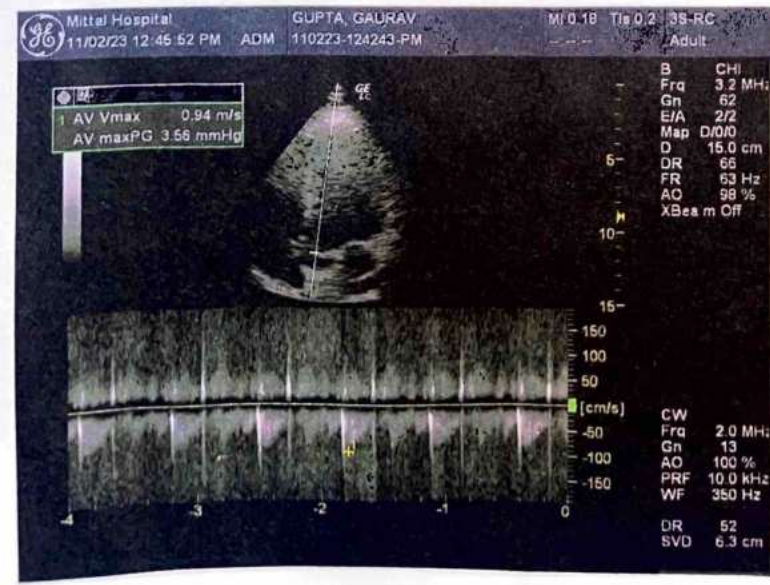
MITTAL HOSPITAL, BARNALA
MD (MEDICINE)

Dr. Parshant Mittal
M.D. Medicine
PMC Regd. No. 37514
Mittal Hospital, Barnala

Not valid for Medico Legal Purpose



Dr. Parshant Mittal
M.D. Medicine
PMC Regd. No. 37514
Mittal Hospital, Barnala



MITTAL COMPUTERISED LAB.

Inside Mittal Hospital, BARNALA-148101

Patient's Name... GAURAV GUPTA 34/M Ref. By Dr. PARSHANT MITTAL Dated..... 11-02-2023

HEMATOLOGY

TEST	RESULT	NORMAL RANGE
Haemoglobin	14.3 gm/dl	Male 12.0-15.5 gm/dl Female 10-13.5 gm/dl
T.L.C.	6200 /cumm	4000-11000/cumm
D.L.C. (Different Leucocyte Count)		
Neutrophils	61 %	40-75%
Lymphocytes	30 %	20-45%
Eosinophils	03 %	1-6%
Monocytes	06 %	2-10%
Basophils	00 %	0-1%
MCV	93	80-99 fl
MCH	31	26-32 pg
MCHC	35	32-36 gm/dl
RDW	45	37-54 fl
Hematocrit	43	³⁷⁻⁵²
ESR (Westergreen)	03 mm. 1st Hr.	Male upto 10mm. 1st Hour. Female upto 20mm. 1st Hour.
Platelet Count	312000 /cumm.	1,50000-4,00000/cu.mm.
T Eosinophil Count	/Cumm	40-440 Cell/cumm
Total RBC COUNT	5.8	4.7-6.2 to 10 ⁶ /µl

SEROLOGY

Widal Test	1:20	1:40	1:80	1:160	1:320	1:640
S. Typhi O	-	-	-	-	-	-
S. Typhi H	-	-	-	-	-	-
S. Paratyphi AH	-	-	-	-	-	-
S. Paaratyphi BH	-	-	-	-	-	-
Dengue NS1						
Dengue IgM/IgG						
TSH:	3.79			(0.550-4.780 uIU/ml)		
S. T4 LEVEL:	102.6			(77-155 nmol/l)		
S. T3 LEVEL:	4.12			(0.3-4 mU/l)		
S. Vitamin D LEVEL:				(30-100 ng/mL)		

URINE EXAMINATION

ROUTINE EXAMINATION	
Appearance :	CLEAR
Colour :	STRAW
Sp. Gravity :	1.015
Reaction :	ACIDIC
Albumin :	NIL
Sugar :	NIL
Bile Salts:	NIL
Bile Pigments :	NIL
MICROSCOPIC EXAMINATION	
RBC	NIL
Pus Cells	OCCASIONAL
Epithelial Cells	0-1/hpf
Calcium Oxalate	NIL
Spermatozoa	
URINE FOR MICROALBUMIN :	(0.00-25.0 mg/l)
URINE FOR NICOTINE:	(<5ng/ml)

BIO-CHEMISTRY

TEST	RESULT	NORMAL RANGE
Blood Sugar Fasting	89 mg/dl.	80-120 mg/dl.
Blood Sugar PP/Random	98 Mg/dl.	Upto 140 mg/dl.
Blood Urea Nitrogen	14 Mg/dl.	10-20 mg/dl.
S. Creatinine	0.7 mg/dl.	0.8-1.4 gm/dl.
S. Uric Acid	3.4 mg/dl.	Male 2-5 mg/dl. Female 2-4.5 mg/dl.
Blood Group	A	

LIVER FUNCTION TEST

S. Bilirubin (Total)	0.48 mg/dl.	0.2-1.0 mg/dl.
Conjugated	0.22	0.1-0.4 mg/dl
Unconjugated	0.26	0.1-0.6 mg/dl
S. Alkaline Phosphatase	86 U/L	37-147U/L
S.G.O.T.	20 U/L	10-40 Units/ml
S.G.P.T.	23 U/L	10-35 Units/ml
G.G.T.P	19	0-40 U/L
AUSTRALIA ANTIGEN		(Hbs Ag) Test
HBeAg		
Total Serum Proteins	7.7 gm/dl.	6.0-8.0 gm/dl.
Albumin	4.6 Gm/dl.	3.5-5.0 gm/dl.
Globulin	3.1 gm/dl.	2.0-3.5 gm/dl
S. Lipase	U/L	20-85 U/L
S. Amylase	U/L	25-80 U/L

LIPIDOGRAM

S. Cholesterol	154 mg/dl.	130-240 mg/dl.
S. Triglycerides	132 mg/dl.	60-170 mg/dl.
S. HDL Cholesterol	41 mg/dl.	30-60 mg/dl.
S. LDL Cholesterol	94 Mg/dl.	Upto 150 mg/dl
S. VLDL Cholesterol	32 Mg/dl.	Upto 45 mg/dl.

ELECTROLYTES TEST

S. Chloride	mmol/L.	96-106 mmol/L.
S. Sodium	Mmol/L	135-155 mmol/L
S. Potassium	mmol/L	3.5-5.5 mmol/L

GLYCOSYLATED HEMOGLOBIN (HbA1c)

Reference Range	4.0 - 6.0 %	5.4 %
Good Diabetic Control	6.0 - 7.0 %	
Fair Control	7.0 - 8.0 %	
Poor Control	Above 8.0 %	
HbA1C test Value in %		Mean Plasma Glucose Level
12.0		345
11.0		310
10.0		275
9.0		240
8.0		205
7.0		170
6.0		135
5.0		100

Medical Technologist

Dr. Sawan Kumar
M.D. Pathology
Reg. No. 45679



Mittal Hospital

ਮਿੱਤਲ ਹਸਪਤਾਲ

For Appointment PH: 01679-237777
For Emergency M: 99142-16070
mittal_parshant@yahoo.com

ਡਾ. ਪ੍ਰਸ਼ਾਂਤ ਮਿੱਤਲ

ਐਮ.ਡੀ. ਮੈਡੀਸਨ (ਡੀ.ਐਮ.ਸੀ. ਲੁਧਿਆਣਾ)
ਐਕਸ ਮੈਡੀਕਲ ਅਫਸਰ, ਸਿਵਲ ਹਸਪਤਾਲ, ਬਰਨਾਲਾ
ਐਕਸ ਸੀਨੀਅਰ ਰਜਿਸਟਰਾਰ, ਫੋਰਟੀਜ਼ ਹਸਪਤਾਲ, ਮੁਹਾਲੀ
ਐਕਸ ਸਪੈਸ਼ਲਿਸਟ, ਰਾਧਾ ਸੁਆਮੀ ਹਸਪਤਾਲ, ਬਿਆਸ
(ਦਿਲ, ਪੇਟ, ਫਾਤੀ, ਸ਼ੂਗਰ ਅਤੇ ਕਾਲੇ ਪੀਲੀਏ ਦੇ ਮਾਹਿਰ)
PMC Regd. No. 37514

ਨੇੜੇ ਪਨਸਪ ਗੈਸ ਏਜੰਸੀ, ਨੇੜੇ ਆਰੀਆ ਮਹਿਲਾ ਕਾਲਜ, ਰਾਮ ਬਾਗ ਰੋਡ, ਬਰਨਾਲਾ

Near Pansup Gas Agency, Near LBS College,
Ram Bagh Road, BARNALA-148101 (Pb.)

ਡਾ: ਪ੍ਰੀਆ ਗਰਗ

ਐਮ.ਡੀ. ਐਨਸਬੀਜੀਆ (ਡੀ.ਐਮ.ਸੀ. ਲੁਧਿਆਣਾ)
ਐਕਸ ਸੀਨੀਅਰ ਰਜਿਸਟਰਾਰ ਡੀ ਐਮ ਸੀ, ਲੁਧਿਆਣਾ
ਐਕਸ ਸੀਨੀਅਰ ਰਜਿਸਟਰਾਰ ਪੀ ਜੀ ਆਈ, ਚੰਡੀਗੜ੍ਹ
ਐਕਸ ਕਨਸਲਟੈਂਟ ਰਾਧਾ ਸੁਆਮੀ ਹਸਪਤਾਲ, ਬਿਆਸ
(ਆਈ.ਸੀ.ਯੂ. ਅਤੇ ਕਰੀਟੀਕਲ ਕੇਅਰ ਸਪੈਸ਼ਲਿਸਟ)
PMC Regd. No. 36677

Name..... Age..... Sex..... Dated.....

Name- GAURAV GUPTA

Age/sex - 36/M

Ref by: Dr. PARSHANT MITTAL

Date-February 11, 2023

USG WHOLE ABDOMEN

Liver- is normal in size (13.4 cm), shape, position and echotexture. No obvious focal lesion is seen. Intrahepatic biliary radicals are not dilated. Portal vein is normal in course and caliber.

Gall Bladder is normally distended. Wall thickness is normal. No evidence of calculus. **Common bile duct** is normal in course and caliber.

Pancreas is normal in size and echotexture. Main pancreatic duct is not dilated.

Right Kidney is normal in size, position and echotexture. Corticomedullary differentiation maintained. No evidence of calculus/ hydronephrosis.

Left Kidney is normal in size, position and echotexture. Corticomedullary differentiation maintained. No evidence of calculus/ hydronephrosis.

Spleen is normal in size, shape and echotexture. Splenic vein is normal in caliber.

Urinary bladder is distended. Wall thickness is normal. No evidence of calculus.

Prostate ~ measures cc in volume and shows normal echopattern.

No e/o free fluid in peritoneal cavity.

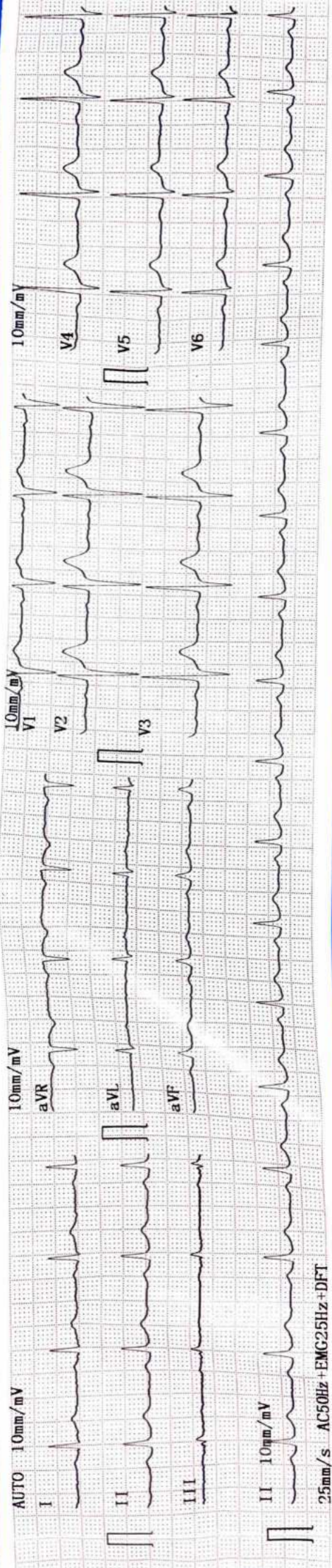
IMPRESSION- USG abdomen reveals- Normal study

Kindly correlate clinically/Lab parameters (CBC, Urine C/E).

DR. PARSHANT MITTAL

M. D. MEDICINE

Dr. Parshant Mittal
M.D. Medicine
PMC Regd. No. 37514
Mittal Hospital, Barnala



AUTO 10mm/mV
I
II
III
aVR
aVL
aVF
V1
V2
V3
V4
V5
V6
10mm/mV
10mm/mV
25mm/s AC50Hz + EMG25Hz + DFT

<< Conclusions >>

MITTAL HOSPITAL
1970-06-18 20:02

Normal Sinus Rhythm,
Normal Cardiac Electric Axis

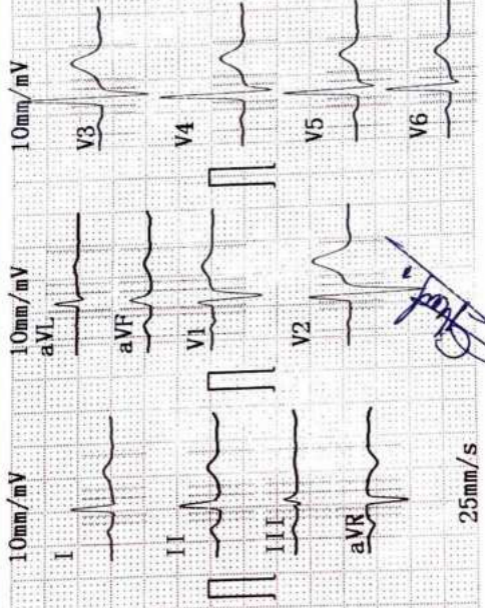
**Report need physician confirm

NOCLMAC ECG

Dr. Parvinder Arora
11/1/23
Physician

ID: _____
Name: CAURAV GUPTA Age: 36 kg
Sex: M Height: _____ cm Weight: _____ kg
SYS: _____ mmHg
DIA: _____ mmHg

HR [bpm] : 81
PR Interval [ms] : 172
P Duration [ms] : 130
QRS Duration [ms] : 105
T Duration [ms] : 205
QT/QTc [ms] : 367/428
P/QRS/T Axis [deg] : 59.3/45.3/44.4
R (V5) / S (V1) [mV] : 1.12/0.74
R (V5) + S (V1) [mV] : 1.86



25mm/s

[Signature]



ਭਾਰਤ ਸਰਕਾਰ

Government of India



ਗੌਰਵ ਗੁਪਤਾ

Gaurav Gupta

ਜਨਮ ਮਿਤੀ/DOB: 29/05/1986

ਮਰਦ/ MALE

Mobile:- 9888403803



8686 0911 4795

ਮੇਰਾ ਆਧਾਰ, ਮੇਰੀ ਪਛਾਣ



ਭਾਰਤੀ ਵਿਲੱਖਣ ਪਛਾਣ ਅਥਾਰਟੀ

Unique Identification Authority of India

Address:

S/O Sat Paul Gupta, Kothi No. 10,16
Acre Scheme , Near Bus Stand,
Barnala, Barnala,
Punjab - 148101

ਪਤਾ:

S/O ਸੱਤ ਪਾਲ ਗੁਪਤਾ, ਕੋਠੀ ਨੰਬਰ 10, 16
ਏਕੜ ਸਕੀਮ , ਨੇੜੇ ਬਸ ਸਟੈਂਡ, ਬਰਨਾਲਾ,
ਬਰਨਾਲਾ,
ਪੰਜਾਬ - 148101

8686 0911 4795



help@uidai.gov.in

www

www.uidai.gov.in

