



Patient Name : Mrs.POOJA AHUJA	Collected : 27/Jan/2024 08:19AM
Age/Gender : 33 Y 11 M 6 D/F	Received : 27/Jan/2024 12:36PM
UHID/MR No : CWAN.0000134274	Reported : 27/Jan/2024 01:22PM
Visit ID : CWANOPV225172	Status : Final Report
Ref Doctor : Dr.SELF	Sponsor Name : ARCOFEMI HEALTHCARE LIMITED
Emp/Auth/TPA ID : 395272159856	

DEPARTMENT OF HAEMATOLOGY

PERIPHERAL SMEAR , WHOLE BLOOD EDTA

RBC's Anisocytosis++, Microcytes++, Elliptocytes+
WBC's are normal in number and morphology
Platelets are Adequate
No Abnormal cells/hemoparasite seen.



Sheha Shah
Dr Sheha Shah
MBBS, MD (Pathology)
Consultant Pathologist

SIN No:BED240019185

This test has been performed at Apollo Health and Lifestyle ltd- Sadashiv Peth Pune, Diagnostics Lab



Patient Name : Mrs.POOJA AHUJA	Collected : 27/Jan/2024 08:19AM
Age/Gender : 33 Y 11 M 6 D/F	Received : 27/Jan/2024 12:36PM
UHID/MR No : CWAN.0000134274	Reported : 27/Jan/2024 01:22PM
Visit ID : CWANOPV225172	Status : Final Report
Ref Doctor : Dr.SELF	Sponsor Name : ARCOFEMI HEALTHCARE LIMITED
Emp/Auth/TPA ID : 395272159856	

DEPARTMENT OF HAEMATOLOGY

ARCOFEMI - MEDIWHEEL - FULL BODY HEALTH ANNUAL PLUS CHECK - FEMALE - 2D ECHO - PAN INDIA - FY2324

Test Name	Result	Status	Unit	Bio. Ref. Range	Method
HEMOGRAM , WHOLE BLOOD EDTA					
HAEMOGLOBIN	12.8	Normal	g/dL	12-15	Spectrophotometer
PCV	37.70	Normal	%	36-46	Electronic pulse & Calculation
RBC COUNT	6.52	High	Million/cu.mm	3.8-4.8	Electrical Impedence
MCV	57.9	Low	fL	83-101	Calculated
MCH	19.6	Low	pg	27-32	Calculated
MCHC	33.8	Normal	g/dL	31.5-34.5	Calculated
R.D.W	20.7	High	%	11.6-14	Calculated
TOTAL LEUCOCYTE COUNT (TLC)	7,610	Normal	cells/cu.mm	4000-10000	Electrical Impedence
DIFFERENTIAL LEUCOCYTIC COUNT (DLC)					
NEUTROPHILS	65.4	Normal	%	40-80	Electrical Impedence
LYMPHOCYTES	25.1	Normal	%	20-40	Electrical Impedence
EOSINOPHILS	1.5	Normal	%	1-6	Electrical Impedence
MONOCYTES	8	Normal	%	2-10	Electrical Impedence
BASOPHILS	0	Normal	%	<1-2	Electrical Impedence
ABSOLUTE LEUCOCYTE COUNT					
NEUTROPHILS	4976.94	Normal	Cells/cu.mm	2000-7000	Calculated
LYMPHOCYTES	1910.11	Normal	Cells/cu.mm	1000-3000	Calculated
EOSINOPHILS	114.15	Normal	Cells/cu.mm	20-500	Calculated
MONOCYTES	608.8	Normal	Cells/cu.mm	200-1000	Calculated
PLATELET COUNT	266000	Normal	cells/cu.mm	150000-410000	Electrical impedence
ERYTHROCYTE SEDIMENTATION RATE (ESR)	11	Normal	mm at the end of 1 hour	0-20	Modified Westergren
PERIPHERAL SMEAR		Normal			

RBC's Anisocytosis++, Microcytes++, Elliptocytes+
WBC's are normal in number and morphology
Platelets are Adequate
No Abnormal cells/hemoparasite seen.



Dr Sheha Shah
 MBBS, MD (Pathology)
 Consultant Pathologist

SIN No:BED240019185

This test has been performed at Apollo Health and Lifestyle ltd- Sadashiv Peth Pune, Diagnostics Lab






Patient Name : Mrs.POOJA AHUJA	Collected : 27/Jan/2024 08:19AM
Age/Gender : 33 Y 11 M 6 D/F	Received : 27/Jan/2024 12:36PM
UHID/MR No : CWAN.0000134274	Reported : 27/Jan/2024 02:35PM
Visit ID : CWANOPV225172	Status : Final Report
Ref Doctor : Dr.SELF	Sponsor Name : ARCOFEMI HEALTHCARE LIMITED
Emp/Auth/TPA ID : 395272159856	

DEPARTMENT OF HAEMATOLOGY

ARCOFEMI - MEDIWHEEL - FULL BODY HEALTH ANNUAL PLUS CHECK - FEMALE - 2D ECHO - PAN INDIA - FY2324

Test Name	Result	Status	Unit	Bio. Ref. Range	Method
BLOOD GROUP ABO AND RH FACTOR , WHOLE BLOOD EDTA					
BLOOD GROUP TYPE	O				Microplate Hemagglutination
Rh TYPE	Positive				Microplate Hemagglutination

Sneha Shah

 Dr Sneha Shah
 MBBS, MD (Pathology)
 Consultant Pathologist

SIN No:BED240019185

This test has been performed at Apollo Health and Lifestyle ltd- Sadashiv Peth Pune, Diagnostics Lab





Patient Name : Mrs.POOJA AHUJA	Collected : 27/Jan/2024 08:19AM
Age/Gender : 33 Y 11 M 6 D/F	Received : 27/Jan/2024 01:01PM
UHID/MR No : CWAN.0000134274	Reported : 27/Jan/2024 01:41PM
Visit ID : CWANOPV225172	Status : Final Report
Ref Doctor : Dr.SELF	Sponsor Name : ARCOFEMI HEALTHCARE LIMITED
Emp/Auth/TPA ID : 395272159856	

DEPARTMENT OF BIOCHEMISTRY

ARCOFEMI - MEDIWHEEL - FULL BODY HEALTH ANNUAL PLUS CHECK - FEMALE - 2D ECHO - PAN INDIA - FY2324

Test Name	Result	Status	Unit	Bio. Ref. Range	Method
GLUCOSE, FASTING , NAF PLASMA	90	Normal	mg/dL	70-100	HEXOKINASE

Comment:

As per American Diabetes Guidelines, 2023

Fasting Glucose Values in mg/dL	Interpretation
70-100 mg/dL	Normal
100-125 mg/dL	Prediabetes
≥126 mg/dL	Diabetes
<70 mg/dL	Hypoglycemia

Note:

- The diagnosis of Diabetes requires a fasting plasma glucose of > or = 126 mg/dL and/or a random / 2 hr post glucose value of > or = 200 mg/dL on at least 2 occasions.
- Very high glucose levels (>450 mg/dL in adults) may result in Diabetic Ketoacidosis & is considered critical.



DR.Sanjay Ingle
M.B.B.S,M.D(Pathology)
Consultant Pathologist

SIN No:PLF02094860

This test has been performed at Apollo Health and Lifestyle Ltd- Sadashiv Peth Pune, Diagnostics Lab





Patient Name : Mrs.POOJA AHUJA	Collected : 27/Jan/2024 08:19AM
Age/Gender : 33 Y 11 M 6 D/F	Received : 27/Jan/2024 12:35PM
UHID/MR No : CWAN.0000134274	Reported : 27/Jan/2024 02:32PM
Visit ID : CWANOPV225172	Status : Final Report
Ref Doctor : Dr.SELF	Sponsor Name : ARCOFEMI HEALTHCARE LIMITED
Emp/Auth/TPA ID : 395272159856	

DEPARTMENT OF BIOCHEMISTRY

ARCOFEMI - MEDIWHEEL - FULL BODY HEALTH ANNUAL PLUS CHECK - FEMALE - 2D ECHO - PAN INDIA - FY2324

Test Name	Result	Status	Unit	Bio. Ref. Range	Method
GLUCOSE, POST PRANDIAL (PP), 2 HOURS , SODIUM FLUORIDE PLASMA (2 HR)	105	Normal	mg/dL	70-140	HEXOKINASE

Comment:

It is recommended that FBS and PPBS should be interpreted with respect to their Biological reference ranges and not with each other.

Conditions which may lead to lower postprandial glucose levels as compared to fasting glucose levels may be due to reactive hypoglycemia, dietary meal content, duration or timing of sampling after food digestion and absorption, medications such as insulin preparations, sulfonylureas, amylin analogues, or conditions such as overproduction of insulin.

Test Name	Result	Status	Unit	Bio. Ref. Range	Method
HBA1C (GLYCATED HEMOGLOBIN) , WHOLE BLOOD EDTA					
HBA1C, GLYCATED HEMOGLOBIN	5.4	Normal	%		HPLC
ESTIMATED AVERAGE GLUCOSE (eAG)	108		mg/dL		Calculated

Comment:

Reference Range as per American Diabetes Association (ADA) 2023 Guidelines:

REFERENCE GROUP	HBA1C %
NON DIABETIC	<5.7
PREDIABETES	5.7 – 6.4
DIABETES	≥ 6.5
DIABETICS	
EXCELLENT CONTROL	6 – 7
FAIR TO GOOD CONTROL	7 – 8
UNSATISFACTORY CONTROL	8 – 10
POOR CONTROL	>10

Note: Dietary preparation or fasting is not required.

- HbA1C is recommended by American Diabetes Association for Diagnosing Diabetes and monitoring Glycemic Control by American Diabetes Association guidelines 2023.
- Trends in HbA1C values is a better indicator of Glycemic control than a single test.
- Low HbA1C in Non-Diabetic patients are associated with Anemia (Iron Deficiency/Hemolytic), Liver Disorders, Chronic Kidney Disease. Clinical Correlation is advised in interpretation of low Values.

Sheha Shah

 Dr Sheha Shah
 MBBS, MD (Pathology)
 Consultant Pathologist

SIN No:EDT240008070

This test has been performed at Apollo Health and Lifestyle ltd- Sadashiv Peth Pune, Diagnostics Lab





Patient Name	: Mrs.POOJA AHUJA	Collected	: 27/Jan/2024 08:19AM
Age/Gender	: 33 Y 11 M 6 D/F	Received	: 27/Jan/2024 12:35PM
UHID/MR No	: CWAN.0000134274	Reported	: 27/Jan/2024 02:32PM
Visit ID	: CWANOPV225172	Status	: Final Report
Ref Doctor	: Dr.SELF	Sponsor Name	: ARCOFEMI HEALTHCARE LIMITED
Emp/Auth/TPA ID	: 395272159856		

DEPARTMENT OF BIOCHEMISTRY

ARCOFEMI - MEDIWHEEL - FULL BODY HEALTH ANNUAL PLUS CHECK - FEMALE - 2D ECHO - PAN INDIA - FY2324

- Falsely low HbA1c (below 4%) may be observed in patients with clinical conditions that shorten erythrocyte life span or decrease mean erythrocyte age. HbA1c may not accurately reflect glycaemic control when clinical conditions that affect erythrocyte survival are present.
- In cases of Interference of Hemoglobin variants in HbA1C, alternative methods (Fructosamine) estimation is recommended for Glycemic Control
 - A: HbF >25%
 - B: Homozygous Hemoglobinopathy.
 (Hb Electrophoresis is recommended method for detection of Hemoglobinopathy)

Sheha Shah
 Dr Sheha Shah
 MBBS, MD (Pathology)
 Consultant Pathologist

SIN No:EDT240008070

This test has been performed at Apollo Health and Lifestyle ltd- Sadashiv Peth Pune, Diagnostics Lab





Patient Name : Mrs.POOJA AHUJA	Collected : 27/Jan/2024 08:19AM
Age/Gender : 33 Y 11 M 6 D/F	Received : 27/Jan/2024 01:12PM
UHID/MR No : CWAN.0000134274	Reported : 27/Jan/2024 02:47PM
Visit ID : CWANOPV225172	Status : Final Report
Ref Doctor : Dr.SELF	Sponsor Name : ARCOFEMI HEALTHCARE LIMITED
Emp/Auth/TPA ID : 395272159856	

DEPARTMENT OF BIOCHEMISTRY

ARCOFEMI - MEDIWHEEL - FULL BODY HEALTH ANNUAL PLUS CHECK - FEMALE - 2D ECHO - PAN INDIA - FY2324

Test Name	Result	Status	Unit	Bio. Ref. Range	Method
LIPID PROFILE , SERUM					
TOTAL CHOLESTEROL	148	Normal	mg/dL	<200	CHO-POD
TRIGLYCERIDES	62	Normal	mg/dL	<150	GPO-POD
HDL CHOLESTEROL	44	Normal	mg/dL	40-60	Enzymatic Immunoinhibition
NON-HDL CHOLESTEROL	104	Normal	mg/dL	<130	Calculated
LDL CHOLESTEROL	91.55	Normal	mg/dL	<100	Calculated
VLDL CHOLESTEROL	12.31	Normal	mg/dL	<30	Calculated
CHOL / HDL RATIO	3.38	Normal		0-4.97	Calculated

Comment:

Reference Interval as per National Cholesterol Education Program (NCEP) Adult Treatment Panel III Report.

	Desirable	Borderline High	High	Very High
TOTAL CHOLESTEROL	< 200	200 - 239	≥ 240	
TRIGLYCERIDES	<150	150 - 199	200 - 499	≥ 500
LDL	Optimal < 100 Near Optimal 100-129	130 - 159	160 - 189	≥ 190
HDL	≥ 60			
NON-HDL CHOLESTEROL	Optimal <130; Above Optimal 130-159	160-189	190-219	>220

- Measurements in the same patient on different days can show physiological and analytical variations.
- NCEP ATP III identifies non-HDL cholesterol as a secondary target of therapy in persons with high triglycerides.
- Primary prevention algorithm now includes absolute risk estimation and lower LDL Cholesterol target levels to determine eligibility of drug therapy.
- Low HDL levels are associated with Coronary Heart Disease due to insufficient HDL being available to participate in reverse cholesterol transport, the process by which cholesterol is eliminated from peripheral tissues.
- As per NCEP guidelines, all adults above the age of 20 years should be screened for lipid status. Selective screening of children above the age of 2 years with a family history of premature cardiovascular disease or those with at least one parent with high total cholesterol is recommended.
- VLDL, LDL Cholesterol Non HDL Cholesterol, CHOL/HDL RATIO, LDL/HDL RATIO are calculated parameters when Triglycerides are below 350mg/dl. When Triglycerides are more than 350 mg/dl LDL cholesterol is a direct measurement.


 Dr Sneha Shah
 MBBS, MD (Pathology)
 Consultant Pathologist

SIN No:SE04610228

This test has been performed at Apollo Health and Lifestyle ltd- Sadashiv Peth Pune, Diagnostics Lab



Patient Name : Mrs.POOJA AHUJA	Collected : 27/Jan/2024 08:19AM
Age/Gender : 33 Y 11 M 6 D/F	Received : 27/Jan/2024 01:12PM
UHID/MR No : CWAN.0000134274	Reported : 27/Jan/2024 02:47PM
Visit ID : CWANOPV225172	Status : Final Report
Ref Doctor : Dr.SELF	Sponsor Name : ARCOFEMI HEALTHCARE LIMITED
Emp/Auth/TPA ID : 395272159856	

DEPARTMENT OF BIOCHEMISTRY

ARCOFEMI - MEDIWHEEL - FULL BODY HEALTH ANNUAL PLUS CHECK - FEMALE - 2D ECHO - PAN INDIA - FY2324

Test Name	Result	Status	Unit	Bio. Ref. Range	Method
LIVER FUNCTION TEST (LFT) , SERUM					
BILIRUBIN, TOTAL	0.66	Normal	mg/dL	0.3-1.2	DPD
BILIRUBIN CONJUGATED (DIRECT)	0.14	Normal	mg/dL	<0.2	DPD
BILIRUBIN (INDIRECT)	0.52	Normal	mg/dL	0.0-1.1	Dual Wavelength
ALANINE AMINOTRANSFERASE (ALT/SGPT)	36.19	High	U/L	<35	IFCC
ASPARTATE AMINOTRANSFERASE (AST/SGOT)	31.8	Normal	U/L	<35	IFCC
ALKALINE PHOSPHATASE	66.09	Normal	U/L	30-120	IFCC
PROTEIN, TOTAL	7.66	Normal	g/dL	6.6-8.3	Biuret
ALBUMIN	4.39	Normal	g/dL	3.5-5.2	BROMO CRESOL GREEN
GLOBULIN	3.27	Normal	g/dL	2.0-3.5	Calculated
A/G RATIO	1.34	Normal		0.9-2.0	Calculated

Comment:

LFT results reflect different aspects of the health of the liver, i.e., hepatocyte integrity (AST & ALT), synthesis and secretion of bile (Bilirubin, ALP), cholestasis (ALP, GGT), protein synthesis (Albumin)

Common patterns seen:

1. Hepatocellular Injury:

- AST – Elevated levels can be seen. However, it is not specific to liver and can be raised in cardiac and skeletal injuries.
- ALT – Elevated levels indicate hepatocellular damage. It is considered to be most specific lab test for hepatocellular injury. Values also correlate well with increasing BMI.
- Disproportionate increase in AST, ALT compared with ALP. • Bilirubin may be elevated.
- AST: ALT (ratio) – In case of hepatocellular injury AST: ALT > 1 In Alcoholic Liver Disease AST: ALT usually >2. This ratio is also seen to be increased in NAFLD, Wilson's diseases, Cirrhosis, but the increase is usually not >2.

2. Cholestatic Pattern:

- ALP – Disproportionate increase in ALP compared with AST, ALT.
- Bilirubin may be elevated. • ALP elevation also seen in pregnancy, impacted by age and sex.
- To establish the hepatic origin correlation with GGT helps. If GGT elevated indicates hepatic cause of increased ALP.

3. Synthetic function impairment:

- Albumin- Liver disease reduces albumin levels. • Correlation with PT (Prothrombin Time) helps.


 Dr Sheha Shah
 MBBS, MD (Pathology)
 Consultant Pathologist

SIN No:SE04610228

This test has been performed at Apollo Health and Lifestyle ltd- Sadashiv Peth Pune, Diagnostics Lab





Patient Name : Mrs.POOJA AHUJA	Collected : 27/Jan/2024 08:19AM
Age/Gender : 33 Y 11 M 6 D/F	Received : 27/Jan/2024 01:12PM
UHID/MR No : CWAN.0000134274	Reported : 27/Jan/2024 02:47PM
Visit ID : CWANOPV225172	Status : Final Report
Ref Doctor : Dr.SELF	Sponsor Name : ARCOFEMI HEALTHCARE LIMITED
Emp/Auth/TPA ID : 395272159856	

Certificate No: M6681

DEPARTMENT OF BIOCHEMISTRY

ARCOFEMI - MEDIWHEEL - FULL BODY HEALTH ANNUAL PLUS CHECK - FEMALE - 2D ECHO - PAN INDIA - FY2324

Sneha Shah
Dr Sneha Shah
MBBS, MD (Pathology)
Consultant Pathologist

SIN No:SE04610228

This test has been performed at Apollo Health and Lifestyle ltd- Sadashiv Peth Pune, Diagnostics Lab





Patient Name : Mrs.POOJA AHUJA	Collected : 27/Jan/2024 08:19AM
Age/Gender : 33 Y 11 M 6 D/F	Received : 27/Jan/2024 01:12PM
UHID/MR No : CWAN.0000134274	Reported : 27/Jan/2024 02:47PM
Visit ID : CWANOPV225172	Status : Final Report
Ref Doctor : Dr.SELF	Sponsor Name : ARCOFEMI HEALTHCARE LIMITED
Emp/Auth/TPA ID : 395272159856	

DEPARTMENT OF BIOCHEMISTRY

ARCOFEMI - MEDIWHEEL - FULL BODY HEALTH ANNUAL PLUS CHECK - FEMALE - 2D ECHO - PAN INDIA - FY2324

Test Name	Result	Status	Unit	Bio. Ref. Range	Method
RENAL PROFILE/KIDNEY FUNCTION TEST (RFT/KFT) , SERUM					
CREATININE	0.50	Low	mg/dL	0.55-1.02	Modified Jaffe, Kinetic
UREA	11.92	Low	mg/dL	17-43	GLDH, Kinetic Assay
BLOOD UREA NITROGEN	5.6	Low	mg/dL	8.0 - 23.0	Calculated
URIC ACID	4.44	Normal	mg/dL	2.6-6.0	Uricase PAP
CALCIUM	8.91	Normal	mg/dL	8.8-10.6	Arsenazo III
PHOSPHORUS, INORGANIC	2.78	Normal	mg/dL	2.5-4.5	Phosphomolybdate Complex
SODIUM	140.53	Normal	mmol/L	136-146	ISE (Indirect)
POTASSIUM	5.6	High	mmol/L	3.5-5.1	ISE (Indirect)
CHLORIDE	104.48	Normal	mmol/L	101-109	ISE (Indirect)

Sheha Shah

Dr Sheha Shah
 MBBS, MD (Pathology)
 Consultant Pathologist

SIN No:SE04610228

This test has been performed at Apollo Health and Lifestyle ltd- Sadashiv Peth Pune, Diagnostics Lab





Patient Name : Mrs.POOJA AHUJA	Collected : 27/Jan/2024 08:19AM
Age/Gender : 33 Y 11 M 6 D/F	Received : 27/Jan/2024 01:12PM
UHID/MR No : CWAN.0000134274	Reported : 27/Jan/2024 02:47PM
Visit ID : CWANOPV225172	Status : Final Report
Ref Doctor : Dr.SELF	Sponsor Name : ARCOFEMI HEALTHCARE LIMITED
Emp/Auth/TPA ID : 395272159856	

DEPARTMENT OF BIOCHEMISTRY

ARCOFEMI - MEDIWHEEL - FULL BODY HEALTH ANNUAL PLUS CHECK - FEMALE - 2D ECHO - PAN INDIA - FY2324

Test Name	Result	Status	Unit	Bio. Ref. Range	Method
GAMMA GLUTAMYL TRANSPEPTIDASE (GGT) , SERUM	10.71	Normal	U/L	<38	IFCC

Sheha Shah
Dr Sheha Shah
MBBS, MD (Pathology)
Consultant Pathologist

SIN No:SE04610228

This test has been performed at Apollo Health and Lifestyle ltd- Sadashiv Peth Pune, Diagnostics Lab





Patient Name : Mrs.POOJA AHUJA	Collected : 27/Jan/2024 08:19AM
Age/Gender : 33 Y 11 M 6 D/F	Received : 27/Jan/2024 01:12PM
UHID/MR No : CWAN.0000134274	Reported : 27/Jan/2024 02:26PM
Visit ID : CWANOPV225172	Status : Final Report
Ref Doctor : Dr.SELF	Sponsor Name : ARCOFEMI HEALTHCARE LIMITED
Emp/Auth/TPA ID : 395272159856	

DEPARTMENT OF IMMUNOLOGY

ARCOFEMI - MEDIWHEEL - FULL BODY HEALTH ANNUAL PLUS CHECK - FEMALE - 2D ECHO - PAN INDIA - FY2324

Test Name	Result	Status	Unit	Bio. Ref. Range	Method
THYROID PROFILE TOTAL (T3, T4, TSH) , SERUM					
TRI-iodothyronine (T3, TOTAL)	1.35	Normal	ng/mL	0.7-2.04	CLIA
THYROXINE (T4, TOTAL)	10.96	Normal	µg/dL	5.48-14.28	CLIA
THYROID STIMULATING HORMONE (TSH)	2.242	Normal	µIU/mL	0.34-5.60	CLIA

Comment:

For pregnant females	Bio Ref Range for TSH in uIU/ml (As per American Thyroid Association)
First trimester	0.1 - 2.5
Second trimester	0.2 - 3.0
Third trimester	0.3 - 3.0

- TSH is a glycoprotein hormone secreted by the anterior pituitary. TSH activates production of T3 (Triiodothyronine) and its prohormone T4 (Thyroxine). Increased blood level of T3 and T4 inhibit production of TSH.
- TSH is elevated in primary hypothyroidism and will be low in primary hyperthyroidism. Elevated or low TSH in the context of normal free thyroxine is often referred to as sub-clinical hypo- or hyperthyroidism respectively.
- Both T4 & T3 provides limited clinical information as both are highly bound to proteins in circulation and reflects mostly inactive hormone. Only a very small fraction of circulating hormone is free and biologically active.
- Significant variations in TSH can occur with circadian rhythm, hormonal status, stress, sleep deprivation, medication & circulating antibodies.

TSH	T3	T4	FT4	Conditions
High	Low	Low	Low	Primary Hypothyroidism, Post Thyroidectomy, Chronic Autoimmune Thyroiditis
High	N	N	N	Subclinical Hypothyroidism, Autoimmune Thyroiditis, Insufficient Hormone Replacement Therapy.
N/Low	Low	Low	Low	Secondary and Tertiary Hypothyroidism
Low	High	High	High	Primary Hyperthyroidism, Goitre, Thyroiditis, Drug effects, Early Pregnancy
Low	N	N	N	Subclinical Hyperthyroidism
Low	Low	Low	Low	Central Hypothyroidism, Treatment with Hyperthyroidism
Low	N	High	High	Thyroiditis, Interfering Antibodies
N/Low	High	N	N	T3 Thyrotoxicosis, Non thyroidal causes
High	High	High	High	Pituitary Adenoma; TSHoma/Thyrotropinoma


 Dr Sheha Shah
 MBBS, MD (Pathology)
 Consultant Pathologist

SIN No:SPL24012530

This test has been performed at Apollo Health and Lifestyle Ltd- Sadashiv Peth Pune, Diagnostics Lab





Patient Name : Mrs.POOJA AHUJA	Collected : 27/Jan/2024 08:19AM
Age/Gender : 33 Y 11 M 6 D/F	Received : 27/Jan/2024 03:02PM
UHID/MR No : CWAN.0000134274	Reported : 27/Jan/2024 03:31PM
Visit ID : CWANOPV225172	Status : Final Report
Ref Doctor : Dr.SELF	Sponsor Name : ARCOFEMI HEALTHCARE LIMITED
Emp/Auth/TPA ID : 395272159856	

DEPARTMENT OF CLINICAL PATHOLOGY

ARCOFEMI - MEDIWHEEL - FULL BODY HEALTH ANNUAL PLUS CHECK - FEMALE - 2D ECHO - PAN INDIA - FY2324

Test Name	Result	Status	Unit	Bio. Ref. Range	Method
COMPLETE URINE EXAMINATION (CUE) , URINE					
PHYSICAL EXAMINATION					
COLOUR	PALE YELLOW			PALE YELLOW	Visual
TRANSPARENCY	CLEAR			CLEAR	Visual
pH	6.0	Normal		5-7.5	DOUBLE INDICATOR
SP. GRAVITY	>1.025	Normal		1.002-1.030	Bromothymol Blue
BIOCHEMICAL EXAMINATION					
URINE PROTEIN	NEGATIVE			NEGATIVE	PROTEIN ERROR OF INDICATOR
GLUCOSE	NEGATIVE			NEGATIVE	GLUCOSE OXIDASE
URINE BILIRUBIN	NEGATIVE			NEGATIVE	AZO COUPLING REACTION
URINE KETONES (RANDOM)	NEGATIVE			NEGATIVE	SODIUM NITRO PRUSSIDE
UROBILINOGEN	NORMAL			NORMAL	MODIFIED EHRlich REACTION
BLOOD	NEGATIVE			NEGATIVE	Peroxidase
NITRITE	NEGATIVE			NEGATIVE	Diazotization
LEUCOCYTE ESTERASE	NEGATIVE			NEGATIVE	LEUCOCYTE ESTERASE
CENTRIFUGED SEDIMENT WET MOUNT AND MICROSCOPY					
PUS CELLS	2 - 3	Normal	/hpf	0-5	Microscopy
EPITHELIAL CELLS	1 - 2		/hpf	<10	MICROSCOPY
RBC	NIL		/hpf	0-2	MICROSCOPY
CASTS	NIL	Normal		0-2 Hyaline Cast	MICROSCOPY
CRYSTALS	ABSENT			ABSENT	MICROSCOPY

Sneha Shah
Dr Sneha Shah
MBBS, MD (Pathology)
Consultant Pathologist

SIN No:UR2268802

This test has been performed at Apollo Health and Lifestyle ltd- Sadashiv Peth Pune, Diagnostics Lab





Patient Name : Mrs.POOJA AHUJA	Collected : 27/Jan/2024 08:19AM
Age/Gender : 33 Y 11 M 6 D/F	Received : 27/Jan/2024 03:02PM
UHID/MR No : CWAN.0000134274	Reported : 27/Jan/2024 03:31PM
Visit ID : CWANOPV225172	Status : Final Report
Ref Doctor : Dr.SELF	Sponsor Name : ARCOFEMI HEALTHCARE LIMITED
Emp/Auth/TPA ID : 395272159856	

DEPARTMENT OF CLINICAL PATHOLOGY


ARCOFEMI - MEDIWHEEL - FULL BODY HEALTH ANNUAL PLUS CHECK - FEMALE - 2D ECHO - PAN INDIA - FY2324

Test Name	Result	Status	Unit	Bio. Ref. Range	Method
URINE GLUCOSE(POST PRANDIAL)	NEGATIVE			NEGATIVE	Dipstick

Test Name	Result	Status	Unit	Bio. Ref. Range	Method
URINE GLUCOSE(FASTING)	NEGATIVE			NEGATIVE	Dipstick

***** End Of Report *****

Result/s to Follow:
LBC PAP TEST (PAPSURE)



Dr Sheha Shah
MBBS, MD (Pathology)
Consultant Pathologist

SIN No:UF010317

This test has been performed at Apollo Health and Lifestyle ltd- Sadashiv Peth Pune, Diagnostics Lab



ahujacharan@rediffmail.com

Name : Mrs. POOJA AHUJA

Age: 33 Y

Sex: F

UHID: CWAN.0000134274



OP Number: CWANOPV225172

Bill No : CWAN-OCR-50051

Date : 27.01.2024 08:15

Address : PUNE
Plan : ARCOFEMI MEDIWHEEL FEMALE AHC CREDIT PAN
INDIA OP AGREEMENT

Sno	Service Type/ServiceName	Department
1	ARCOFEMI - MEDIWHEEL - FULL BODY HEALTH ANNUAL PLUS CHECK - FEMALE - 2D ECHO - PAN INDIA - FY2324	
<input checked="" type="checkbox"/>	1 URINE GLUCOSE (FASTING)	
<input checked="" type="checkbox"/>	2 GAMMA GLUTAMYL TRANSFERASE (GGT)	
<input checked="" type="checkbox"/>	3 HbA1c, GLYCATED HEMOGLOBIN	
<input checked="" type="checkbox"/>	4 2D ECHO	
<input checked="" type="checkbox"/>	5 LIVER FUNCTION TEST (LFT)	
<input checked="" type="checkbox"/>	6 X-RAY CHEST PA	
<input checked="" type="checkbox"/>	7 GLUCOSE, FASTING	
<input checked="" type="checkbox"/>	8 HEMOGRAM + PERIPHERAL SMEAR	
<input checked="" type="checkbox"/>	9 ENT CONSULTATION	
<input checked="" type="checkbox"/>	10 FITNESS BY GENERAL PHYSICIAN	
<input checked="" type="checkbox"/>	11 GYNAECOLOGY CONSULTATION	
<input checked="" type="checkbox"/>	12 DIET CONSULTATION	
<input checked="" type="checkbox"/>	13 COMPLETE URINE EXAMINATION	
<input checked="" type="checkbox"/>	14 URINE GLUCOSE (POST PRANDIAL)	
<input checked="" type="checkbox"/>	15 PERIPHERAL SMEAR	
<input checked="" type="checkbox"/>	16 ECG - FTI 9:09 25 9:15	
<input checked="" type="checkbox"/>	17 BLOOD GROUP ABO AND RH FACTOR	
<input checked="" type="checkbox"/>	18 LIPID PROFILE	
<input checked="" type="checkbox"/>	19 BODY MASS INDEX (BMI)	
<input checked="" type="checkbox"/>	20 CBC PAP TEST- PAPSURE	
<input checked="" type="checkbox"/>	21 OPHTHAL BY GENERAL PHYSICIAN	
<input checked="" type="checkbox"/>	22 RENAL PROFILE/RENAL FUNCTION TEST (RFT/KFT)	
<input checked="" type="checkbox"/>	23 ULTRASOUND - WHOLE ABDOMEN	
<input checked="" type="checkbox"/>	24 THYROID PROFILE (TOTAL T3, TOTAL T4, TSH)	
<input checked="" type="checkbox"/>	25 DENTAL CONSULTATION	
<input checked="" type="checkbox"/>	26 GLUCOSE, POST PRANDIAL (PP), 2 HOURS (POST MEAL) 11:00 Am	

Audiometry


Ht- 165cm

Wt- 69.2kg

BP- 110/70

FREE CONSULTATIONS
DENTAL / PHYSIO / AUDIOMETRY

FREE CONSULTATIONS
DENTAL / PHYSIO / AUDIOMETRY



CERTIFICATE OF MEDICAL FITNESS

This is to certify that I have conducted the clinical examination

of Ms. Pooja Ahija on 29/1/2024

After reviewing the medical history and on clinical examination it has been found that he/she is

	Tick
<ul style="list-style-type: none"> • Medically Fit 	<input checked="" type="checkbox"/>
<ul style="list-style-type: none"> • Fit with restrictions/recommendations <p>Though following restrictions have been revealed, in my opinion, these are not impediments to the job.</p> <p>1.....</p> <p>2.....</p> <p>3.....</p> <p>However the employee should follow the advice/medication that has been communicated to him/her.</p> <p>Review after _____</p>	
<ul style="list-style-type: none"> • Currently Unfit. <p>Review after _____ recommended</p>	
<ul style="list-style-type: none"> • Unfit 	



Dr. Mushfiya Bahrainwala
 Medical Officer
 The Apollo Clinic, (Location)

This certificate is not meant for medico-legal purposes

DR. MUSHFIYA BAHRAINWALA
M.B.B.S
 Reg. No.: 47527
 Apollo Clinic Wanowarie
 NIBM Road, Kondhwa.

Date : 27-01-2024
 MR NO : CWAN.0000134274
 Name : Mrs. POOJA AHUJA
 Age/ Gender : 33 Y / Female

Department : GENERAL
 Doctor :
 Registration No :
 Qualification :

Consultation Timing: 08:14

Height : 165 cm	Weight : 69.2 kg	BMI :	Waist Circum :
Temp :	Pulse :	Resp :	B.P : 110/70/49

General Examination / Allergies History

Clinical Diagnosis & Management Plan

EXAMINATION

3 Covid Vaccines taken

Admission

For AEC

*Has mild nose block
 Knee pain +. Also has numbness in
 the Rt-hand only x 4-5 days
 O/E - CVS
 CVS
 Resp. was
 Abcd*

Vit. B12 & D3 levels



DR. MUSHFIYA BAHRAINWALA
 M.B.B.S
 Reg. No.: 47527
 Apollo Clinic, Manawarie,
 NIBM Road, Kondli.wa.

SAMPLE
 HC
 9763461253
 Clinic
 9121226368
PATHOLOGY
COLLECTION
 Follow-up date:

Doctor Signature

Mr.
~~Mr.~~ Boja Shuja

Dr. Akanksha Jain.

ENT

Came for routine check-up.

o/e @ ear ringing sensation. once in 6 months.

O/E.
Ear - BHTM intact

Nex - DNS to (L)

throat - ulcers @ lower lip.

Rx.

TAB NEUROBION FORTE.

1-0-0 x (90) days.

Avoid loud noises.

Zytee gel for LA 1-0-1

x (5) days.

Akanksha.

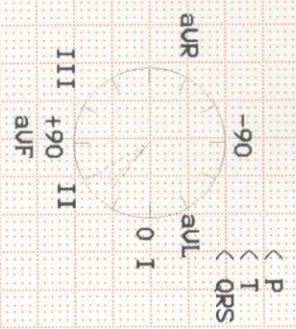


GE MAC1200 ST AHUJA, POOJA 000134274, APOLLO CLINIC WANDOURIE
Female, 33 Years (21.02.1990)

Arrow CE

Measurement Results:

QRS	84 ms
QT/QTcB	364 / 434 ms
PR	136 ms
P	106 ms
RR/PP	704 / 700 ms
P/QRS/T	60 / 45 / 40 degrees
QTd/QTcBd	74 / 88 ms
Sokolow	1.8 mV
NK	12



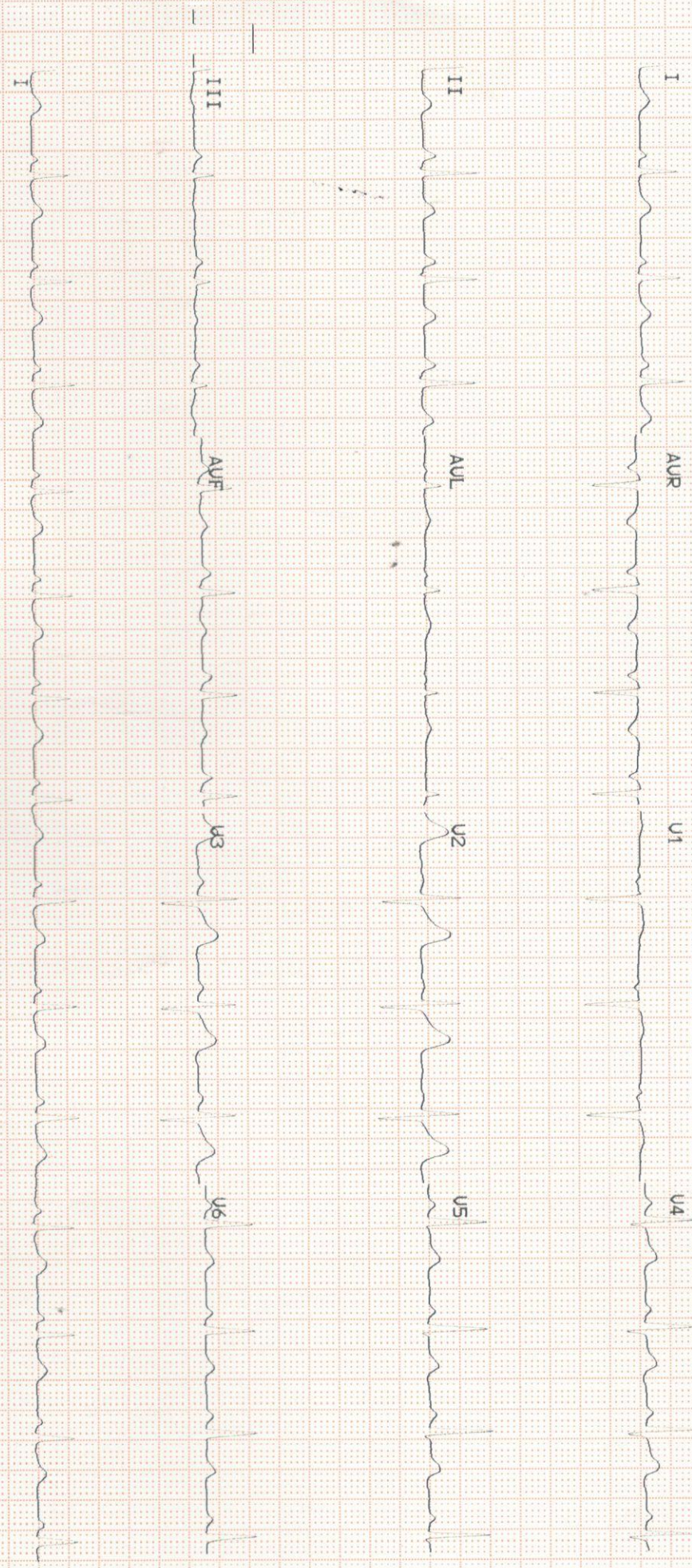
Interpretation:

normal ECG

HR 85 bpm

DR. MUSHTFIYA BAHRAINWALA
M.B.B.S
Reg. No.: 47527
Apollo Clinics, Yancuarie
NIBIM Road, Kondiwa.

Unconfirmed report.



2D ECHOCARDIOGRAPHY & COLOR DOPPLER STUDY *Expertise. Closer to you.*

Name : MRS.POOJA AHUJA Age/Sex :33/F Date : 27/01/2024.

2D Echo:-

Cardiac chamber dimensions –Normal

Wall motion abnormalities - no RWMA

LV systolic function - Normal, LVEF -60%

LV diastolic function – No LV diastolic dysfunction

Cardiac valves -

Mitral valve –Normal, No mitral regurgitation.

Aortic valve – Three thin leaflets, no aortic regurgitation, Aortic PG –8 mm Hg

Tricuspid valve – no tricuspid regurgitation, No PAH

Pulmonary valve - normal

Septae (IAS/IVS) – intact

Clot/vegetation/Pericardial effusion – No

Great Arteries (Aorta/pulmonary artery) - Normal

IVC - Normal

Measurements -

Aorta	LA	IVS	PWD	LVIDd	LVIDs	LVEF
31	32	10	10	35	28	60%


Conclusion:-

Normal chamber dimensions.

No RWMA, normal LV systolic function, LVEF – 60%

Normal LV Diastolic dysfunction.

Normal PA pressure.

Dr. Bhushan Bari
DNB Medicine, DNB Cardiology
Consultant and Interventional Cardiologist

The Apollo Clinic

Wanowrie
Pune-411048

PATIENT NAME :- Mrs. Pooja

DATE :- 27/11/24

AGE/SEX :- 33/F

UHID :

EYE CHECKUP

COMPLETE

PREMEDICAL/OTHER

	RIGHT EYE	LEFT EYE
Far Vision	6/6 - 11 / -1.25 x 30°	6/6 - 11.25 / -1.25 x 140°
Near Vision	N/6	N/6
Anterior Segment Pupil	NORMAL ✓	NORMAL ✓
Fundus	NORMAL ✓	NORMAL ✓
Colour Vision	NORMAL ✓	NORMAL ✓
Iop	NORMAL NA	NORMAL ✓
Family History/Medical History	NA	✓

IMPRESSION :- myopia

Advice :- use computer glasses / on tears

Pooja
Ophthalmologist



8308913914 - Pooja More

PATIENT CASE SHEET



Name: Mrs Pooja Ahuja Age: 33 Gender: Female
Address: Pune
UHID / Emp Id: 134274

Ref. by Doctor

Treating Doctor

Dr Rainab

Past Dental History:

Oral Periapicalitis.

Past Medical History:

Chief Complaint(s):

Regular dental checkup.

Investigation: RVG OPG CBCT

Patient Name : Mrs. POOJA AHUJA
UHID : CWAN.0000134274
Reported on : 27-01-2024 13:45
Adm/Consult Doctor :

Age : 33 Y F
OP Visit No : CWANOPV225172
Printed on : 27-01-2024 13:46
Ref Doctor : SELF

DEPARTMENT OF RADIOLOGY

X-RAY CHEST PA

Both lung fields and hila are normal .

No obvious active pleuro-parenchymal lesion seen .

Both costophrenic and cardiophrenic angles are clear .

Cardiac shadow is normal.

Both diaphragms are normal in position and contour .


Thoracic wall and soft tissues appear normal.

CONCLUSION :

No obvious abnormality seen.

Printed on:27-01-2024 13:45

---End of the Report---


Dr. SATINDER LAMBA
MBBS, DMRE
Dr. Satinder K. Lamba Radiology
(Ex-Major) Radiologist
Reg. No. 2004/02/386

Patient Name	: Mrs. POOJA AHUJA	Age	: 33 Y F
UHID	: CWAN.0000134274	OP Visit No	: CWANOPV225172
Reported on	: 27-01-2024 09:45	Printed on	: 27-01-2024 09:47
Adm/Consult Doctor	:	Ref Doctor	: SELF

DEPARTMENT OF RADIOLOGY

ULTRASOUND - WHOLE ABDOMEN

Liver appears normal in size and echotexture. No focal lesion is seen. PV and CBD normal. No dilatation of the intrahepatic biliary radicals.

Gall bladder is distended. No evidence of calculus. Wall thickness appears normal. No evidence of periGB collection. No evidence of focal lesion.

Spleen appears normal. No focal lesion seen. Splenic vein appears normal.

Pancreas appears normal in echopattern. No focal mass lesion/calcification. No evidence of peripancreatic free fluid or collection. Pancreatic duct appears normal.

Both the kidneys appear normal in size, shape and echopattern. Cortical thickness and CM differentiation are maintained. No calculus / hydronephrosis seen on either side.

Urinary Bladder is distended and appears normal. No evidence of any wall thickening or abnormality. No evidence of any intrinsic or extrinsic bladder abnormality.

Uterus measures 8.7 x 4.5 x 5.0 cm. appears normal in size. No significant focal lesion seen. Endometrial echo-complex appears normal and measures 11 mm.

Both ovaries appear normal in size, shape and echotexture.

No evidence of any adnexal pathology.

No free fluid is detected in abdomen.

No retroperitoneal lymphadenopathy seen.

Patient Name	: Mrs. POOJA AHUJA	Age	: 33 Y F
UHID	: CWAN.0000134274	OP Visit No	: CWANOPV225172
Reported on	: 27-01-2024 09:45	Printed on	: 27-01-2024 09:47
Adm/Consult Doctor	:	Ref Doctor	: SELF

No obvious bowel mass detected.

IMPRESSION:


No significant abnormality detected.

Suggest – clinical correlation.

(The sonography findings should always be considered in correlation with the clinical and other investigation finding where applicable.) It is only a professional opinion, Not valid for medico legal purpose.

Printed on:27-01-2024 09:45

---End of the Report---


Dr. SHAAZ AHMED KHAN
MBBS,DMRE
Radiology

Pending Test Form

I, Mrs. Pooja Ahuja visiting from _____
_____ Company for health check.

UHID: - 134274 ; Date: - 27/1/24.

This is a consent form to inform you that I do not wish to do this test.

Gynaecology and Diet con.

Or will be doing their test later on _____.

Signature: - _____

