

REVIVAL DIAGNOSTICS



HEALTH CHECK-UP SUMMARY

Name: Nitish Kodgarkar

Date: 31/08/2022

Email ID:

Sex: M Age: 33 Years Contact No: 9823239244

Remarks:	
Under-weight	-
Normal	-
Over-weight	✓

i> BMI

Height (in Cm): 171	Weight (in Kg): 89	BMI: 30.4	
---------------------	--------------------	-----------	--

ii> Blood Pressure & Pulse

120/82 mm/hg.
70/min. Regular

If high or low, whether the person is on medication: YES / NO

iii> Blood Tests & Lung Function Remarks

RS }
CVS }
CNS }

If abnormal, whether the person is on medication: YES / NO

iv> Eye Test Remarks

Eye test Lf 6/6 Rt 6/6
Color Vision:

v> Heart Disease

Whether any specific heart ailment detected (ECG findings):
Normal

vi> Any other problems needing attention / Overall Assessment:

NO

Revival Diagnostic
401, Aqua Corridor,
B/s. Star Bazar, Surat-395009
Mo. 91062-28601

C.K. Patel
Signature of the Doctor

Dr. Chirag Patel
M.B.B.S. G-49432

Laboratory Test Result are Subject to technical limitation and should be clinically correlate for final diagnosis



NAME: Nitish Kodgirkar SEX: M
BIRTHDATE: 01/01/1989 AGE: 33

DEPARTMENT OF OPHTHALMOLOGY

EYE TEST:

1. VISION:

RIGHT EYE - 6/6
LEFT EYE - 6/6

2. COLOR VISION:

RIGHT EYE - (N)
LEFT EYE - (N)

3. FUNDUS:

RIGHT EYE - (N)
LEFT EYE - (N)

REMARKS:

(S) *[Signature]*

Revival Diagnostic
401, Aqua Corridor,
B/s. Star Bazar, Surat-395009
M/01063-3880
Ophthalmologist/Optomtrist

Laboratory Test Result are Subject to technical limitation and should be clinically correlate for final diagnosis



Dental Assessment Form

NAME
AGE

Nitish Kodgirkar
33

DATE
SEX

31/08/2022
M

* CHIEF COMPLAINT

- A CLINICAL FEATURES :- normal
- 1 CAVIES :-
2 MISSING TOOTH :- } (2)
3 MALOCCLUSION :-
4 FILLING :-
- B DIAGNOSIS :- normal
- C PERSONAL HISTORY :- Hygenic
- D PROVISIONAL D/G :- normal
- E MEDICAL HISTORY :- NO
- F FINAL D/G :- normal
- G TREATMENT PLAN :- NO

CLINT SIGN

Revival Diagnostic
401, Aqua Corridor,
B/s. Star Bazar, Surat-395009
Mo. 91062-28601

Laboratory Test Result are Subject to technical limitation and should be clinically correlate for final diagnosis



Name : NITISH D KODGIRKAR
Age/Sex : 33 Yrs. Male
UHID : 21424
Ref. By Dr. : MEDI WHEEL
Category : CTR

Date : 31-Aug-2022 8:48 am
Receipt No : 5416
Lab ID : 17090

Collection Date & Time : 31-Aug-2022 8:48 am

CBC HAEMOGRAM

PARAMETER	RESULT	UNITS	Biological Reference Range
Hemoglobin	: 17.0	gm/dL	13.5-18.0
RBC Count	: 5.86	m/c.mm.	4.5-6.5
WBC Count	: 10000	c. mm.	4,000 - 10,000
Platelet Count	: 3.10	c. mm.	1.5 Lac - 5.0 Lac
Blood Indices			
Hematocrit (PCV)	: 51.0	%	39-54 %
MCV	: 87.0	fl	75-96
MCH	: 29.0	pg	27-32
MCHC	: 33.3	g/dL	30-36
RDW	: 13.9	%	11- 16
ESR (WINTORBE)	: 02	mm./hr.	0-20
DIFF WBC Count			
Neutrophils	: 55	%	40-75
Lymphocytes	: 40	%	20-50
Eosinophils	: 03	%	1-6
Monocytes	: 02	%	2-10
Basophils	: 00	%	0-5
Band Form	: 00	%	0-5
Smear Study			
Platelets in Smear	: Adequate		
Malarial Parasites	: Malarial Parasites Not Detected		
Blood Group	: "O"		
RH Factor	: Positive		

Lab Technician/Technologist

Dr. Mihir Icecreamwala
M.B.B.S.,M.D. Pathologist

Revival Diagnostic
401, Aqua Corridor,
B/s. Star Bazar, Surat-395009
Mo. 91062-28801

Operator Name: Namrata Patel | Reporting Print Date & Time: 31-Aug-2022

4th Floor, Aqua Corridor, Hazira Road, Adajan Paal, Surat-395009.

0261 2747788

revivaldiagnostics.surat@gmail.com

www.revivaldiagnostics.com

This medical report is not intended for medico-legal purposes.




Name : NITISH D KODGIRKAR
Age/Sex : 33 Yrs./Male
UHID : 21424
Ref. By Dr. : MEDI WHEEL
Collection Date & Time : 31-Aug-2022 8:48 am

Date : 31-Aug-2022 8:48 am
Rec. No : 5416
Lab ID : 17090
Category : CTR

BIOCHEMISTRY

TEST	RESULTS	Unit	BIOLOGICAL REFERENCE RANGI
GGT <i>IFCC, Without Pyridoxal Phosphate</i>	: 50	U/L	5 - 50 U/L
SGOT <i>IFCC, Without Pyridoxal Phosphate</i>	: 16	U/L	0 - 50 U/L
SGPT <i>IFCC, Without Pyridoxal Phosphate</i>	: 46	U/L	0 - 50 U/L
Alkaline Phosphatase <i>ALP-AMP</i>	: 79	IU/l	38 - 126 IU/l
Total Bilirubin <i>DIAZO METHOD</i>	: 0.7	mg/dl	0.2 - 1.2 mg/dl
Direct Bilirubin <i>DIAZO METHOD</i>	: 0.3	mg/dl	0.1 - 0.4 mg/dl
Indirect Bilirubin <i>CALCULATED</i>	: 0.4	mg/dl	0.1 - 0.8 mg/dl
Blood Urea Nitrogen (BUN) <i>GLDH-UREASE METHOD</i>	: 12	mg/dl	9 - 20 mg/dl
Creatinine <i>(METHOD : ENZYMATIC)</i>	: 0.7	mg/dl	0.5 - 1.5 mg/dl
Uric Acid <i>URICASE-POD</i>	: 3.8	mg/dl	4 - 8.5 mg/dl
Blood Sugar - F	: 77	mg/dL	70 - 110 mg/dL
Urine Sugar - F	: Absent		
Urine Ketone - F	: Absent		
Blood Sugar- PP	: 102	mg/dL	80 - 140 mg/dL
Urine Sugar - PP	: Absent		
Urine Ketone - PP	: Absent		
Total Protein <i>Biuret</i>	: 6.6	gm/dl	6.3 - 8.2 gm/dl
S.Albumin	: 4.2	gm/dl	3.7 - 5.3 gm/dl

Revival Diagnostic
401, Aqua Corridor,
B/s. Star Bazar. Surat-395009
Mo. 91062-28891


Dr. Mihir Icecreamwala
M.B.B.S., M.D. Pathologist

Reporting Date & Time : 31-Aug-2022 01:39:00PM

Test Performed On Fully Automated Clinical Chemistry Analyser EM-200

Laboratory Test Result are Subject to technical limitation and should be clinically correlate for final diagnosis

4th Floor, Aqua Corridor, Hazira Road, Adajan Paal, Surat-395009.

0261 2747788

revivaldiagnostics.surat@gmail.com

www.revivaldiagnostics.com

This medical report is not intended for medico-legal purposes.

REVIVAL DIAGNOSTICS



BCG(Bromo Cresol Green)

Globulin CALCULATED	: 2.4	gm/dl	2.4 - 3.2 gm/dl
A/G Ratio CALCULATED	: 1.75	gm/dl	1 - 2.3 gm/dl



Revival Diagnostic
401, Aqua Corridor,
B/s. Star Bazar, Surat-395009
Mo. 91062-28601

Dr. Mihir Icecreamwala
M.B.B.S.,M.D. Pathologist

Reporting Date & Time : 31-Aug-2022 01:39:00PM

Test Performed On Fully Authomated Clinical Chemistry Analyser EM-200

Laboratory Test Result are Subject to technical limitation and should be clinically correlate for final diagnosis

📍 4th Floor, Aqua Corridor, Hazira Road, Adajan Paal, Surat-395009.

☎ 0261 2747788

✉ revivaldiagnostics.surat@gmail.com

🌐 www.revivaldiagnostics.com

This medical report is not intended for medico-legal purposes.



Name : NITISH D KODGIRKAR
Age/Sex : 33 Yrs. Male
UHID : 21424
Ref. By Dr. : MEDI WHEEL
Catagory : CTR

Date : 31-Aug-2022
Receipt No : 5416
Lab ID : 17090


Collection Date & Time : 31-Aug-2022 8:48 am

REPORT OF SERUM LIPID PROFILE

Test	Result	Biological Reference Range
Serum Cholesterol (Mehod : CHOD-POD)	182	Normal : Less than 200 mg / dl Borderline : 200 to 239 mg / dl Undesirable : More than 240 mg / dl
Serum Triglyceride (Mehod : GPO-POD)	139	Normal : Less than 150 mg / dl Borderline High : 150 to 199 mg / dl High : 200 - 499 mg / dl Very High : More than 500 mg / dl
Serum HDL - Cholesterol (Mehod : PVS-PEGME Precipitation with CHOD-POD)	52	Desirable : More than 55 mg / dl Borderline : 35 to 55 mg / dl Undesirable : Less than 35 mg / dl
Serum LDL - Cholesterol (Mehod : Calculated)	102.2	Optimal : Less than 100 mg / dl Above Optimal : 100 - 129 mg / dl Borderline High : 130 to 159 mg / dl High : 160 to 189 mg / dl Very High : More than 190 mg / dl
VLDL (Mehod : Calculated)	27.8	Normal : 5 to 30 mg / dl
Chol. / HDL - Chol. Ratio	3.5	Low Risk : Less than 3.8 Vedium Risk : 3.8 to 5.9 High Risk : More than 6
LDL / HDL - Chol. Ratio	1.97	Low Risk : Less than 3.55 Medium Risk : 3.55 - 4 High Risk : More than 6

Revival Diagnostic
 401, Aqua Corridor,
 B/s. Star Bazar. Surat-395009
 Mo. 91062-26601

Lab Technician/Technologist


Dr. Mihir Icecreamwala
M.B.B.S..M.D. Pathologist

Operator Name: Namrata Patel

Reporting PrintDate & Time: 31-Aug-2022

Laboratory Test Result are Subject to technical limitation and should be clinically correlate for final diagnosis



Name : NITISH D KODGIRKAR
Age/Sex : 33 Yrs. / Male
UHID : 21424
Category : CTR
Ref. By Dr. : MEDI WHEEL

Date : 31-Aug-2022 8:48 am
Receipt No : 5416
Lab ID : 17090
Collection Date & Time : 31-Aug-2022 8:48 am

ROUTINE URINE EXAMINATION REPORT

PHYSICAL EXAMINATION :

Quantity : 15 ml
Colour : Pale Yellow
Appearance : Clear
Reaction : Acidic
Specific Gravity : 1.030

CHEMICAL EXAMINATION :


Proteins : Absent
Sugar : Absent
Acetone : Absent
Bile Salts : Absent
Bile Pigments : Absent
Urobilinogen : Normal
O.B.T. : Negative

MICROSCOPIC EXAMINATION :

Pus Cells : 1-2/hpf.
R. B. C. : Absent
Epithelial Cells : 2-3/hpf.
Bacteria : Absent
Casts : Absent
Crystals : Absent
Yeast cell : Absent
Mucus : Absent
Other Findings : NIL

Revival Diagnostic
401, Aqua Corridor,
B/s. Star Bazar, Surat-395009
Mo. 91062-28601

Lab Technician/Technologist


Dr. Mihir Icecreamwala
M.B.B.S.,M.D. Pathologist

Laboratory Test Result are Subject to technical limitation and should be clinically correlate for final diagnosis

Operator Name: Sheta Parma Aqua Corridor, Hazira Road, Reporting Print Date & Time: 31-Aug-2022 12:15:00PM
☎ 0261 2747788 ✉ revivaldiagnostics.surat@gmail.com 🌐 www.revivaldiagnostics.com

This medical report is not intended for medico-legal purposes.



Name : NITISH D KODGIRKAR
Age/Sex : 33 Yrs. Male
UHID : 21424
Ref. By Dr. : MEDI WHEEL
Category : CTR

Date : 31-Aug-2022 8:48 am
Receipt No : 5416

Lab ID : 17090
Collection Date & Time : 31-Aug-2022 8:48 am

THYROID TEST

TEST	RESULT	Biological Reference Range
T3	1.21	0.87 - 1.78 ng/ml
T4	8.42	4.60 - 13.5 ug/dl
TSH	1.53	0.50 - 5.50 uIU/ml 5.5 to 15 uIU/ml - Suggested Clinical co-relation Or Repeat test with new sample as physiological factors can give falsely high TSH Above 15uIU/ml Hypothyroid

PREGNANT WOMEN normal ranges for TSH:
1st Trimester :0.0878 - 2.8293 uIU/ml
2nd Trimester :0.1998 - 2.7915 uIU/ml
3rd Trimester :0.307 - 2.9028 uIU/ml
Ref:TIETZ Fundamentals of Clinical Chemistry.

Revival Diagnostic

401, Aqua Corridor,
B/s. Star Bazar, Surat-395009
Mo. 91062-28601

Lab Technician/Technologist

Dr. Mihir Icecreamwala
M.B.B.S.,M.D. Pathologist

Operator Name : Namrata Patel

Reporting Print Date & Time : 31-Aug-2022

Laboratory Test Result are Subject to technical limitation and should be clinically correlate for final diagnosis

☎ 0261 2747788

✉ revivaldiagnostics.surat@gmail.com

🌐 www.revivaldiagnostics.com

This medical report is not intended for medico-legal purposes.



Name : NITISH D KODGIRKAR
Age/Sex : 33 Yrs. Male
UHID : 21424
Ref. By Dr. : MEDI WHEEL
Category : CTR

Date : 31-Aug-2022
Receipt No : 5416
Lab ID : 17090


Collection Date & Time : 31-Aug-2022 8:48 am

REPORT OF TUMOR MARKERS

Test	Result	Biological Reference Range
PROSTATE SPECIFIC ANTIGEN (PSA)	: 0.5 ng/ml	[0.0 - 2.5 ng/ml] 40 - 49 Years [0.0 - 3.5 ng/ml] 50 - 59 Years [0.0 - 4.5 ng/ml] 60 - 69 Years [0.0 - 5.5 ng/ml] 70 - 79 Years

Revival Diagnostic
401, Aqua Corridor,
B/s. Star Bazar, Surat-395009
Mo. 91062-28601

Dr. Mihir Icecreamwala
M.B.B.S.,M.D. Pathologist
Operator Name:Namrata Patel


Lab Technician/Technologist

PrintDate & Time:31-Aug-2022

Method: - Test performed on Automated Chemiluminescence Assay [COBAS E411, ROCHE]
Corrobrative clinicopathologic correlation is essential for final diagnosis. Test reports are subjected to technical limitation and should be clinically co-related. Laboratory may be contacted if required.

Laboratory Test Result are Subject to technical limitation and should be clinically correlate for final diagnosis

📍 4th Floor, Aqua Corridor, Hazira Road, Adajan Paal, Surat-395009.
☎ 0261 2747788 ✉ revivaldiagnostics.surat@gmail.com 🌐 www.revivaldiagnostics.com

This medical report is not intended for medico-legal purposes.



Name : NITISH D KODGIRKAR

Date : 31-Aug-2022

Age/Sex : 33 Yrs. Male

Receipt No : 5416

UHID : 21424

Ref. By Dr. : MEDI WHEEL

Lab ID : 17090

Report By Dr. : Dr.

Catagory : CTR

Collection Date & Time : 31-Aug-2022 8:48 am

REPORT OF GLYCOSYLATED HEMOGLOBIN [HbA1C]

Parameter	Result	Unit	Biological Reference Interval
Hemoglobin A1C(HbA1C)	5.3	%	HbA1C Degree of Glucose Control

< 5.6 % Non Diabetics
5.7 - 6.4 % Prediabetics
> = 6.5 % Diabetics

(REF : Wallace, 11th Edition)

REMARKS:

6 - 7 % Excellent Control
7 - 8 % Good Control
8 -10 % Unsatisfactory Control
> 10 % Poor Control


Method : High performance liquid chromatography (HPLC)

MEAN BLOOD GLUCOSE OVER THE PAST 60 DAYS FROM THE HbA1C RESULT : 000 mg/dl

Remarks : GHb test is useful for the long term control and monitoring of diabetes mellitus since it reflects the integration of blood glucose levels during past 4-8 weeks.

Revival Diagnostic
401, Aqua Corridor,
B/s. Star Bazar, Surat-395009
Mo. 91062-28601

Lab Technician/Technologist


Dr. Mihir Icecreamwala
M.B.B.S..M.D. Pathologist

Operator Name : Namrata Patel

Reporting Print Date & Time : 31-Aug-2022

Laboratory Test Result are Subject to technical limitation and should be clinically correlate for final diagnosis

📍 4th Floor, Aqua Corridor, Hazira Road, Adajan Paal, Surat-395009.

☎ 0261 2747788

✉ revivaldiagnostics.surat@gmail.com

🌐 www.revivaldiagnostics.com

This medical report is not intended for medico-legal purposes.



2D-ECHOCARDIOGRAPHY & COLOR DOPPLER REPORT

Name:	NITISH D. KODGIRKAR	Age/Gender	33Yrs /Male
Referred by.	MEDI WHEEL	Date	31/08/2022

VITALS: BP = 120/80mmHg, PULSE =70 bpm, SPO2 =98%


INDICATION: Preventive Health check up

- **CARDIAC CHAMBERS:** Left Ventricle: Normal size, Left Atrium: Normal size.
- No e/o thrombus in LA/LV.
- **Right Atrium:** Normal size. **Right Ventricle:** Normal size,
- **Normal Right Ventricular function.** (TAPSE=20mm)
- **Normal Left Ventricular systolic function. LVEF = 60% ,**
No regional wall abnormality. No thinning / scarring / dyskinesia of LV wall.
- **No Concentric Left Ventricular Hypertrophy.** (IVSd= 11 mm),
LV Compliance :
No Left Ventricular Diastolic Dysfunction [LVDD]. No Doppler e/o raised LVEDP.
- **VALVES:**
- Structurally Normal Mitral valve/ Aortic valve/Tricuspid valve/ Pulmonary valve .
No significant Valvular Stenosis.
- **Doppler findings:** AV max = 1.21 m/s, PV max = 0.9 m/s.
Trivial Pulmonary Regurgitation, Trivial Tricuspid regurgitation.
- **No Pulmonary Arterial Hypertension.** PASP by TRjet vel.method = 23 mmHg.
- **SEPTAE:** IAS / IVS Appear Intact.
- **IVC :** Normal in dimension and shows good inspiratory 13mm collapse.
- **OTHERS:** No e/o Pericardial effusion / vegetation.

IMPRESSION:

**NORMAL LV SYSTOLIC FUNCTION, LVEF= 60 %, NO RWMA,
NO LVH , NO LVDD ,TRIVIAL PR/TR, NO PAH.**

Revival Diagnostic
401, Aqua Corridor,
B/s. Star Bazar, Surat-395009
Mo. 91062-28601

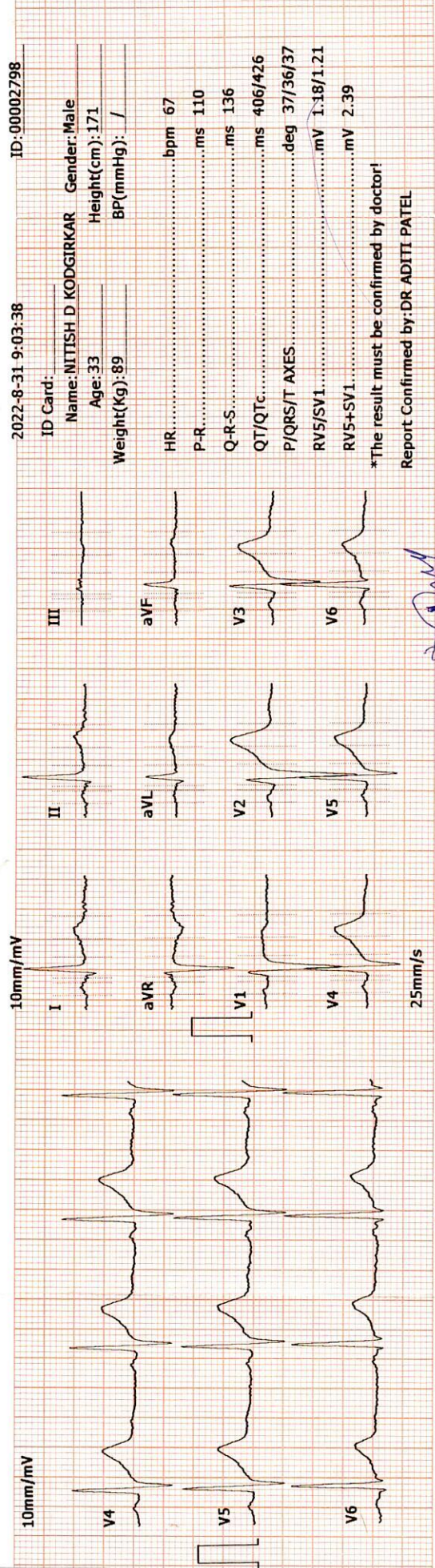
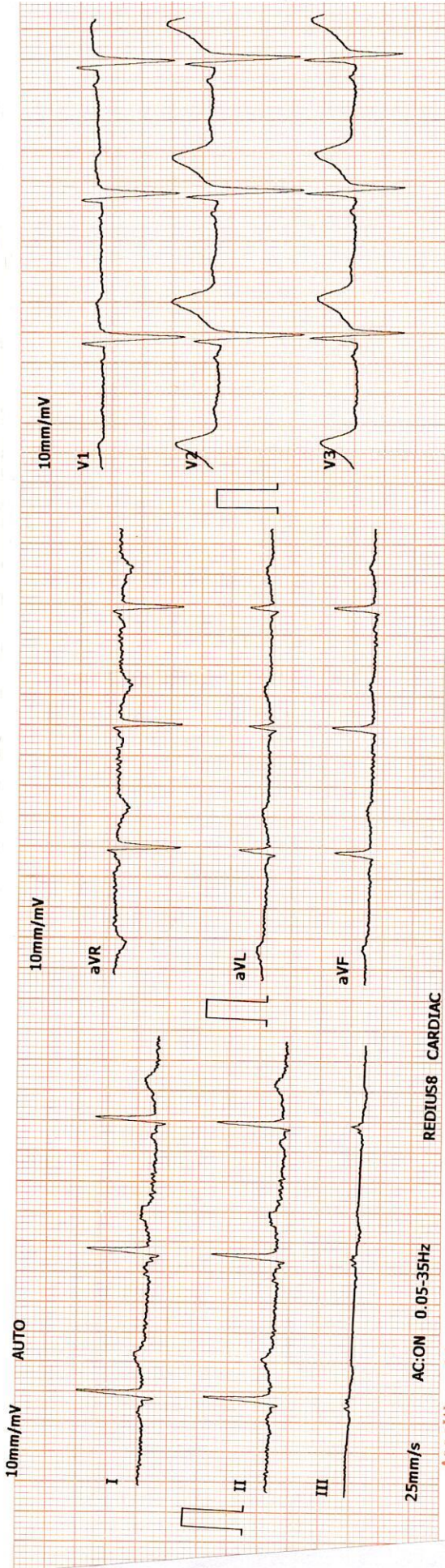

DR SUSHIL YADAV
CONSULTING & CLINICAL
CARDIOLOGIST

Laboratory Test Result are Subject to technical limitation and should be clinically correlate for final diagnosis

📍 4th Floor, Aqua Corridor, Hazira Road, Adajan Pal, Surat-395009.

☎ 0261 2747788, 9825947712 ✉ revivaldiagnostics.surat@gmail.com 🌐 www.revivaldiagnostics.com

This medical report is not intended for medico-legal purposes.



2022-8-31 9:03:38 ID: 00002798
 ID Card: _____
 Name: NITISH D KODGIRKAR Gender: Male
 Age: 33 Height(cm): 171
 Weight(Kg): 89 BP(mmHg): /
 HR: _____ bpm 67
 P-R: _____ ms 110
 Q-R-S: _____ ms 136
 QT/QTc: _____ ms 406/426
 P/QRS/T AXES: _____ deg 37/36/37
 RV5/SV1: _____ mV 1.18/1.21
 RV5+SV1: _____ mV 2.39
 *The result must be confirmed by doctor!
 Report Confirmed by: DR. ADITI PATEL

ADITI PATEL

Revival Diagnostic
 401, Aqua Corridor,
 B/s. Star Bazar, Surat-395009
 MO. 91062-28601

DR. ADITI PATEL
 M.B.B.S., D. CARDIO (MUM)
 CLINICAL CARDIOLOGIST
 REG.NO.G-42901



Name : NITISH D KODGIRKAR

Age/Sex : 33 Yrs. Male

UHID : 21424

Ref. By Dr : MEDI WHEEL

Catagory : CTR

Date : 31-Aug-2022

Rec No : 5416

Lab ID : 17090

Collection Date & Time : 31-Aug-2022 8:48 am

ECG

Test	Observed Value	Biological Referance Interval
------	----------------	-------------------------------

ECG

1. The rhythm is sinus.
2. Heart rate is 67 beats per minute.
3. Normal P,QRS,T wave axis.
4. Normal PR,QRS,Q.T. Duration.
5. No pathological q wave or ST-T changes seen.
6. No evidence of chamber hypertrophy or enlargement seen.

IMPRESSION : ECG WITHIN NORMAL LIMITS

DR. ADITI PATEL
M.B.B.S., D. CARD (MUM)
CLINICAL CARDIOLOGIST
REG.NO.G-42901

Revival Diagnostic
401, Aqua Corridor,
B/s. Star Bazar, Surat-395009
Mo. 91062-28601

Laboratory Test Result are Subject to technical limitation and should be clinically correlate for final diagnosis

4th Floor, Aqua Corridor, Hazira Road, Adajan Pal, Surat-395009.

0261 2747788, 9825947712 revivaldiagnostics.surat@gmail.com www.revivaldignostics.com

This medical report is not intended for medico-legal purposes.



NAME	NITISH KODGIRKAR	DATE	31-Aug-2022
REFERRED BY	MEDI WHEEL	AGE / SEX	33 YRS / M

Thanks for the reference

USG ABDOMEN

LIVER: is normal in size and shows increased echotexture.

No evidence of intrahepatic biliary radicles dilatation / focal space occupying lesion.

The portal vein and common bile duct show normal caliber.

GALL BLADDER: is distended and shows smooth walls. Wall thickness is normal.

No evidence of sludge / calculus. No evidence of pericholecystic collection.

SPLEEN: Is normal in size and shows normal echo pattern.

PANCREAS: shows normal echo anatomy and its relationship with splenic vein is normal.

KIDNEYS: Both the kidneys are normal in size, shape and location and show normal cortico-medullary differentiation.

Right kidney measures- 9.9 X 4.5 cms.

Left kidney measures- 10.3 X 4.8 cms.

No evidence of hydronephrosis or calculus.

URINARY BLADDER: is distended with smooth walls.

No evidence of diverticulum or calculus.

PROSTATE: is normal in size and shows homogeneous echotexture.

No evidence of ascites / pleural effusion.

Fluid and gas filled bowel loops with normal wall thickness and peristalsis noted.

IMPRESSION:

- Fatty Liver - Grade I

Dr. Chirag K. Patel

MBBS-DMPD

Reg. No. G-28509

DR. CHIRAG K. PATEL

4th Floor, Aqua Corridor,

Nr. Star Bazar, Hazira Main Road,

Adajan, Surat-395009.

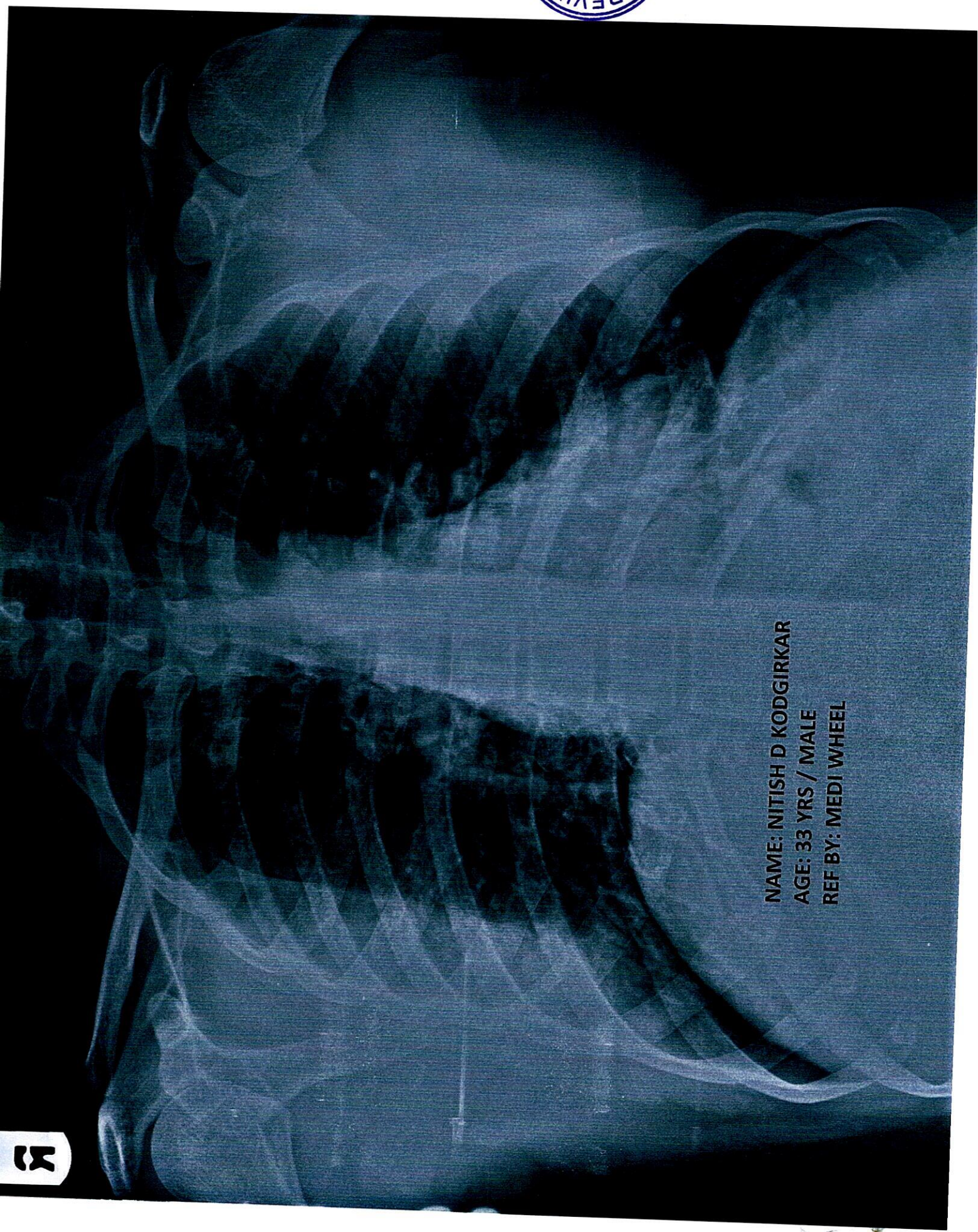Mo. 97266 726683

Laboratory Test Result are Subject to technical limitation and should be clinically correlate for final diagnosis

4th Floor, Aqua Corridor, Hazira Road, Adajan Pal, Surat-395009.

☎ 0261 2747788, 9825947712 ✉ revivaldiagnostics.surat@gmail.com 🌐 www.revivaldiagnostics.com

This medical report is not intended for medico-legal purposes.



NAME: NITISH D KODGIRKAR
AGE: 33 YRS / MALE
REF BY: MEDI WHEEL

R



Name : NITISH D KODGIRKAR
Age/Sex : 33 Yrs. Male
UHID : 21424
Ref. By Dr : MEDI WHEEL
Category : CTR

Date : 31-Aug-2022
Rec No : 5416

Lab ID : 17090

Collection Date & Time : 31-Aug-2022 8:48 am

CHEST RADIOGRAPH-PA VIEW

Hilar shadows are within normal limits.

Pulmonary vasculature appears normal.

Cardiac appears normal in size.

Both domeh of the diaphragm are smooth.

Both costophrenic recesses are clear.

Both lung fields appear normal.

Visualized bones and soft tissue shadows appear normal.

IMPRESSION:

NORMAL STUDY.

Dr. Chirag K. Patel

DR. CHIRAG K. PATEL

MBBS, MD
Reg. No. G-23509

RADIOLOGIST
Revival Diagnostic

4th Floor, Aqua Corridor,
Nr. Star Bazar, Hazira Main Road,
Adajan, Surat-395009.
Mo. 97266 726683

Laboratory Test Result are Subject to technical limitation and should be clinically correlate for final diagnosis

📍 4th Floor, Aqua Corridor, Hazira Road, Adajan Paal, Surat-395009.

☎ 0261 2747788

✉ revivaldiagnostics.surat@gmail.com

🌐 www.revivaldiagnostics.com

This medical report is not intended for medico-legal purposes.