

SARDA

CENTRE FOR DIABETES & SELF CARE

NAME: MR. PRASHANT BOYANE.

SEX: Male AGE: .

REF. BY : Dr. BOB

DATE :04/04/2023

COMPLETE BLOOD COUNT

TEST	RESULT	NORMAL RANGE
WBC COUNT	4900 /cumm	4.0 - 11.0 x 10 ³ /cumm
Haemoglobin:	14.6 g%	13.0 - 18.0 g%
Platelets:	240000 /cumm	1,50,000 - 4,50,000 / cumm
Red Blood Cells:	4.69 /Mill/ul	4.20 - 6.00 Mill/ul
MCV:	92.0 fL	80.0 - 97.0 fL
MCH:	31.1 pg	26.0 - 32.0 pg
MCHC:	33.8 g/dL	31.0 - 36.0 g/dL
HCT:	43.1 %	37.0 - 51.0 %
Differential Count		
Neutrophils:	60 %	40 - 75 %
Lymphocyte:	34 %	20 - 45 %
Monocytes:	04 %	2 - 10 %
Eosinophills:	02 %	1 - 06 %
Basophills:	00 %	0 - 1 %
ESR:	08 mm at 1 Hr.	Male: 0 - 8 mm at 1 Hr. Female: 0 - 20 mm at 1 Hr.

AGE: YRS

BLOOD GROUP

BLOOD GROUP : "B"
R.H.FACTOR : POSITIVE

Dr. R. SARDA

M.D. Reg. No. 54462

SARDA CENTER FOR DIABETES & SELF CARE

Dr. Sampat Sarda, Jalna Road, Aurangabad

M.D. (Pathology) Ph. No. 2333851, 2334858

SARDA

CENTRE FOR DIABETES & SELF CARE

NAME: MR. PRASHANT BOYANE.

SEX: Male AGE: .

REF. BY : Dr. BOB

DATE :04/04/2023

BLOOD SUGAR EXAMINATION

TEST	RESULT		
Fasting Blood Sugar:	79 mg/dl		
Post Meal Blood Suagr Level:	114 mg/dl		
REFERANCE RANGE :	NON DIABETIC	IGT	DIABETIC
FASTING	</=90MG	90-126 mg %	>/=126mg %
POSTMEAL	</=140mg	140-200mg%	>/=200mg

GYCOCYTED HAEMOGLOBIN

TEST	RESULT	NORMAL
HbA1C:	5.6 %	4.7-5.9 %
M.B.G	108.88% mg	70 - 120 mg
INTERPRETATION:		
FOR DIABETIC PATIENT		
Good Control:	6.0 - 7.0 %	
Fair Diabetic Control:	7.0 - 8.0 %	
Unsatisfactory control:	8.0 - 10 %	
Poor Diabetic Control:	Above 10 %	

Dr. G. R. SARDA
M.D. Reg. No. 59462
SARDA CENTER FOR DIABETES & SELF CARE
Dr. Sampat Sarda
M.D. (Pathology) 2333851, 2334858

SARDA

CENTRE FOR DIABETES & SELF CARE

NAME: MR. PRASHANT BOYANE.

SEX: Male AGE: .

REF. BY : Dr. BOB

DATE :04/04/2023

BLOOD PROFILE

TEST	RESULT	NORMAL
CHOLESTROL	244mg%	150-250 mg%
TRIGLYCERIDES'''	531mg %	30-160 mg%
H.D.L	38mg%	35-.55mg %
CREATININE	0.9mg%	0.6-1.4 mg %
BILIRUBIN TOTAL	0.6mg%	0.2-1.0 mg
DIRECT	0.2	0.0-0.3
INDIRECT	0.4	0.3-0.7
S.G.O.T	37 IU/L	15-40 IU/L
S.G.P.T	39 IU/L	15-40 IU/L
ALK PHOSPHATASE	58 IU/L	42-128IUL
S.PROTEIN TOTAL	7.1gm%	6.0-8.0 gm%
ALBUMIN	4.3gm%	3.2-4.4 gm%
GLOBULINS	2.8gm%	2.3-3.5 gm%
ALB/GLO RATIO	1.5357	
G.G.T.P	26	upto50IU
SR.URIC ACID	4.1	3.5-7.0 mg %\$sruric-

Dr. S R. SARDA

M.D Reg. No.86462

SARDA CENTER FOR DIABETES & SELF CARE

Dr. Sampat Sarda, Jalna Road, Aurangabad

M.D.(Pathology) 2333851, 2334668

SARDA

CENTRE FOR DIABETES & SELF CARE

NAME: MR. PRASHANT BOYANE.

SEX: Male AGE: .

REF. BY : Dr. BOB

DATE :04/04/2023

AGE: YRS

THYROID FUCTION TEST

TEST	RESULT	NORMAL RANGE
Total T 3 :	96.50 ng/ml	87 - 178 ng/ml
Total T 4 :	8.47 ug/dl	6.09 - 12.23 ug/dl
TSH Ultrasensitive :	1.33 uIU/ml	0.38 - 5.33 uIU/ml

Dr. Sampat Sarda
M.D. (Pathology)
Dr. R. SARDA
M.D. Reg. No. 54462
CENTRE FOR DIABETES & SELF CARE
4, Vyanktesh Nagar, Jalna Road, Aurangabad
Phone No. 2333851, 2334858

SARDA

CENTRE FOR DIABETES & SELF CARE

NAME: MR. PRASHANT BOYANE.

SEX: Male AGE: .

REF. BY : Dr. BOB

DATE :04/04/2023

Urine Routine Examination

Physical Examination

Colour:	Pale Yellow
Appearance:	Clear
Reaction:	Acidic
Deposit	Absent

Chemical Examination:

Specific Gravity	1.010
Albumin	Absent
Sugar:	Absent
Acetone:	----
Bile Salts	----
Bile Pigment:	----

Microscopic Examination

RBC :	Absent
Pus Cells:	OCASSIONAL/HPF
Epithelial cells:	Absent
Crystals:	Absent
Casts:	Absent

Dr. G R. SARDA
M.D Reg. No. 62462
SARDA CENTER FOR DIABETES & SELF CARE
Dr. Sampat Sarda Jalna Road, Aurangabad
M.D.(Pathology) Reg. No. 2333851, 2334858

SARDA

CENTRE FOR DIABETES & SELF CARE

Date:- 04/02/23

Name Mr. Prashant Bhatnagar Age/Sex 33/Male

Address Behind of B7 dobler

OPHTHALMIC EXAMINATION REPORT

	<u>Right Eye</u>	<u>Left eye</u>
Vision Distant	6/6E - 300m/pt	6/6E - 250m/pt
Vision Near	N6	N6
Anterior segment	<u>NAD</u>	<u>NAD</u>
Pupils	NSRTL	<u>NSRTL</u>
Lens	clear	clear
Tension	<u>Normal</u>	<u>Normal</u>
Fundus:-	Disc WNL C100.3F R+	Disc WNL C100.3F R+
Colour Vision	Normal	Normal

Impression: BE Myopic Astigmatism++
Rest within normal limits.



Dr. Ajay Lohiya

DR. AJAY LOHIYA
M.B.B.S., D.O. (BOM) D.N.B.F.C.P.S.
REG. NO. 66436
TIRUPATI-NETRALAYA & DENTAL CLINIC
AURANGABAD.

Sarda Centre For Diabetes & Selfcare

04, Venkateshnagar, Jalna Rd, Aurangabad

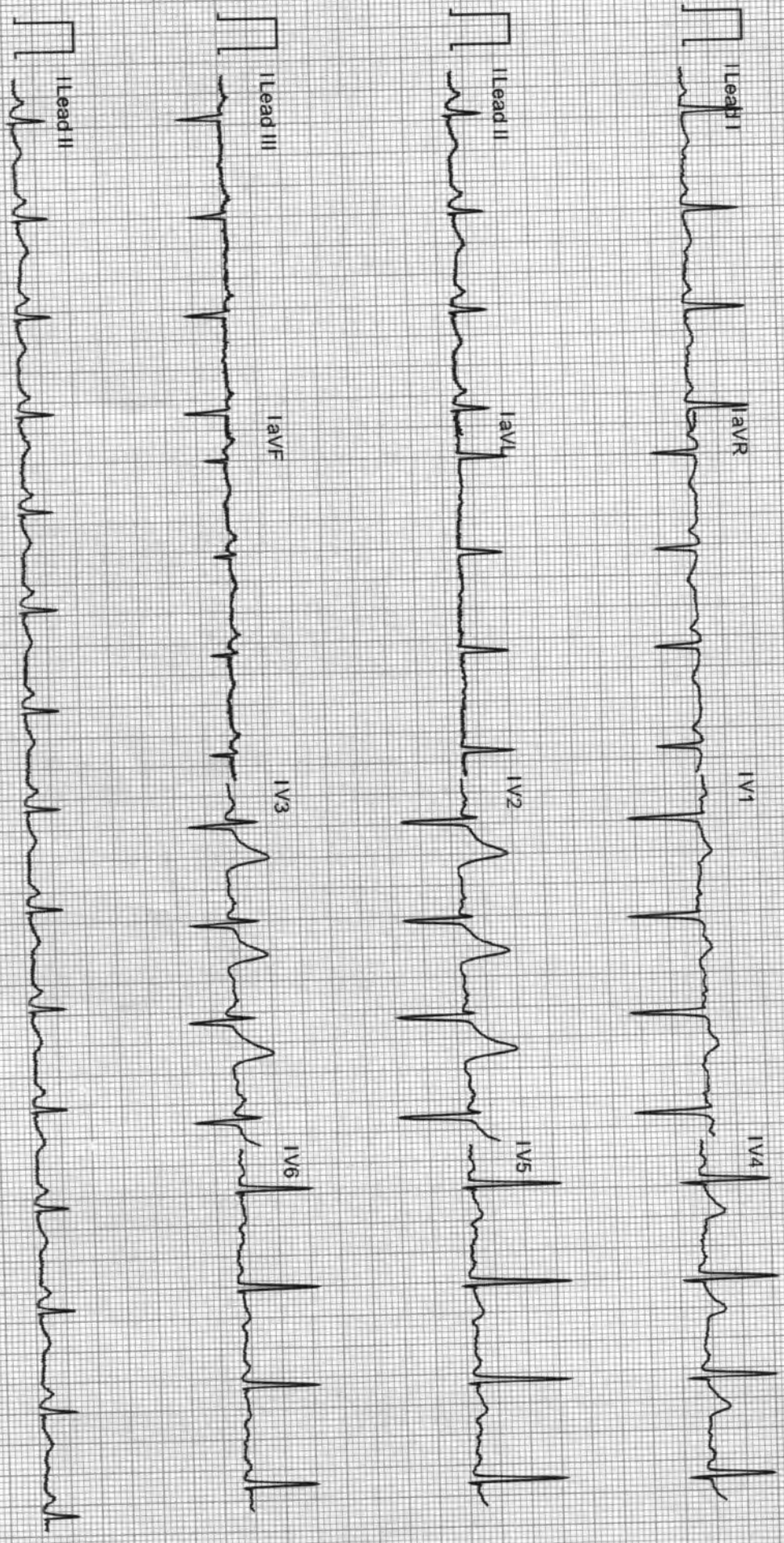
Abnormal waveform detected

Prashant Boyane

AGE/SEX : 32 Yrs / M
DATE TIME : 04/04/2023 10:22
REF BY : DR. Dr. A.S. Sarda

DR. A.S. SARDA
M.D. (P) (G) (D)
SARDA CENTRE FOR DIABETES & SELF CARE
& Vascular medicine, Jalna Rd, Aurangabad

Handwritten signature

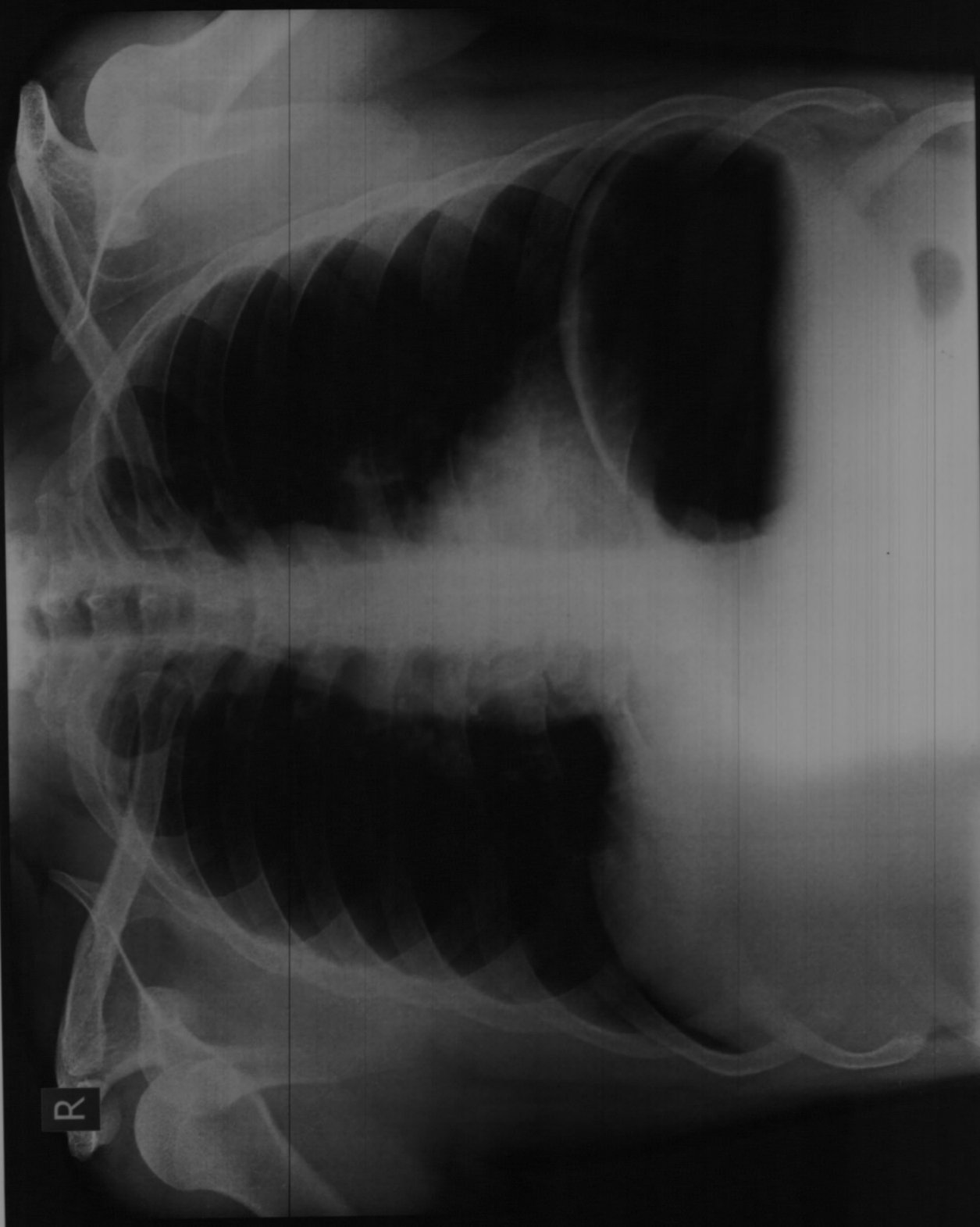


25.0 mm/s, 10.0 mm/mV
Technician : saradabtechnician

ET Cardioplot 12

Handwritten signature

R



MR PRASHANT BOYANE Age : 32 YRS Male

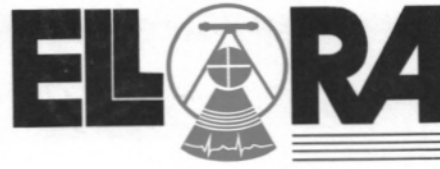Chest - PA Patient ID

Ref Dr - DR S SARDA

Date 04-04-2023 PM 12:23:34

Ellora Diagnostic Centre, Aurangabad (0240) 2353182

DIGITAL X-RAY
INTERVENTIONAL RADIOLOGY
3D/4D SONOGRAPHY & COLOR DOPPLER
2-D ECHOCARDIOGRAPHY
PERIPHERAL COLOR DOPPLER
HI-SPEED HELICAL C.T. SCAN
C.T. ANGIOGRAPHY
PATHOLOGY LAB. SERVICES



DIAGNOSTIC CENTRE
X-RAY, IMAGING & PATHOLOGY

1, VYANKATESH NAGAR, OPP. SFS
HIGH SCHOOL, JALNA ROAD,
AURANGABAD - 431005
☎ : 0240 - 2353182, 2325282, 8446100111

PRASHANT BOYANE

04-04-2023

Ref. by:

CHEST PA VIEW

Trachea central.

Apices are clear.

Both lung fields appeared well pneuamtised and appeared normal.

Both cp angles are clear.

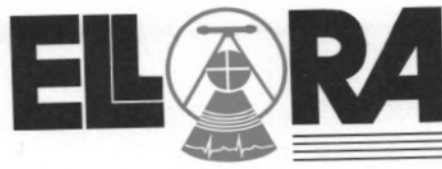Cardiac shadow apperaed normal.

IMPRESSION :
NORMAL CHEST

DR. P. A. BARJATYA
M.B.B.S., M.D.
9823344449

Dr. Gokuldas S. Lahoti
Radiologist
Regd.No.59887
Sarda Center For Diabetes & Selfcare
4, Venkatesh Nagar, Aurangabad.
DR. G. S. LAHOTI
M.B.B.S., D.M.R.D.
9850171587

DIGITAL X-RAY
INTERVENTIONAL RADIOLOGY
3D/4D SONOGRAPHY & COLOR DOPPLER
2-D ECHOCARDIOGRAPHY
PERIPHERAL COLOR DOPPLER
HI-SPEED HELICAL C.T. SCAN
C.T. ANGIOGRAPHY
PATHOLOGY LAB. SERVICES



DIAGNOSTIC CENTRE
X-RAY, IMAGING & PATHOLOGY

1, VYANKATESH NAGAR, OPP. SFS
HIGH SCHOOL, JALNA ROAD,
AURANGABAD - 431005
☎ : 0240 - 2353182, 2325282, 8446100111

Prashant Boyane

04-04-2023

Ref. by:

USG ABDOMEN

Liver is normal in size, shape and revealed normal echotexture.
Intrahepatic biliary radicles and portovenous echocomplex appeared normal.
No e/o any focal solid, cystic, or diffuse parenchymal pathology seen.
Normal cbd and portal vein.
Gallbladder is physiologically distended and appeared normal, no e/o any gallbladder calculus.
Normal gb wall thickness.
Spleen is normal in size & echogenicity. no e/o focal lesion seen.
Pancreas is normal in size, shape and echotexture. Normal peripancreatic fat planes.
No e/o pancreatic calcification/calculi. normal pancreatic duct.
Both kidneys are normal in size, shape, position and revealed normal cortical & medullary echopattern,
No e/o any calculus seen, No e/o hydronephrosis.
No e/o ascitis. no e/o any paraaortic adenopathy.
Normal bowel loop peristalsis & caliber.
Urinary bladder is well distended and appeared normal, no e/o any vesical calculus or mass lesion.
No changes of cystitis.
Normal prostate.

IMPRESSION :

**NORMAL LIVER, GALL BLADDER, SPLEEN, PANCREAS, BOTH KIDNEYS, .
NORMAL UR BLADDER, PROSTATE.**

DR. P. A. BARJATYA
M.B.B.S., M.D.
9823344449

Dr. Gokuldas S. Lahoti
Radiologist
Regd.No.59887
Sarda Center For Diabetes & Selfcare
4, Venkatesh Nagar, Aurangabad.
DR. G. S. LAHOTI
M.B.B.S., D.M.R.D.
9850171587