



Savita

Superspeciality Hospital
(A Unit of Solace Healthcare Pvt. Ltd.)

Parivar Char Rasta, Waghodia-Dabhoi Ring Road, Vadodara-390019

0265-2578844 / 2578849 | mh@savitahospital.com | savitahospital.com

PHYSICIAN EXAMINATION

| | | | |
|-----------------|-------------------------|--------------|-------------------|
| Name : | RAKESHBHAI TADVI | Age : | 35/MALE |
| Reg.No : | 20230107923 | DOE : | 28/01/2023 |

Physical Examination:

| | | | | | | | |
|----------------|--------------|----------------|---------------|---------------|------------|---------------------|---------------|
| Height: | 174CM | Weight: | 71KG | PULSE: | 70 | Temperature: | NORMAL |
| BMI : | 23.45 | BP : | 114/76 | SPO2 | 98% | | |

| | |
|-------------------------------|---|
| Chief Complaint : | HEADACHE |
| Past History : | NAD |
| General Examination : | NAD |
| Systemic Examination : | NAD |
| INVESTIGATION : | NAD |
| ADVICE : | FREE FATTY DIET TAB .ROSUCOR -F (10/160) 0----0----1 (1 MONTH) TAB.NAXDOM 500 1---0---1 (3 DAYS) SOS |

DR. SAURABH JAIN







Examination By Ophthalmologist

| | | | |
|---------------------------------------|--------------------------------------|-------|------------------|
| Name : | RAKESHBHAI TADVI | Age : | 35/MALE |
| Reg.No : | 20230107923 | DOE : | 28/01/2023 |
| Present Complaints : | NO FRESSH C/O | | |
| Medical History : | NAD | | |
| Examination Of Eye : | NAD | | |
| External Examination : | NAD | NAD | |
| Ati Seg Examination : | NAD | NAD | |
| Schiotz Tonometry IOP : | 14 | 14 | |
| Fundus : | NAD | NAD | |
| Without Glass | Distant Vision : | | |
| | Near Vision : | | |
| With Glass | Distant Vision : 6/6WITH-0.75/180 | | 6/6WITH-0.75/180 |
| | Near Vision :N6 | | N6 |
| Colour Vision (With Ishihara Chart) : | WNL | | |
| Advice : | NAD | | |

DR CHETAN CHAUHAN





| | | | |
|-----------------------|-----------------------------|------------------------|--|
| Patient Name : | Rakeshbhai Jagdishbhai Tadv | Sample No. : | 20230113863  |
| Patient ID : | 20230107923 | Visit No. : | OPD20230123557 |
| Age / Sex : | 35y/Male | Coll. Date : | 28/01/2023 10:14 |
| Consultant : | DR SAURABH JAIN | S. Coll. Date : | 28/01/2023 10:43 |
| Ward : | - | Report Date : | 28/01/2023 13:00 |

CBC, ESR

| Investigation | Result | Normal Value |
|------------------------|-----------------------------------|-------------------------------------|
| Hemoglobin : | 14.4 gm/dl | 13.5 to 18.0 gm/dl |
| P.C.V. : | 45.8 % | 42.0 to 52.0 % |
| M.C.V. : | 70.9 fL [L] | 78 to 100 fL |
| M.C.H. : | 22.3 pg [L] | 27 to 31 pg |
| M.C.H.C. : | 31.4 g/dl [L] | 32 to 36 g/dl |
| RDW : | 11.6 % | 11.5 to 14.0 % |
| RBC Count : | 6.46 X 10 ⁶ / cumm [H] | 4.7 to 6.0 X 10 ⁶ / cumm |
| Polymorphs : | 60 % | 38 to 70 % |
| Lymphocytes : | 36 % | 15 to 48 % |
| Eosinophils : | 2 % | 0 to 6 % |
| Monocytes : | 2 % [L] | 3 to 11 % |
| Basophils : | 0 % | 0.0 to 1.0 % |
| Total : | 100 | < 100 > 100 |
| WBC Count : | 5000 /cmm | 4000 to 10000 /cmm |
| Platelets Count : | 346000 /cmm | 1,50,000 to 4,50,000 /cmm |
| ESR - After One Hour : | 5 mm/hr | 1 to 13 mm/hr |



Dr. Mehul Desai
M.B.D.C.P
Reg.No.G-9521




Savita

Superspeciality Hospital
(A Unit of Solace Healthcare Pvt. Ltd.)

Parivar Char Rasta, Waghodia-Dabhoi Ring Road, Vadodara-390019

☎ 0265-2578844 / 2578849 ✉ mh@savitahospital.com 🌐 savitahospital.com

| | | | |
|-----------------------|------------------------------|------------------------|--|
| Patient Name : | Rakeshbhai Jagdishbhai Tadvi | Sample No. : | 20230113863  |
| Patient ID : | 20230107923 | Visit No. : | OPD20230123557 |
| Age / Sex : | 35y/Male | Coll. Date : | 28/01/2023 10:14 |
| Consultant : | DR SAURABH JAIN | S. Coll. Date : | 28/01/2023 10:43 |
| Ward : | - | Report Date : | 28/01/2023 13:00 |

Blood Group

| Investigation | Result | Normal Value |
|----------------------|----------|--------------|
| BLOOD GROUP : | | |
| ABO | O | |
| Rh | Positive | |

RENAL FUNCTION TEST

| Investigation | Result | Normal Value |
|---------------|-----------|-----------------|
| Creatinine : | 0.7 mg/dl | 0.6 - 1.4 mg/dl |
| Urea : | 24 mg/ dl | 13 - 45 mg/dl |
| Uric Acid : | 6.2 mg/dl | 3.5 - 7.2 mg/dl |
| Calcium : | 9 mg/dl | 8.5 - 10.5 |
| Phosphorus : | 4.3 mg/dl | 1.5 - 6.8 |



Dr. Mehul Desai
M.B.D.C.P
Reg.No.G-9521




Savita

Superspeciality Hospital
(A Unit of Solace Healthcare Pvt. Ltd.)

Parivar Char Rasta, Waghodia-Dabhoi Ring Road, Vadodara-390019

☎ 0265-2578844 / 2578849 ✉ mh@savitahospital.com 🌐 savitahospital.com

| | |
|--|--|
| Patient Name : Rakeshbhai Jagdishbhai Tadvi | Sample No. : 20230113863  |
| Patient ID : 20230107923 | Visit No. : OPD20230123557 |
| Age / Sex : 35y/Male | Coll. Date : 28/01/2023 10:14 |
| Consultant : DR SAURABH JAIN | S. Coll. Date : 28/01/2023 10:43 |
| Ward : - | Report Date : 28/01/2023 13:00 |

Lipid Profile

| Investigation | Result | Normal Value |
|--------------------------|----------------------|---|
| Sample : | Fasting | |
| Sample Type : | Normal | |
| Cholesterol (Chol) : | <u>245 mg/dl [H]</u> | Low risk : < 200 Moderate risk : 200 - 239 High risk : > or = 240 |
| Triglyceride : | <u>310 mg/dl [H]</u> | Normal : < 200.0 High : 200 - 499 Very High : > or = 500 |
| HDL Cholesterol : | 42 mg/dl | Low risk : >or = 60 mg/dL High risk : Up to 35 mg/dL |
| LDL : | <u>141 mg/dl [N]</u> | 131.0 to 159.0(N) < 130.0(L) > 159.0(H) |
| VLDL : | <u>62 mg/dl [H]</u> | Up to 0 to 34 mg/dl |
| LDL/HDL Ratio : | 3.36 | Low risk : 0.5 to 3.0 Moderate risk : 3.0 to 6.0 Elevted level high > 6.0 |
| Total Chol / HDL Ratio : | 5.83 | Low Risk : 3.3 to 4.4 Average Risk : 4.4 to 7.1 Moderate Risk : 7.1 to 11.0 High Risk : > 11.0 |
| Total Lipids : | <u>897 mg/dl [H]</u> | 400 to 700 mg/dl |

Note :- Lipemic samples give high triglyceride value and falsely low LDL value.



Dr. Mehul Desai
M.B.D.C.P
Reg.No.G-9521



| | | | |
|-----------------------|------------------------------|------------------------|--|
| Patient Name : | Rakeshbhai Jagdishbhai Tadvi | Sample No. : | 20230113863  |
| Patient ID : | 20230107923 | Visit No. : | OPD20230123557 |
| Age / Sex : | 35y/Male | Coll. Date : | 28/01/2023 10:14 |
| Consultant : | DR SAURABH JAIN | S. Coll. Date : | 28/01/2023 10:43 |
| Ward : | - | Report Date : | 28/01/2023 13:00 |

LFT (Liver Function Test)

| Investigation | Result | Normal Value |
|------------------------------|-----------|------------------|
| Total Bilirubin : | 0.5 mg/dl | 0.2 to 1.0 mg/dl |
| Direct Bilirubin : | 0.2 mg/dl | 0.0 to 0.2 mg/dl |
| Indirect Bilirubin : | 0.3 mg/dl | 0.0 to 0.8 mg/dl |
| AST (SGOT) : | 23 U/L | 5 to 34 U/L |
| ALT (SGPT) : | 37 U/L | 0 to 55 U/L |
| Total Protein (TP) : | 6.7 g/dL | 6.4 to 8.3, g/dl |
| Albumin (ALB) : | 4.2 g/dl | 3.5 to 5.2 g/dl |
| Globulin : | 2.5 g/dl | 2.3 to 3.5 g/dl |
| A/G Ratio : | 1.68 | |
| Alkaline Phosphatase (ALP) : | 84 U/L | 40 to 150 U/L |
| GAMMA GT. : | 19 U/L | 7 to 35 U/L |



Dr. Mehul Desai
M.B.D.C.P
Reg.No.G-9521



Savita

Superspeciality Hospital
(A Unit of Solace Healthcare Pvt. Ltd.)

Parivar Char Rasta, Waghodia-Dabhoi Ring Road, Vadodara-390019

☎ 0265-2578844 / 2578849 ✉ mh@savitahospital.com 🌐 savitahospital.com

Patient Name : Rakeshbhai Jagdishbhai Tadvi

Sample No. : 20230113863



Patient ID : 20230107923

Visit No. : OPD20230123557

Age / Sex : 35y/Male

Coll. Date : 28/01/2023 10:14

Consultant : DR SAURABH JAIN

S. Coll. Date : 28/01/2023 10:43

Ward : -

Report Date : 28/01/2023 13:00

Urine R/M

| Investigation | Result | Normal Value |
|--------------------|-------------|--------------|
| Quantity - : | 10 ml | |
| Colour - : | Pale Yellow | |
| Reaction (pH) : | 6.0 | 4.6-8.0 |
| Turbidity : | Clear | |
| Deposit : | Absent | Absent |
| Sp.Gravity : | 1.020 | 1.005-1.010 |
| Protein : | Absent | Absent |
| Glucose : | Absent | Absent |
| Bile Salts : | Absent | Absent |
| Bile pigments : | Absent | Absent |
| Ketones : | Absent | Absent |
| Urobilinogen : | Absent | |
| Blood : | Absent | Absent |
| Pus Cells : | Absent /hpf | 0-5/hpf |
| Red Blood Cells : | Absent /hpf | Absent |
| Epithelial Cells : | 0-1 /hpf | |

Dr.Mehul Desai
M.B.D.C.P
Reg.No.G-9521




Savita

Superspeciality Hospital
(A Unit of Solace Healthcare Pvt. Ltd.)

Parivar Char Rasta, Waghodia-Dabhoi Ring Road, Vadodara-390019

☎ 0265-2578844 / 2578849 ✉ mh@savitahospital.com 🌐 savitahospital.com

| | | | |
|-----------------------|------------------------------|---|------------------|
| Patient Name : | Rakeshbhai Jagdishbhai Tadvi | Sample No. : | 20230113863 |
| Patient ID : | 20230107923 |  | |
| Age / Sex : | 35y/Male | Visit No. : | OPD20230123557 |
| Consultant : | DR SAURABH JAIN | Coll. Date : | 28/01/2023 10:14 |
| Ward : | - | S. Coll. Date : | 28/01/2023 10:43 |
| | | Report Date : | 28/01/2023 17:14 |

FBS & PPBS

| Investigation | Result | Normal Value |
|-------------------------|---------------|-----------------|
| Blood Sugar (FBS) : | 127 mg/dl [H] | 74 - 100 mg/dl |
| Urine Sugar (FUS) : | Nil | |
| Blood Sugar (PP2BS) : | 140 mg/dl [H] | 70 to 120 mg/dl |
| Urine Sugar (PP2US) : | Nil | |

HBA1C

| Investigation | Result | Normal Value |
|---|-----------|---|
| Glycosylated Hb : | 6.2 % [H] | Near Normal Glycemia : 6 to 7 Excellent Control : 7 to 8 Good Control : 8 to 9 Fair Control : 9 to 10 Poor Control : > 10 |
| Average Plasma Glucose of Last 3 Months : | 131.24 | |



Dr. Mehul Desai
M.B.D.C.P
Reg.No.G-9521



TEST REPORT

| | | | |
|----------------|-----------------------------------|-------------|---|
| Name | : RAKESHBHAI TADVI | Acc. ID | : 231001380 |
| Age/Sex | : 35 Years / Male | Birthdate | : Regd. Dt : 28-Jan-2023 02:54 PM |
| Refd. By | : SAVITA SUPERSPECIALITY HOSPITAL | Status | : Final |
| Sample | : Serum (Blood in Plain) | PassportNo: | : Coll Dt. TM. : 28-Jan-2023 02:30 PM |
| Client Details | : SAVITA SUPERSPECIALITY HOSPITAL | Mobile | : Recd. Dt. Tm. : 28-Jan-2023 02:54 PM |
| | | | : Report Dt. Tm. : 28-Jan-2023 04:24 PM |

IMMUNOLOGY

| Test Name | Result | Unit | Biological Ref. Interval |
|-----------|--------|------|--------------------------|
|-----------|--------|------|--------------------------|

THYROID FUNCTION TEST

| | | | |
|--|-------|--------|----------------|
| T3 (Triiodothyronine) CHEMILUMINESCENT MICROPARTICLE IMMUNOASSAY | 1.55 | ng/mL | 0.97 - 1.69 |
| T4 (Thyroxine) CHEMILUMINESCENT MICROPARTICLE IMMUNOASSAY | 7.50 | µg/dL | 5.5 - 11.0 |
| TSH CHEMILUMINESCENT MICROPARTICLE IMMUNOASSAY | 2.005 | µIU/ml | 0.4001 - 4.049 |

----- End Of Report -----

This is an Electronically Authenticated Report.

Kinjal
Dr. Kinjal Patel
M. D. PATHOLOGY
GMC No. G-33123

Verified By
Auto

Dr. VIRAL A. PATEL
M. D. PATHOLOGY
GMC No. G-22658

Page 1 of 1

35 Years

Male

Rate 70

PR 172

QRSD 92

QT 340

QTc 367

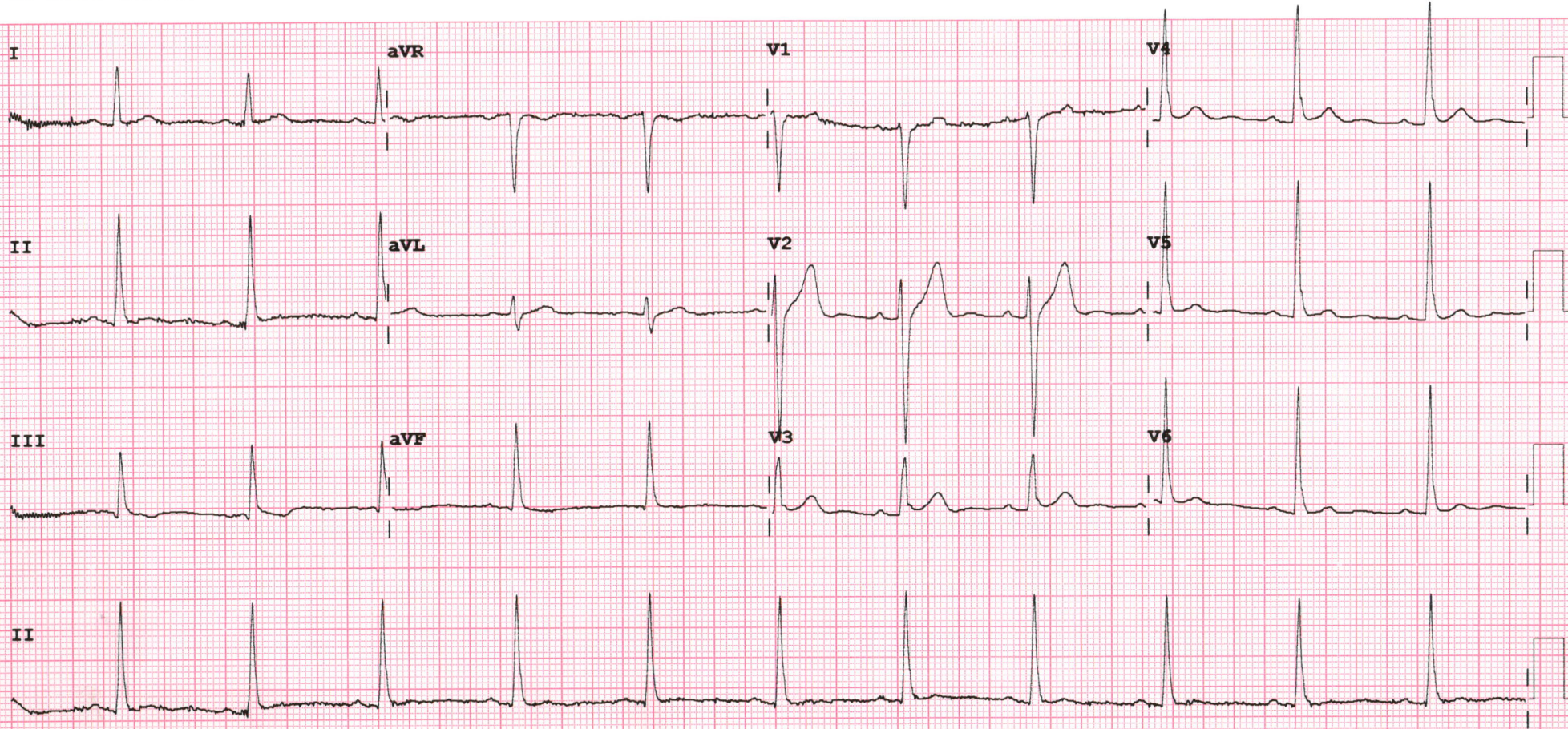
--AXIS--

P 17

QRS 62

T -11

12 Lead; Standard Placement



Device:

Speed: 25 mm/sec

Limb: 10 mm/mV

Chest: 10.0 mm/mV

F 50~ 0.50-150 Hz W

PH09

P?



2D-ECHOCARDIOGRAPHY AND COLOR DOPPLER REPORT

NAME: RAKESHBHAI TADVI

AGE/SEX: 35 YRS/MALE

DATE: 28/01/2023

REF BY - HCP

OBSERVATION:

- NORMAL LV SIZE WITH NORMAL LV SYSTOLIC FUNCTION. LVEF = 60% (VISUAL).
- NO RWMA AT REST.
- NO E/O LV DIASTOLIC DYSFUNCTION.
- TRIVIAL MR. NO MS.
- NO AR. NO AS.
- TRIVIAL TR. NO PAH.
- NORMAL SIZED LA, RA & RV SIZE WITH NORMAL RV SYSTOLIC FUNCTION.
- NORMAL MPA, RPA & LPA.
- INTACT IAS & IVS.
- NO E/O INTRACARDIAC CLOT/VEGETATION/PE.
- NORMAL IVC.
- NORMAL PERICARDIUM.

CONCLUSION:

- NORMAL LV/RV SIZE AND SYSTOLIC FUNCTION.
- NO RWMA AT REST.
- LVEF = 60% (VISUAL).



DR. NIRAV BHALANI
[CARDIOLOGIST]

DR. ARVIND SHARMA
[CARDIOLOGIST]

DR. CHIRAG SHETH
[CARDIOLOGIST]

DR. KASHYAP PATEL
[CARDIOLOGIST]



Saturday, January 28, 2023

RAKESHBHAI J. TADVI

35 YEARS/MALE

ULTRASONOGRAPHY OF ABDOMEN AND PELVIS

Liver shows normal size and echogenicity. No mass lesion detected.
PV, CBD and intrahepatic biliary radicals shows no dilatation.

The gall bladder is contracted.

Spleen appears normal in size and echotexture. No evidence of focal lesion.
Pancreas appears normal in size and echotexture. No focal lesion.

Both kidneys show normal size, position and cortical echogenicity.
Right kidney measures 9.9 cm and Left kidney measures 10.4 cm.
Corticomedullary differentiation is preserved bilaterally.
No calculus or hydronephrosis on either side.

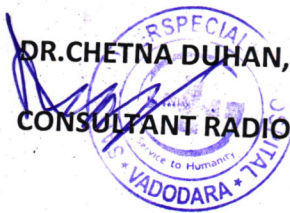The urinary bladder is distended and appears normal.
Prostate appears normal. (17 cc) No focal lesion.

CONCLUSION:

NO SONOGRAPHIC ABNORMALITY IS DETECTED.

DR. CHETNA DUHAN, M.D

CONSULTANT RADIOLOGIST





28/01/2023

RAKESHBHAI J. TADVI

35 YEARS/MALE

CHEST X RAY PA VIEW

Both the lung fields appear normal.

Both costophrenic angles appear clear.

Cardiac silhouette appear normal.

Both hila appears normal.

Mediastinum and aorta appear normal.

Bony thorax appears normal.

No evidence of free gas seen under dome of diaphragm.

COMMENTS:

- **NORMAL BOTH LUNG FIELDS.**
- **NORMAL CARDIAC SIZE.**

DR. CHETNA DUHAN, M.D
CONSULTANT RADIOLOGIST

