



भारतीय विशिष्ट पहचान प्राधिकरण
भारत सरकार
 Unique Identification Authority of India
 Government of India

नामांकन क्रम / Enrollment No.: 2019/22167/00099

To
 रंजू सिंह
 Ranju Singh
 W/O: Neeraj Aggarwal
 C - 8/38
 Rohini Sector 15
 Rohini Sector 15
 Narela North West Delhi
 Delhi 110089
 9868018806

06/07/2013
 135817369



ML358173691FT



Handwritten signature

आपका आधार क्रमांक / Your Aadhaar No. :

2584 5756 7398

आधार - आम आदमी का अधिकार

Handwritten signature
 DEENITIN AGARWAL
 MBBS, MD
 Regn. No. DMC-R-1436



भारत सरकार
 Government of India



रंजू सिंह
 Ranju Singh
 जन्म तिथि / DOB : 17/04/1975
 महिला / Female



2584 5756 7398

आधार - आम आदमी का अधिकार

ONEPLUS ULTRASOUND LAB
 47, Harsh Vihar, Pitam Pura,
 Delhi-110034
 Ph. 011-42480101, 9599913051
 E-mail: oneplusul@gmail.com



ONEPLUS ULTRASOUND LAB
47, Harsh Vihar, Pitam Pura,
Delhi-110034
Ph. 011-42492101, 9559913051
E-mail: oneplusul@gmail.com



RHV

Dr. NITIN AGARWAL
MBBS, MD
Regn. No. DMC-R-1436

11111

ONEPLUS ULTRASOUND LAB

47, HARSH VIHAR, PITAMPURA, DELHI- 110034

Ms. RANJU SINGH
Age : 47/F
Ref. by: MEDIWHEEL
Indication1 :
Indication2 :
Indication3 :
COMMENTS : Moderate Right Axis Deviation, Sinus Rhythm.

ID : 2103
HWT : 151/84
Recorded : 11-2-2023 10:16
Medication1 :
Medication2 :
Medication3 :

BPM : 83
BP : 124/82
P Axis : 59 deg
QRS Axis : 99 deg
T Axis : -31 deg

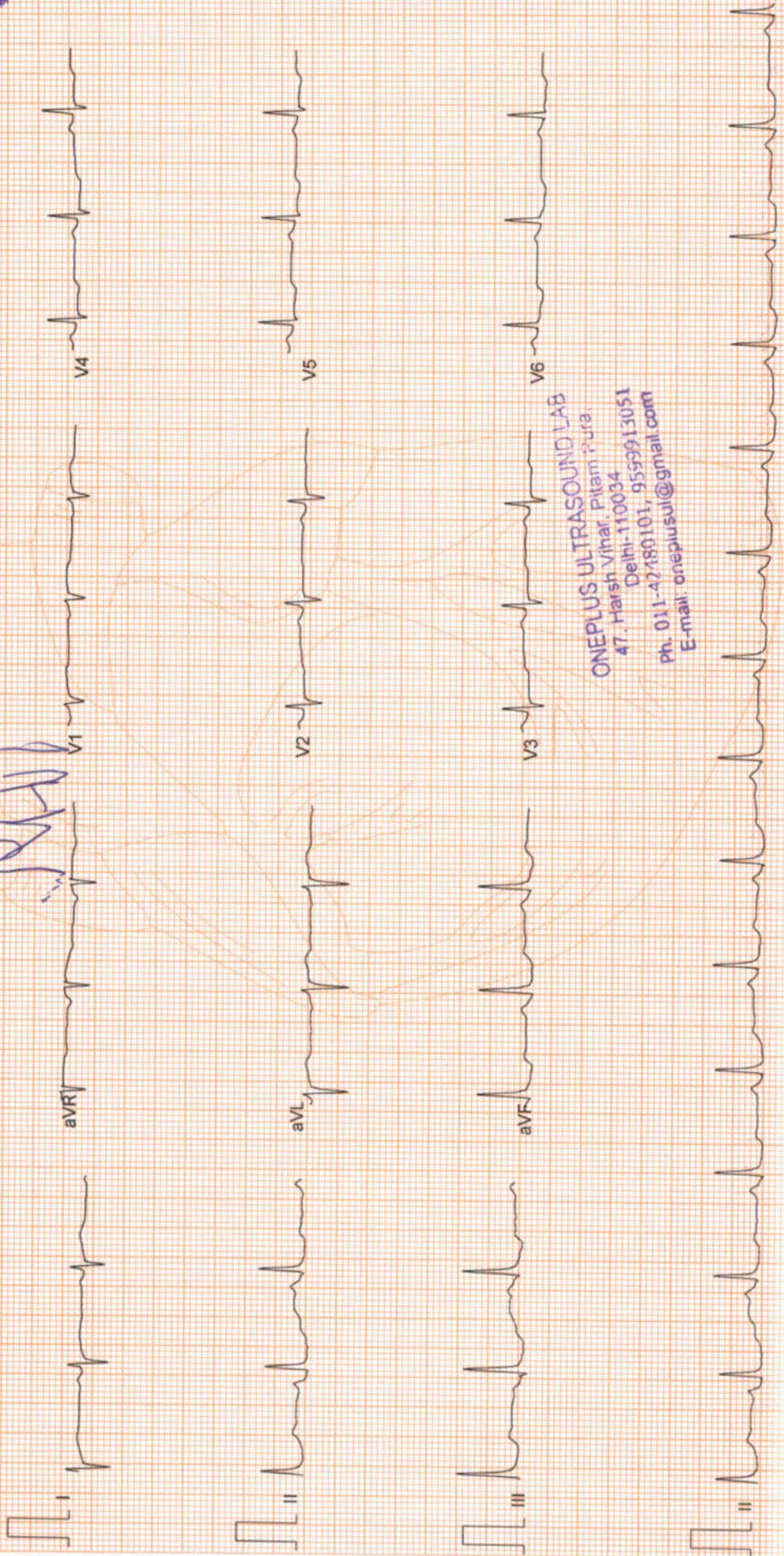
P duration : 83 msec
PR duration : 136 msec
QRS duration : 93 msec
QT interval : 330 msec
QTc interval : 370 msec

Raw E.C.G. (Seq)

Dr. P. K. GUPTA
Reg. No. 955-10
Reg. No. 1077

Unconfirmed Report Reviewed By:

Cardiologist



ONEPLUS ULTRASOUND LAB
47, Harsh Vihar, Pitam Pura,
Delhi-110034
Ph. 011-42180101, 9559913051
E-mail: oneplusul@gmail.com

ONEPLUS ULTRASOUND LAB

47, HARSH VIHAR PITAMPURA DELHI 110034

Ms. RANJU SINGH
 Age : 47/F
 Ref. by : MEDIWHEEL
 Indication1 :
 Indication2 :
 Indication3 :

ID : 992
 H/Wt : 151/64
 Recorded : 11-2-2023-10:20

TREADMILL TEST SUMMARY REPORT
 Protocol: BRUCE
 History:
 Medication1 :
 Medication2 :
 Medication3 :

PHASE	PHASE TIME	STAGE TIME	SPEED (Km./Hr.)	GRADE (%)	H.R. (BPM)	B.P. (mmHg)	RPP X100	II	ST LEVEL (mm) V2	V5	METS
SUPINE STANDING					78 82	124/82 124/82	96 101	-0.4 -0.3	0.2 0.1	-0.4 -0.3	
STAGE 1	2:59	2:59	2.70	10.00	104	124/82	128	-0.5	0.3	-0.3	4.80
STAGE 2	5:59	2:59	4.00	12.00	118	140/86	165	-0.7	0.2	-0.5	7.10
STAGE 3	8:59	2:59	5.40	14.00	141	150/88	211	1.0	-0.3	-0.2	10.00
STAGE 4	9:29	0:29	6.70	16.00	156	160/90	249	0.7	0.2	-1.1	10.65
PEAK EXER	9:33	0:33			159	160/90	254	-0.1	0.0	-1.3	10.74
RECOVERY	2:59	2:59	0.00	0.00	89	126/82	112	-0.6	0.3	-0.5	

RESULTS

Exercise Duration : 9:33 Minutes
 Max Heart Rate : 159 bpm 91 % of target heart rate 173 bpm
 Max Blood Pressure : 160/90 mmHg
 Max Work Load : 10.74 METS
 Reason of Termination :

IMPRESSIONS

Negative for Inducible Ischemia

[Handwritten Signature]

ONEPLUS ULTRASOUND LAB
 47, Harsh Vihar, Pitam Pura,
 Delhi-110034
 Ph. 011-42480101, 95599913051
 E-mail: oneplusul@gmail.com

Dr. P.K. GUPTA
 Cardiologist
 Reg. No. 11071

ONEPLUS ULTRASOUND LAB

Ms. RANJU SINGH
I.D. : 992

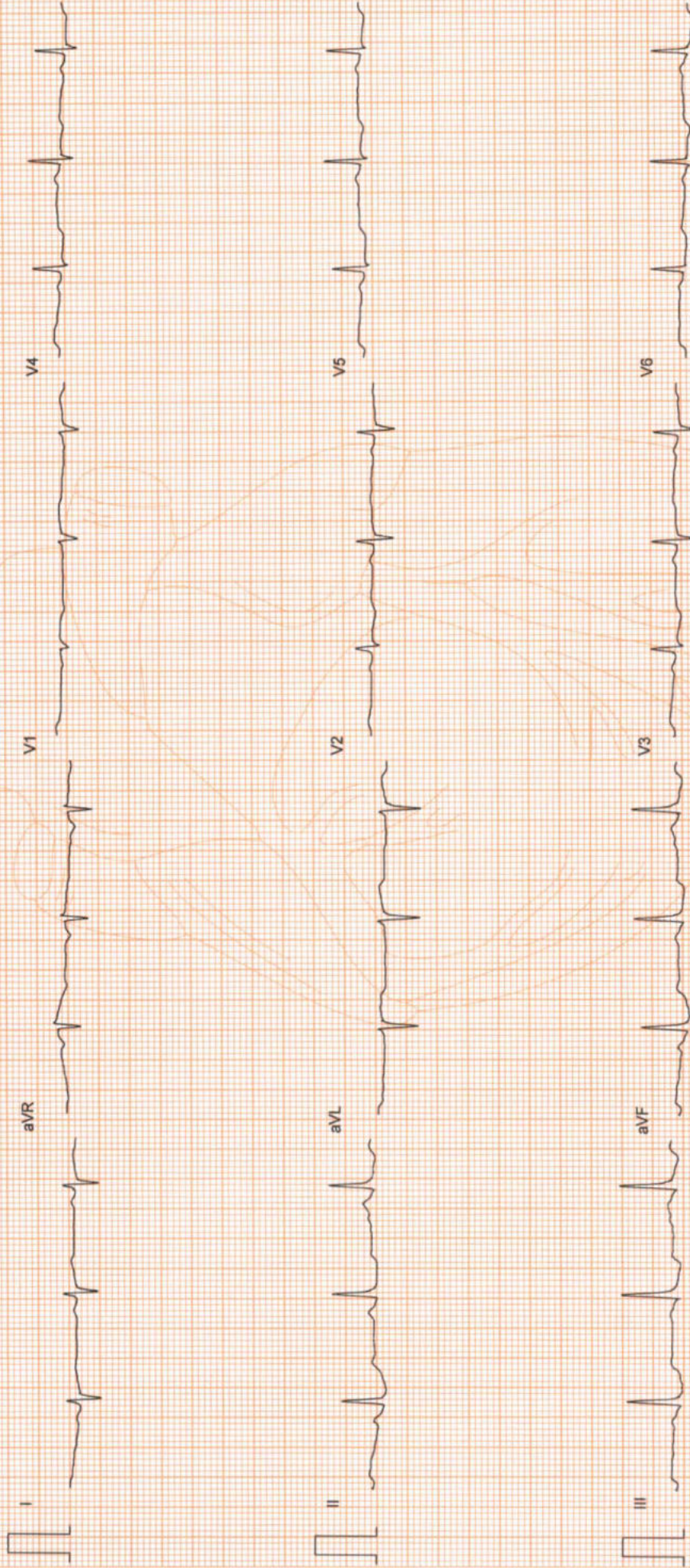
AGE/SEX : 47/F
RECORDED : 11-2-2023 10:20

RATE : 78 BPM
B.P. : 124/82 mmHg

ST @ 10mm/mV
80ms PostJ

SUPINE
PRETEST

RAW E.C.G.



ONEPLUS ULTRASOUND LAB
47, Harsh Vihar, Pitam Pura,
Delhi-110034
Ph. 011-2620740, 9599913051
E-mail: oneplusul@gmail.com

ONEPLUS ULTRASOUND LAB

Ms. RANJU SINGH
I.D. : 992

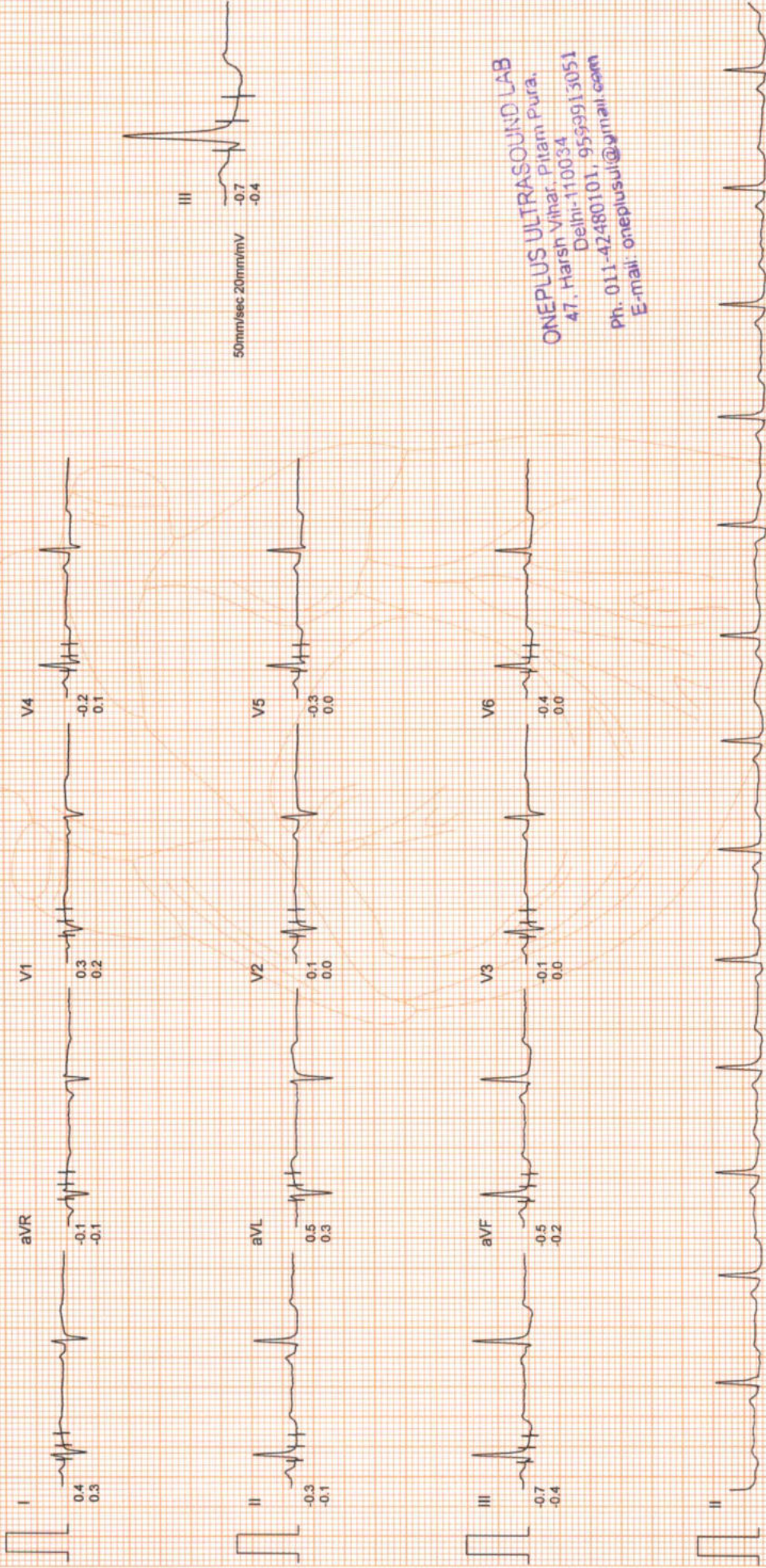
STANDING
PRETEST

ST @ 10mm/mV
80ms PostJ

AGE/SEX : 47/F
RECORDED : 11-2-2023 10:20

RATE : 82 BPM
B.P. : 124/82 mmHg

LINKED MEDIAN



50mm/sec 20mm/mV

ONEPLUS ULTRASOUND LAB
47, Harsh Vihar, Pitam Pura,
Delhi-110034
Ph. 011-42480101, 9559913051
E-mail: oneplusul@gmail.com

ONEPLUS ULTRASOUND LAB

Ms. RANJU SINGH

I.D. : 992

AGE/SEX : 47/F

RECORDED : 11-2-2023 10:20

RATE : 104 BPM

B.P. : 124/82 mmHg

BRUCE

EXERCISE 1

PHASE TIME : 2:59

STAGE TIME : 2:59

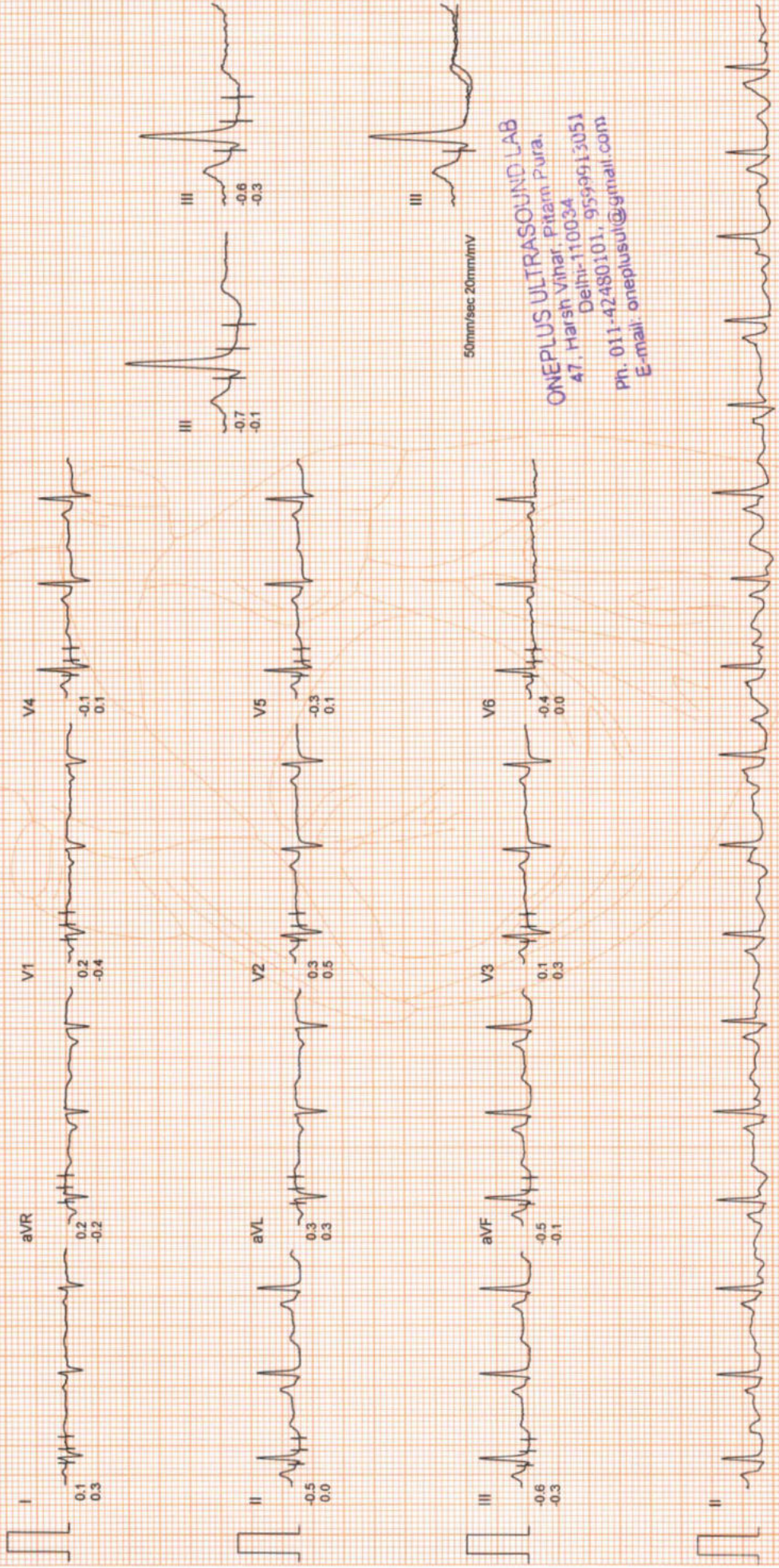
ST @ 10mm/mV

80ms PostJ

SPEED : 2.7 Km./Hr.

GRADE : 10.0 %

LINKED MEDIAN



50mm/sec 20mm/mV

ONEPLUS ULTRASOUND LAB

47, Harsh Vihar, Pitam Pura,

Delhi-110034

Ph. 011-42480101, 9599913051

E-mail: oneplusul@gmail.com

ONEPLUS ULTRASOUND LAB

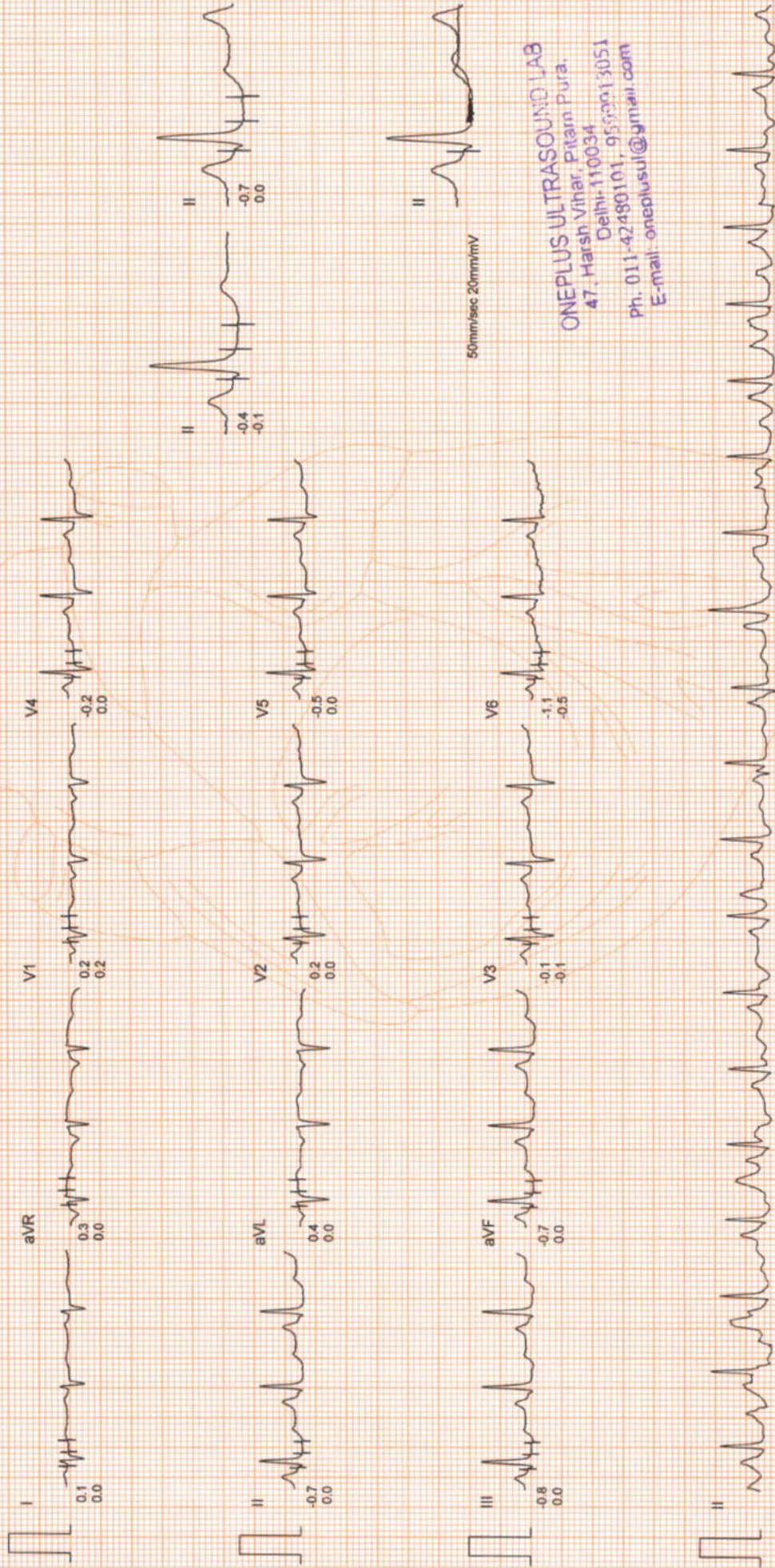
Ms. RANJU SINGH
I.D. : 992

AGE/SEX : 47/F
RECORDED : 11-2-2023 10:20

BRUCE
EXERCISE 2
PHASE TIME : 5:59
STAGE TIME : 2:59

ST @ 10mm/mV
80ms PostJ
SPEED : 4.0 Km./Hr.
GRADE : 12.0 %

LINKED MEDIAN



50mm/sec 20mm/mV

ONEPLUS ULTRASOUND LAB

47, Harsh Vihar, Pitam Pura,

Delhi-110034

Ph. 011-42480101, 9550913051

E-mail: oneplusul@gmail.com

ONEPLUS ULTRASOUND LAB

Ms. RANJU SINGH

I.D. : 992

AGE/SEX : 47/F

RECORDED : 11-2-2023 10:20

RATE : 141 BPM

B.P. : 150/88 mmHg

ST @ 10mm/mV

80ms PostJ

SPEED : 5.4 Km./Hr.

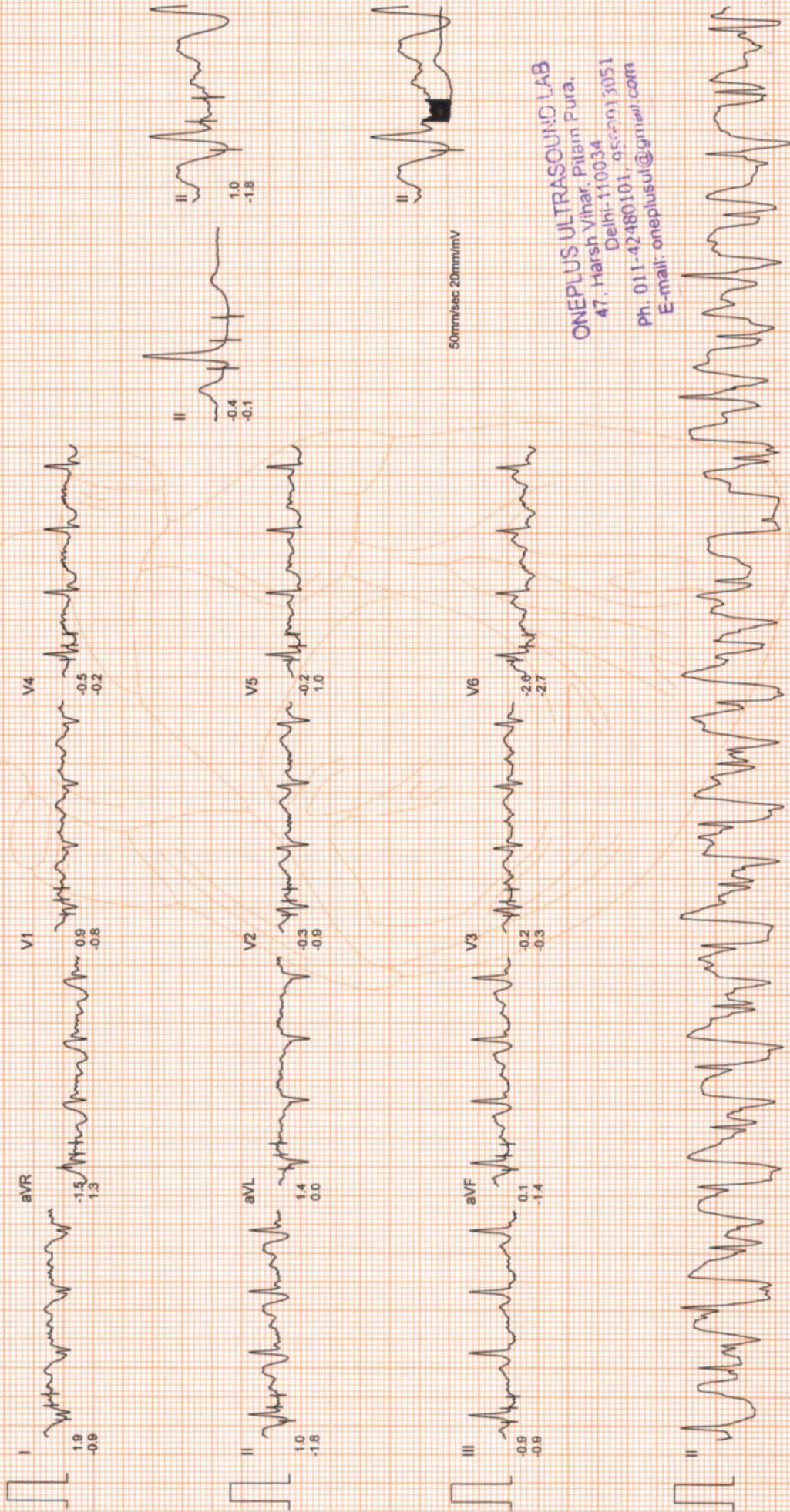
GRADE : 14.0 %

LINKED MEDIAN

BRUCE
EXERCISE 3

PHASE TIME : 8:59

STAGE TIME : 2:59



50mm/sec 20mm/mV

ONEPLUS ULTRASOUND LAB

47, Harsh Vihar, Pitam Pura,

Delhi-110034

Ph. 011-42480101, 9550013051

E-mail: oneplusul@gmail.com

ONEPLUS ULTRASOUND LAB

Ms. RANJU SINGH

I.D. : 992

AGE/SEX : 47/F

RECORDED : 11-2-2023 10:20

RATE : 156 BPM

B.P. : 160/90 mmHg

BRUCE

EXERCISE 4

PHASE TIME : 9:29

STAGE TIME : 0:29

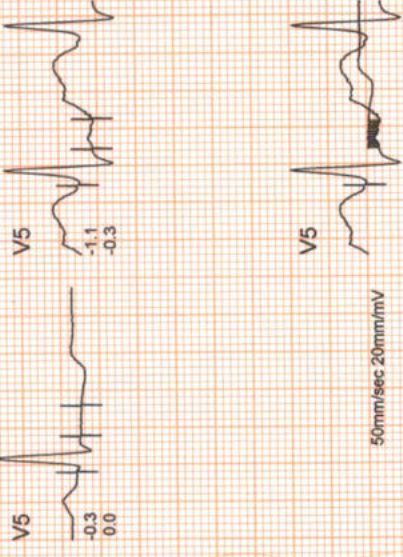
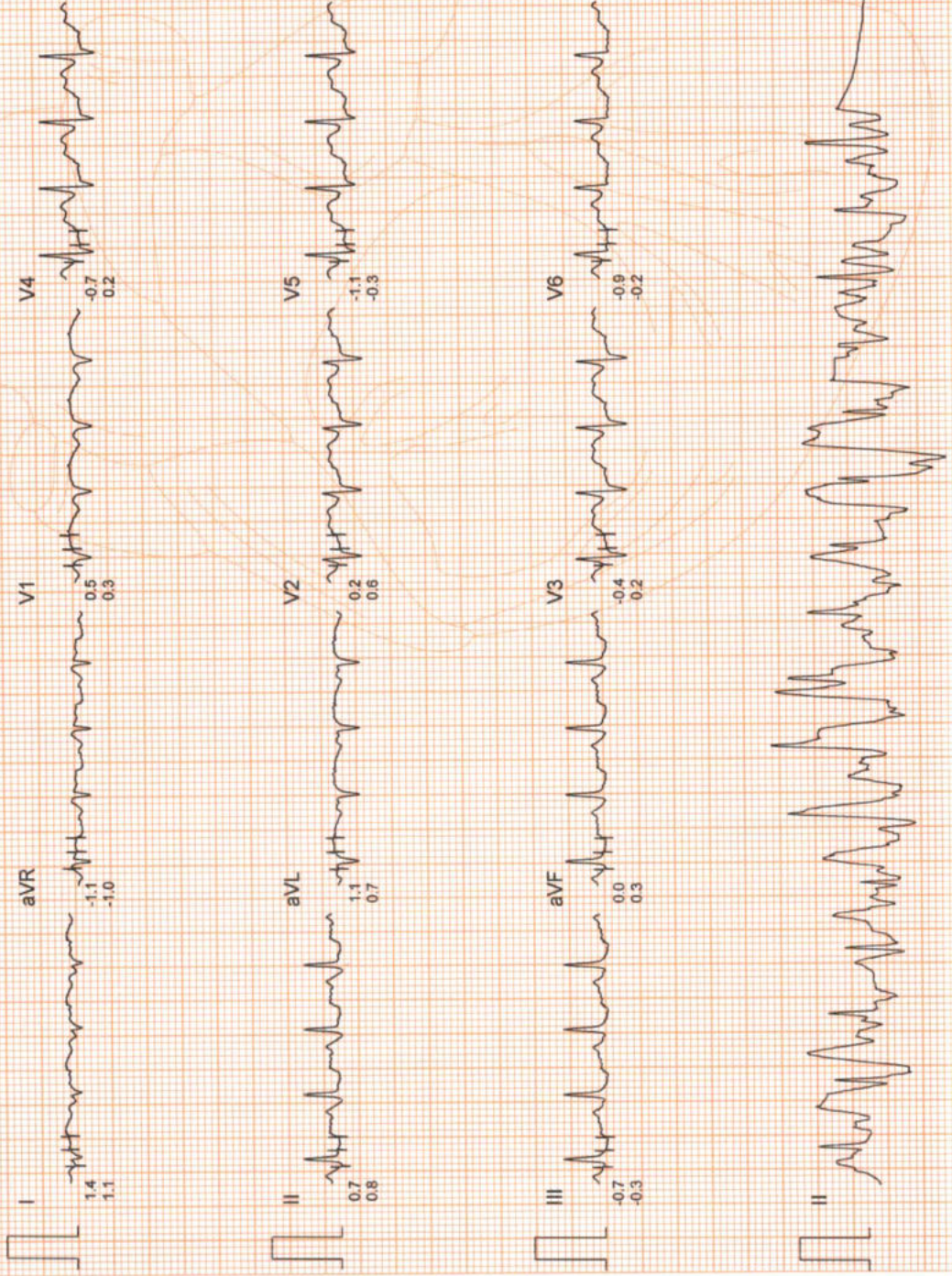
ST @ 10mm/mV

80ms PostJ

SPEED : 6.7 Km/Hr.

GRADE : 16.0 %

LINKED MEDIAN



ONEPLUS ULTRASOUND LAB
47, Harsh Vihar, Pitam Pura,
Delhi-110034
Ph. 011-4377101, 9559913051
E-mail: oneplusul@gmail.com

ONEPLUS ULTRASOUND LAB

Ms. RANJU SINGH
I.D. : 992

BRUCE
PEAK EXER

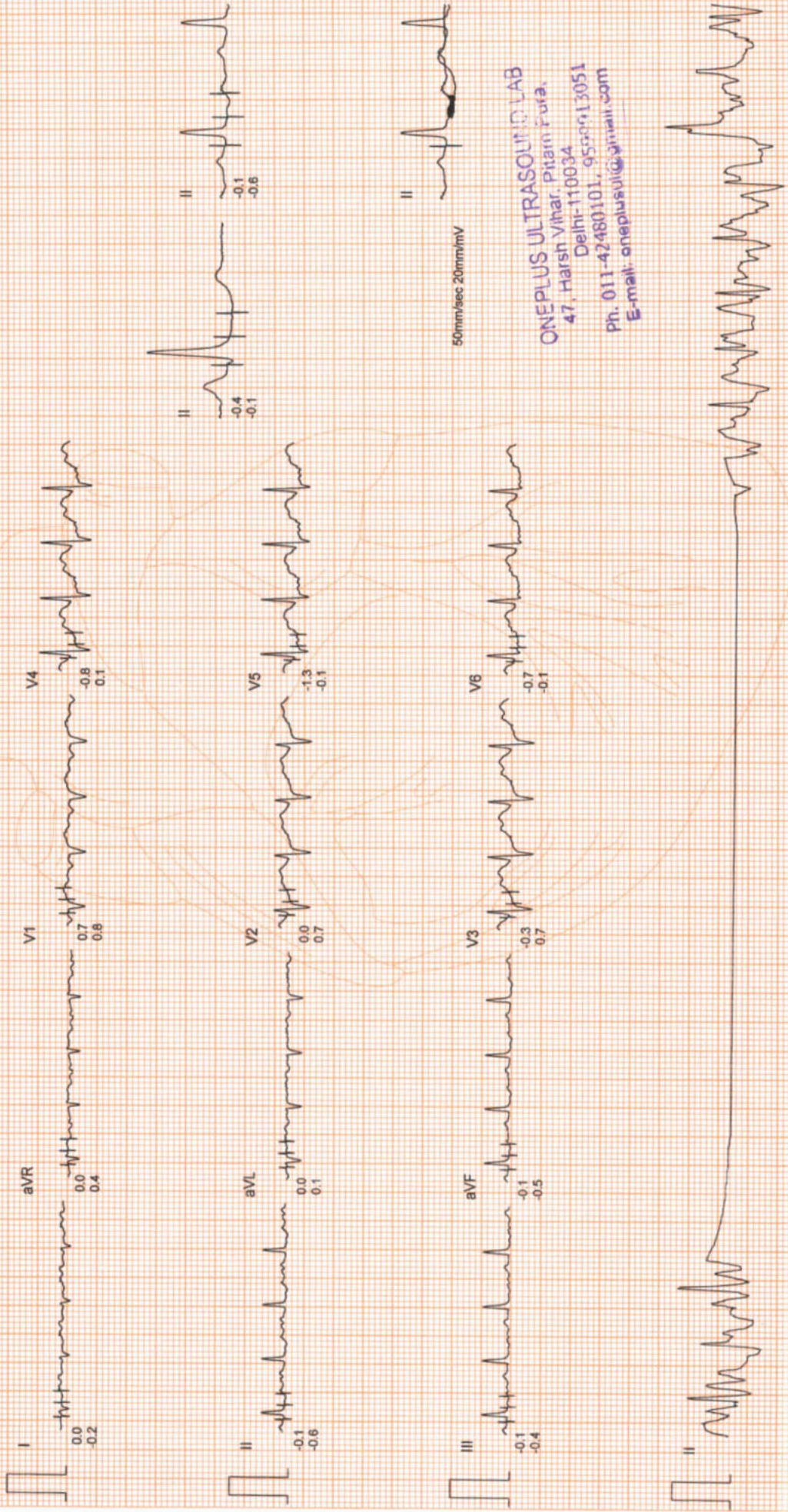
ST @ 10mm/mV
80ms PostJ

AGE/SEX : 47/F
RECORDED : 11-2-2023 10:20
RATE : 159 BPM
B.P. : 160/90 mmHg

PHASE TIME : 9:33
STAGE TIME : 0:33

SPEED : 6.7 Km./Hr.
GRADE : 16.0 %

LINKED MEDIAN



ONEPLUS ULTRASOUND LAB
47, Harsh Vihar, Pitam Fata,
Delhi-110034
Ph. 011-42480101, 9550913051
E-mail: oneplusul@gmail.com

ONEPLUS ULTRASOUND LAB

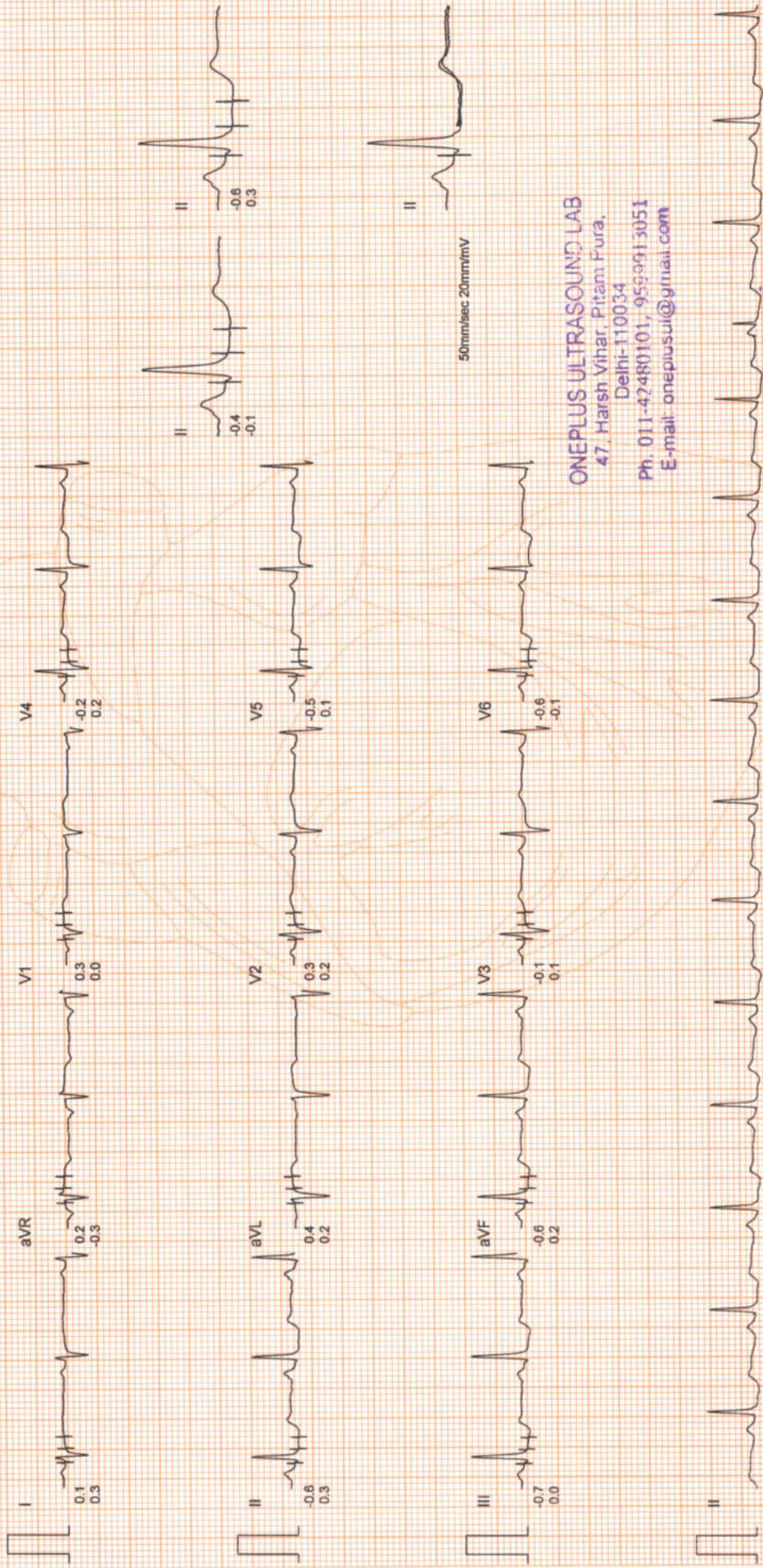
Ms. RANJU SINGH
I.D. : 992

AGE/SEX : 47/F
RECORDED : 11-2-2023 10:20

BRUCE
RECOVERY
PHASE TIME : 2:59

ST @ 10mm/mV
80ms PostJ
SPEED : 0.0 Km./Hr.
GRADE : 0.0 %

LINKED MEDIAN



ONEPLUS ULTRASOUND LAB
47, Harsh Vihar, Pitam Fura,
Delhi-110034
Ph. 011-42480101, 9559913051
E-mail: oneplusul@gmail.com

ONEPLUS ULTRASOUND LAB

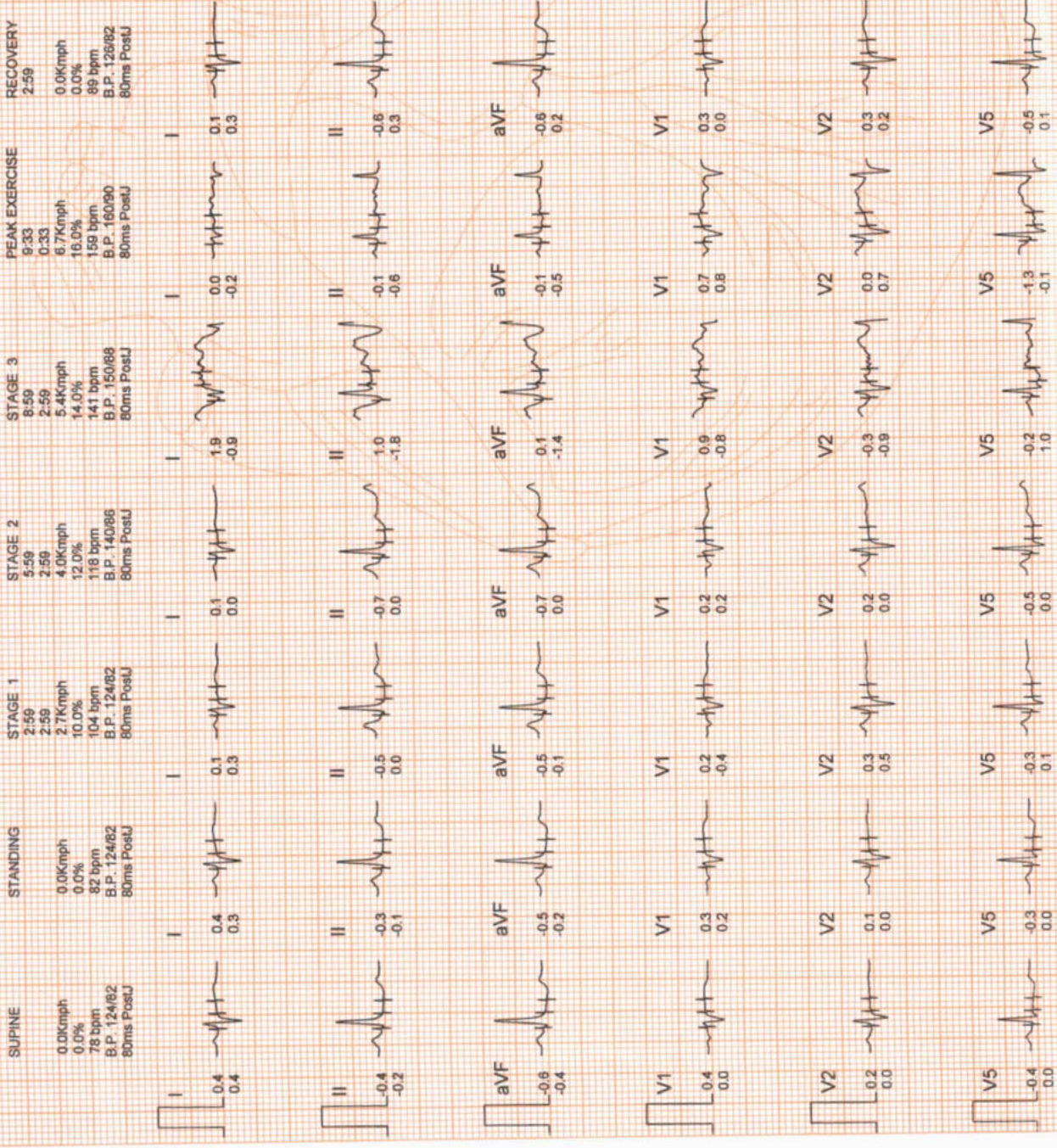
Ms. RANJU SINGH

I.D. : 992

AGE/SEX : 47/F

RECORDED : 11-2-2023 10:20

AVG E.C.G.



ONEPLUS ULTRASOUND LAB
 47, Harsh Vihar, Pitam Pura,
 Delhi-110034
 Ph. 011-47480101, 9599913051
 E-mail: onepiusound@gmail.com /

ONEPLUS ULTRASOUND LAB

Ms RANJU SINGH

I.D. : 992

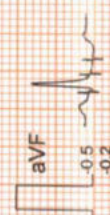

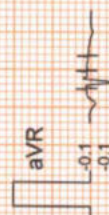


AGE/SEX : 47/F

RECORDED : 11-2-2023 10:20

COMPARISON REPORT

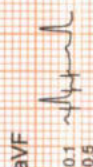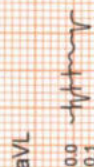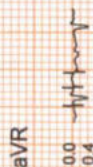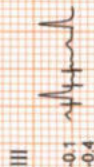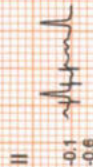STANDING

0.0Kmph
0.0%
82 bpm
B.P. 124/82
80ms PostJ



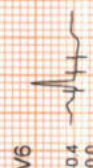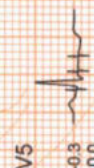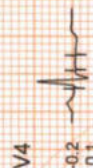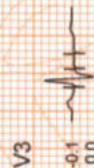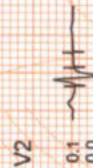
PEAK EXERCISE

9.33
0.33
6.7Kmph
16.0%
159 bpm
B.P. 160/90
80ms PostJ



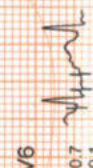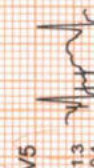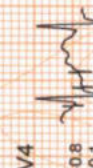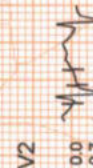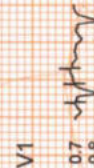STANDING

0.0Kmph
0.0%
82 bpm
B.P. 124/82
80ms PostJ



PEAK EXERCISE

9.33
0.33
6.7Kmph
16.0%
159 bpm
B.P. 160/90
80ms PostJ



ONEPLUS ULTRASOUND LAB
47, Harsh Vihar, Pitam Pura,
Delhi-110034
Ph. 011-47480101, 9559913051
E-mail: oneplusultrasound@gmail.com



OnePLUS Ultrasound Lab

— QUALITY FIRST... ALWAYS! —

Dr. Nitin Agarwal
Pathologist & Director
Ex. Sr. Res. MAMC
& Lok Nayak Hospital
Ex. Chief of Lab Dr. Lal Path Labs.

Dr. Pooja (Garg) Agarwal
Radiologist & Director
MAMC & Lok Nayak Hospital



NAME	:Mrs. RANJU SINGH	Barcode No	:10137656
AGE/GENDER	:47 YRS/Female	SPECIMEN DATE	:11/Feb/2023 09:16AM
PATIENT ID	:109046	SPECIMEN RECEIVED	:11/Feb/2023 12:40PM
REFERRED BY	:Dr. MEDIWHEEL	REPORT DATE	:11/Feb/2023 02:11PM
CENTRE NAME	:ONEPLUS ULTRASOUND LAB	LAB NO.	:012302110013

Test Name	Result	Unit	Ref. Range
-----------	--------	------	------------

HAEMATOLOGY

Medi Wheel Health checkup < 40 Female

Glycosylated Hemoglobin (HbA1c)	4.6	%	Non Diabetic adults <5.7 Prediabetic (at risk) 5.7-6.4 Diabetes >6.4
--	-----	---	--

Estimated average blood glucose (eag) 85

Reference range (mg/dl):

90 - 120:Excellent control, 121 - 150:Good Control, 151 - 180:Average Control, 181 - 210:Action Suggested

>211:Panic value

BLOOD GROUP (ABO)	B
Rh typing	POSITIVE

NOTE :

- * Apart from major A,B,H antigens which are used for ABO grouping and Rh typing, many minor blood group antigens exist. Agglutination may also vary according to titre of antigen and antibody.
- * So before transfusion, reconfirmation of blood group as well as cross-matching is needed.
- * Presence of maternal antibodies in newborns, may interfere with blood grouping.
- * Auto agglutination (due to cold antibody, falciparum malaria, sepsis, internal malignancy etc.) may also cause erroneous result.

CBC

Haemoglobin	11.2	g/dl	11.5-15.0
Total Leucocyte Count	6800	/cumm	4000-10000
Differential leucocyte count			
Neutrophils	63.3	%	40-80
Lymphocyte	30.10	%	20-40
Monocytes	3.60	%	2-10
Eosinophils	2.5	%	1-6
Basophils	0.5	%	0-2
RBC Count	4.30	million/cumm	3.8-4.8

Checked By.

DR. NITIN AGARWAL
MBBS,MD(PATHOLOGIST)

47, Harsh Vihar, Pitampura, New Delhi-110034 | Ph.: 011-42480101, 9599913051

E-mail: onepusul@gmail.com | Web.: www.onepusul.in

Page 1 of 5



OnePLUS Ultrasound Lab

— QUALITY FIRST... ALWAYS! —

Dr. Nitin Agarwal
Pathologist & Director
Ex. Sr. Res. MAMC
& Lok Nayak Hospital
Ex. Chief of Lab Dr. Lal Path Labs.

Dr. Pooja (Garg) Agarwal
Radiologist & Director
MAMC & Lok Nayak Hospital



NAME	:Mrs. RANJU SINGH	Barcode No	:10137656
AGE/GENDER	:47 YRS/Female	SPECIMEN DATE	:11/Feb/2023 09:16AM
PATIENT ID	:109046	SPECIMEN RECEIVED	:11/Feb/2023 12:40PM
REFERRED BY	:Dr. MEDIWHEEL	REPORT DATE	:11/Feb/2023 02:11PM
CENTRE NAME	:ONEPLUS ULTRASOUND LAB	LAB NO.	:012302110013

Test Name	Result	Unit	Ref. Range
PCV(Hematocrit)	38.8	%	36-46
MCV	89.7	fL	83-101
MCH	25.9	Pg	27-32
MCHC	28.9	G/dL	32-35
Platelet count	292000	/cumm	150000-450000
RDW-CV	13.4	%	11.4-14.0
ESR(WESTGRENs METHOD)	10	mm/1hr	<20

BIOCHEMISTRY

<u>Bun (blood urea nitrogen)</u>	12.20	mg/dl	7-18.7
<u>Uric acid, serum</u>	4.6	mg/dl	2.6-6.0
<u>BLOOD SUGAR RANDOM</u>	83	mg/dL	<140 Normal 140-199 Pre Diabetes >200 Diabetes

Comments :-

- Random blood sugar measures the glucose levels regardless of the last meal/intake.
- Random testing is useful because glucose levels in healthy individuals do not vary widely throughout the day.
- A random blood sugar - > / = 200 mg/ dL denotes diabetes- > / = 140 but < 199 mg/ dL suggest fasting blood glucose levels and Post Prandial blood glucose levels to be done.

<u>Creatinine, serum</u>	0.72	mg/dl	0.50-1.0
--------------------------	------	-------	----------

LFT(LIVER FUNCTION TEST)

Bilirubin Total	0.48	mg/dl	0.1-1.2
Bilirubin Conjugated	0.14	mg/dl	0-0.4
Bilirubin Unconjugated	0.34	mg/dl	up to 0.7
SGOT (AST)	27	U/L	0-46
SGPT (ALT)	11	U/L	0-49
Alkaline phosphatase	98	U/L	35-104
Gamma glutamyl transpeptidase	24	U/L	5.0-32.0
Total Protein	7.0	gm/dl	6.60 - 8.70
Albumin serum	4.0	g/dL	3.0-5.2
Globulin	3.00	gm/dl	1.8-3.4

Checked By.

DR. NITIN AGARWAL
MBBS,MD(PATHOLOGIST)

47, Harsh Vihar, Pitampura, New Delhi-110034 | Ph.: 011-42480101, 9599913051

E-mail: oneplusul@gmail.com | Web.: www.oneplusul.in

Page 2 of 5

*** End Of Report ***



OnePLUS
Ultrasound Lab

QUALITY FIRST... ALWAYS!

Dr. Nitin Agarwal

Pathologist & Director
Ex. Sr. Res. MAMC
& Lok Nayak Hospital
Ex. Chief of Lab Dr. Lal Path Labs.

Dr. Pooja (Garg) Agarwal

Radiologist & Director
MAMC & Lok Nayak Hospital



NAME	:Mrs. RANJU SINGH	Barcode No	:10137656
AGE/GENDER	:47 YRS/Female	SPECIMEN DATE	:11/Feb/2023 09:16AM
PATIENT ID	:109046	SPECIMEN RECEIVED	:11/Feb/2023 12:40PM
REFERRED BY	:Dr. MEDIWHEEL	REPORT DATE	:11/Feb/2023 02:11PM
CENTRE NAME	:ONEPLUS ULTRASOUND LAB	LAB NO.	:012302110013

Test Name	Result	Unit	Ref. Range
Albumin/Globulin Ratio	1.33		1.10 - 2.50

LIPID PROFILE

Cholesterol	226	mg/dl	50-200
Triglycerides	146	mg/dL	25-150
HDL Cholesterol	48	mg/dL	40 - 60
LDL cholesterol	149	mg/dL	< 130
VLDL cholesterol	29.2	mg/dL	5-40
Cholesterol/HDL Ratio	4.7		Low Risk 3.3-4.97 Average Risk 4.4-7.1 Moderate Risk 7.1-11.0 High Risk >11.0
LDL/HDL Ratio	3.1		0 - 3.55

According to ATP III and NCEP guidelines

Parameter	Normal	Desirable	Borderline	High
Total cholesterol	<200		200-239	240
Triglycerides	<150	150-199	200-499	500
LDL	Optimal <100 Near Optimal 100-129	130-159	160-180	190
HDL	<40 : LOW 60 : HIGH			

BUN/Creatinine ratio

Bun (blood urea nitrogen)	12.20	mg/dl	7-18.7
CREATININE	0.72	mg/dl	0.30-1.10
BUN/Creatinine ratio	16.94		10.0 - 20.0

ENDOCRINOLOGY

THYROID PROFILE(T3,T4,TSH)

Checked By.

DR. NITIN AGARWAL
MBBS,MD(PATHOLOGIST)

47, Harsh Vihar, Pitampura, New Delhi-110034 | Ph.: 011-42480101, 9599913051

E-mail: oneplusul@gmail.com | Web.: www.oneplusul.in

Page 1 of 5

Clinical correlation is essential for final diagnosis. • If test results are unsatisfactory please contact personally or on phone. • This report is for perusal of doctors only. • All disputes Subject to Delhi Jurisdiction only. • Not for medicolegal purposes. • All congenital anomalies in a foetus may not be diagnosed in routine obstetric ultrasound.



OnePLUS Ultrasound Lab

— QUALITY FIRST... ALWAYS! —

Dr. Nitin Agarwal
Pathologist & Director
Ex. Sr. Res. MAMC
& Lok Nayak Hospital
Ex. Chief of Lab Dr. Lal Path Labs.

Dr. Pooja (Garg) Agarwal
Radiologist & Director
MAMC & Lok Nayak Hospital



NAME	:Mrs. RANJU SINGH	Barcode No	:10137656
AGE/GENDER	:47 YRS/Female	SPECIMEN DATE	:11/Feb/2023 09:16AM
PATIENT ID	:109046	SPECIMEN RECEIVED	:11/Feb/2023 12:40PM
REFERRED BY	:Dr. MEDIWHEEL	REPORT DATE	:11/Feb/2023 02:11PM
CENTRE NAME	:ONEPLUS ULTRASOUND LAB	LAB NO.	:012302110013

Test Name	Result	Unit	Ref. Range
Triiodothyronine total [t3]	0.64	ng/dl	0.52-1.9
Thyroxine total [t4]	7.20	µg/dl	4.8-11.6
TSH (Thyroid Stimulating Hormone)	4.77	µIU/ml	0.25-5.0

AGE WISE VARIATION IN TSH

AGE	TSH(µIU/ml)	AGE	TSH(µIU/ml)
1-4 weeks	1.00 - 19.0	16-20 yrs	0.25 - 5.0
1-12 mths	1.70 - 9.1	21 - 80 yrs	0.25 - 5.0
1-5 yrs	0.80 - 8.2	I st trimester	0.25 - 5.0
6-10 yrs	0.25 - 5.0	II nd trimester	0.50 - 5.0
11-15 yrs	0.25 - 5.0	III rd trimester	0.4 - 6.0

Reference ranges - Interpretation of Diagnostic tests - (Jacques Wallach)

1. Primary hypothyroidism is accompanied by depressed serum T3 and T4 values and elevated serum TSH level.
2. Primary hyperthyroidism is accompanied by elevated serum T3 and T4 levels along with depressed TSH values.
3. Slightly elevated T3 levels may be found in pregnancy and estrogen therapy, while depressed levels may be encountered in severe illness, renal failure and during therapy with drugs like propranolol and propyl thiouracil.
4. Although elevated TSH levels are nearly always indicative of primary hypothyroidism, and may be seen in secondary thyrotoxicosis

CLINICAL PATHOLOGY

URINE ROUTINE

Physical examination

Quantity	20	ML
Colour	PALE YELLOW	
Transparency	SLIGHTLY TURBID	CLEAR
Sp.gravity	1.015	1.010-1.030
pH	6.00	
Reaction	ACIDIC	ACIDIC

Chemical examination

Urine protein	NIL	NIL
Urine sugar	NIL	NIL

Checked By.

DR. NITIN AGARWAL
MBBS,MD(PATHOLOGIST)

47, Harsh Vihar, Pitampura, New Delhi-110034 | Ph.: 011-42480101, 9599913051

E-mail: oneplusul@gmail.com | Web.: www.oneplusul.in

Page 4 of 5

Clinical correlation is essential for final diagnosis. • If test results are unsatisfactory please contact personally or on phone. • This report is for perusal of doctors only. • All disputes Subject to Delhi Jurisdiction only. • Not for medicolegal purposes. • All congenital anomalies in a foetus may not be diagnosed in routine obstetric ultrasound.



OnePLUS Ultrasound Lab

QUALITY FIRST... ALWAYS!

Dr. Nitin Agarwal
Pathologist & Director
Ex. Sr. Res. MAMC
& Lok Nayak Hospital
Ex. Chief of Lab Dr. Lal Path Labs.

Dr. Pooja (Garg) Agarwal
Radiologist & Director
MAMC & Lok Nayak Hospital



NAME	:Mrs. RANJU SINGH	Barcode No	:10137656
AGE/GENDER	:47 YRS/Female	SPECIMEN DATE	:11/Feb/2023 09:16AM
PATIENT ID	:109046	SPECIMEN RECEIVED	:11/Feb/2023 12:40PM
REFERRED BY	:Dr. MEDIWHEEL	REPORT DATE	:11/Feb/2023 02:11PM
CENTRE NAME	:ONEPLUS ULTRASOUND LAB	LAB NO.	:012302110013

Test Name	Result	Unit	Ref. Range
Bilirubin, urine	NEGATIVE		NEGATIVE
Urobilinogen	NORMAL		NORMAL
Ketones	NEGATIVE		NEGATIVE
Microscopic examination			
Pus cells.	3-5	/HPF	1-2
Epithelial cells	4-6	/HPF	0-5
R.B.C.	NIL	/HPF	NIL
Casts	NIL	/HPF	NIL
Crystals	NIL	/HPF	NIL
Bacteria	NIL	/HPF	NIL
Others.	NIL		NIL

*** End Of Report ***

Checked By.

DR. NITIN AGARWAL
MBBS,MD(PATHOLOGIST)

47, Harsh Vihar, Pitampura, New Delhi-110034 | Ph.: 011-42480101, 9599913051
E-mail: oneplusul@gmail.com | Web.: www.oneplusul.in

Page 5 of 5


Clinical correlation is essential for final diagnosis. • If test results are unsatisfactory please contact personally or on phone. • This report is for perusal of doctors only.
• All disputes Subject to Delhi Jurisdiction only. • Not for medicolegal purposes. • All congenital anomalies in a foetus may not be diagnosed in routine obstetric ultrasound.

Name	: Mrs. RANJU SINGH	Age/Sex	: 47 YRS/Female
Ref. By	: Dr. MEDIWHEEL	Lab No	: 012302110013
Date	: 11-Feb-2023	Patient ID	: LSHHI109046

X-ray-Chest PA view

Bony cage and soft tissues are normal.
Cardiothoracic ratio is normal.
Mediastinum is normal.
Both hila are normal.
Both costophrenic angles are clear.
Both domes of diaphragm are normal.
Lung fields are clear. No parenchymal lesion seen.

IMPRESSION: Normal Study.

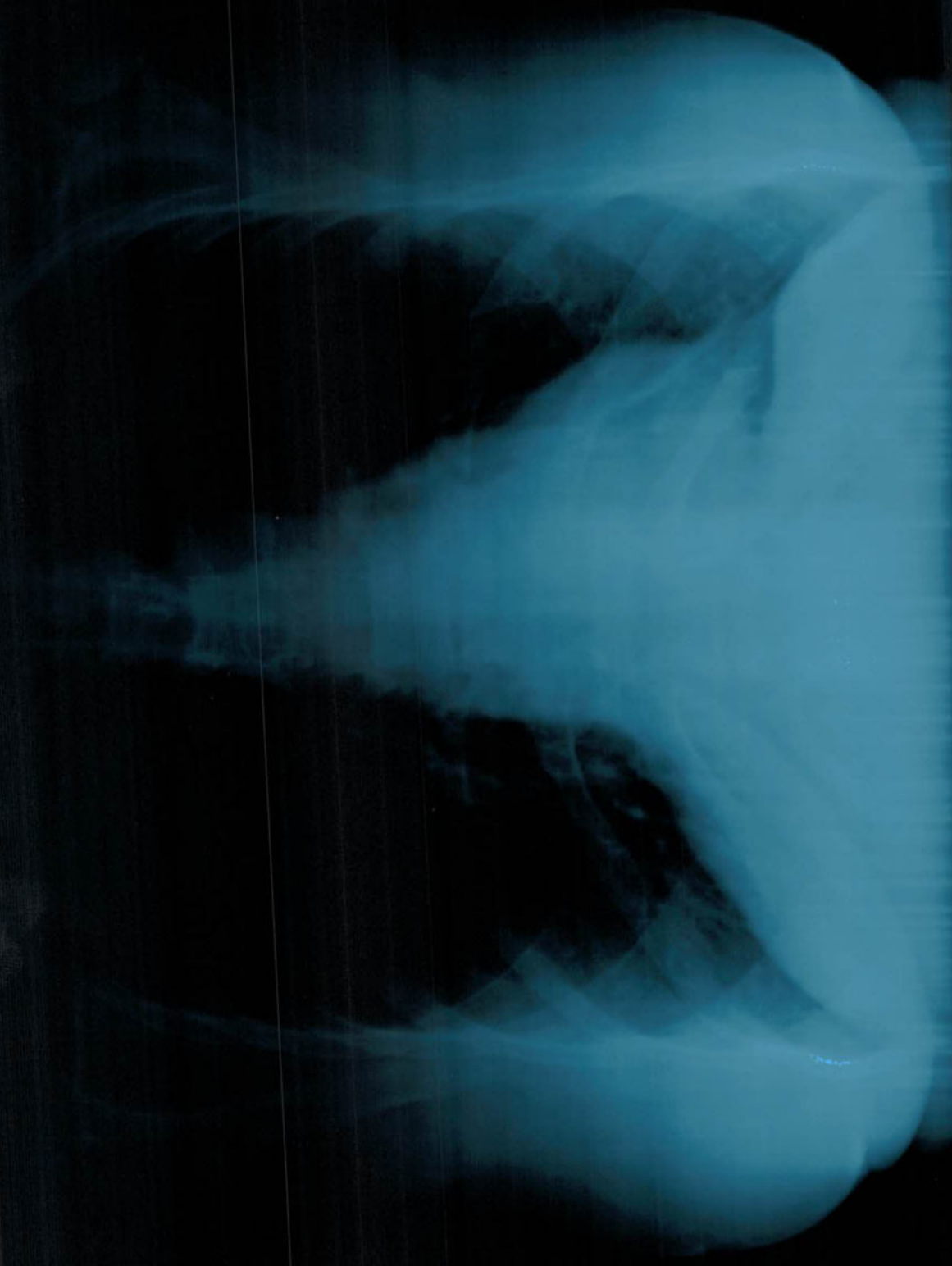


DR. POOJA GARG
RADIOLOGIST
REG NO- DMC/R/03398

Type By : kusum

47, Harsh Vihar, Pitampura, New Delhi-110034 | Ph.: 011-42480101, 9599913051

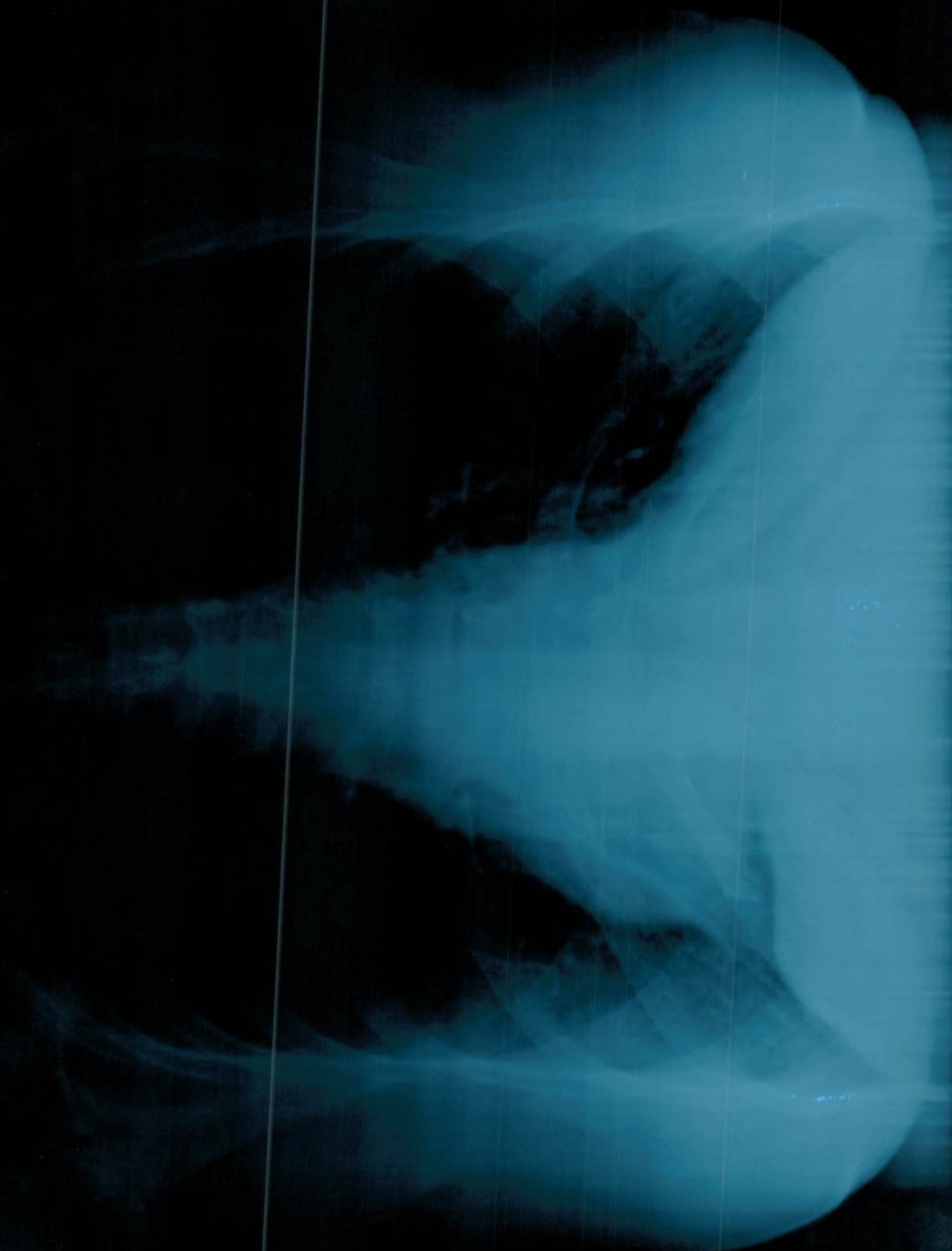
E-mail: oneplusul@gmail.com | Web.: www.oneplusul.in



MRS RANJU SINGH 47 YRS 11/2/2023 F CHEST PA VIEW 2/11/2023

ONEPLUS UL TRASOUND LAB 47 HARSH VIHAR PITAMPURA

DIEPLUS ULTRASOUND LAB 42 HARSH VIHAR PITAMPURA
MRS RANJU SINGH 42 YRS 11/5/2023 F CHEST PA VIEW 21/1/2023





OnePLUS
Ultrasound Lab
— QUALITY FIRST... ALWAYS! —

Dr. Nitin Agarwal
Pathologist & Director
Ex. Sr. Res. MAMC
& Lok Nayak Hospital
Ex. Chief of Lab Dr. Lal Path Labs.

Dr. Pooja (Garg) Agarwal
Radiologist & Director
MAMC & Lok Nayak Hospital

Name	: Mrs. RANJU SINGH	Age/Sex	: 47 YRS/Female
Ref. By	: Dr. MEDIWHEEL	Lab No	: 012302110013
Date	: 11-Feb-2023	Patient ID	: LSHHI109046

ULTRASOUND EXAMINATION----WHOLE ABDOMEN

Liver is normal in size and outline with normal echopattern. No abscess or mass lesion seen. Hepatic veins, portal vein, IVC and aorta are normal. Intrahepatic biliary radicles are not dilated. CBD is normal in caliber .

Gall bladder is well distended with anechoic lumen .Wall thickness is normal.

Both **kidneys** are normal in size, shape, position, outline and echopattern.. Corticomedullary differentiation is maintained. No pelvicalyceal dilation or calculus or mass lesion is seen.

Spleen is normal in size and echotexture. No mass lesion seen.

Pancreas is normal in size, outline and echotexture .

Urinary bladder is normal in shape and position. No evidence of intravesical stone or mass seen.


Uterus is post menopausal small in size, normal in shape, position and echopattern. No mass seen.

Uterine cavity is empty. **Endometrium** is thin and central and measures 2.5 mm.

No adnexal mass lesion seen.

No abnormal bowel wall thickening seen in right iliac fossa.
No mass or free fluid seen anywhere in abdomen.

IMPRESSION: Normal study.


DR. POOJA GARG
RADIOLOGIST
REG NO- DMC/R/03398

Type By : kusum

47, Harsh Vihar, Pitampura, New Delhi-110034 | Ph.: 011-42480101, 9599913051
E-mail: oneplusul@gmail.com | Web.: www.oneplusul.in

