



Name : Mr. KALYAN HONAJI GAVLI (55 Yr) www.askapollo.com

Date : 27/08/2022

Address : AMBEDKAR NAGAR OZAR TOWNSHIP GANH PATI MANDIR OJHAR NASHIK,
NASHIK, NASHIK, MAHARASHTRA, INDIA

Examined by:

UHID : MHN1.0000124754

Package : MediWheel Full Body Health Checkup Male Above 40

AHC No : NSKAH27436



CHIEF COMPLAINTS

For corporate health checkup

No specific complaints

HTN
Diabetes



DRUG ALLERGY

NO KNOWN ALLERGY

:27/08/2022



SYSTEMIC REVIEW

Cardiovascular system

- Nil Significant



Past medical history

Do you have any allergies? - No

Do you have any drug allergies? - No

Past medical history - nil significant

Covid 19 - No



Surgical history

Surgical history - Nil



Personal history

Marital status - Married

No. of children - 02

Diet - Mixed Diet

Alcohol - does not consume alcohol

Smoking - No

Chews tobacco - Yes

Chews paan - No

Uses snuff - No

Illicit substance use - No

Physical activity - Active



Family history

Father - alive

Aged - 80 yrs

Mother - alive

Aged - 80 yrs

Brothers - 5

Sisters - 2

Coronary artery disease - none

Cancer - brother

PHYSICAL EXAMINATION



General

General appearance - normal

Build - normal

Height - 160

Weight - 64.7

BMI - 25.27

Pallor - No

Oedema - no

Temperature - 95.1

SpO2 - 98



Cardiovascular system

Heart rate (Per minute) - 64

Rhythm - Regular

- B.P. Supine

Systolic(mm of Hg) - 130

Diastolic(mm of Hg) - 80

Heart sounds - S1S2+

Respiratory system

Swaminarayan Nagar, Off Mumbai-Agra Highway,
Panchvati, Nashik - 422 003.

+91 - 253 - 2510250 / 350 / 450 / 550 / 750

apollonashik@apollohospitals.com

www.askapollo.com

QFAHN/BILL/003/V1



Name : Mr. KALYAN HONAJI GAVLI (55 /M)


UHID : MHN1.0000124754

Date : 27/08/2022

Package : MediWheel Full Body Health Checkup Male Above 40

AHC No : NSKAH27436

Breath sounds - Normal vesicular breath sounds

 **Abdomen**

Organomegaly - No
Tenderness - No



Printed By : Shweta Sharad Shardul



Name : Mr. KALYAN HONAJI GAVLI (55 /M)

UHID : MHN1.0000124754

Date : 27/08/2022

Package : MediWheel Full Body Health Checkup Male Above 40

AHC No : NSKAH27436

URINE ROUTINE (CUE)

Test Name	Result	Unit	Level	Range
Specific Gravity	1.020		●	1.016-1.026
Color,:	PALE YELLOW			
Transparency:	Clear			
Reaction:	Acidic			7.2-7.8
Protein :	Nil			
Sugar:	2+			
pH	5.0		●	4.6-8
Blood:	Negative			
Ketone	Negative			
Pigments:	Negative			
Bile Salts :	Negative			
Urobilinogen	Normal			
Nitrite	Negative			
RBC	0	/hpf	●	0-2
WBC/Pus Cells	0-2/hpf	/hpf		
Tc/Sqc(Transitional/Squamous epithelial cells)	2-3/hpf	/hpf		

Eosinophils	03	%	●	1-6
Monocytes	03	%	●	1-10
Basophils	00	%	●	0-1
ERYTHROCYTE SEDIMENTATION RATE (ESR)	11 *	mm/1st hr	●	0-10

BLOOD GROUPING AND TYPING (ABO and Rh)

Test Name	Result	Unit	Level	Range
ABO Group:	O			
Rh (D) Type:	POSITIVE			

LIVER FUNCTION TEST (PACKAGE)

Test Name	Result	Unit	Level	Range
ALT(SGPT) - SERUM / PLASMA	19 *	U/L	●	30-65
ALBUMIN - SERUM	4.7	g/dL	●	3.5-5
GLOBULIN - SERUM: (Calculated)	3.9 *	g/dL	●	1.8-3.6
ALBUMIN:GLOBULIN - SERUM(RATIO) (Calculated)	1.2		●	1.1-1.8
ALKALINE PHOSPHATASE - SERUM/PLASMA	71	U/L	●	0-100
AST (SGOT) - SERUM	15	U/L	●	15-37
BILIRUBIN, TOTAL - SERUM	0.2	mg/dL	●	0.0-1.0

C B C WITH ESR (AUTOMATION + STANDARD METHOD)

Test Name	Result	Unit	Level	Range
Hemoglobin	14.8	g/dl	●	13.0-18.0
Haematocrit	46	%	●	39.0-54.0
RBC COUNT	6	Million/ul	●	4.2-6.5
MCV	77.3	fl	●	75.0-95.0
MCH	24.9 *	pg	●	26.0-32.0
MCHC	32.2	g/dl	●	31.0-36.0
RDW	22 *	%	●	11-16
Platelet Count(Optical/Impedance)	276	10 ³ /m ³	●	140-440
TLC Count	7.6	10 ³ /m ³	●	4.0-11.0
Neutrophils	58	%	●	45-75
Lymphocytes	36	%	●	20-45

LIPID PROFILE TEST (PACKAGE)

Test Name	Result	Unit	Level	Range
Total Cholesterol	259 *	mg/dL	●	0-200

CREATININE - SERUM / PLASMA

Test Name	Result	Unit	Level	Range
CREATININE - SERUM / PLASMA	0.8	mg/dL	●	0.8-1.3

LIVER FUNCTION TEST (PACKAGE)

Test Name	Result	Unit	Level	Range
GGTP: GAMMA GLUTAMYL TRANSPEPTIDASE - SERUM	48	U/L	●	0-50

GLUCOSE - SERUM / PLASMA (FASTING)

● Within Normal Range ● Borderline High/Low ● Out of Range



Name : Mr. KALYAN HONAJI GAVLI (55 /M)

UHID : MHN1.0000124754

Date : 27/08/2022

Package : MediWheel Full Body Health Checkup Male Above 40

AHC No : NSKAH27436

Test Name	Result	Unit	Level	Range
Glucose - Plasma (Fasting)	219 *	mg/dL	●	70-100
URINE GLUCOSE(FASTING): (Strip Method)	2+			

GLUCOSE - SERUM / PLASMA (POST PRANDIAL)

Test Name	Result	Unit	Level	Range
Glucose - Plasma (POST PRANDIAL)	418 *	mg/dL	●	70-140
URINE GLUCOSE(POST PRANDIAL):(Strip Method)	3+			

GLYCOSYLATED HEMOGLOBIN (HbA1C) - WHOLE BLOOD

Test Name	Result	Unit	Level	Range
Glycosylated Hemoglobin (HbA1c)	7.4 *	%	●	0.0-6.0
Mean Plasma Glucose (MPG) Estimate:	186.14	mg/dL		

LIPID PROFILE TEST (PACKAGE)

Test Name	Result	Unit	Level	Range
HDL CHOLESTEROL - SERUM / PLASMA	48	mg/dL	●	40-60
TOTAL CHOLESTEROL/HDL CHOLESTEROL RATIO(Calculated)	5.4 *		●	0.0-4.5
Cholesterol (Direct LDL)	194	mg/dL		

LIVER FUNCTION TEST (PACKAGE)

Test Name	Result	Unit	Level	Range
PROTEIN, TOTAL - SERUM / PLASMA	8.6 *	g/dL	●	6.4-8.2

THYROID PROFILE - I(T3,T4 AND TSH)

Test Name	Result	Unit	Level	Range
TOTAL T3: TRI IODOTHYRONINE - SERUM	150	ng/dL	●	Healthy Adults: 69 - 215
TOTAL T4: THYROXINE - SERUM	10.8	µg/dL	●	Healthy Adults:5.2-12.7

LIPID PROFILE TEST (PACKAGE)

Test Name	Result	Unit	Level	Range
Triglycerides - Serum	268 *	mg/dL	●	0-150

THYROID PROFILE - I(T3,T4 AND TSH)

Test Name	Result	Unit	Level	Range
TSH: THYROID STIMULATING HORMONE - SERUM	4.0	uIU/mL	●	Euthyroid: 0.3 - 4.5 Hypothyroid: 7.1 - >75

UREA - SERUM / PLASMA

Test Name	Result	Unit	Level	Range
UREA - SERUM / PLASMA	28	mg/dL	●	15-38
UREA NITROGEN SERUM/PLASMA: (Calculated)	13	mg/dL	●	7-18

URIC ACID - SERUM

Test Name	Result	Unit	Level	Range
URIC ACID - SERUM	4.1	mg/dL	●	3.5-7.2

LIVER FUNCTION TEST (PACKAGE)

Test Name	Result	Unit	Level	Range
BILIRUBIN CONJUGATED (DIRECT) - SERUM	0.1	mg/dL	●	0.0-0.3
BILIRUBIN UNCONJUGATED - SERUM(Calculated)	0.1	mg/dL	●	0.0-0.7

PROSTATIC SPECIFIC ANTIGEN (PSA TOTAL)

Test Name	Result	Unit	Level	Range
PROSTATIC SPECIFIC ANTIGEN (PSA TOTAL)	0.88	ng/mL	●	0.24-3

CARDIAC STRESS TEST - (TMT)

ECG

ULTRASOUND - WHOLE ABDOMEN

Grade I fatty liver.

No other significant abnormality is detected.

Suggest : Clinical correlation.

X-RAY CHEST PA

● Within Normal Range ● Borderline High/Low ● Out of Range

Swaminarayan Nagar, Off Mumbai-Agra Highway,
Panchvati, Nashik - 422 003.

+91 - 253 - 2510250 / 350 / 450 / 550 / 750

apollonashik@apollohospitals.com

www.askapollo.com

UHD : MHN1.0000124754

QFAHN/BILL/003/V1



Name : Mr. KALYAN HONAJI GAVLI (55 /M)

Date : 27/08/2022

Package : MediWheel Full Body Health Checkup Male Above 40

AHC No : NSKAH27436

INVESTIGATIONS NOT DONE / NOT YET REPORTED / NOT
PART OF PACKAGE(LAB,RADIOLOGY & CARDIOLOGY)

Haematology

STOOL ROUTINE



● Within Normal Range ● Borderline High/Low ● Out of Range



Name : Mr. KALYAN HONAJI GAVLI (55 /M)

UHID : MHN1.0000124754

Date : 27/08/2022

Package : MediWheel Full Body Health Checkup Male Above 40

AHC No : NSKAH27436

Printed By :

AHC Physician / Consultant Internal Medicine

Adv:-

tab. Tamsan-H
1-0-1

tab. Cromer 2
1-0-1

tab. Tenlimac M
 $\frac{1}{2}$ -1-0

inj Lantus 20 units 2TID

tab. Rozavel -A (75/10)
0-0-1

Chol - 259

TC - 268

F - 219

PP - 418

Opt E fatty liver

x 15 days

Note :- The Health Check-up examinations and routine investigations have certain limitations and may not be able to detect all the diseases. Any new or persisting symptoms should be brought to the attention of the Consulting Physician. Additional tests, consultations and follow up may be required in some cases.

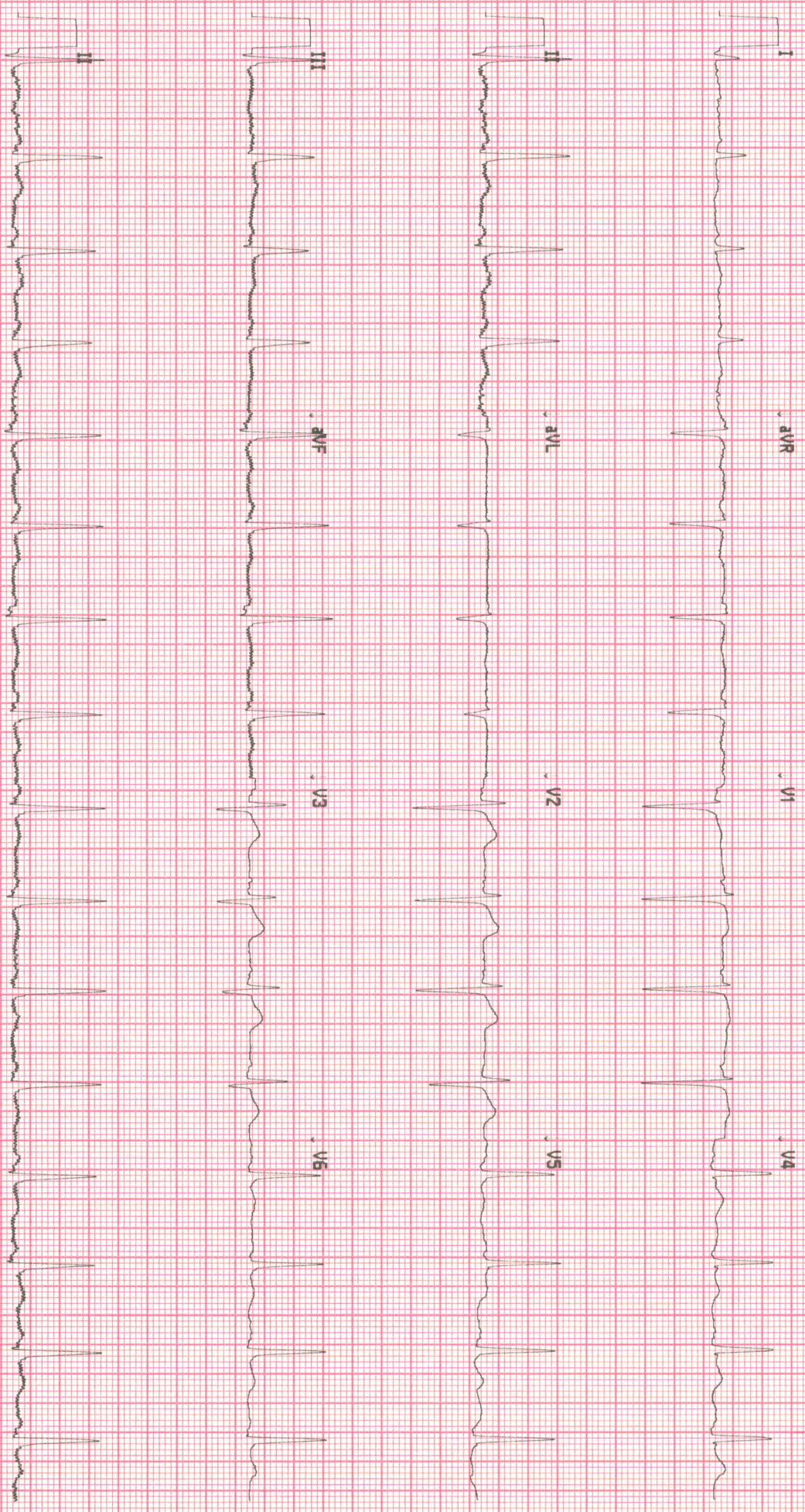
- FBS, PPS after 15 days
not req, daily exercise, diabetic diet

Gauli, Kalyan
ID:
DOB:
55yr, Male

27-Aug-2022 12:36:23

Vent rate: 94 BPH
PR int: 137 ms
QRS dur: 85 ms
QT/QTc: 329/381 ms
P-R-T axes: 50 75 65

SINUS RHYTHM
NONSPECIFIC T-WAVE ABNORMALITY
BORDERLINE ECG
UNCONFIRMED REPORT



113500188213

No Site Name

Site # 0 Cart # 2 Version 2.0.4.0 Sequence #19931 25mm/s 10mm/mV 0.05-40 Hz

Swaminarayan Nagar, Off Mumbai-Agra Highway,
Panchvati, Nashik - 422 003.
+91- 253 - 2510250 / 350 / 450 / 550 / 750
apollonashik@apollohospitals.com
www.askapollo.com

QFAHN/BILL/003/V1



Screening Echocardiography Report

Name: - Mr. KALYAN HONAJI GAVLI
UHID No: - MHN1. 0000124754
Referred by: -Dr. Sudhir Shetkar
Echo window: - Good


Age/Sex: 55/M
DATE: 27/08/2022
Echo No: -30261

Normal all rest of valves and chambers.
Normal LV systolic function. No RWMA at rest.
Normal RV systolic function.
AO/LA= 30 mm/ 37 mm, LVIDd/LVIDs= 48 mm/ 31 mm, IVS/PW= 11 mm/11 mm.
No PAH.
No Clot/ Vegetation/Pericardial effusion.
No Coarctation.

Normal Echo Study.


Impression: -

Normal all rest of valves and chambers.
Normal LV systolic function. No RWMA at rest.
Normal RV systolic function.
No PAH.
No clot/ vegetation/pericardial effusion.
No Coarctation.


DR.Niramal Kolate.



Radiology

Patient Details : Mr. KALYAN HONAJI GAVLI | Male | 55Yr 6Mth 26Days
UHID : MHN1.0000124754 **Patient Location:** AHC
Patient Identifier: NSKAH27436 
DRN : 222019143 **Completed on :** 27-AUG-2022 15:50
Ref Doctor : DR. Rajashri Dhongade

ULTRASOUND - WHOLE ABDOMEN

LIVER : Normal in size and measures 14.9cm. Grade I fatty liver. Echotexture is uniform.
No I.H.B.D./ focal lesions.

PORTAL VEIN: Normal in size.

GALL BLADDER: Well distended with normal walls and lumen.
No calculi/pericholecystic fluid.

COMMON BILE DUCT: Normal in size.

PANCREAS : Visualized portion of head and body of pancreas appears normal in size and echotexture. Rest of the pancreas is obscured due to bowel gases.

AORTA, IVC and para aortic areas are normal.

SPLEEN : Normal in size (10.9cm) and echotexture.

KIDNEYS: Both kidneys are normal in site, size and echotexture.

No evidence of calculi/ hydronephrosis.

Right kidney measures: 11.2 x 4.6 cm.

A subcentimeter sized simple cortical cyst is noted at lower pole and interpolar region of right kidney.

Left kidney measures : 11 x 6.2 cm

A simple cortical cyst measures 2.3 x 1.9cm is noted at lower pole of left kidney. Another subcentimeter sized simple cortical cyst noted at interpolar region of left kidney.

URINARY BLADDER: Well distended with normal walls.



Mr. KALYAN HONAJI GAVLI

MHN1.0000124754

NSKAH27436

ULTRASOUND - WHOLE ABDOMEN

No evidence of calculi/ growth/ diverticula .

PROSTATE : Normal in size with homogenous echogenicity.

Prostate measures : 18.7 cc.

Seminal vesicles are normal.

Few subcentimeter sized calcific foci are noted in prostate gland.

Visualized bowel loops appear grossly normal.

No evidence of any free fluid in the peritoneal cavity.

Impression

Grade I fatty liver.

No other significant abnormality is detected.

Suggest : Clinical correlation.


--- END OF THE REPORT ---

Dr.Samruddhi Sonawane

Consultant - Radiology



Radiology

Patient Details : Mr. KALYAN HONAJI GAVLI | Male | 55Yr 6Mth 26Days
UHID : MHN1.0000124754 **Patient Location:** AHC
Patient Identifier: NSKAH27436 
DRN : 122032536 **Completed on :** 27-AUG-2022 10:35
Ref Doctor : DR. Rajashri Dhongade

X-RAY CHEST PA

Mild rotation.

Mid inspiratory.

Mild perihilar bronchovascular prominence.

Rest of the lung fields are clear.

Costophrenic angles are clear.

Cardiac size and contour are within normal limits.

Rib cage is normal.

Soft tissues are normal.

Suggest : Clinical correlation.

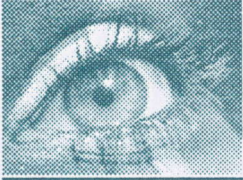Impression

”

---- END OF THE REPORT ----

Dr. Gorakhnath T

CONSULTANT-RADIOLOGY



OPHTHALMOLOGY



Name : Mr Kalyan Gauri
 Occupation : _____
 Age : 55 Sex : Male Female S/M/W/D
 Address : NSIC
 Tel. No. _____

Date 27/08/22 UNIT _____
 Room No. _____ Out Patient
 Ref. Physician : _____
 Copies to : _____

REPORT ON OPHTHALMIC EXAMINATION

HISTORY : _____

PRESENT COMPLAINT : vision Blurring x 1 1/2 yrs

PAST HISTORY DM HTN ALLERGY _____

ON EXAMINATION

VISION :

RE
LE

A6/36
M/36
A6/24

10-12 yrs
prc 18p
prc 18p N18

	RIGHT					LEFT				
	PGP	SPH	CYL	AXIS	VA	SPH	CYL	AXIS	VA	
DIST										
NEAR										

REFRACTION / Retinoscopy :

	RIGHT			LEFT		
	SPH	CYL	AXIS	SPH	CYL	AXIS
	-	-	70	-	-	104
	5.75	4.25		0.75	2.00	

Refraction or Acceptance :

	RIGHT					LEFT				
	SPH	CYL	AXIS	VA	SPH	CYL	AXIS	VA		
DIST										
NEAR										


 CONSULTANT OPTOMETRIST

H Swaminarayan Nagar, Off Mumbai-Agra Highway,
Panchvati, Nashik - 422 003.

+91- 253 - 2510250 / 350 / 450 / 550 / 750

apollonashik@apollohospitals.com

www.askapollo.com

QFAHN/BILL/003/V1



27/8/22

Mrs. Sunanda. Ganli

1P.

- chronic tobacco chewer.

- supra & subgingival plaque present.

- stains - + + +

- class I malocclusion bilaterally.

Advise oral prophylaxis