

DAKSH HOSPITAL

396 - 397, Gandhi Nagar, Scheme No. 8, ALWAR -301001

Ref. No.

Date.....

MEDICAL EXAMINATION REPORT

Mediwheel (BOB)

Name: Mr Shyam Kumar Junwal Age: 39 yrs Sex: Male Date: 14/04/2023

General Physical Examination

Height	: 164 cm.	Weight	: 69 kg
Pulse	: 82/mt	BP	: 110/90 mm/hg
Temp.	: 97.6 °F	Respiration	: 97 %
BMI	: 25.7		

Systemic Exam:- *NORMAL*Dental Check up :- *NORMAL*Eye check-up :- *NORMAL*Skin Check up:- *NORMAL*ENT Check up:- *NORMAL*Gynae Check up:- *N/A*Impression:- *NORMAL* *Fatty Liver*Recommendation:- *NORMAL*

Mukesh
 डॉ० मुकेश गुप्ता
 M.D. F.C.C.S.
 फिजिशियन मेडिसिन एवं जनरल मेडिसिन
 M.D. Gen. Medicine
 Reg. No. 5423/16262

Results

Run Date 14/04/2023 10:28:07 AM

Operator DAKSH

Last Name

Sample ID 6

First Name MR SHYAM KUMAR

Department

Gender Male

Age

Physician DR. MUKESH GUPTA M.D

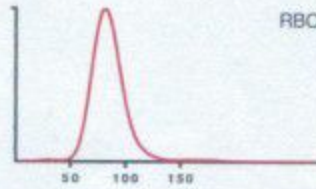
Patient ID AUTO_PID13053

Type Man

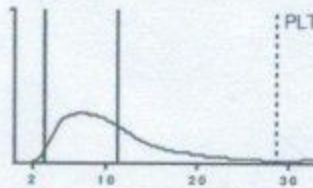
Date of birth

Sample comments

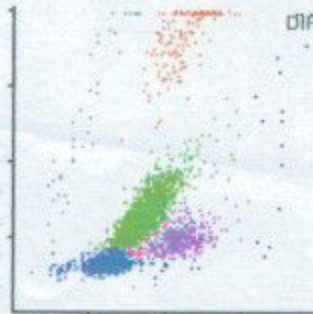
				Range
RBC	5.01	*	10 ⁶ /μL	3.80 - 5.50
HGB	14.2		g/dL	13.0 - 17.0
HCT	44.9	*	%	39.0 - 52.0
MCV	89.6	*	μm ³	76.0 - 100.0
MCH	28.4		pg	26.0 - 34.0
MCHC	31.7	L	g/dL	32.0 - 35.0
RDW-CV	15.8		%	11.0 - 16.0
RDW-SD	53.1	h	μm ³	37.0 - 49.0



			Range
PLT	227		10 ³ /μL
PCT	0.24		%
MPV	10.5		μm ³
PDW	17.4		μm ³
P-LCC	81		10 ³ /μL
P-LCR	35.7		%



			Range
WBC	7.27		10 ³ /μL
			3.50 - 10.00
	#		Range
NEU	4.14		1.60 - 7.00
			%
LYM	2.56		1.00 - 3.00
			%
MON	0.19	l	0.20 - 0.80
			%
EOS	0.25		0.00 - 0.50
			%
BAS	0.09		0.00 - 0.15
			%
LIC	0.04		0.00 - 0.10
			%



डॉ० मुकेश गुप्ता
M.D. P.C.C.S.

14/04/2023 10:29:20 AM रोग विशेषज्ञ

Printed by : DAKSH

S/N 107YOXH0 TECHNOLOGIST

All investigations have their own limitations regarding the sensitivity & specificity of individual assay procedures. Isolated laboratory investigations never confirm the final diagnosis of the disease. They only help in arriving at a diagnosis in conjunction with clinical presentation and other related investigations. Report is not valid for medico-legal purpose subject to ALWAR jurisdiction only.

Date :-14/04/2023

Name :- MR. SHYAM KUMAR

Age & Sex :- 39Yrs/ male

Refd. :- Dr Mukesh Gupta M.D.

	TEST NAME	RESULT	REFERENCE RANGE
	ESR	20	00 -20 mm/hrs
	Blood Group & Rh Factor	B * POSITIVE	
	HbA1C	4.5	4 - 5.6%
	Blood Sugar (F)	85.2	< 70 - 100 mg/dl
	Blood Sugar (PP)	102.1	< 140 mg/dl
	Urine Sugar (F)	NIL	-
	Urine Sugar (PP)	NIL	-
LIVER	S.Bilirubin Total	1.00	0.30 - 1.20 mg/dl
	S.Bilirubin Direct	0.30	0.10 - 0.30 mg/dl
	S.Bilirubin Indirect	0.70	0.30 - 0.90 mg/dl
	S.G.O.T.	40	> 37 u/l
	S.G.P.T.	48	> 40 u/l
	S.Aik. Phosp.	195	80 - 306 u/l
	G.G.T.	15	5 -40 u/l
	Total Protein	6.9	6.5 - 8.5 gm/dl
	Albumin	3.8	3.8 - 5.4 gm/dl
	Globulin	3.1	2.3 - 3.5 gm/dl
	A/G Ratio	1.2	-
AST/ALT Ratio	0.8	-	
KIDNEY	Blood Urea	27.1	15 -45 mg/dl
	S.Creatinine	0.98	0.60 - 1.30 mg/dl
	BUN	15.0	6 -24 mg/dl
	S.Uric Acid	5.0	M 3.1 - 7.0, F 2.5 - 5.6 mg/dl
	BUN/Creatinine Ratio	15.3	-
LIPID PROFILE	Total Cholesterol	180.1	Up to 200 mg/dl
	S.HDL	44.1	30 - 70 mg/dl
	S.LDL	109.1	Up to 170 mg/dl
	S.VLDL	27.1	5.0 - 40 mg/dl
	S. Triglycerides	135.1	Up to 170 mg/dl
	LDL/HDL Ratio	2.4	-
	Total Cholesterol/ HDL Ratio	4.0	-
THYROID	T3	82.1	40 - 181 ng/dL
	T4	6.5	4.6 - 10.5 µg/dL
	TSH	1.55	0.30 - 5.0 mIU/L

URINE EXAMINATION

Microscopic Examination :

General/Chemical Examination:			RBC	Absent
	Colour	Pale Yellow	WBC	0 - 1
	Reaction	Acidic	Epithelial Cells	0- 1
	Specific Gravity	QNS	Cast	Absent
	Appearance	Clear	Crystal	Absent
	Albumin	Nil	Spermatozoa	Absent
	Sugar	Nil	Amorphous Sediments	Absent
			Other	Absent


X-RAY CHEST

NORMAL STUDY

STOOL EXAMINATION

Microscopic Examination :

General/ Chemical Examination:			RBC	-
	Colour	-	WBC	-
	Consistency	-	Ova & Parasites	-
	PH	-		
	Reducing Substances	-		


डॉ. मुकेश गुप्ता
 M.D. F.C.C.S.
 डिजिटल एवं मध्यम रोग विशेषज्ञ
 अलवर

TECHNOLOGIST

All investigations have their own limitations regarding the sensitivity & specificity of individual assay procedures, isolated laboratory investigations never confirm the final diagnosis of the disease. They only help in arriving at a diagnosis in conjunction with clinical presentation and other related investigations. Report is not valid for medico-legal purpose subject to ALWAR jurisdiction only.



दक्ष हॉस्पिटल

396, गाँधी नगर स्कीम नं.8, अलवर (राज०) ☎ 0144-2703340

Sonography / 2D Echo Cardiography / Doppler Report

2D/ ECHO REPORT

Name: - Mr SHYAM KUMAR Age: - 39 Yrs Date: - 14-Apr-23

Reg. No.: - Alw/2009/04
BOB health checkup

PROCEDURES:

M-MODE/2D/DOPPLER/COLOR/CONTRAST B.A.S. M²

MEASUREMENT:		DOPPLER:	
AOD	22	NORMAL	NORMAL (cm/sec.)
LA	24	(20- 37mm)	MV 0.5 (0.8- 1.3) MR No
AVO	98	(19- 40mm)	AV 1.4 (1.2- 1.8) AR No
RVDd	11	(12- 25mm)	TV 0.6 (0.3- 0.8) TR No
		(03- 09mm)	PV 0.8 (0.7- 1.1) PR No
LV Dd	46	(37- 56mm)	MITRAL VALVE-
LV Ds	27	(22- 40mm)	AML Normal
IVS d	7.8	(06- 12mm)	PML Normal
IVS s	11.6		
PWd	3.9	(05- 10mm)	AORTIC VALVE Normal
LV FUNCTION		TV & PV are normal.	
M- E- S Separation		<0.9cm	
Minor		24.42%	
LV Ejection Fraction	71%	65 +/- 12%	

LV WALL MOTION: NO RWMA
ALL CARDIAC CHAMBERS ARE NORMAL
ALL VALVES ARE NORMAL
NO CLOT, VEGETATION, PERICARDIAL EFFUSION

FINAL DIAGNOSIS: NORMAL STUDY

Adv - Follow up/ review at higher center for confirmation

Note - Please Correlate clinically. Due to technical limitations as well as inaccuracies inherent in the laboratory and statistical analysis of biological process. Diagnostic accuracy of ECHO is up to 95% only.
Report is not valid for medico-legal purpose.


DR. Mukesh Kumar Gupta
Physician & Sonologist
RM 5423/16262



"भ्रूण लिंग परीक्षण की शिकायत
104 टोल फ्री सेवा पर भी की
जा सकती है"

भ्रूण लिंग परीक्षण की शिकायत 104 टोल फ्री सेवा पर भी की जा सकती है।



दक्ष हॉस्पिटल

396, गाँधी नगर स्कीम नं.8, अलवर (राज०) ☎ 0144-2703340

Sonography / 2D Echo Cardiography / Doppler Report

Name: MR. SHYAM KUMAR /M/39 YRS

Date: 14-Apr-23

BOB HEALTH CHECK UP

U.S.G. OF ABDOMEN & PELVIS

LIVER

Liver is **12.3 cm vertically with increase echogenicty (Grade II fatty liver)**. Intra hepatic biliary radicals are not dilated.

Portal vein normal.

No evidence of focal or diffuse lesion.

GALL BLADDER

Gall bladder is normal dilated. Lumen clear. Wall thickness normal. CBD normal

PANCREAS

Pancreas is normal in size, shape & echo-texture.

SPLEEN

9.8 cm in size with normal shape & echo- texture.

BOTH KIDNEY

Both kidneys are normal in size shape and echo- texture.

PROSTATE is normal shape, size & echo texture..

URINARY BLADDER is normal shape, size & echo texture..

Advice- X Ray KUB / URINE EXAM

Grade II fatty liver

Please correlate clinically. USG accuracy is 95 % due to technical limitations as well as inaccuracies inherent in the laboratory and statistical analysis biological process.

This report is not valid for medico-legal cases.


DR. MUKESH GUPTA
SONOLOGIST
Physician & Sonologist
RM 5423/16262



"भ्रूण लिंग परीक्षण की शिकायत
104 टोल फ्री सेवा पर भी की
जा सकती है"

भ्रूण लिंग परीक्षण की शिकायत 104 टोल फ्री सेवा पर भी की जा सकती है।

ID: 605

14-04-2023 13:27:12

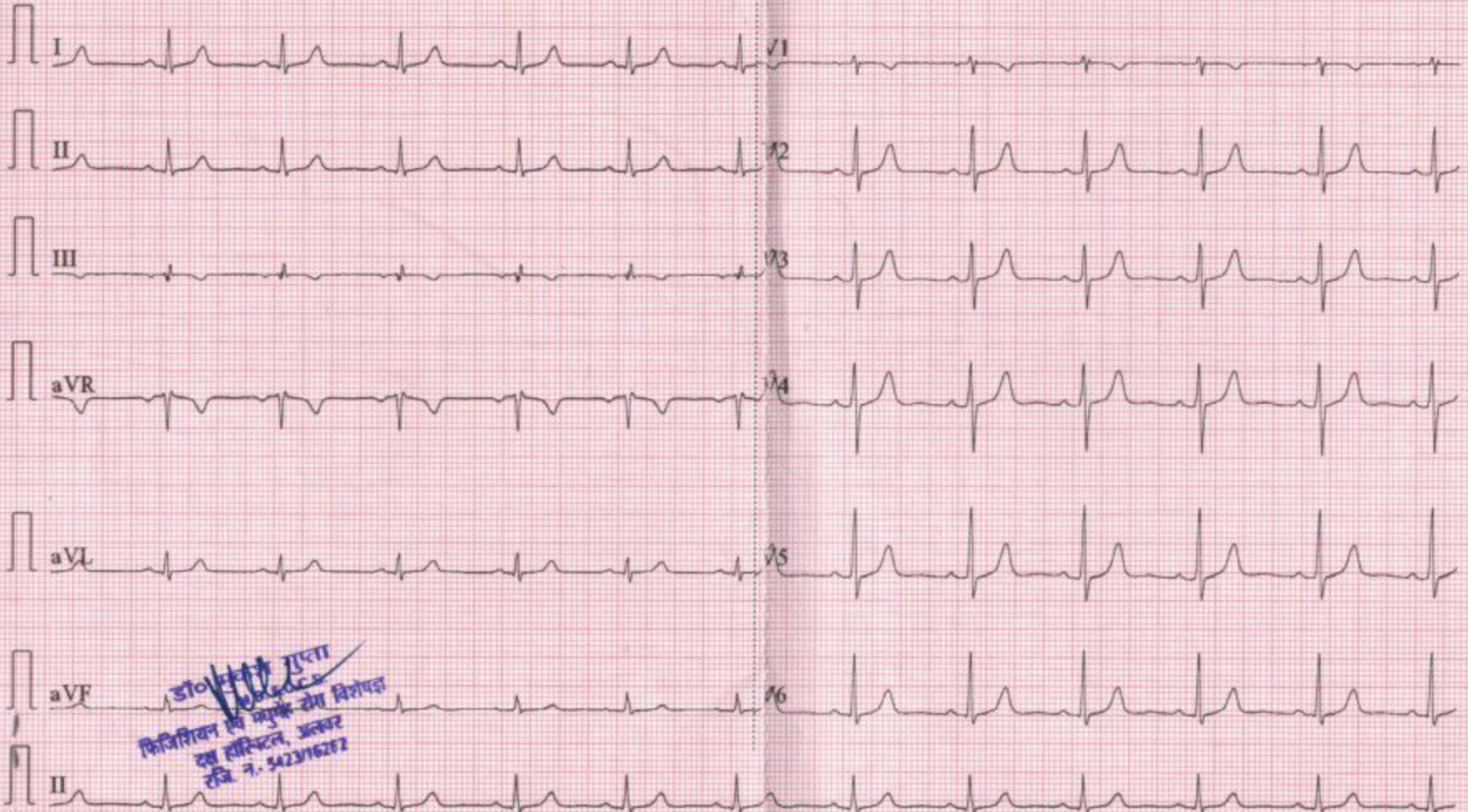
Female Years
Req. No. :

HR : 73 bpm
 P : 90 ms
 PR : 142 ms
 QRS : 84 ms
 QT/QTcBz : 368/406 ms
 P/QRS/T : 11/39/17 °
 RV5/SV1 : 1.226/0.192 mV

Diagnosis Information:

Sinus rhythm
Normal ECG

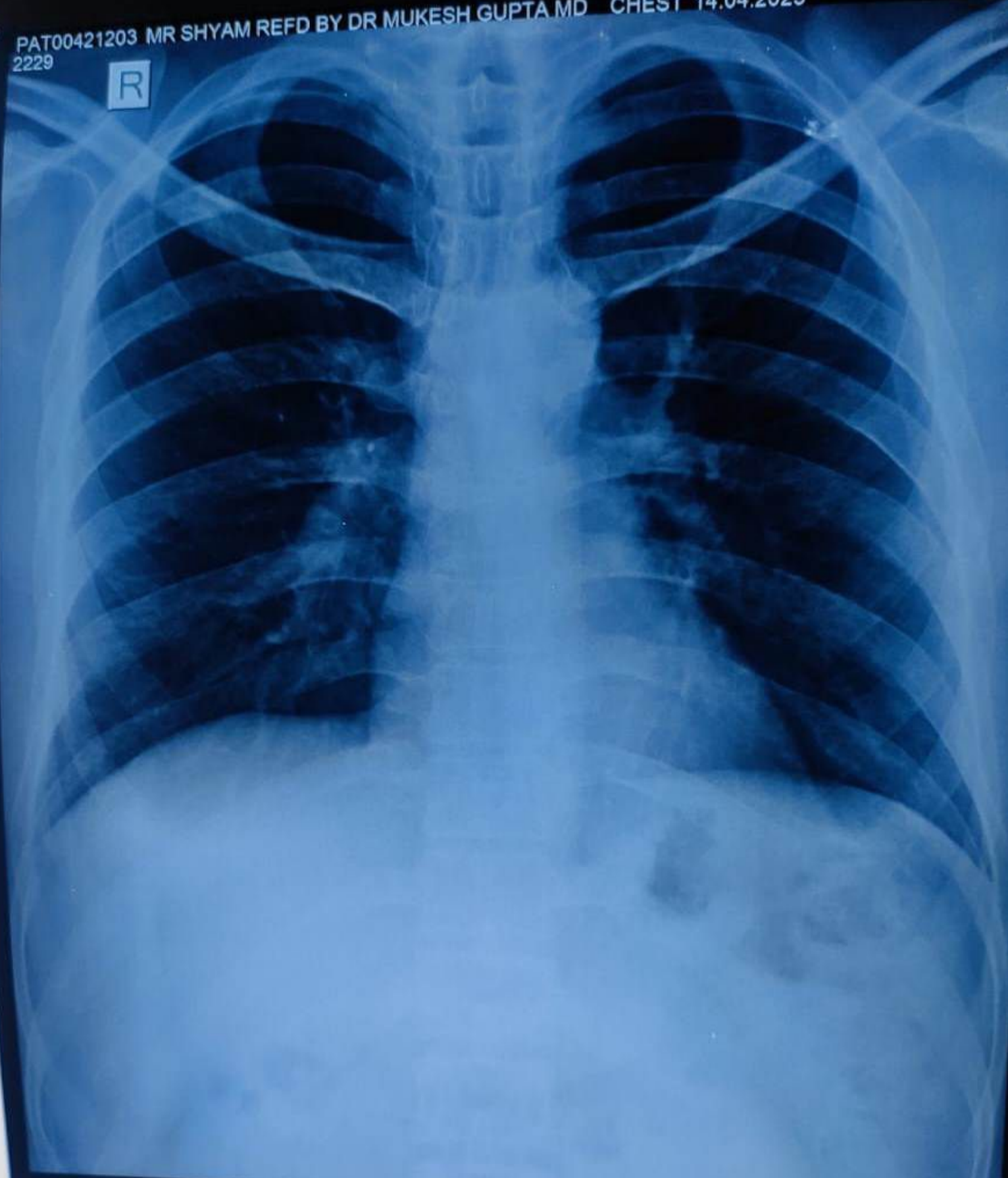
Report Confirmed by:



डॉ. मधुसूदन गुप्ता
 MD (CC) -
 फिजिशियन एवं कर्मानुसंगी विभागाध्यक्ष
 दक्ष हॉस्पिटल, अलवर
 रजि. नं. 5423/16272

PAT00421203 MR SHYAM REFD BY DR MUKESH GUPTA MD CHEST 14.04.2023
2229

R



VIJAY DIAGNOSTIC CENTRE 1/16 KALA KUAN .ALWAR

2229