

CONSULTATION SUMMARY

Patient MRN : 17540000321007
Patient Name : Ranjeeta Jagne
Gender/Age/Dob : Female , 34 Years , 01/05/88
Patient Phone No : 9713066056
Patient Address : H NO 2 PHASE III KHUSHI
VATIKA AMLIDIH,Raipur,Raipur,
Chhattisgarh,India,-492001

Consultation Date: 14/01/2023 11:14 AM
Consultant : Dr.Kshitij Dwivedi (DENTAL)
Consultation Type : OP , NEW VISIT



CHIEF COMPLAINTS & HISTORY OF PRESENT ILLNESS

- regular health check up :

DENTAL EXAMINATION

- h/o trauma
h/o rct
o/e - root canal treated 11 and 21
missing 16
stains+
calculus++

CONSULTANT DETAILS



Dr.Kshitij Dwivedi , VISITING CONSULTANT , DENTAL
Registration No : 29664 A

One free consultation with the same doctor within next 6 days.

Printed By: Dr.Kshitij Dwivedi | Printed On: 14.01.2023 13:05



CONSULTATION SUMMARY

Patient MRN : 17540000321007
Patient Name : Ranjeeta Jagne
Gender/Age/Dob : Female , 34 Years , 01/05/88
Patient Phone No : 9713066056
Patient Address : H NO 2 PHASE III KHUSHI
VATIKA AMLIDIH,Raipur,Raipur,
Chhattisgarh,India,-492001

Consultation Date: 14/01/2023 01:04 PM
Consultant : Dr. Manisha Sharma
(OBSTETRICS & GYNAECOLOGY)
Consultation Type : OP , NEW VISIT



CHIEF COMPLAINTS & HISTORY OF PRESENT ILLNESS

- came for health check-up :
- P2L2 / 2ND / Sterilized :
- k/c/o - Hypothyroid (on Tab. Thyroxine 100mcg OD) :
- 14/1/23 USG - RIGHT ADNEXAL ANECHOIC CYST ~ 4.2 X 2.9 CM. :
- LMP - 5th day today :

SYSTEMIC EXAMINATION

- Per Abdomen : NAD
- Per Speculum : cervical erosion +, bleeding + (5th days of menses today)

INVESTIGATION ORDER

PAP SMEAR

MEDICATION ORDER

- DRUG NAME
- 1) CLINDAMYCIN+CLOTRIMAZOLE+TINIDAZOLE-SUPPOSITORY-100MG+100MG+100MG-CLINGEN FORTE
 - 2) THERAPY LIQUID SOAP-SOLUTION-100ML-INTIWASH

PATIENT INSTRUCTION

Once Daily (0 - 0 - 0 - 1) Vaginal At Bed Time For 7 Days For vaginal insertion only , **Qty: 1 , Start Date:** Jan 14, 2023 , **End Date:** Jan 20, 2023
for vaginal wash , **Qty: 1 , Start Date:** Jan 14, 2023

CONSULTANT DETAILS

Dr. Manisha Sharma , VISITING CONSULTANT , OBSTETRICS & GYNAECOLOGY



CONSULTATION SUMMARY

Patient MRN : 17540000321007
Patient Name : Ranjeeta Jagne
Gender/Age/Dob : Female , 34 Years , 01/05/88
Patient Phone No : 9713066056
Patient Address : H NO 2 PHASE III KHUSHI
VATIKA AMLIDIH,Raipur,Raipur,
Chhattisgarh,India,-492001

Consultation Date: 14/01/2023 03:55 PM
Consultant : Dr. Mukesh Kumar Sharma
(GENERAL MEDICINE)
Consultation Type : OP , NEW VISIT



CLINICAL DIAGNOSIS

• HYPOTHYROIDISM
RHD , MS

CHIEF COMPLAINTS & HISTORY OF PRESENT ILLNESS

- CAME FOR HEALTH CHECK UP :
- H/O : INTERMITTENT COUGH , BACKCHE :
- H/O : DOE+ :

VITALS

Blood Pressure: 118/73 mmHg Heart Rate: 81 /bpm Temperature: 97.9 F
Respiratory Rate: 20 /min
SPO2 : 100 % , Room air
Weight: 67 kg
Fall Score: Low Pain Score: 0

MEDICATION ORDER

DRUG NAME

- 1) THYROXINE SODIUM-TABLET-50MCG-**ELTROXIN**
- 2) ESOMEPRAZOLE+DOMPERIDONE(SR)-CAPSULE-40MG+30MG-**ESOFINE DSR**
- 3) MONTELUKAST+LEVOCETIRIZINE-TABLET-10MG+5MG-**MONTEMAC L**

PATIENT INSTRUCTION

Once Daily (1 - 0 - 0 - 0) Tablet Orally Empty Stomach For 30 Days , **Qty: 30** , **Start Date:** Jan 14, 2023 , **End Date:** Feb 12, 2023

Once Daily (1 - 0 - 0 - 0) Capsule Orally Empty Stomach For 30 Days , **Qty: 30** , **Start Date:** Jan 14, 2023 , **End Date:** Feb 12, 2023

Once Daily (0 - 0 - 0 - 1) Tablet Orally At Bed Time For 30 Days , **Qty: 30** , **Start Date:** Jan 14, 2023 , **End Date:** Feb 12, 2023





9177 4210 901 / 902 - 0200 5210 097

DRUG NAME

- 4) CALCITRIOL+VITB 12+CACO3+EPA+FOLIC ACID-TABLET-10'S-**BIO D3 MAX**
- 5) ACECLOFENAC+CHLORZOXAZONE+PARACETAMOL-TABLET-100MG+500MG+325MG-**HIFENAC MR**

PATIENT INSTRUCTION


Once Daily (1 - 0 - 0 - 0) After Food For 30 Days , **Qty: 1** , **Start Date:** Jan 14, 2023 , **End Date:** Feb 12, 2023

Twice Daily (1 - 0 - 0 - 1) Tablet Orally After Food For 5 Days , **Qty: 10** , **Start Date:** Jan 14, 2023 , **End Date:** Jan 18, 2023

NOTES

- LIFE STYLE MODIFICATIONS AS ADVISED
LOW SALT DIET, AVOID SPICY N JUNK FOODS
REGULAR EXERCISE
- CARDIOLOGY OPINION

CONSULTANT DETAILS



Dr. Mukesh Kumar Sharma , CONSULTANT , GENERAL MEDICINE
Registration No : 5549/2014

One free consultation with the same doctor within next 6 days.

Printed By: Dr. Mukesh Kumar Sharma | Printed On: 14.01.2023 16:09



CONSULTATION SUMMARY

Unit of Narayana Health

Patient MRN : 17540000321007
Patient Name : Ranjeeta Jagne
Gender/Age/Dob : Female , 34 Years , 01/05/88
Patient Phone No : 9713066056
Patient Address : H NO 2 PHASE III KHUSHI
VATIKA AMLIDIH,Raipur,Raipur,
Chhattisgarh,India,-492001

Consultation Date: 14/01/2023 02:00 PM
Consultant : Dr. Renuka Sharma
(OPHTHALMOLOGY)
Consultation Type : OP , NEW VISIT



CHIEF COMPLAINTS & HISTORY OF PRESENT ILLNESS

- CAME FOR ROUTINE HEALTH CHECK UP


MEDICATION ORDER

DRUG NAME
1) KETOROLAC TROMETHAMINE-DROPS-5ML-ACULAR LS

PATIENT INSTRUCTION

(1-1-1-1) For 20 Days , **Qty: 1** , **Start Date:** Jan 14, 2023 ,
End Date: Feb 02, 2023

CONSULTANT DETAILS



Dr. Renuka Sharma , VISITING CONSULTANT , OPHTHALMOLOGY
Registration No : 2434/2009

One free consultation with the same doctor within next 6 days.

Printed By: Dr. Renuka Sharma | Printed On: 14.01.2023 14:21



Patient Name	Ranjeeta Jagne	Requested By	Dr. Mukesh Kumar Sharma
MRN	17540000321007	Procedure Date Time	2023-01-14 18:58:55
Age/Sex	34Y 8M/Female	Hospital	NH-RAIPUR

CHEST RADIOGRAPH (PA VIEW)

CLINICAL DETAILS:For health checkup.

FINDINGS:

- The lung fields and bronchovascular markings appear normal.
- The cardiac size is within normal limits.
- Mediastinum and great vessels are within normal limits.
- Trachea is normal and is central. The hilar shadows are unremarkable.
- The costo-phrenic angles are clear. No evidence of pleural effusion or pneumothorax.
- The visualized bones and soft tissue structures appear normal.
- Both the diaphragmatic domes appear normal.

IMPRESSION:

- **Normal chest radiograph.**



DR VIJENDRA RUPRELA
MBBS, DMRD, DNB, MNAMS
CONSULTANT RADIOLOGIST

* **This is a digitally signed valid document.**Reported Date/Time: 2023-01-18 12:56:50



ECHOCARDIOGRAPHY REPORT

Patient ID : 17540000321007 Report Date : 14/01/2023
Patient Name: : Mrs. Ranjeeta Jagne
Age / Gender : 34Years/ Female

MEASUREMENT

AO : 24 (20 - 35)mm LVID(d) : 41 (36 - 52)mm IVS: 09 (06 - 11)mm
LA : 34 (19 - 40)mm LVID s : 26 (23 - 39)mm PW: 08 (06 - 11)mm
EF : 60%

VALVES

Mitral Valve : Doming of AML, fixed PML, trivial MS(MVA-2.0 cm² by planimetry & 1.9 cm² by PHT) Max/Mean PG-7/3mmHg, mild MR
Aortic valve : Normal
Tricuspid Valve : Normal
Pulmonary Valve : Normal

CHAMBERS

Left Atrium : Normal
Right Atrium : Normal
Left Ventricle : Normal
Right Ventricle : Normal

SEPTAE

IVS : Intact
IAS : Intact

GREAT ARTERIES

Aorta : Normal
Pulmonary Artery : Normal



NH MMI Narayana Superspeciality Hospital

(A Unit of Narayana (Innovative) Limited) CIN: L85110KA2005PLC027492
Registered Office: 258/A, Bommasandra Industrial Area, Anekal Taluk, Bangalore 560099
Hospital Address: New Dhamtari Road, Lalpur, Raipur 492001
Tel +91 771 4210901 / 902 | Fax +91 771 408 1106 | Email: info.rpr@narayanahealth.org | www.narayanahealth.org



Appointments
1800-309-0309

Emergencies
8821-818181

NAME: MS. RANJEETA JAGNE

AGE: 34YRS/F MRN:321007

REF. BY: DR. M.SHARMA

DATE: 14.01.2023

SONOGRAPHY OF ABDOMEN AND PELVIS

The Real time, B mode, gray scale sonography was performed.

LIVER : The liver is normal in size 14.8cm & reveals normal echotexture with smooth outlines.

PORTAL VEIN : The portal vein is normal in calibre.

GALL BLADDER : The gall bladder is minimally distended.

Visualized proximal CBD is normal in calibre.

SPLEEN : The spleen is normal in size . No evidence of focal lesion is noted.

PANCREAS :The visualized pancreas is normal in size, shape, contours and echotexture.

B/L KIDNEYS :

The right kidney measures - 10.0 x 3.7cm and left kidney measures - 10.5 x 4.9cm in size. Both kidneys reveal normal cortical echotexture and have smooth margins. Cortico-medullary differentiation is maintained. No calculus or hydronephrosis is seen.

URINARY BLADDER : The urinary bladder is partially distended.

UTERUS: Uterus is anteverted and normal in size 7.1 x 5.5 x 3.8cm. The endometrial thickness is 5.8mm.

Right ovary could not well visualized. Right adnexa anechoic cyst of size 4.2x 2.9cm -.

Left ovary measures: 4.5 x 2.7cm (enlarged). Cne anechoic cyst of size 2.4 x 1.6cm - ? follicular cyst.

No free fluid is seen in the peritoneal cavity.

Excessive intrabowel gases are noted.

IMPRESSION :

- **Right adnexa anechoic cyst.**

ADVISED: Clinical correlation & appropriate further evaluation.



Ranjana

DR. RANJANA KEDIA
MBBS, CBET
CONSULTANT SONOLOGIST

DEPARTMENT OF LABORATORY MEDICINE

MRN	: 17540000321007	Department	: GENERAL MEDICINE
Name	: Ranjeta Jagne	Specimen	: WHOLE BLOOD
Age / Sex	: 34 Year(s) / Female	Visit Type	: OP
Sample No	: 22301140125	Collected On	: 14/01/2023 11:13 AM
Consulting DR	: Dr. Mukesh Kumar Sharma	Referred DR	: Dr. Mukesh Kumar Sharma
Patient Address	: H NO 2 PHASE III KHUSHI VATIKA AMLIDIH Raipur Raipur Chhattisgarh,India	Received On	: 14/01/2023 12:12 PM
		Reported On	: 14/01/2023 12:50 PM
		Report Type	: Final

HAEMATOLOGY LAB

Test	Result	Unit	Biological Reference Interval
EHP MEDIWHEEL FULL BODY HEALTH CHECK PACKAGE FEMALE BELOW 40 YRS			
ERYTHROCYTE SEDIMENTATION RATE (ESR)	<u>25.00</u> H	mm/hr	0-19



(Signature)



Dr. SMRITI RATHORE MBBS MD
PATHOLOGY

Appointments

1800-309-0309

Emergencies

8821-818181

NH MMI Narayana Superspeciality Hospital

(A Unit of Narayana Hrudayalaya Limited) CIN: LB6110KA2003PLC027487

Registered Office: 256/A, Bommasandra Industrial Area, Anekal Taluk, Bangalore 560069

Hospital Address: New Dhamtari Road, Lalpur, Raipur 492001

Tel +91 771 4210901 / 902 | Fax +91 771 408.1106 | Email: info.rpr@narayanahealth.org | www.narayanahealth.org

DEPARTMENT OF LABORATORY MEDICINE

MRN : 17540000321007
 Name : Ranjeeta Jagne
 Age / Sex : 34 Year(s) / Female
 Sample No : IR2301140234
 Consulting DR : Dr. Mukesh Kumar Sharma
 Patient Address : H NO 2 PHASE III KHUSHI VATIKA
 AMLIDIH Raipur Raipur, Chhattisgarh, India

Department : GENERAL MEDICINE
 Specimen : SERUM
 Visit Type : OP
 Collected On : 14/01/2023 11:13 AM
 Referred DR : Dr. Mukesh Kumar Sharma
 Received On : 14/01/2023 12:12 PM
 Reported On : 14/01/2023 01:57 PM
 Report Type : Final

BIOCHEMISTRY

Test	Result	Unit	Biological Reference Interval
FASTING BLOOD SUGAR (FBS)	84.00	mg/dl	70-99
LIPID PROFILE (CHOL,TRIG,HDL,LDL,VLDL)			
CHOLESTEROL TOTAL	161.00		50-200
TRIGLYCERIDES	145.00	mg/dl	0-150
HDL CHOLESTROL (HDLC)	<u>30.00</u> L	mg/dl	35-70
LDL CHOLESTEROL	<u>102.00</u> H	mg/dl	0-100
VLDL CHOLESTEROL	29.00	mg/dl	0-40
CHOLESTEROL /HDL RATIO	<u>5.37</u> H		0-5



(Signature)



DEPARTMENT OF LABORATORY MEDICINE

MRN	: 17540000321007	Department	: GENERAL MEDICINE
Name	: Ranjeeta Jagne	Specimen	: PLASMA
Age / Sex	: 34 Year(s) / Female	Visit Type	: OP
Sample No	: 1R2301140231	Collected On	: 14/01/2023 11:13 AM
Consulting DR	: Dr. Mukesh Kumar Sharma	Referred DR	: Dr. Mukesh Kumar Sharma
Patient Address	: H NO 2 PHASE III KHUSHI VATIKA AMLIDIH Raipur Raipur Chhattisgarh,India	Received On	: 14/01/2023 12:12 PM
		Reported On	: 14/01/2023 03:15 PM
		Report Type	: Final

Test	Result	Unit	Biological Reference Interval
POST PRANDIAL BLOOD SUGAR (PPBS)	109.00		



Ni

NH MMI Narayana Superspeciality Hospital

(A unit of Narayana Healthcare Limited) CIN: L65110KA2000PLC027497

Registered Office: 256/A, Bommasandra Industrial Area, Anekal Taluk, Bangalore-560099

Hospital Address: New Dhamtari Road, Lalpur, Raipur 492001

Tel +91 771 4210901 / 902 | Fax +91 771 408 1108 | Email: info.rpr@narayanahealth.org | www.narayanahealth.org



NEERAJ NAIK M.B.B.S D.C.P
CONSULTANT PATHOLOGIST

1800-309-0309

Emergencies

8821-818181

DEPARTMENT OF LABORATORY MEDICINE

MRN : 17540000321007	Department : GENERAL MEDICINE
Name : Ranjeeta Jagne	Specimen : WHOLE BLOOD
Age / Sex : 34 Year(s) / Female	Visit Type : OP
Sample No : 22301140126	Collected On : 14/01/2023 11:13 AM
Consulting DR : Dr. Mukesh Kumar Sharma	Referred DR : Dr. Mukesh Kumar Sharma
Patient Address : H NO 2 PHASE III KHUSHI VATIKA AMLIDIH Raipur Raipur Chhattisgarh,India	Received On : 14/01/2023 12:12 PM
	Reported On : 14/01/2023 12:36 PM
	Report Type : Final

Test	Result	Unit	Biological Reference Interval
COMPLETE BLOOD COUNT (CBC)			
HAEMOGLOBIN (HB%)	13.30	g/dl	13-18
RED BLOOD CELL COUNT	4.49	Million/ul	3.8-5.8
PCV (PACKED CELL VOLUME) / HEMATOCRIT	38.7	%	36-46
MCV (MEAN CORPUSCULAR VOLUME)	86.2	fl	76-96
MCH (MEAN CORPUSCULAR HAEMOGLOBIN)	29.70	pg	27-32
MCHC (MEAN CORPUSCULAR HAEMOGLOBIN CONCENTRATION)	34.50	%	30-35
RED CELL DISTRIBUTION WIDTH (RDW)	12.90	%	11.6-14.0
PLATELET COUNT	349.00	Thous/ul	150-400
TOTAL LEUKOCYTE COUNT (TLC)	6.7	Thousand/cu.mm	4.0-10.0
DIFFERENTIAL COUNT (DC)			
Neutrophils	65	%	40-75
Lymphocytes	30	%	20-45
Monocytes	03	%	2-10
Eosinophils	02	%	1-6
Basophils	00	%	0-1




Dr. SMRITI RATHORE MBBS MD
PATHOLOGY

Appointments

1800-309-0309

Emergencies

8821-818181



DEPARTMENT OF LABORATORY MEDICINE

MRN : 17540000321007 Department : GENERAL MEDICINE
 Name : Ranjeeta Jagne Specimen : blood
 Age / Sex : 34 Year(s) / Female Visit Type : OP
 Sample No : 1R2301140233 Collected On : 14/01/2023 11:13 AM
 Consulting DR : Dr. Mukesh Kumar Sharma Referred DR : Dr. Mukesh Kumar Sharma
 Patient Address : H NO 2 PHASE III KHUSHI VATIKA Received On : 14/01/2023 12:12 PM
 AMLIDIH Raipur Raipur Chhattisgarh,India Reported On : 14/01/2023 01:58 PM
 Report Type : Final

Test	Result	Unit	Biological Reference Interval
LIVER FUNCTION TEST(LFT)			
BILIRUBIN TOTAL	1.00	mg/dl	0-1.3
BILIRUBIN DIRECT	0.30	mg/dl	0-0.3
TOTAL PROTEIN	7.90	gm/dL	6.4-8.2
BILIRUBIN INDIRECT	0.70		
SERUM ALBUMIN	4.50	gm/dL	3.4-5
SERUM GLOBULIN	3.40		
ALBUMIN TO GLOBULIN (A/G)RATIO	1.32		1-2.1
SGOT (AST)	24.00	IU/L	15-37
SGPT (ALT)	33.00	IU/L	30-65
ALKALINE PHOSPHATASE (ALP)	104.00	IU/L	50-136
GAMMA GLUTAMYL TRANSFERASE (GGT)	21	U/L	5-85



(Handwritten Signature)

Dr. SMRITI RATHORE MBBS MD
PATHOLOGY

Appointments

1800-309-0309

Emergencies

8821-818181

NH MMI Narayana Superspeciality Hospital

(A Unit of Narayana Hrudayaleya Limited) CIN: L85110KA2000PLC027497

Registered Office: 258/A, Bommasandra Industrial Area, Anekal Taluk, Bangalore-560099

Hospital Address: New Dhamtari Road, Lalpur, Raipur 492001

Tel +91 771 4210901 / 902 | Fax +91 771 408 1106 | Email: info.rpr@narayanahealth.org | www.narayanahealth.org



DEPARTMENT OF LABORATORY MEDICINE Narayana Health

MRN	: 17540000321007	Department	: GENERAL MEDICINE
Name	: Ranjeeta Jagne	Specimen	: SERUM
Age / Sex	: 34 Year(s) / Female	Visit Type	: OP
Sample No	: 1R2301140234	Collected On	: 14/01/2023 11:13 AM
Consulting DR	: Dr. Mukesh Kumar Sharma	Referred DR	: Dr. Mukesh Kumar Sharma
Patient Address	: H NO 2 PHASE III KHUSHI VATIKA AMLIDIH Raipur Raipur Chhattisgarh,India	Received On	: 14/01/2023 12:12 PM
		Reported On	: 14/01/2023 03:37 PM
		Report Type	: Final

Test	Result	Unit	Biological Reference Interval
THYROID PROFILE (T3, T4, TSH)			
TRI IODO THYRONINE (T3)	1.49	ng/dL	0.6-1.81
THYROXINE (T4)	18.60 H	ug/dl	3.2-12.6
TSH (THYROID STIMULATING HORMONE)	0.04 L	mIU/mL	0.35-5.50



Signature

Dr. NEERAJ NAIKM.B.B.S D.C.P
CONSULTANT PATHOLOGIST

NH MMI Narayana Superspeciality Hospital

(A Unit of Narayana Healthcare Limited) CIN: L85110KA2000PLC227497

Registered Office: 258/A, Bommasandra Industrial Area, Anekal Taluk, Bangalore 560099

Hospital Address: New Dhantari Road, Lalpur, Raipur 492001

Tel: +91 771 4210901 / 902 | Fax: +91 771 408 1106 | Email: info.rpr@narayanahealth.org | www.narayanahealth.org



DEPARTMENT OF LABORATORY MEDICINE

MRN	: 17540000321007	Department	: GENERAL MEDICINE
Name	: Ranjceta Jagne	Specimen	: WHOLE BLOOD
Age / Sex	: 34 Year(s) / Female	Visit Type	: OP
Sample No	: 1R2301140235	Collected On	: 14/01/2023 11:13 AM
Consulting DR	: Dr. Mukesh Kumar Sharma	Referred DR	: Dr. Mukesh Kumar Sharma
Patient Address	: H NO 2 PHASE III KHUSHI VATIKA AMLIDIH Raipur Raipur Chhattisgarh,India	Received On	: 14/01/2023 12:12 PM
		Reported On	: 14/01/2023 02:37 PM
		Report Type	: Final

Test	Result	Unit	Biological Reference Interval
HBA1C			
HBA1C	5.0	%tage	

Reference Group HBA1c in %

Non diabetic Adult (18 years or more) < 5.7

At risk (Prediabetes) 5.7 - 6.4

Diagnosing Diabetes >= 6.5

Estimated Average Glucose	96.8	mg/dL	
---------------------------	------	-------	--



Signature

Dr. NEERAJ NAIKM.B.B.S D.C.P
CONSULTANT PATHOLOGIST



NH MMI Narayana Superspeciality Hospital

(A unit of Narayana Healthcare Limited) CIN: L8511DKA2000PLC07497

Registered Office: 258/A, Bommasandra Industrial Area, Anekal Taluk, Bangalore 560099

Hospital Address: New Dhamtari Road, Lalpur, Raipur 492001

Tel +91 771 4210901 / 902 | Fax +91 771 408 1106 | Email: info.rpr@narayanahealth.org | www.narayanahealth.org

Page 7 of 11

Appointments
1800-309-0309


Emergencies
8821-818181

DEPARTMENT OF LABORATORY MEDICINE

MRN : 17540000321007	Department : GENERAL MEDICINE
Name : Ranjeeta Jagne	Specimen : URINE
Age / Sex : 34 Year(s) / Female	Visit Type : OP
Sample No : 7R2301140062	Collected On : 14/01/2023 11:13 AM
Consulting DR : Dr. Mukesh Kumar Sharma	Referred DR : Dr. Mukesh Kumar Sharma
Patient Address : H NO 2 PHASE III KHUSHI VATIKA AMLIDIH Raipur Raipur Chhattisgarh,India	Received On : 14/01/2023 12:12 PM
	Reported On : 14/01/2023 12:32 PM
	Report Type : Final

CLINICAL PATHOLOGY

Test	Result	Unit	Biological Reference Interval
URINE ROUTINE & MICROSCOPY			
PHYSICAL EXAMINATION			
VOLUME	25	ml	
COLOUR	Pale yellow		
APPEARANCE	Slightly turbid		
SP. GRAVITY	1.005		1.002-1.03
CHEMICAL EXAMINATION			
pH(REACTION)	5.5 ↓		4.8-7.5
PROTEIN	Negative		Negative
URINE GLUCOSE	Negative		Negative
KETONE BODIES	Negative		Negative
BILE SALTS	Negative		Negative
BILE PIGMENT (BILIRUBIN)	Negative		Negative
UROBILINOGEN	Negative		
BLOOD URINE	Negative		Negative
URINE LEUCOCYTE ESTERASE	Negative		Negative
MICROSCOPIC EXAMINATION			
NITRITE	Negative		Negative


DEPARTMENT OF LABORATORY MEDICINE

MRN	: 17540000321007	Department	: GENERAL MEDICINE
Name	: Ranjeeta Jagne	Specimen	: URINE
Age / Sex	: 34 Year(s) / Female	Visit Type	: OP
Sample No	: 7R2301140062	Collected On	: 14/01/2023 11:13 AM
Consulting DR	: Dr. Mukesh Kumar Sharma	Referred DR	: Dr. Mukesh Kumar Sharma
Patient Address	: H NO 2 PHASE III KHUSHI VATIKA AMLIDIH Raipur Raipur Chhattisgarh,India	Received On	: 14/01/2023 12:12 PM
		Reported On	: 14/01/2023 12:32 PM
		Report Type	: Final

CLINICAL PATHOLOGY

Test	Result	Unit	Biological Reference Interval
PUS CELLS	4-6	hpf	0-2
RBC	2-3	hpf	0-3
EPITHELIAL CELLS	<u>2-3</u> L	hpf	2-3
CRYSTALS	Not seen		
CASTS	Not seen		OCC HYALINE CAST / HPF



Dr. SMRITI RATHOREMBBS MD
PATHOLOGY

NH MMI Narayana Superspeciality Hospital

(A Unit of Narayana Hrudayalewa Limited) CIN: L85110KA2000PLC027497

Registered Office: 258/A, Bommasandra Industrial Area, Anekal Taluk, Bangalore 560099

Hospital Address: New Dhamtari Road, Lalpur, Raipur 492001

Tel: +91 771 4210901 / 902 | Fax: +91 771 408 1106 | Email: info.rpr@narayanahealth.org | www.narayanahealth.org

Page 9 of 11



1800-309-0309

8821-818181

Appointments

Emergencies

DEPARTMENT OF LABORATORY MEDICINE

MRN	: 17540000321007	Department	: GENERAL MEDICINE
Name	: Ranjeeta Jagne	Specimen	: SERUM
Age / Sex	: 34 Year(s) / Female	Visit Type	: OP
Sample No	: IR2301140232	Collected On	: 14/01/2023 11:13 AM
Consulting DR	: Dr. Mukesh Kumar Sharma	Referred DR	: Dr. Mukesh Kumar Sharma
Patient Address	: H NO 2 PHASE III KHUSHI VATIKA AMLIDIH Raipur Raipur Chhattisgarh,India	Received On	: 14/01/2023 12:12 PM
		Reported On	: 14/01/2023 01:57 PM
		Report Type	: Final

Test	Result	Unit	Biological Reference Interval
RENAL PACKAGE - 2 (RFT FASTING)			
SERUM CREATININE			
SERUM CREATININE	0.6	mg/dl	0.6-1.2
eGFR	111.57	mL/min/1.73m2	
BLOOD UREA NITROGEN (BUN)	7.00	mg/dl	7-20
SODIUM, SERUM	144.00	mmol/L	135-150
POTASSIUM, SERUM	4.40	mmol/L	3.5-5
CHLORIDE	106.00	mmol/L	95-106
CALCIUM	9.00	mg/dl	8.5-10.1
MAGNESIUM	1.70 L	mg/dL	1.8-2.4
URIC ACID	5.70	mg/dl	2.6-6
PHOSPHORUS	3.90	mg/dl	2.6-4.7
FASTING BLOOD SUGAR (FBS)	84.00	mg/dl	70-99

Note:
Abnormal results are highlighted.
Results relate to the sample only.
Kindly correlate clinically.



(Signature)

Dr. SMRITI RATHOREMBBS MD
PATHOLOGY

Appointments

1800-309-0309

Emergencies

8821-818181

NH MMI Narayana Superspeciality Hospital

(A Unit of Narayana Healthcare Limited) CIN: L85110KA2300PL0027497

Registered Office: 258/A, Bommasandra Industrial Area, Anekal Taluk, Bangalore-560095

Hospital Address: New Dhamtari Road, Lalpur, Raipur 492001

Tel +91 771 4210901 / 902 | Fax +91 771 408 1106 | Email: info.rpr@narayanahealth.org | www.narayanahealth.org



DEPARTMENT OF PATHOLOGY LAB

MRN	: 17540000321007	Department	: GENERAL MEDICINE
Name	: Ranjeeta Jagne	Specimen	: blood,PLASMA,SERUM,Stool,SWA B,URINE,WHOLE BLOOD
Age / Sex	: 34 Year(s) / Female	Visit Type	: OP
Sample No	: 0,1R2301140231,1R2301140232,1R230114 0233,1R2301140234,1R2301140235,22301 140125,22301140126,7R2301140062,92301 140003	Collected On	: 14/01/2023 11:13 AM
Consulting DR	: Dr. Mukesh Kumar Sharma	Referred DR	: Dr. Mukesh Kumar Sharma
Patient Address	: H NO 2 PHASE III KHUSHI VATIKA AMLIDIH Raipur Raipur Chhattisgarh,India	Received On	: 14/01/2023 12:12 PM
		Reported On	: 14/01/2023 03:19 PM
		Report Type	: Final

HISTOPATHOLOGY

EHP MEDIWHEEL FULL BODY HEALTH CHECK PACKAGE FEMALE BELOW 40 YRS

PAP SMEAR

GENERAL CATEGORIZATION	Smear show superficial and intermediate squamous epithelial cells in background of mild inflammatory cells. No intra epithelial lesion or malignant cells. No malignant cells seen.
MATERIAL RECEIVED	Received one unstained smear.
SPECIMEN TYPE	Pap smear.
IMPRESSION	Normal smear. Correlate Clinically.
Lab No	2023/C/29

-- End of Report --

Result Entered by



Dr. NEERAJ NAIK.M.B.B.S D.C.P
CONSULTANT PATHOLOGIST



ID: 321007
Name: RANJEETA JAGNE
Age: 34 Years
Gender: Female

2023-01-14 11:04:53

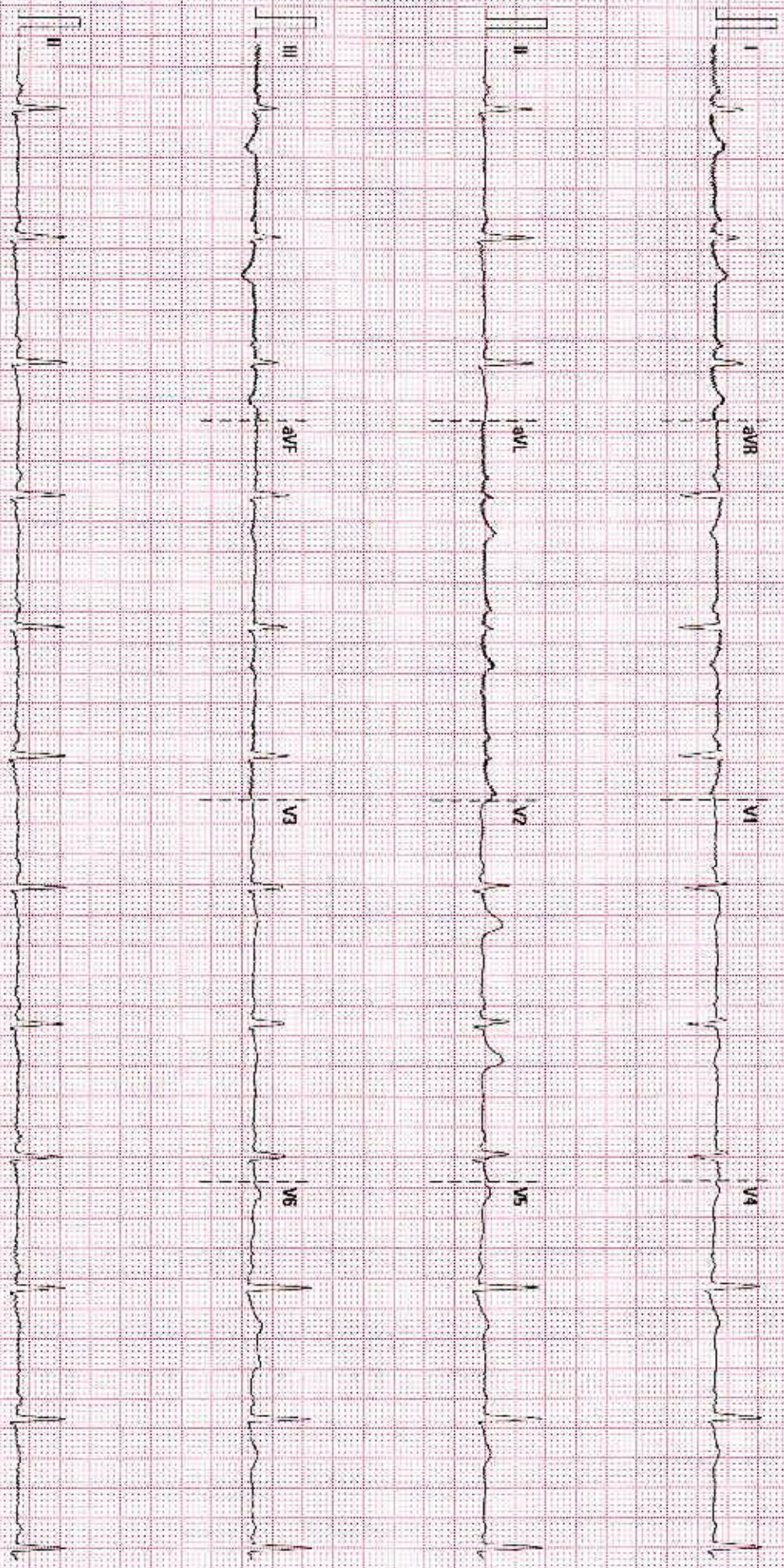
Vent. Rate
PR Interval
QRS Duration
QT/QTc Interval
P/QRS/T Axes
Dr: Hodges

69 bpm
144 ms
78 ms
368/384 ms
0/51/-23 deg

Sinus rhythm
Inferior T wave abnormality is borderline for age and gender
Borderline ECG

Unconfirmed Diagnosis

"Please Xerox this Copy"



25 mm/s

10 mm/mV

50 Hz

808 35 Hz

RAJAWADE SUPER SPECIALITY HOSPITAL, MUMBAI

02:10:00 V28.4.1

SN:FN-11027135