



D. Iswarya
Age 26/Y/F

Bp! - 110/80 mm/Hg.

Date: 24/9/22

Dr. P. Lalitha

Dr. K. Harish

Dr. K. HARISH KATRAGADDA
MBBS, MD,
Regd No (849)
Consultant Physician & Diabetologist
SENTINI HOSPITALS PVT. LTD.,
54-15-5, B & C, Beside Vinayaka Theatre
Ring Road, VIJAYAWADA-520 008

patient come for health check up

No speech complaints
at present

Adu

1 month x ① 1. orofen - XT
or 1-0

→ Hh



Department Of Laboratory

Date :

Name : Mrs. ISWARYA .DUPAGUNTLA	Age /Sex : 26 Y(s)/Female
Bill Date : 24-Sep-2022 09:44 AM	UMR No. : UMR2213293
Rept. Dt : 24-Sep-2022 12:56 PM	Bill No. : BIL22019751
Ref By : Dr.GENERAL HEALTH CHECK UP	Result No : 0 / RES22021073

<u>Parameter</u>	<u>Result</u>	<u>Normal Values</u>
HB A1C	: 5.1 %	Non Diabetic : < 6.0 % Good Control : 6.0 - 7.5 % Fair control : 7.5 - 8.5 % Poor Control : > 8.5 %
Post Prandial Blood Sugar	: 120 mg/dl	80 - 199 mg/dl
TFT (THYROID FUNCTION TEST)		
T3 (TRI IODO THYRONINE)	: 132 ng/dl	80 - 200 ng/dl
T4 (THYROXINE)	: 9.6 ug/dl	5.1 - 14.1 ug/dl
TSH (THYROID STIMULATING HORMONE)	: 2.78 mIU/l	0.3 - 4.2 mIU/l

*** End Of Report ***


Lab Tech.

Correlate Clinically

Bio-Chemist

Lab In-Charge

Incharge Pathologist

We use only sterilised disposable syringes & needles.

This report is to help you for better management of patient and not valid for medicolegal purpose.

Discrepancies due to technical or typing errors should be reported within 3 days for correction.



Department Of Laboratory

Date :

Name : Mrs. ISWARYA .DUPAGUNTLA	Age /Sex : 26 Y(s)/Female
Bill Date : 24-Sep-2022 09:44 AM	UMR No. : UMR2213293
Rept. Dt : 24-Sep-2022 11:42 AM	Bill No. : BIL22019751
Ref By : Dr.GENERAL HEALTH CHECK UP	Result No : 0 / RES22021045

Parameter	Result	Normal Values
LFT(LIVER FUNCTION TEST)		
Total Bilirubin	: 0.6 mg/dl	0.1 - 1.2 mg/dl
Direct Bilirubin	: 0.1 mg/dl	0.0 - 0.3 mg/dl
Indirect Bilirubin	: 0.5 mg/dl	
SGOT	: 19 IU/L	5 - 55 IU/L
SGPT	: 24 IU/L	5 - 55 IU/L
Alkaline Phosphatase	: 53 IU/L	Adult : 35 - 125 IU/L Children : 125 - 330 IU/L
Total Protein	: 6.7 gm/dl	6.0 - 8.3 gm/dl
Albumin	: 3.7 gm/dl	3.2 - 5.0 gm/dl
Globulin	: 3.0 gm/dl	2.5 - 3.0 gm/dl
A / G RATIO	: * 1.2	1.51 - 1.81
CBC (COMPLETE BLOOD COUNT)		
HAEMOGLOBIN	: * 9.8 g/dl	11.5 - 16.0 g/dl
Total WBC Count	: 4,000 cells/cumm	4000 - 11000 cells/cumm
DC COUNT		
Neutrophils	: 70 %	50 - 70 %
Lymphocytes	: 25 %	15 - 40 %
Eosinophils	: 03 %	0 - 7 %
Monocytes	: 02 %	0 - 4 %
Basophils	: 00 %	0 - 1 %
RBC COUNT	: * 3.2 millions/cumm	4.5 - 6.5 millions/cumm
PLATELET COUNT	: 2.0 lakhscells/cumm ✓	1.5 - 4.0 lakhscells/cumm

*** End Of Report ***

Lab Tech.

Bio-Chemist

Lab In-Charge

Incharge Pathologist

Correlate Clinically, We use only sterilised disposable syringes & needles.

Discrepancies due to technical or typing errors should be reported within 3 days for correction.

This report is to help you for better management of patient and not valid for medicolegal purpose.



Department Of Laboratory

Date :

Name : Mrs. ISWARYA .DUPAGUNTLA
Bill Date : 24-Sep-2022 09:44 AM
Rept. Dt : 24-Sep-2022 11:42 AM
Ref By : Dr.GENERAL HEALTH CHECK UP

Age /Sex : 26 Y(s)/Female
UMR No. : UMR2213293
Bill No. : BIL22019751
Result No : 0 / RES22021045

<u>Parameter</u>	<u>Result</u>	<u>Normal Values</u>
Fasting Blood Sugar	: 90 mg/dl	70 - 110 mg/dl

RFT (RENAL FUNCTION TEST)

BLOOD UREA	: 21 mg/dl	13 - 45 mg/dl
Serum Creatinine	: 0.8 mg/dl	0.7 - 1.4 mg/dl

LIPID PROFILE

Fasting Blood Sugar	: 90 mg/dl	70 - 110 mg/dl
Total Cholesterol	: 184 mg/dl	150 - 240 mg/dl
Triglycerides	: 75 mg/dl	50 - 200 mg/dl
HDL Cholesterol	: 40 mg/dl	
LDL Cholesterol	: 129 mg/dl	80 - 160 mg/dl
VLDL	: 15 mg/dl	10 - 50 mg/dl
Cholesterol / HDL ratio	: 4.6	< 6
LDL / HDL	: 3.2	< 4

URINE ROUTINE EXAMINATION

Sugar	: Nil
Albumin	: Nil

Microscopic Examination

Pus cells	: 3-4 /HPF
Epithelial cells	: 1-2 /HPF
RBC	: Nil /HPF

Blood Grouping & Rh Typing : "O" POSITIVE

*** End Of Report ***

Lab Tech.

Bio-Chemist

Lab In-Charge

Incharge Pathologist

09-2022 11:07:45 AM

BPL

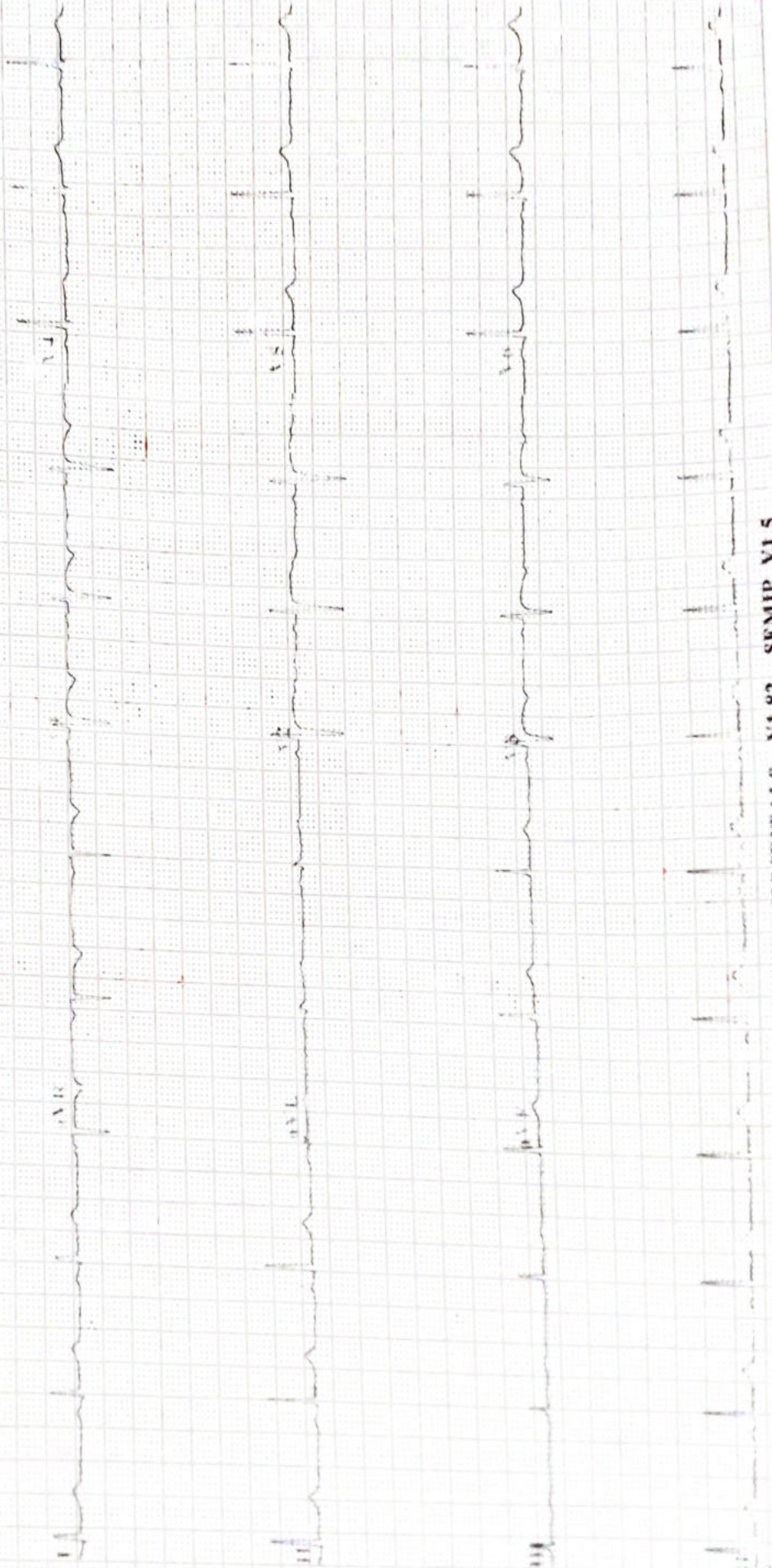ID
Name
Age
Years
Gender : Male

HR : 70
P Dur : 85 m
PR int : 129 m
QRS Dur : 82 ms
QT/QTc int : 387/419 ms
P/QRS/T axis : 30/53/44 °
RV5/SV1 amp : 1.150/0.835 mV
RV5+SV1 amp : 1.994 mV
RV6/SV2 amp : 1.073/0.922 mV

Diagnosis Information:
300 Sinus Rhythm
Normal ECG***

Mrs. D. Iswarya
age 26 y/f

Report Confirmed by:





Sentini Hospitals (P) Limited
Cardiology Department

ECHOCARDIOGRAM REPORT

Name : MRS D.ISWARYA UMR/OP/IP No : 2213293
Age : 26 Years Sex : F
Date : 24/09/2022 Echo No : 407
Technician: Srinivas/Chetansai

MITRAL VALVE : Normal
AORTIC VALVE : Normal
TRICUSPID VALVE : Normal
PULMONARY VALVE : Normal
AORTA : 24 mm
LEFT ATRIUM : 31 mm
LEFT VENTRICLE : Normal
RWMA : No LV RWMA
IVS : 10 mm LV IDd : 45 mm
PW : 10 mm LVIDs : 30 mm
LV EF : 64 %
RIGHT ATRIUM : Normal
RIGHT VENTRICLE : Normal
PULMONARY ARTERY : Normal
PULMONARY VEINS : Normal
IAS : Intact
IVS : Intact
PERICARDIUM : Normal
PERICARDIAL EFFUSION : No Effusion

DOPPLER STUDY

MITRAL FLOW : E>A
TRICUSPID FLOW : TRJV- m/s TR Gr : mmHg RVSP: mmHg
AORTIC JET VELOCITY : 1.2 m/s AV Gr: mmHg
PULMONARY JET VELOCITY : 0.7 m/s
COLOUR DOPPLER : 1+ MR 1+ TR No AR No PR
IVC : Normal
SVC : Normal
OTHERS :
CONCLUSION : Normal Sized Cardiac Chambers,
No LV RWMA,
Trivial MR , TR , No PAH,
Normal LV Systolic Function
No Pericardial Effusion,
No Clot/Vegetation/Masses.

Dr. MADHURI MD.DM

CONSULTANT CARDIOLOGIST

Dr. A.RAVI KUMAR MD.DM

CONSULTANT CARDIOLOGIST

Dr. P.V. SIVA PRASAD MD. DM.FESC

CHIEF CARDIOLOGIST



D. ISWARYA

Date: 24/09/2022

Date :
UMR : 2213293

Age/Sex: 26Y/F

Ref :GENERAL

REAL TIME ULTRASONOGRAPHY OF THE ABDOMEN

LIVER: Normal in size, shape and outline. Parenchymal texture normal. No focal cystic or solid mass lesion. No intrahepatic biliary dilatation. Intrahepatic portion of IVC is normal.
Portal vein is normal. Porta hepatis is normal.

G. B: Normal.

C.B.D: Not dilated.

PANCREAS: Parenchymal texture normal. No ductal dilatation. No calculi.

SPLEEN: Normal in size & echotexture.

AORTA: Normal.

KIDNEYS: **Right kidney** measures 9.4 x 4.1cm .
Normal in size, shape and outline. Parenchymal texture normal.
Corticomedullary differentiation is well made out and is normal.
No evidence of calculi/ Hydronephrosis.

Left kidney measures 9.5 x 4.3cm
Normal in size, shape and outline. Parenchymal texture normal.
Corticomedullary differentiation is well made out and is normal.
No evidence of calculi / Hydronephrosis.

U.B: Normal.

UTERUS : Normal

OVARIES : Normal

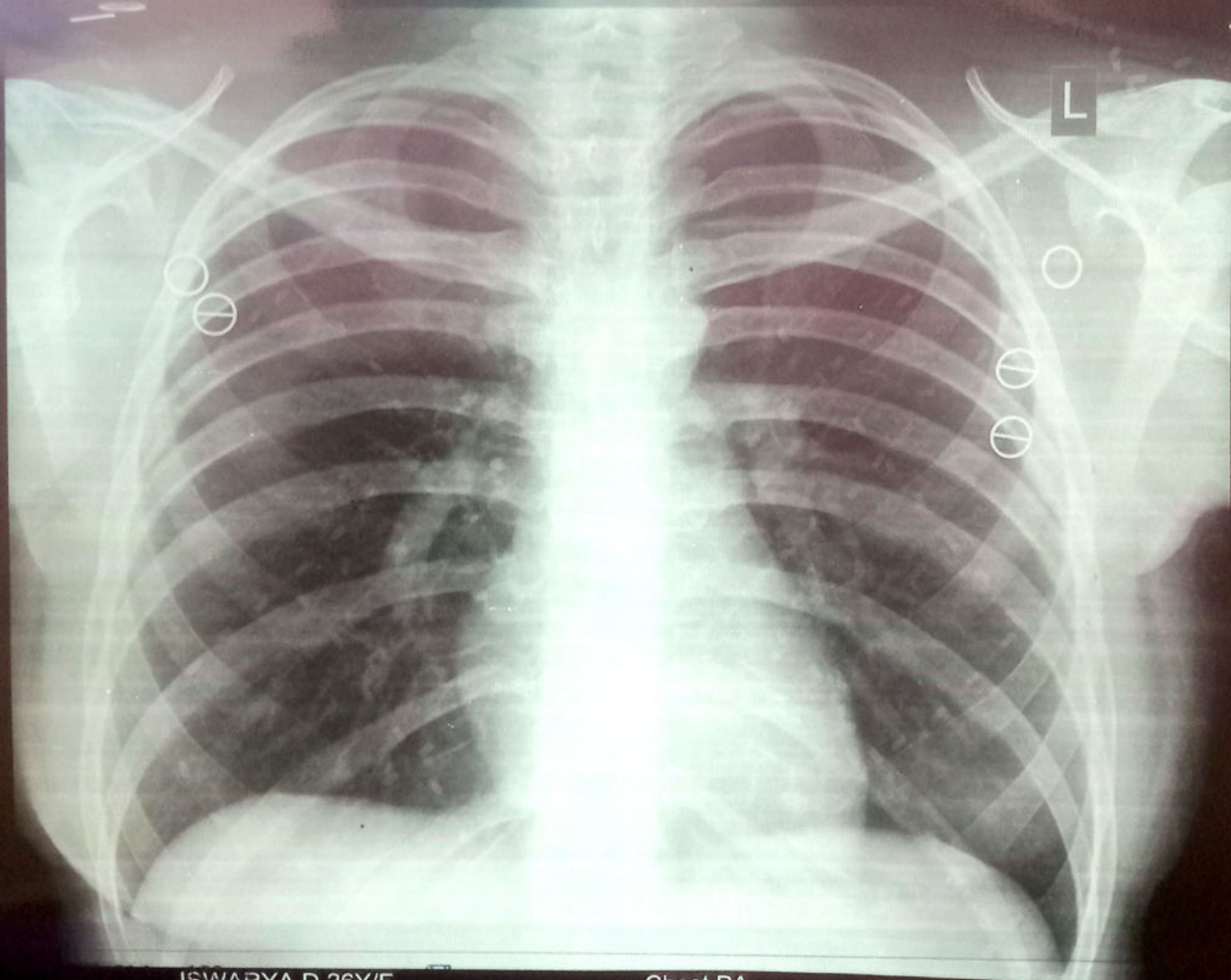
* No evidence of free fluid / lymphadenopathy.

IMPRESSION:

➤ **NORMAL STUDY.**

- For clinical correlation & follow up.


Dr. P.JAYA RAM MD RD.,
[Consultant Radiologist]



ISWARYA D 26Y/F
2213293

Chest PA
Female

DR. G H C

24-Sep-22 10:48:33 AM

SENTINI HOSPITALS, VIJAYAWADA.