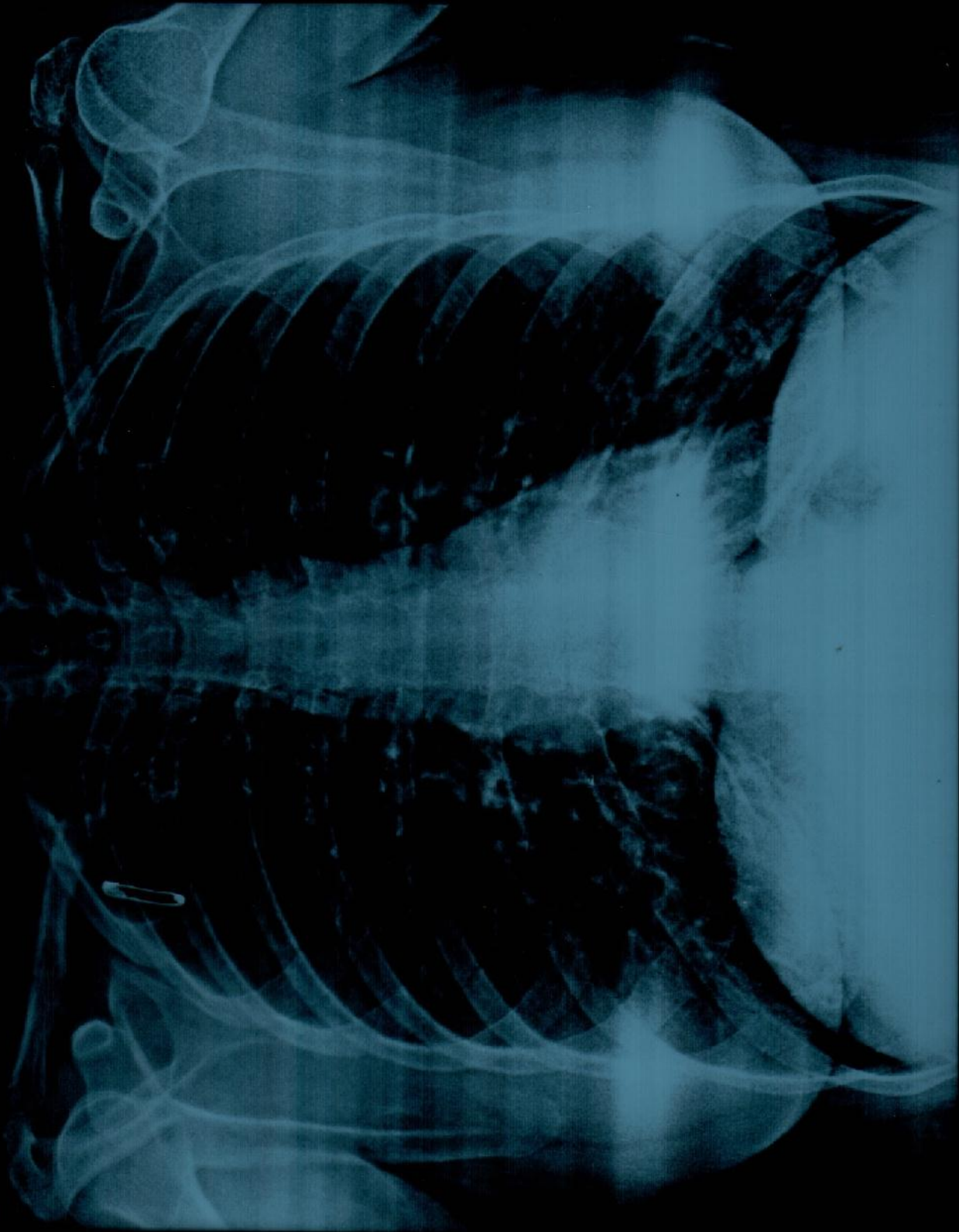


Fujifilm

R



MRS. PRANITA JOSHI 36 YRS CHEST PA 10-JUL-21

SADGURU HOSPITAL NASHIK

- MULTI SPECIALITY
- CRITICAL CARE
- TRAUMA CARE CENTER

Patient Name : MRS PRANITA JOSHI	Patient ID : 0
Age : 36	Sex : Female
Referring Physician : Dr. SADGURU HOSPITAL	Date : July 10, 2021

X-RAY CHEST PA

MRS PRANITA JOSHI's plain P.A. Radiograph of chest shows :-

- Both lung fields show normal and equal radiolucency.
- There is no pulmonary parenchymal abnormal density.
- The broncho vascular markings show normal size and distribution.
- The hilar shadows are normal in size, position and density.
- Both Cardiophrenic and Costophrenic angles are clear.
- The Cardiac silhouette is within normal limits.
- Aortic shadow is normal.
- Rest of the visualized mediastinum shadows are normal.
- Both domes of diaphragms are normal.
- The visualised bony thorax is normal.

CONCLUSION : NO SIGNIFICANT ABNORMALITY NOTED IN THE CHEST P.A. VIEW RADIOGRAPH.



DR. Nikunj Kothia
MBBS, DMRD Reg -2009093218

