



NAME: MANJULABEN SOLANKI
REF.BY: PRAMUKH HOSPITAL

40YRS/F

DATE: 01/03/2022

U.S.G. OF ABDOMEN

Liver: appears normal in size & shows bright echopattern. No focal lesion is seen. No dilated IHBR is seen. Portal vein and CBD appear normal in course and caliber.

Gall bladder: is moderately distended & appears normal. No calculus, sludge or mass is seen. Gall bladder wall thickness appears normal.

Pancreas: appears normal in size & echopattern. No focal lesion is seen.

Spleen: appears normal in size and shows normal echotexture. No focal lesion is seen. Splenic vein appears normal.

Both Kidneys appear normal in size, position and echopattern.
C-M differentiation is well preserved on either side.
No calculus or hydronephrosis is seen on either side.
Cortical thickness appears normal on both sides.
No focal lesion is seen on either side.

Urinary bladder is moderately distended & appears normal. No calculus, internal echoes or mass is seen. Urinary bladder wall thickness appears normal.

Uterus appears normal in size & echopattern. No focal lesion is seen
Both ovaries appear normal.
No adnexal mass is seen on either side.

Para-aortic region appears normal.
No abdominal lymphadenopathy is seen.
Bowel loops appear normal in caliber & show normal peristalsis.
No abnormal dilatation of bowel loops or wall thickening is seen.
No fluid collection or lump formation is seen in RIF.
No ascites is seen.
No pleural effusion is seen on either side.

IMPRESSION:

- Fatty liver (Grade I).



DR. SANDIP MEVADA
M.D.

DR. ANIRUDDHSINH RAHEVAR
DMRD DNB

DR. RUCHIT SHAH
M.D.

DR. AMISHA PATEL
M.D.

DR. PRANAY PATEL
M.D.



NAME: MANJULABEN SOLANKI

40YRS/F

DATE: 01/03/2022

REF.BY: PRAMUKH HOSPITAL

X RAY CHEST PA VIEW

Both lung fields under vision appears normal.

No evidence of koch's lesion or consolidation is seen.

Both CP angles are clear.

Cardiac size is within normal limits.


Bony thoracic cage and both domes of diaphragm appears normal.

DR. SANDIP MEVADA
M.D.

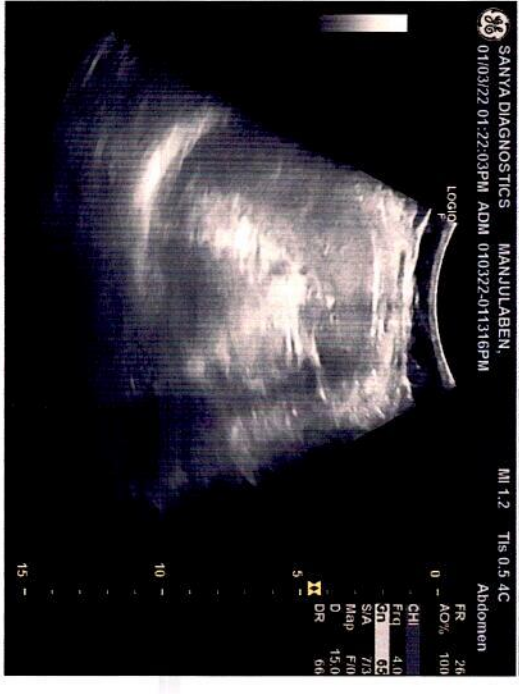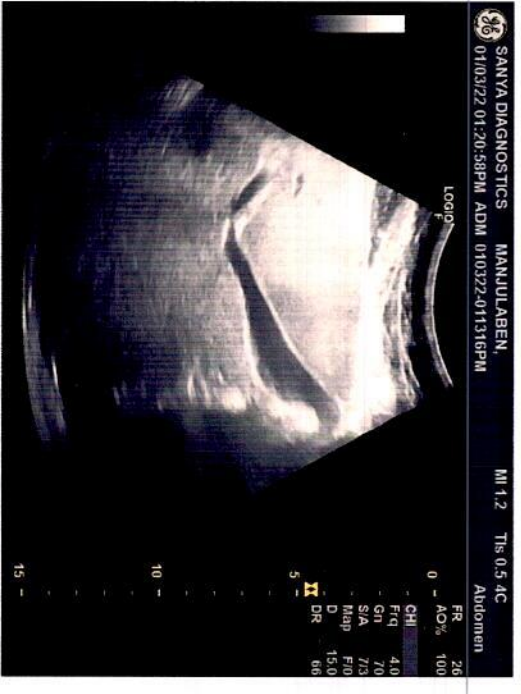
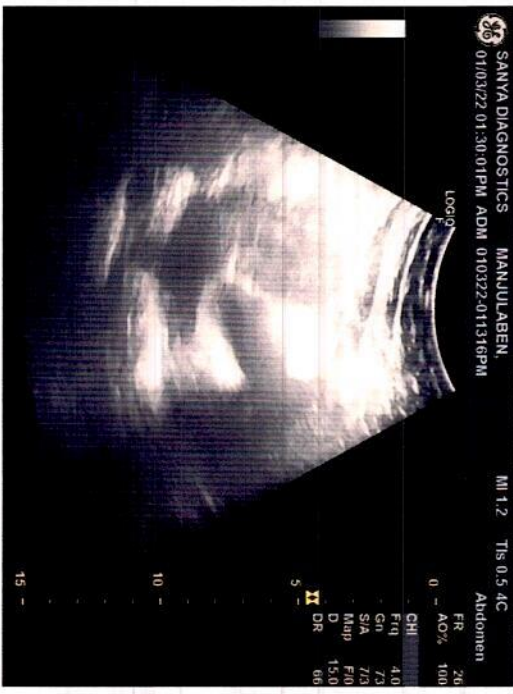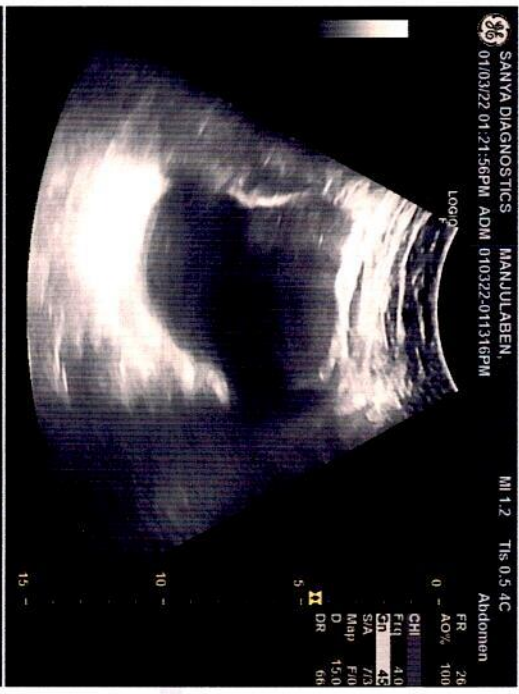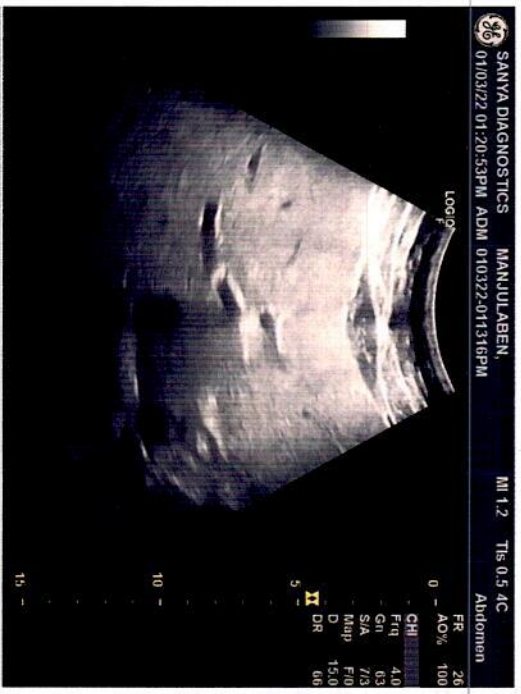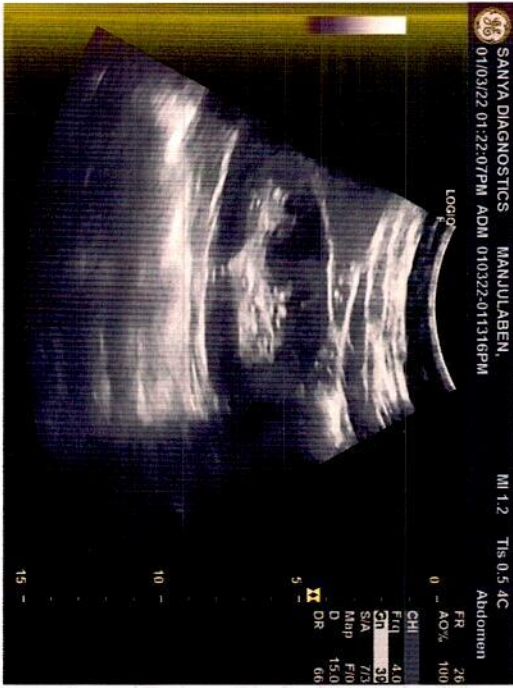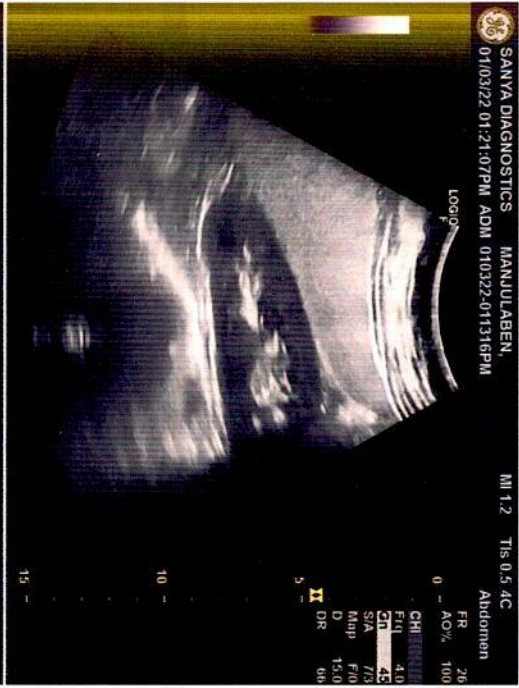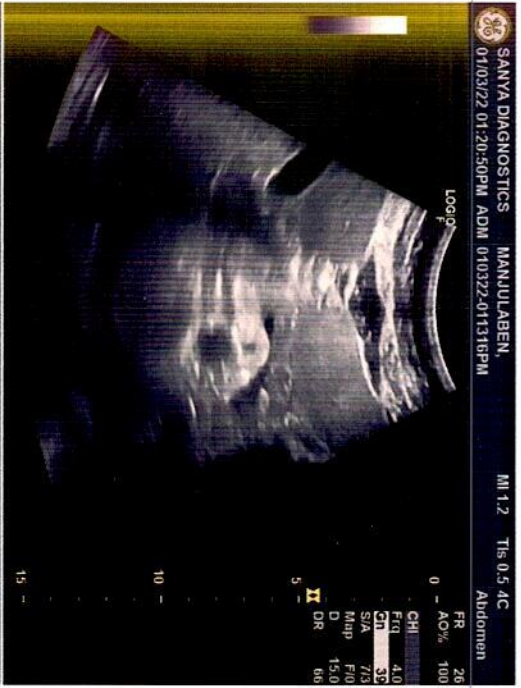DR. ANIRUDDHSINH RAHEVAR
DMRD DNB

DR. RUCHIT SHAH
M.D.

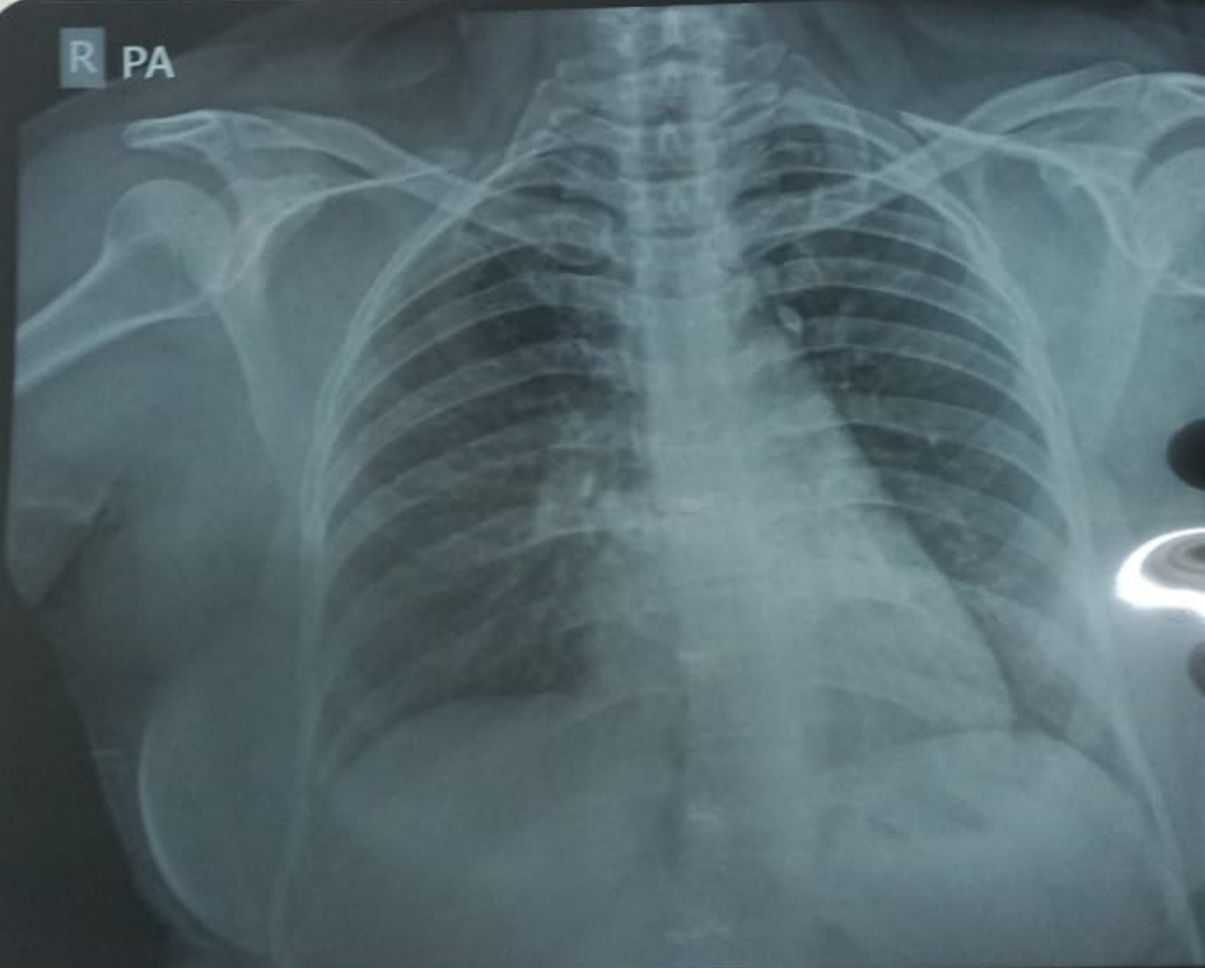
DR. AMISHA PATEL
M.D.


DR. PRANAY PATEL
M.D.





R PA



MANJULABEN SOLANKI 40/YRS Female

Chest PA

01/03/2022 11:56:45 AM

SANYA DIAGNOSTICS , MANINAGAR , AHMEDABAD.

