

Name Mrs. Poonam Kumari
 UHID : 13353188 Date : 28/08/24
 Age : 40 Gender : F
Nursing Assessment

Profile	
Height (cm) : <u>160cm</u>	Waist Circumference (cm) : <u>30 inch</u>
Weight (Kg.) : <u>72kg</u>	Body Mass Index : <u>28.1 kg/m²</u>
Occupation : <u>11070mmHg</u>	Marital Status <input type="checkbox"/> Single <input checked="" type="checkbox"/> Married

Vital Signs	
Pulse Rate (/min) : <u>76b/m</u> <u>S102-99.1</u>	Respiratory Rate (/min) :
Blood Pressure (mmHg) :	Temperature (if febrile) :

Past History	
<input checked="" type="checkbox"/> Hypertension :	<input checked="" type="checkbox"/> Diabetes :
<input checked="" type="checkbox"/> Heart disease :	<input checked="" type="checkbox"/> Dyslipidemia :
<input checked="" type="checkbox"/> Asthma :	<input checked="" type="checkbox"/> Tuberculosis :
<input checked="" type="checkbox"/> Allergies :	
<input type="checkbox"/> Others :	

For Women	
LMP: <u>29/08/24</u>	Last Pap smear done in <u>2022</u>
Menopause <input type="checkbox"/> Yes <input checked="" type="checkbox"/> No	Last Mammography done in
Consent for X-ray & Mammography	

Current Medications

Signature, Name and Emp. ID of the Nurse : _____

Name Mrs - Poojam Kumari
UHID : 13353188 Date 28/08/24
Age : 40 Gender : F

Internal Medicine Consultation

Relevant History:

Diagnosis:

Examination Findings:

Advice / Treatment Plan:

Investigations:

Signature and stamp of the Consultant: _____

Name Mrs Poonam Kumar
UHID : _____ Date : _____
Age : _____

28/8/24

Gynecology Consultation

Symptoms: No complaint.

Diagnosis:

Obstetric History:

GH - nil ML = 1 gm
No using OCPs

Advice / Treatment Plan:

Menstrual History:

MH = Reg
dy = 29/7/24

Past & Family History:

Not taking Rx
No H/O drug allergy
No FH family history

Examination Findings:

• Breast:

• P/A:

• P/S:

• PV:

pt in periods
Pap's not done

Investigations:

Name Mrs. Poonam Kaur
UHID : 13353/88 Date : 28/08/21
Age : 40 Gender : F

Ophthalmology Consultation

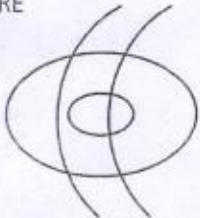History:

Examination findings:

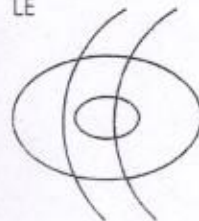Visual acuity $\begin{matrix} \text{R} \\ \diagup \\ \diagdown \\ \text{L} \end{matrix}$ Visual acuity with glasses $\begin{matrix} \text{R} \\ \diagup \\ \diagdown \\ \text{L} \end{matrix}$ Colour Vision $\begin{matrix} \text{R} \\ \diagup \\ \diagdown \\ \text{L} \end{matrix}$

Slit Lamp Examination

RE

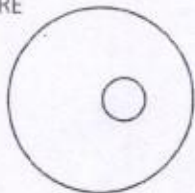


LE

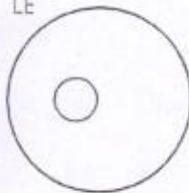


Fundus Examination

RE



LE



Diagnosis:

Treatment:

Spectacle prescription:

Right eye


	SPH	CYL	AXIS	VA
Distance				
Near				

Left eye

	SPH	CYL	AXIS	VA
Distance				
Near				

Signature and stamp of the Ophthalmologist : _____

TEST REQUEST FORM



TRF ID : 0080XH010317

TRF Date : 28-08-2024

PATIENT INFORMATION	
Name :	Ms. RANA KUMARI POONAM
Address :	,,AVNDH,Andaman and Nicobar Islands,
Phone No :	9805051222
Email :	
Date Of Birth :	10-11-1983
Age / Sex :	40 / Female
Height / Weight :	/

BILL TO	
Client Code :	C000138383
Client Name :	ARCOFEMI HEALTHCARE LTD (MEDIWHEEL
Address :	NEW DELHI
Phone No. :	8800465156
Email :	

ESSENTIAL CLINICAL INFORMATION	
Provisional Diagnosis :	
H / o Medication :	Yes / No
If Yes, Name :	
Status of Medication :	Ongoing / Terminated
If Ongoing, Duration :	
If Terminated, When :	
LMP (Where Applicable) :	
Fasting Period :	
24 Hour Urine Volume :	
For Histopathology / IHC, Attach Detailed History	
Attach Other Relevant Information :	

REFERRING DOCTOR	
Doctor Name :	SELF
Phone No :	
City :	
Email :	

SPECIMEN INFORMATION	
Patient Id / Hospital Id :	
SRL Id :	RANAF10118380
Date Drawn :	
Time Drawn(HRS) :	
Specimen Collected at :	

TEMP SENT	TEMP RECD.
<input type="checkbox"/> Frozen(< - 10 Celcius)	<input type="checkbox"/> Frozen(< - 10 Celcius)
<input type="checkbox"/> Cold(2 - 8 Celcius)	<input type="checkbox"/> Cold(2 - 8 Celcius)
<input type="checkbox"/> Ambient	<input type="checkbox"/> Ambient

Rcvd In :Agilus Diagnostics Ltd-Chandigarh	
Date :	
Time :	

FOR REPEAT/FOLLOW-UP PATIENTS	
Old Accession No. :	
SRL Care Code No. :	

Product Details

HM7235D	MEDI WHEEL FULL BODY HEALTH CHECKUP ABOVE 40FEMALE
---------	--

Specimen Details

SERUM
SMEAR
STOOL
URINE
OTHERS (FX)
EDTA WHOLE BLOOD
FASTING PLASMA FL.

Please Note: After completion of the ordered tests, the remaining sample may be stored and used for research in medical sciences.

I agree

I don't agree

Signature / Thumb impression of patient
Date :

Signature of Requisitioner
Date :

Important : It is mandatory to provide all the requested information to enable accurate and timely reporting.

NAME: Mrs. POONAM KUMARI**AGE AND SEX:40Y/F****UHID NO: 13353188****DATE: 28/08/2024****ROI: WHOLE ABDOMEN**

Liver is normal in size, outline and echogenicity. No focal lesion seen. IHBR's are not dilated. Portal vein and hepatic veins are normal.

Gall bladder is normally distended with anechoic lumen. Wall thickness is normal. No calculus / focal lesion seen. No pericholecystic fluid / collection seen. CBD is normal.

Pancreas is visualized in region of head and proximal body and is normal in size, shape, outline and echotexture. No focal lesion seen. Distal body and tail are obscured by bowel gases

Spleen is normal in size, outline and echotexture. No focal lesion

Right kidney is normal in size, outline and echogenicity. Cortico-medullary differentiation is maintained. No hydronephrosis / calculus is seen

Left kidney is normal in size, outline and echogenicity. Cortico-medullary differentiation is maintained. No hydronephrosis / calculus is seen. Few concretions are seen in the lower calyx.

Retroperitoneum is normal.

The urinary bladder is fully distended with normal outline and wall thickness. No calculus / SOL seen.

Uterus is normal in size, shape and outline. Endometrium is normal. A small fibroid is seen in the anterior wall of size 9 mm

Bilateral ovaries are normal in size, shape and echotexture.

No free fluid is seen in POD.

**Opinion: Left Renal Concretions
Small Intrauterine Fibroid**

Suggested clinical correlation.

Dr. ADITI PANWAR
PMC - 41230
Consultant Radiologist

POONAM KUMARI 40 F

Study Date: 28/08/2024

Patient ID: 13353188

Accession #:

Alt ID:

DOB:

Age:

Gender: F

Ht:

Wt:

BSA:

Institution: Fortis MEDCENTRE, Chandigarh

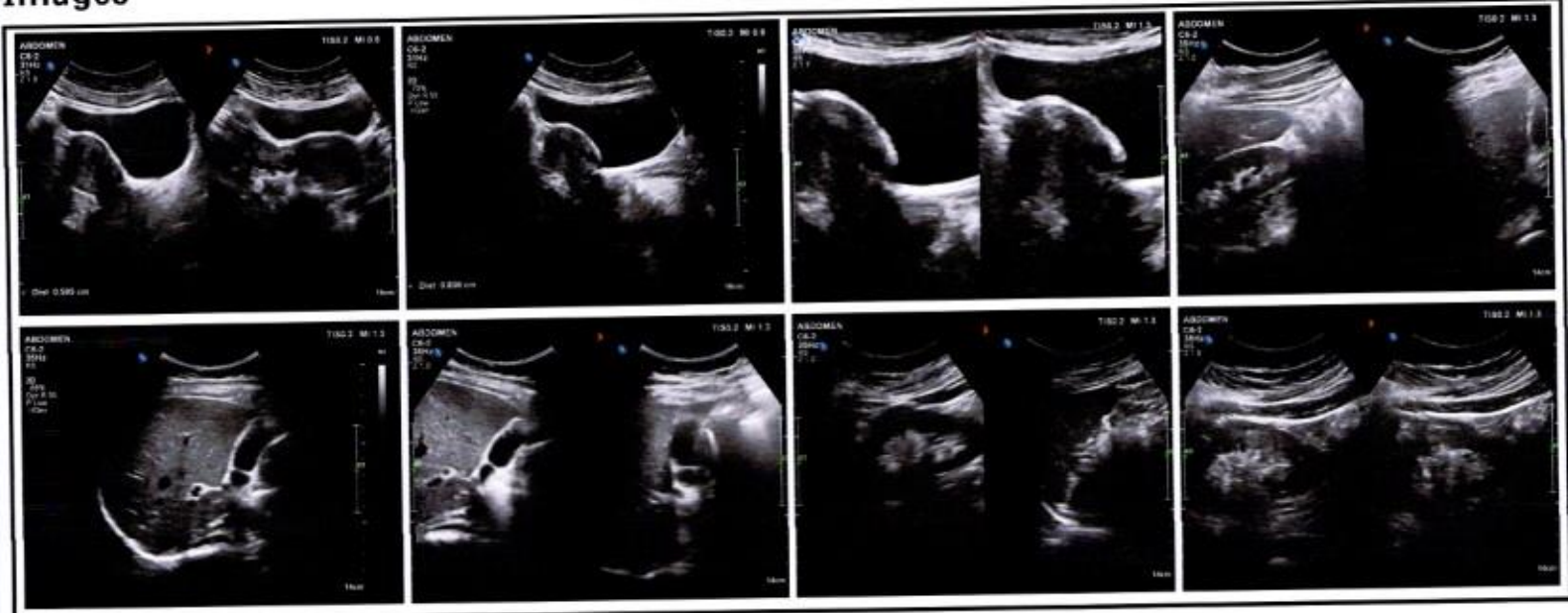Referring Physician:

Performed By:

Physician of Record:

Comments:

Images



Signature

Signature:
Name(Print):

Date:

DEPARTMENT OF FMC-RADIOLOGY LAB

Date: 28/Aug/2024

Name: Mrs. Poonam Kumari

UHID | Episode No : 13353188 | 13390/24/10021

Age | Sex: 40 YEAR(S) | Female

Order No | Order Date: 10021/PN/OP/2408/34277 | 28-Aug-2024

Order Station : FRONTOFFICE-FMC

Admitted On | Reporting Date : 28-Aug-2024 12:16:35

Bed Name :

Order Doctor Name : Dr.SELF .

CHEST X-RAY (PA VIEW)

Both the domes of diaphragm are normal.

Both costophrenic angles are normal.

Both lung fields are clear.

Cardiac size and silhouette are normal.

Both hila and mediastinum are normal.

Bony cage and soft tissues are normal.

IMPRESSION: NORMAL STUDY.

Please correlate clinically and with other relevant investigations.

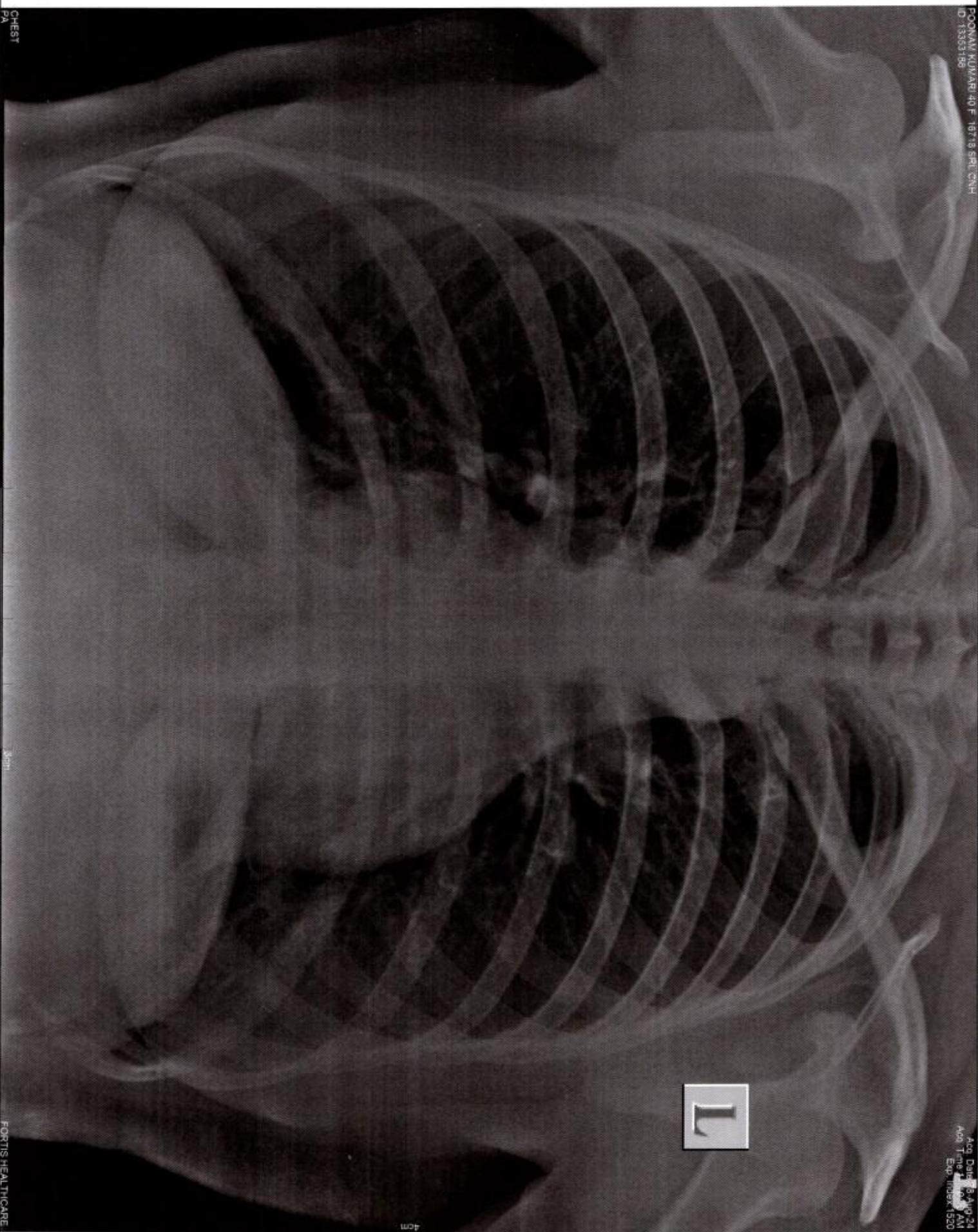
Dr. ADITI PANWAR

PMC F 41230

Consultant Radiologist

POONAM KUMARI/40 F 18718 SPL CNH
ID: 13353186

CHEST
PA



L

Acq. Date: 15-Aug-24
App. Type: A
Exp. Index: 1520

4cm

FORTIS HEALTHCARE

GE

MAC600 1.02

20030887-001

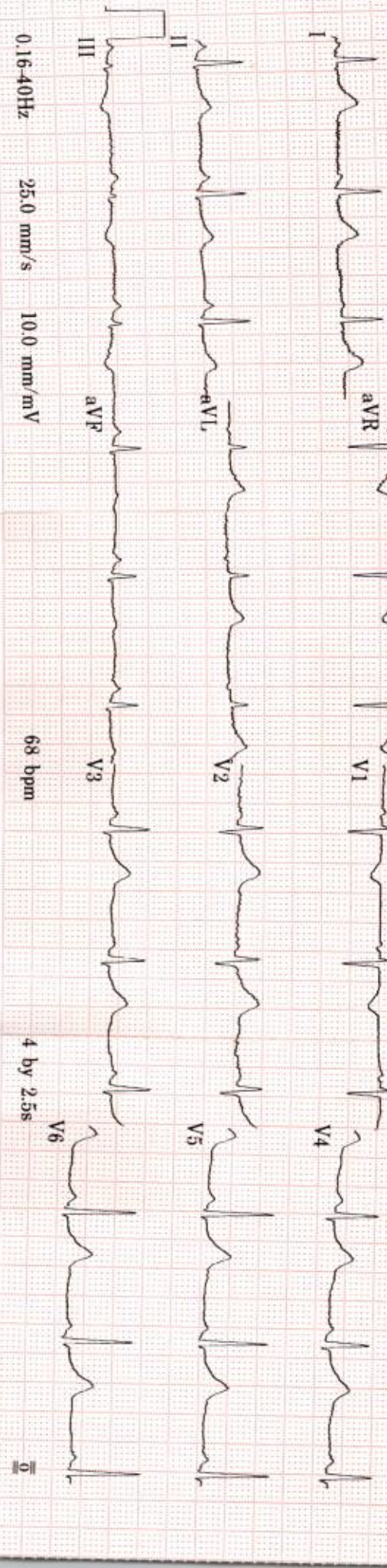
CE 0837

LOT# 575

ID: 0000000013353188

28-Aug-2024 11:06:51

Vital Signs™



0.16-40Hz 25.0 mm/s 10.0 mm/mV

68 bpm

4 by 2.5s

II

2030887-001

CE 6837

ETHIO 575

ID: 00000000013353188

Poonam Kumari

Female | 40yrs

Normal sinus rhythm
Normal ECG

Vent. rate	68 bpm
QRS duration	70 ms
QT/QTc	440/467 ms
PR interval	126 ms
P duration	94 ms
RR interval	882 ms
P-R-T axes	73 36 6

MAC600 1.02

12SL™ v239

MAC600 1.02

12SL™ v239