

PATIENT NAME : MR. SENTHAMARAI KANNAN	AGE / SEX : 30 Yrs / MALE
REF. By : ANNAMALAIYAR LAB	DATE : 03.07.2021

## USG WHOLE ABDOMEN

**LIVER** : Normal in size with normal echotexture. No evidence of intra / extrahepatic biliary tree dilatation noted. Portal and hepatic veins appear normal .

**GALL BLADDER** : Adequately distended. No evidence of abnormal wall thickening noted

**SPLEEN** : Appears normal in size, with no focal parenchymal lesions identified.

**PANCREAS**: Appears normal.

**KIDNEYS**: Right kidney measures ~ 10.6 x 5.2 cm. Left kidney measures ~ 10.4 x 5.0 cm.

Parenchymal thickness and echopattern appears normal on both sides. Cortico medullary differentiation maintained. Both ureterovesicular junction appear normal.

**URINARY BLADDER**: Appears normal.

**PROSTATE**: Appear normal.

**PERITONEAL CAVITY** : Visualized bowel loops appear normal. No definite lymphadenopathy noted .

### IMPRESSION :

- **USG STUDY OF THE ABDOMEN SHOWS NO SIGNIFICANT ABNORMALITY.**

*Suggested clinical correlation & further evaluation.*



**DR. VENKATESWARAN MBBS MD (A)**  
MCI REG NO : 37001

**NOTE:** Impression is professional opinion, not a final diagnosis. This examination has its own limitations. This has to be correlated clinically with other tests. If there is a variance clinically examination may be repeated or reevaluated by other investigation. This report is not for medicolegal purpose .

# Abdomen Ultrasound Report

Name SENTHAMARAIKANNAN 30/M

Age

Gender Unknown

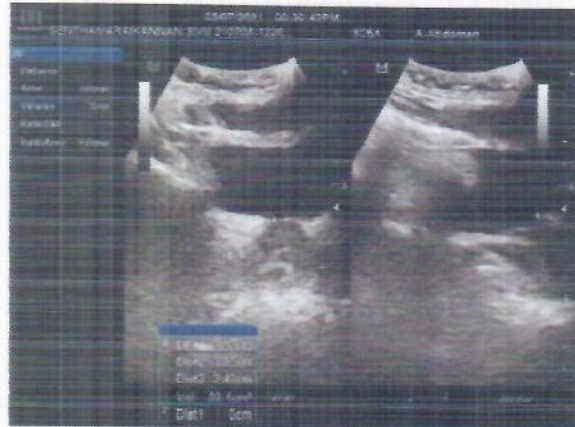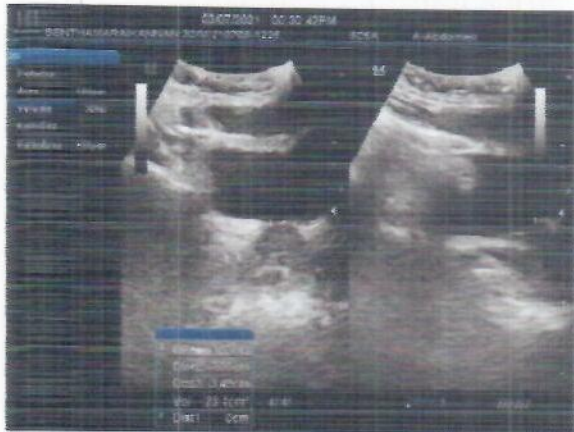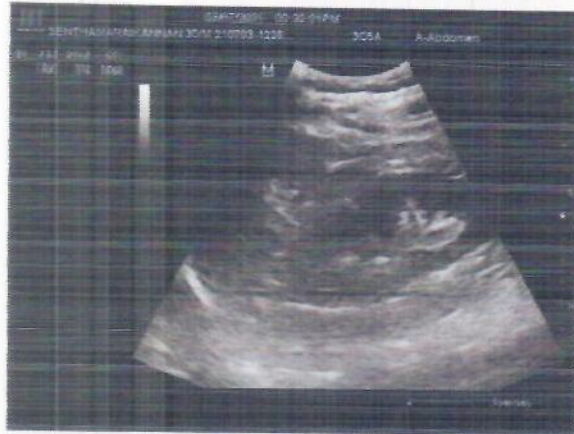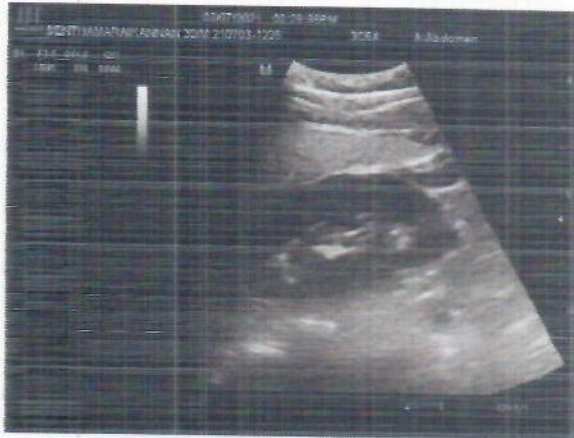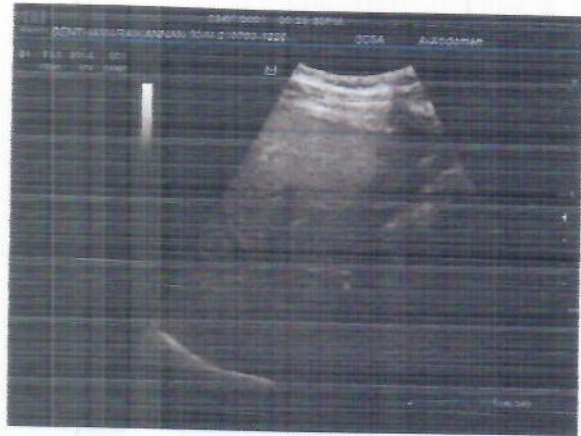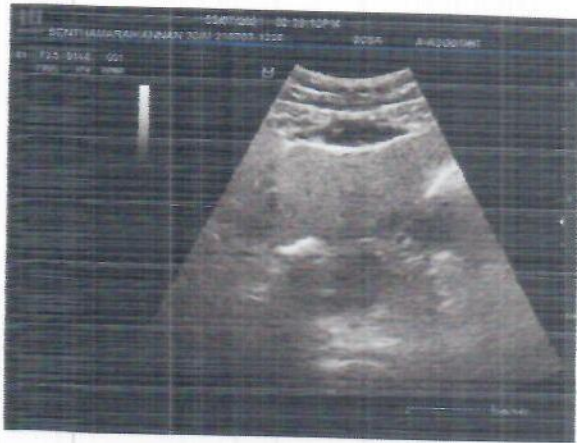ID 210703-122658-5FB6

Operator

Exam Date 03/07/2021

Height Weight

BSA



Comments:

Signature:

Exam Date: 03/07/2021

03/07/21,

**DR. S.V. VARAN**

MBBS, DOMS, FAIMS, FAMS, (VIENNA)

**CONSULTANT EYE SURGEON**

MCI REGD. NO 37001

EYE FITNESS CERTIFICATE FOR.

MR. SENTHAMANI KANNAN 30Yr.

BOTH EYES - DISTANCE Vn - 6/6. Nmal.

NEAR Vn - N5 Nmal.

Ant. & Post. Segments } - Nmal / Br

- Nmal.

FUNDUS

Color Vn.

Ngim Vn

FIELD OF Vn.

}  
}

Nmal / Br

△ Br PHYSIOLOGICALLY

Nmal

**Dr.S.V. வரன்**

MBBS DO MS FAIMS FAMS (வியன்னா)

80/40, சன்னதி வீதி,

(கருர் வைஸ்யா பேங்க் எதிரில்)

திருவள்ளூர் - 606 601.

[svvaran786@gmail.com](mailto:svvaran786@gmail.com)

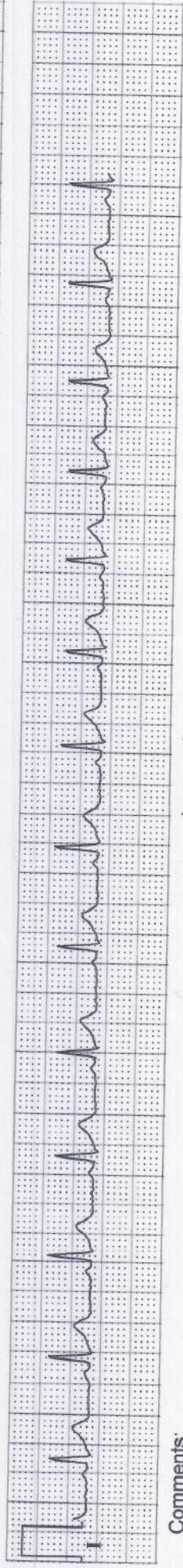
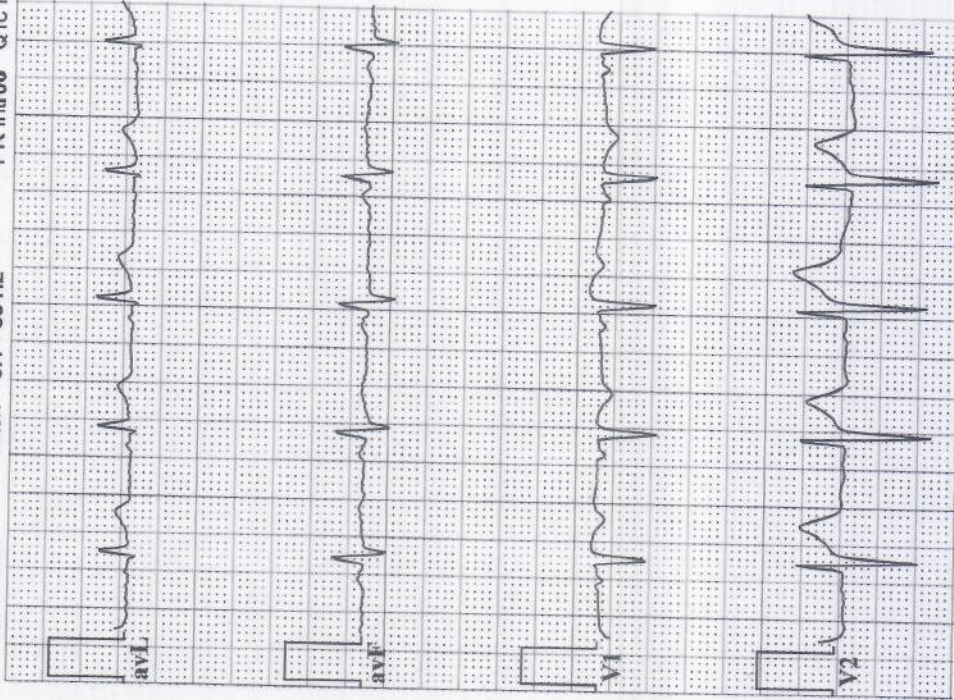
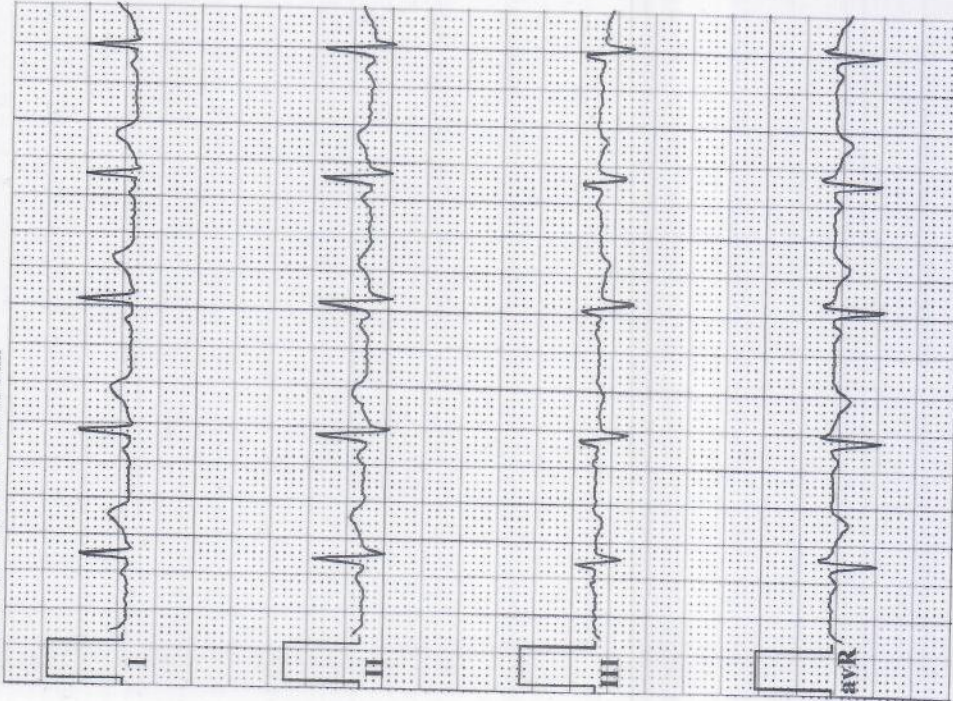
176  
30 Yrs/M  
Date: 03/07/2021 Time: 10:43 AM

SENTHAMARIKANNAN  
Kg / Ht- cms Ref. No.:

**ANNAMALAIYAR MEDICAL FOUNDATION**

79/156, BIG STREET, TIRUVANNAMALAI - 9489836877

Gain: 10 mm/mV  
Sweep: 25 mm/s  
Filter: 0.1 - 35 Hz  
Notch: On  
Hr: 98  
P Int: 48  
PR Int: 06  
QRS Int: 64  
QT Int: 306  
QTc Int: 391  
P Axis: 19  
QRS Axis: 46  
T Axis: 06  
Ref. By:  
Tech.:



Comments:

Impression:

*Normal* **Dr. K. BALARAMAN, M.D.**  
GENERAL MEDICINE