



# RAJASTHANI DIAGNOSTIC & MRI CENTRE

FULLY COMPUTERISED PATHOLOGY LABORATORY

MRI

CT SCAN

TMT

SONOGRAPHY

X-RAY

ECG

MAMMOGRAPHY

NAME : NEELAM	AGE /SEX : F
REF. BY : MEDIWHEEL	DATE: 14.05.2022

## X-RAY CHEST PA

- Both lung fields appear normal in under view
- No e/o consolidation or cavitations is seen.
- Both costo-phrenic angles appear clear.
- Cardiac size is within normal limits.
- Both domes of diaphragm appear normal.
- Bony thoracic cage & soft tissue shadow appear normal.

## IMPRESSION :- NORMAL X-RAY CHEST (PA)

**DR. B S GUPTA**

**MD RADIODIAGNOSIS**



आपताकालीन सेवाएं

THIS REPORT IS NOT VALID FOR MEDICO LEGAL PUPOSE





# RAJASTHANI DIAGNOSTIC & MRI CENTRE

FULLY COMPUTERISED PATHOLOGY LABORATORY

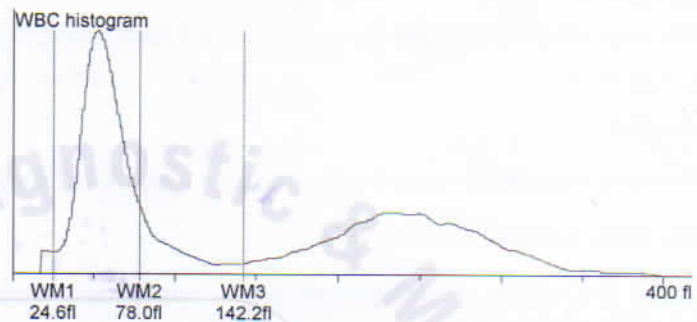
**MRI CT SCAN TMT SONOGRAPHY X-RAY ECG MAMMOGRAPHY**

Report date: 2022-05-14 10:51

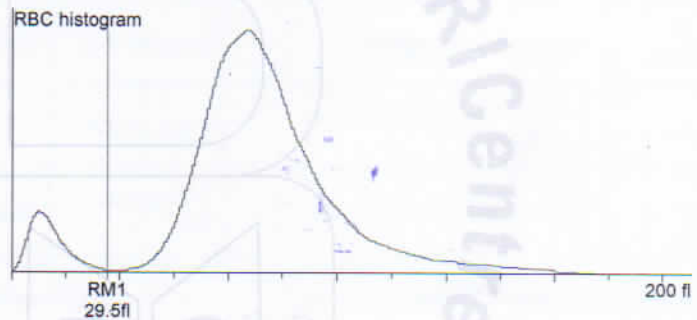
Patient ID: 39958 Birth date: 0000-00-00  
Name: NEELAM KUMARI Sex: Female

Measure type: Human Doctor: MEDI WHEEL INS  
Sample ID: 39019 Date: 2022-05-14


Parameter:	Result:	Limit:
WBC:	6.58 $10^9/l$	[4.00 - 11.00]
LYM:	3.27 $10^9/l$	[1.30 - 4.00]
MID:	0.19 $10^9/l$	[0.15 - 0.70]
GRA:	3.12 $10^9/l$	[2.50 - 7.50]
LYM%: +	49.70 %	[25.0 - 40.0]
MID%: -	2.90 %	[3.0 - 7.0]
GRA%: -	47.40 %	[50.0 - 75.0]



RBC:	4.30 $10^{12}/l$	[4.00 - 5.50]
HGB: -	8.90 g/l	[11.5 - 16.5]
HCT: -	34.28 %	[36.00 - 52.00]
MCV:	80.00 fl	[76 - 96]
MCH: -	20.80 pg	[27 - 32]
MCHC: -	26.10 g/l	[30 - 35]
RDWs: +	55.50 fl	[20.0 - 42.0]
RDWcv:	18.70 %	[0.0 - 0.0]



PLT:	350.00 $10^9/l$	[100 - 400]
PCT:	0.37 %	[0.00 - 0.00]
MPV:	10.60 fl	[8.0 - 15.0]
PDWs:	15.90 fl	[0.0 - 0.0]
PDWcv:	40.00 %	[0.0 - 0.0]



*Nida*  
Dr. NIDA FAHMI  
M.D.S. Pathology  
Reg. No. A-4048

Doctor:



आपताकालीन सेवाएं

THIS REPORT IS NOT VALID FOR MEDICO LEGAL PUPOSE











# RAJASTHANI DIAGNOSTIC & MRI CENTRE

FULLY COMPUTERISED PATHOLOGY LABORATORY

**MRI CT SCAN TMT SONOGRAPHY X-RAY ECG MAMMOGRAPHY**



## Laboratory Report

Name : **NEELAM KUMARI**  
Age : **26** Gender : **FEMALE**  
Ref. By Dr : **MEDI-WHEEL HEALTH CHECKUP**

Sr. Number : **39958**  
Invoice Date : **14-05-2022 10:47 AM**  
Registration No.: **11189**  
Print Date : **14-05-2022 03:20 PM**

### BIO-CHEMISTRY

Test Name	Observed Values	Reference Intervals	Units
Fasting Blood Sugar	80.0	60-110	mg/dL
Blood Sugar PP	109.0	60 - 140	mg/dL
Gamma glutamyl transferase (GGT)	20.0	15.0-85.0	IU/L

### Liver Function Test

Test Name	Observed Values	Reference Intervals	Units
SGOT/AST(Tech.:UV Kinetic)	23.0	5-40	U/L
SGPT/ALT(Tech.:UV Kinetic)	34.0	5-40	U/L
Bilirubin(Total)(Tech.:Jendrassik Grof)	0.79	0.1-1.1	mg/dL
Bilirubin(Direct)	0.20	0-0.3	mg/dL
Bilirubin(Indirect)	0.59	0.1-1.0	mg/dL
Total Protein(Tech.:Biuret)	6.94	6-8	gm/dL
Albumin(Tech.:BCG)	3.80	3.5-5	gm/dL
Globulin(CALCULATION)	3.14	2.5-4.5	gm/dL
A/G Ratio(Tech.:Calculated)	1.21	1.2 - 2.5	
Alkaline Phosphatase(Tech.:Pnp Amp Kinetic)	94.0	30-128	U/L

Dr. NIDA FAHMI  
M.D.S. Pathology  
No. A-4048

24  
SIGNATURE

Dr. Mamta Khuteta  
M.D. (Path.)  
BMC No. : 4720/16260

PATHOLOGIST

T&C : This Reports is Not Valid For Medico Legal Purposes. \* Identification and name of person is not our responsibility.  
આપતાકાલિન સેવા આ રિપોર્ટ શુદ્ધ છે. આ રિપોર્ટ પર કોઈ પણ પ્રકારનો મેડિકલ લેગલ કાર્યવાહી કરવામાં આવશે નહીં. ઉંમર, લિંગ, જાત, ડ્રગ અને અન્ય સંબંધિત પરિબલોને ધ્યાનમાં લેવાયા છે.













# RAJASTHANI DIAGNOSTIC & MRI CENTRE

FULLY COMPUTERISED PATHOLOGY LABORATORY

**MRI CT SCAN TMT SONOGRAPHY X-RAY ECG MAMMOGRAPHY**



## Laboratory Report

Name : **NEELAM KUMARI**  
Age : **26** Gender : **FEMALE**  
Ref. By Dr : **MEDI-WHEEL HEALTH CHECKUP**

Sr. Number : **39958**  
Invoice Date : **14-05-2022 10:47 AM**  
Registration No.: **11189**  
Print Date : **14-05-2022 03:20 PM**

### URINE EXAMINATION

#### URINE COMPLETE

Test Name	Observed Values	Reference Intervals	Units
<b>PHYSICAL</b>			
Quantity	20		ml
Colour	Dark Yellow		
Appearance / Transparency	S.Turbid		
Specific Gravity	1.020		
PH	5.50	4.5--6.5	
<b>CHEMICAL</b>			
Reaction	Acidic		
Albumin	+		
Urine Sugar	Nil		
<b>MICROSCOPIC</b>			
Red Blood Cells	Nil		/h.p.f.
Pus Cells	5--7		/h.p.f.
Epithelial Cells	6--8		/h.p.f.
Crystals	Nil		/h.p.f.
Casts	Nil		/h.p.f.
Bactria	Nil		/h.p.f.
Others	Nil		/h.p.f.
Test Name	Observed Values	Reference Intervals	Units
URINE SUGAR FASTING	Nil		
URINE SUGAR PP	Nil		

<<< END OF REPORT >>>

Dr. NIDA FAHMI  
M.D.S. Pathology  
No. A-4048

24  
SIGNATURE

Mamta Khuteta  
Dr. Mamta Khuteta  
M.D. (Path.)  
RMC No. : 4720/16260

PATHOLOGIST

T&C : \* This Reports is Not Valid For Medico Legal Purposes. \* Identification and name of person is not our responsibility.  
आपताकालीन समय  
relevant factor.

B-110, Indra Nagar, Jhunjhunu (Raj.) Ph. No. 01592 294977

132 (PKG1000228) / NEELAM / 26 Yrs / F / 158 Cms / 62 Kg Date: 14-May-2022 Technician : NEETU Examined By:

Stage	Time	Duration	Belt Speed (mph)	Elevation	NETS	Rate	% THR Achieved	BP	RPP	PVC	Comments
Supine	01:05	1:05	00.0	00.0	01.0	091	47%	126/86	114	00	
Standing	02:11	1:07	00.0	00.0	01.0	089	46%	126/86	112	00	
HV	03:16	1:06	00.0	00.0	01.0	082	42%	126/86	103	00	
Warm Up	04:25	1:09	00.0	00.0	01.0	094	48%	126/86	118	00	
ExStart	07:26	3:02	01.0	00.0	01.0	130	67%	130/90	169	00	
BRUCE Stage 1	10:26	3:00	01.7	10.0	04.7	156	80%	136/96	212	00	
PeakEx	11:17	0:51	02.5	12.0	05.4	155	80%	136/96	210	00	
Recovery	11:46	0:30	01.1	00.0	01.7	160	82%	136/96	217	00	
Recovery	12:16	1:00	00.0	00.0	01.0	146	75%	136/96	198	00	
Recovery	13:16	2:00	00.0	00.0	01.0	115	59%	132/92	151	00	
Recovery	14:16	3:00	00.0	00.0	01.0	119	61%	130/90	154	00	
Recovery	15:16	4:00	00.0	00.0	01.0	117	60%	128/88	149	00	
Recovery	15:16	4:00	00.0	00.0	01.0	117	60%	128/88	149	00	

**Findings :**

Exercise Time : 03:51  
 Max HR Attained : 160 bpm 82% of Target 194  
 Max BP Attained : (Sys) 136/96  
 Max Workload Attained : 5.4 Fair response to induced stress  
 Max ST Dep Lead & Value : avL & -1.5 mm in ExStart mm  
 Test Objective : MEDIWHEEL MEDICAL  
 History : No  
 Test End Reasons : Test Complete, Test Complete

**Report :**

*Test is negative for ischemia*

(SEM214190403)(R)Allengers

  
 Rajashanti Diagnostic & Research Centre  
 Doctor : JRD/MRC

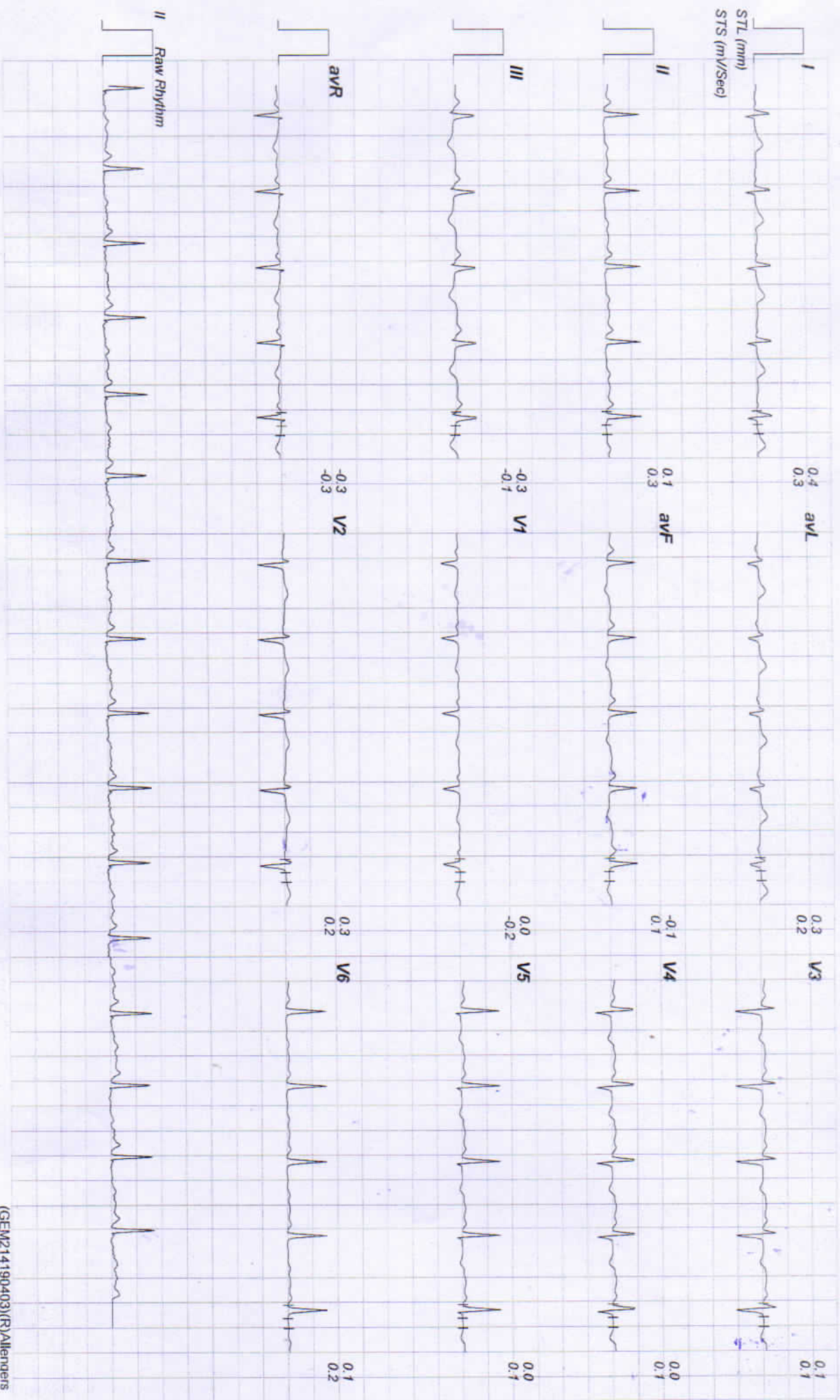


132 / NEELAM / 26 Yrs / Female / 158 Cm / 62 Kg

Date: 14-05-2022 11:45:56 AM METs: 01.00 HR: 91 Target HR: 46% of 194 BP: 126/66 Post J @80mSec ExtTime: 01:05 0.0 mph Grade: 00.00 % 25 mm/Sec. 1.0 Cm/mV

# Linked Medians Report

Supine



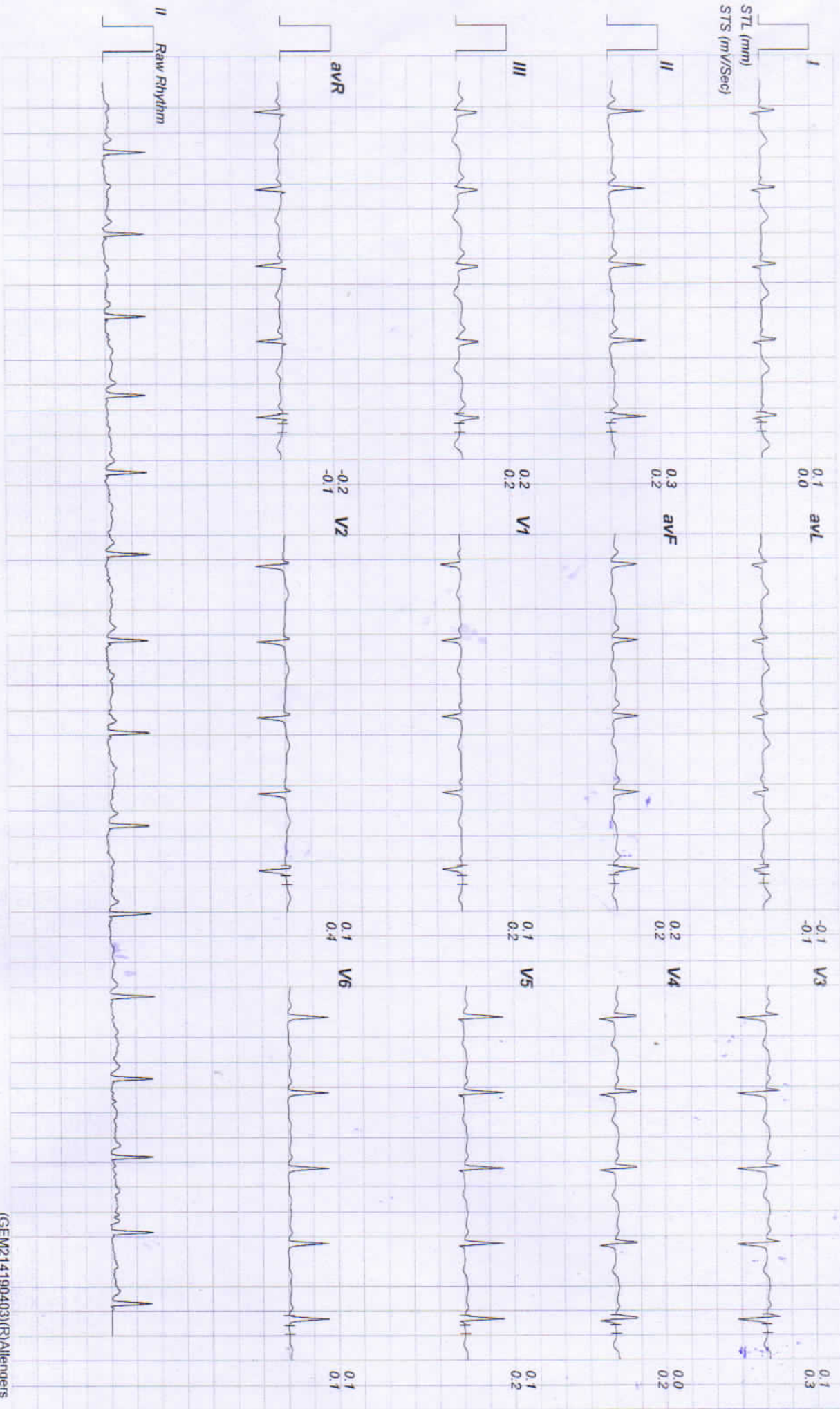
(GEM214190403)(R)/Allengers

132 / NEELAM / 26 Yrs / Female / 158 Cm / 62 Kg

Date: 14 - 05 - 2022 11:45:56 AM METs : 01.00 HR : 89 Target HR : 45% of 194 BP : 126/86 Post J @80mSec EXTime : 02:11 0.0 mph Grade : 00.00 % 25 mm/Sec 1.0 Cm/mV

# Linked Medians Report

Standing





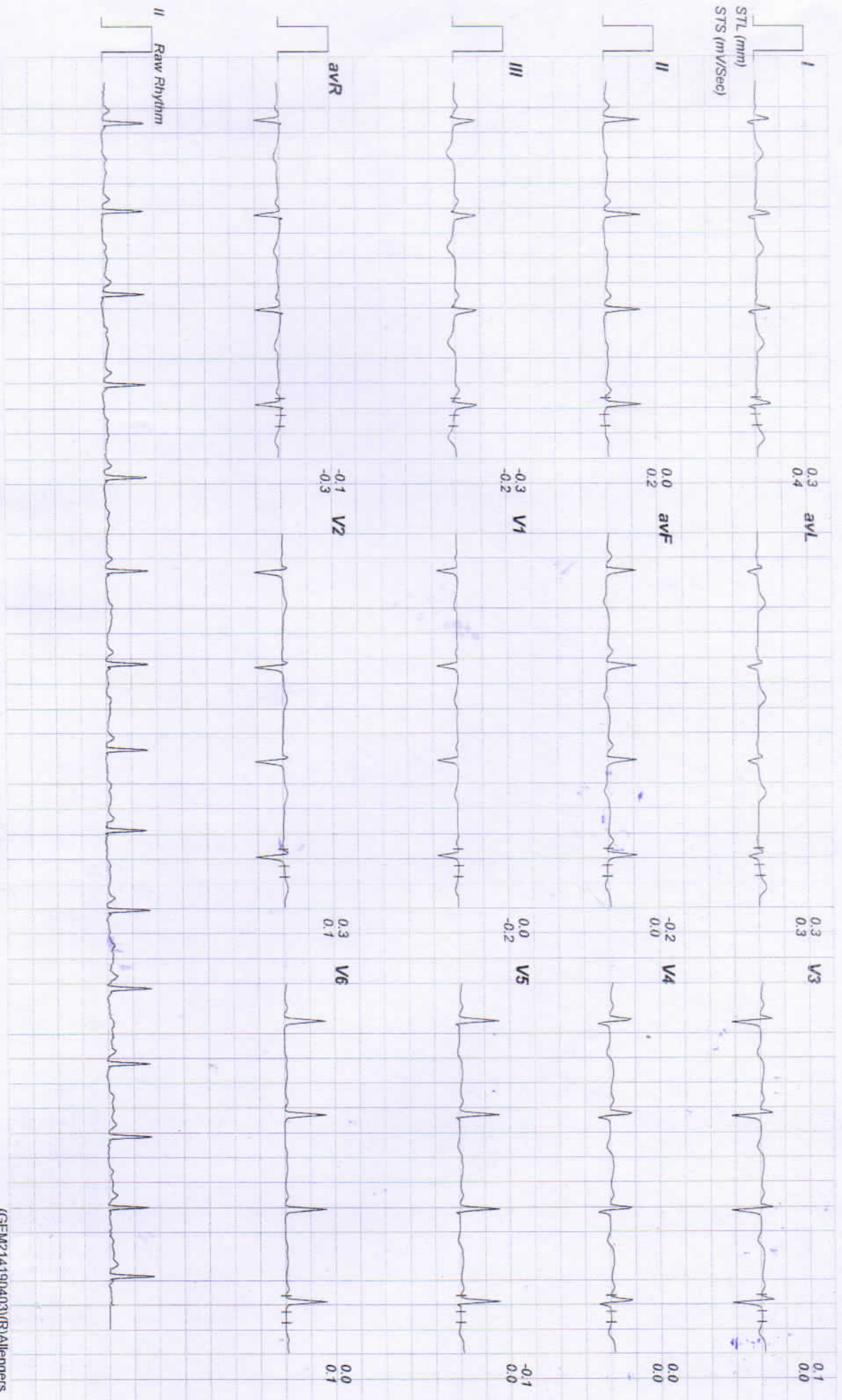
132 / NEELAM / 26 Yrs / Female / 158 Cm / 62 Kg

Date: 14 - 05 - 2022 11:45:56 AM METs : 01.00 HR : 82 Target HR : 42% of 194 BP : 126/86 Post J @80mSec ExtTime : 03:16 0.0 mph Grade : 00.00 % 25 mm/Sec. 1.0 Cm/mV

# Linked Medians Report



HV



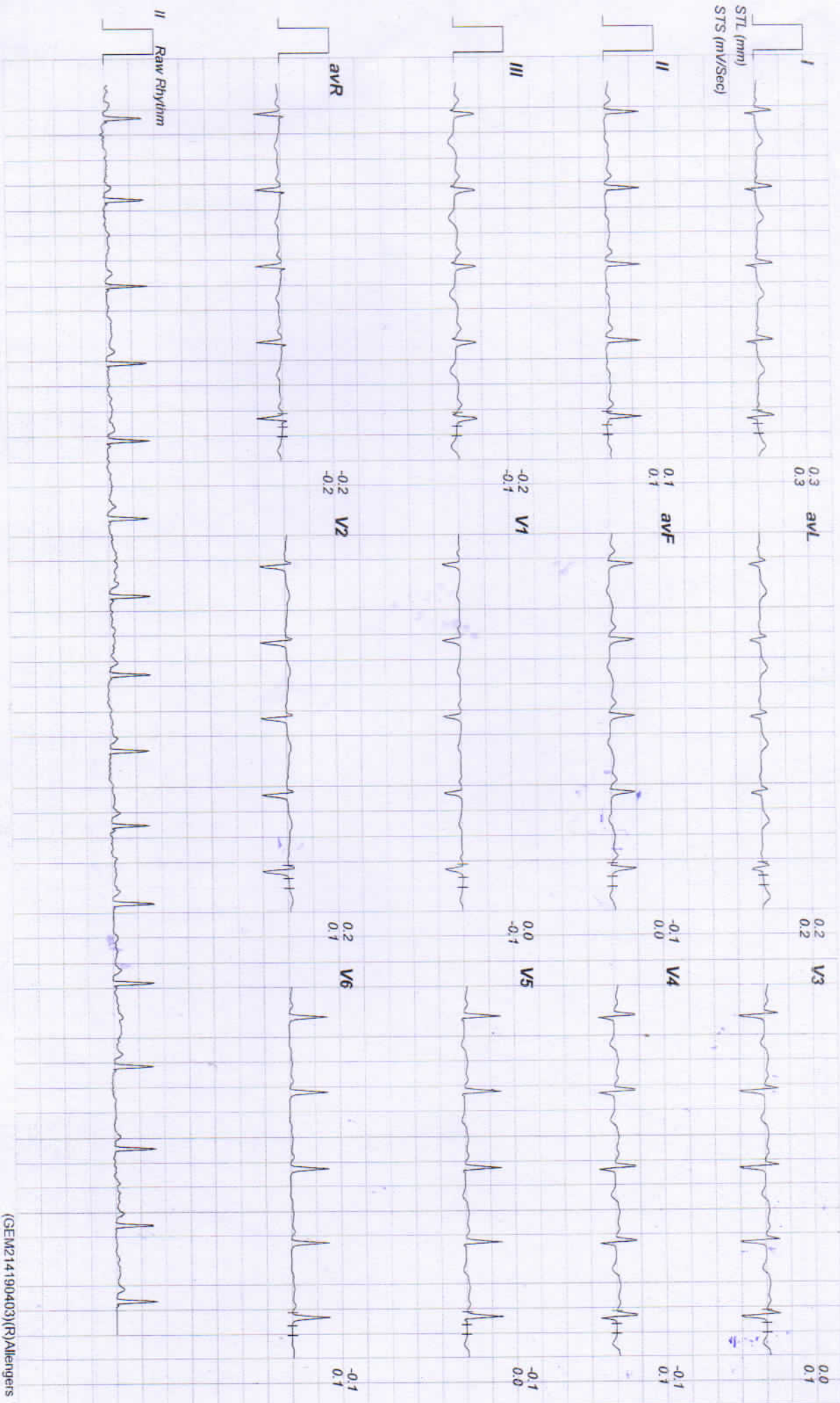
(GEM214190403)(R)Allengers

132 / NEELAM / 26 Yrs / Female / 158 Cm / 62 Kg

Date: 14 - 05 - 2022 11:45:56 AM METS : 01.00 HR : 94 Target HR : 48% of 194 BP : 126/86 Post J @80mSec ExTime : 04:24 0.0 mph Grade : 00.00 % 25 mm/Sec. 1.0 Cm/mV

# Linked Medians Report

Warm Up



(GEM214190403)(R)/Allengers



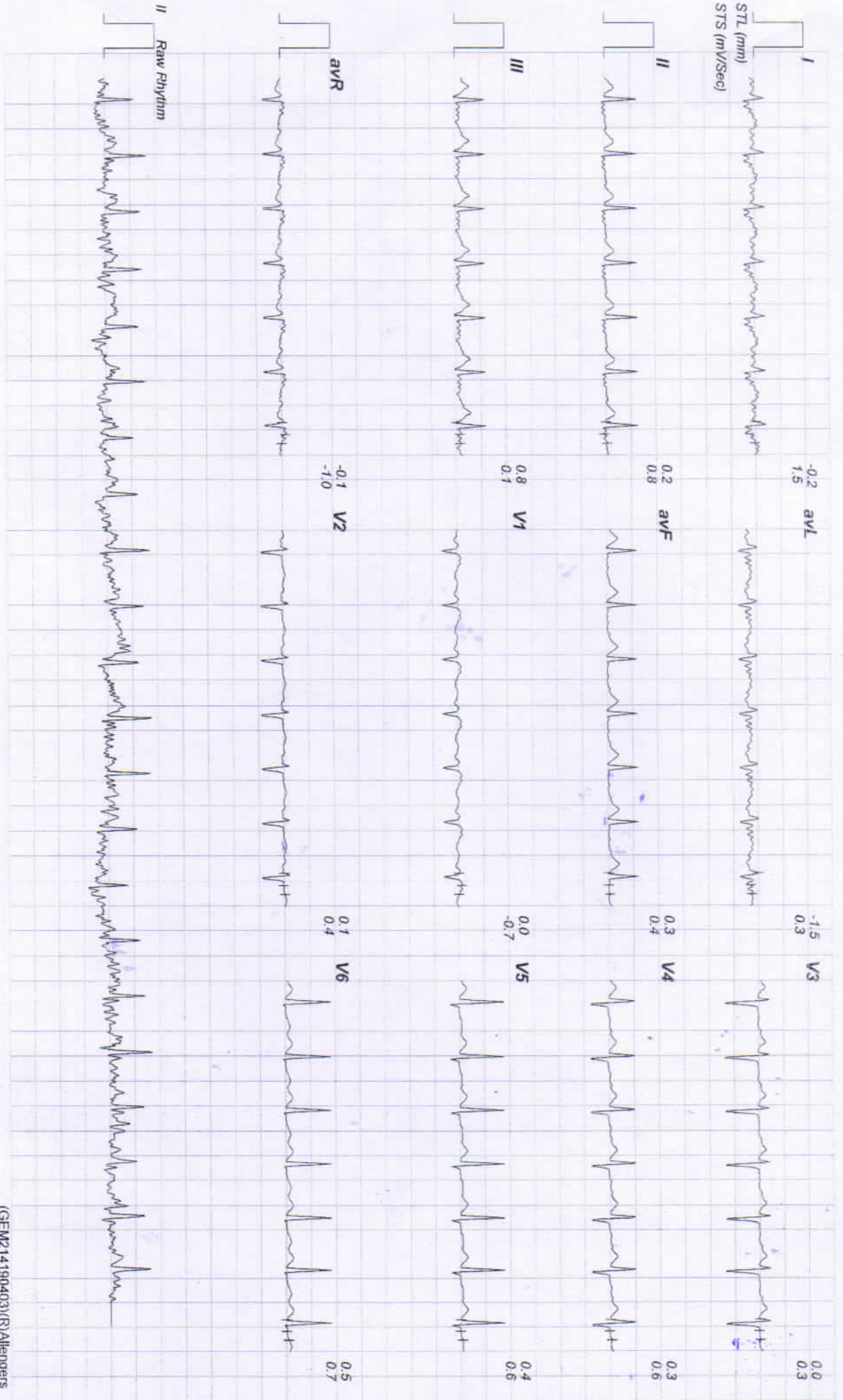
# Linked Medians Report



ExStart

132 / NEELAM / 26 Yrs / Female / 158 Cm / 62 Kg

Date: 14 - 05 - 2022 11:45:56 AM METs: 01.00 HR: 130 Target HR: 67% of 194 BP: 130/90 Post J @80mSec ExTime: 00:00 1.0 mph Grade: 00.00 % 25 mm/Sec. 1.0 Cm/mV



(GEM214190403)(R)Allengers

132 / NEELAM / 26 Yrs / Female / 158 Cm / 62 Kg

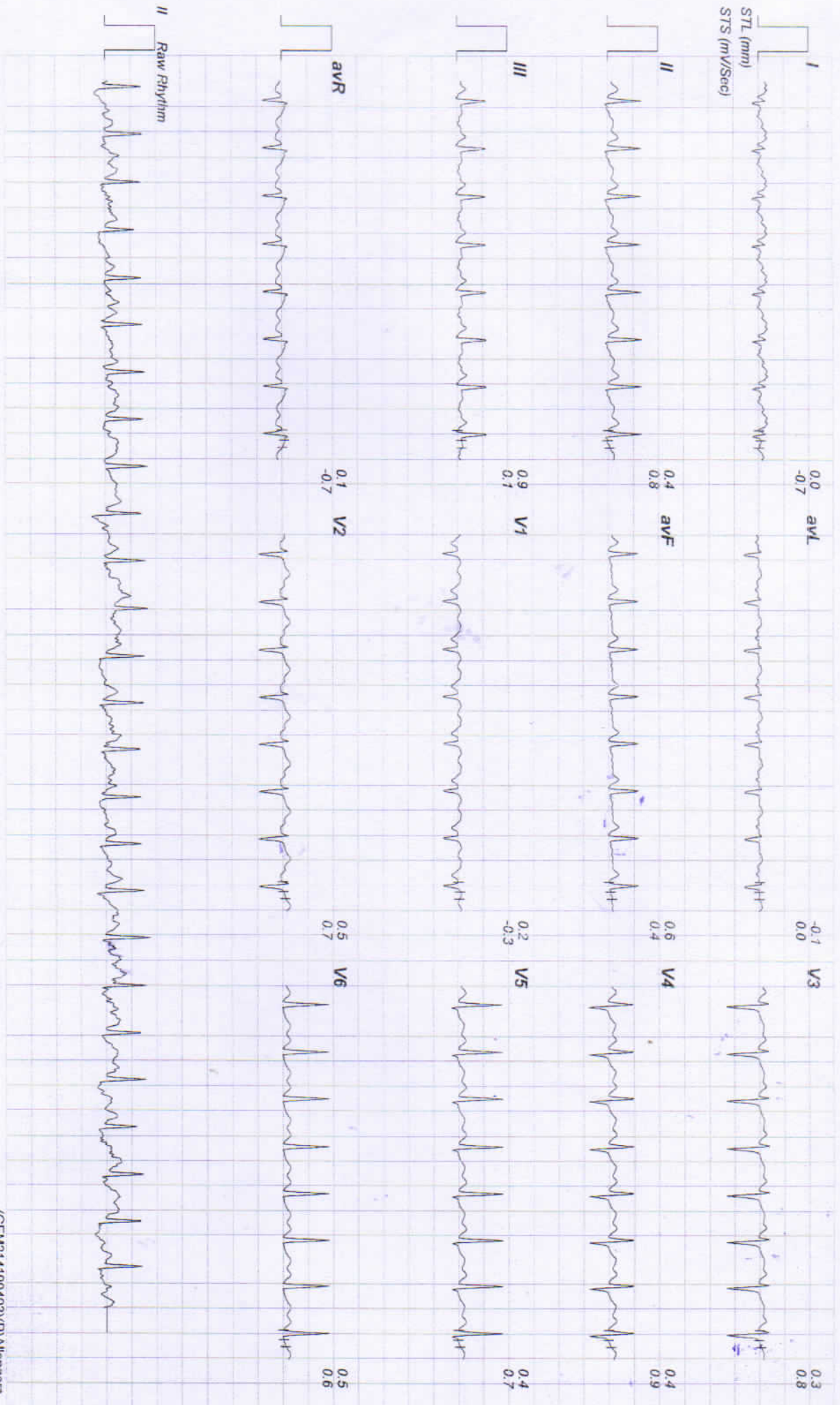
Date: 14 - 05 - 2022 11:45:56 AM METs : 04.70 HR : 156 Target HR : 80% of 194 BP : 136/96 Post J @60mSec EXTime : 03:00 1.7 mph Grade : 10.00 % 25 mm/Sec. 1.0 Cm/mV

### Linked Medians Report

BRUCE: Stage 1(3:00)



AGHP



(GEM214190403)(R)Allengers



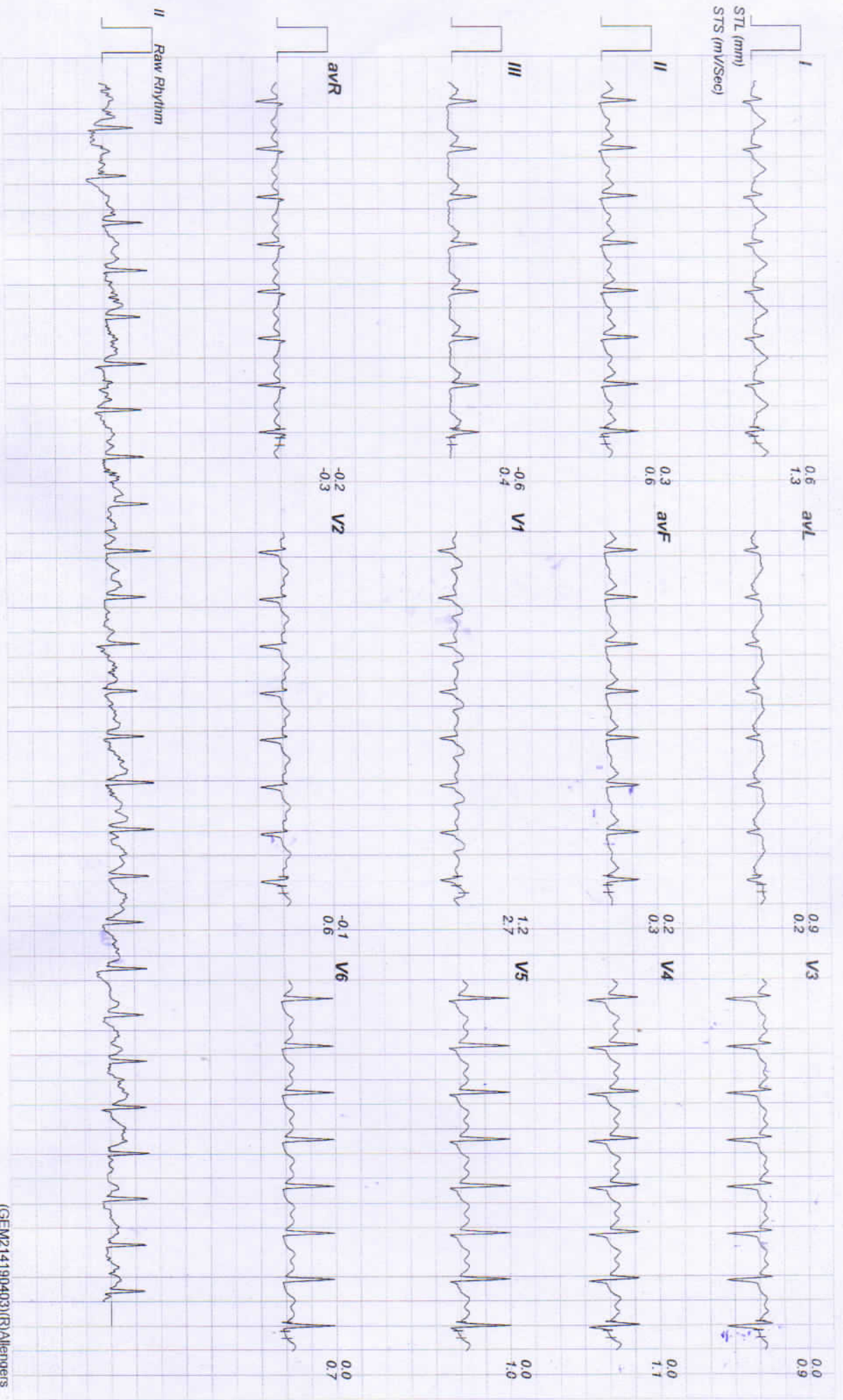
# Linked Medians Report



PeakEx

132 / NEELAM / 26 Yrs / Female / 158 Cm / 62 Kg

Date: 14 - 05 - 2022 11:45:56 AM METS: 05.40 HR: 155 Target HR: 79% of 194 BP: 136/96 Post J @ 60mSec ExTime: 03:51 2.5 mph Grade: 12.00 % 25 mm/Sec. 1.0 Cm/mV



(GEM214190403)(R)Allengers

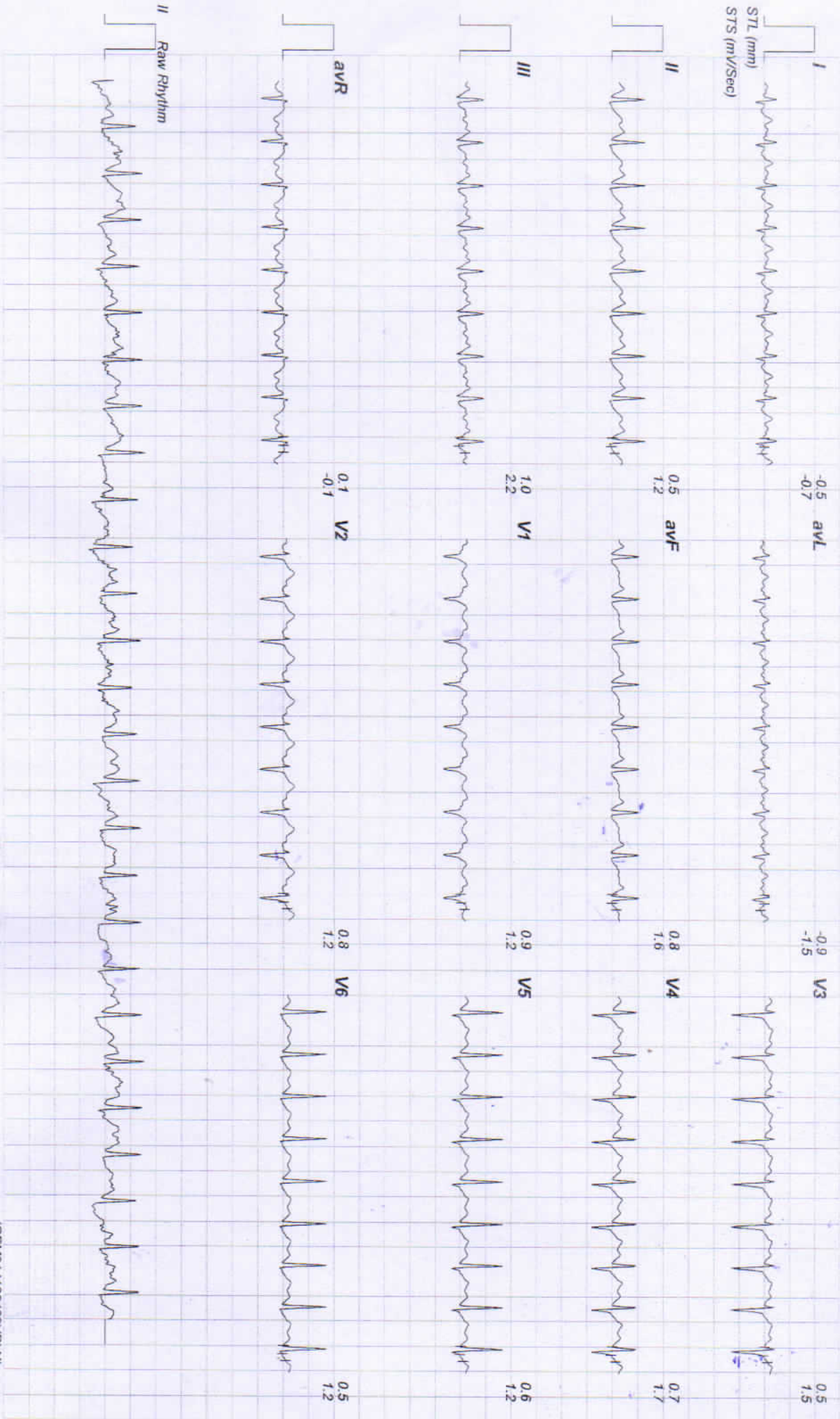
132 / NEELAM / 26 Yrs / Female / 158 Cm / 62 Kg

Date: 14 - 05 - 2022 11:45:56 AM METs : 01:70 HR : 160 Target HR : 82% of 194 BP : 136/96 Post J @60mSec ExTime : 03:51 1.1 mph Grade : 00.00 % 25 mm/Sec. 1.0 Cm/mV

### Linked Medians Report

Recovery(0:30)

ACHPL



(GEM214190403)(R)Allengers

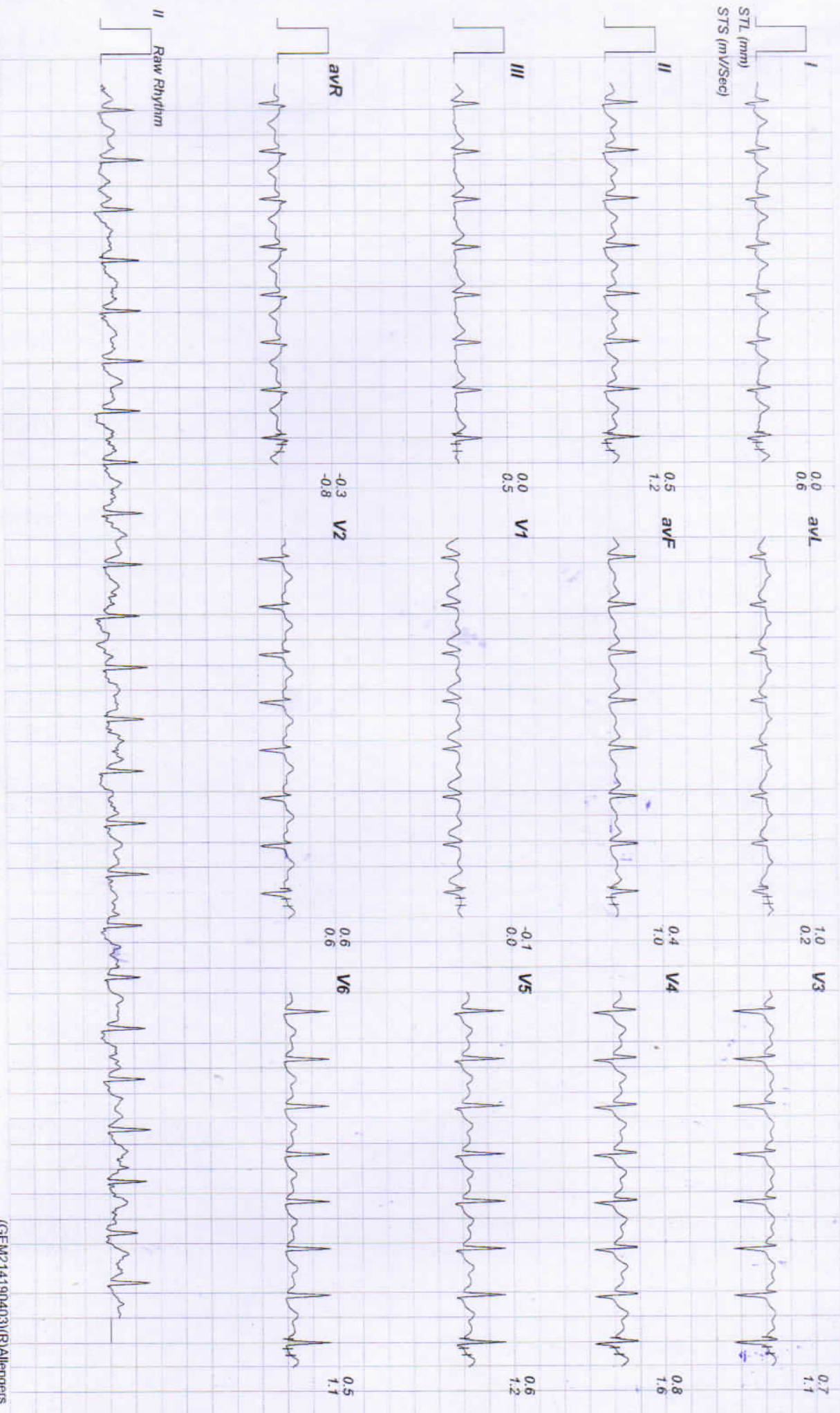


132 / NEELAM / 26 Yrs / Female / 158 Cm / 62 Kg

Date: 14 - 05 - 2022 11:45:56 AM METs : 01.00 HR : 146 Target HR : 75% of 194 BP : 136/96 Post J @60mSec ExTime : 03:51 0.0 mph Grade : 00.00 % 25 mm/Sec. 1.0 Cm/mv

### Linked Medians Report

Recovery(1:00)

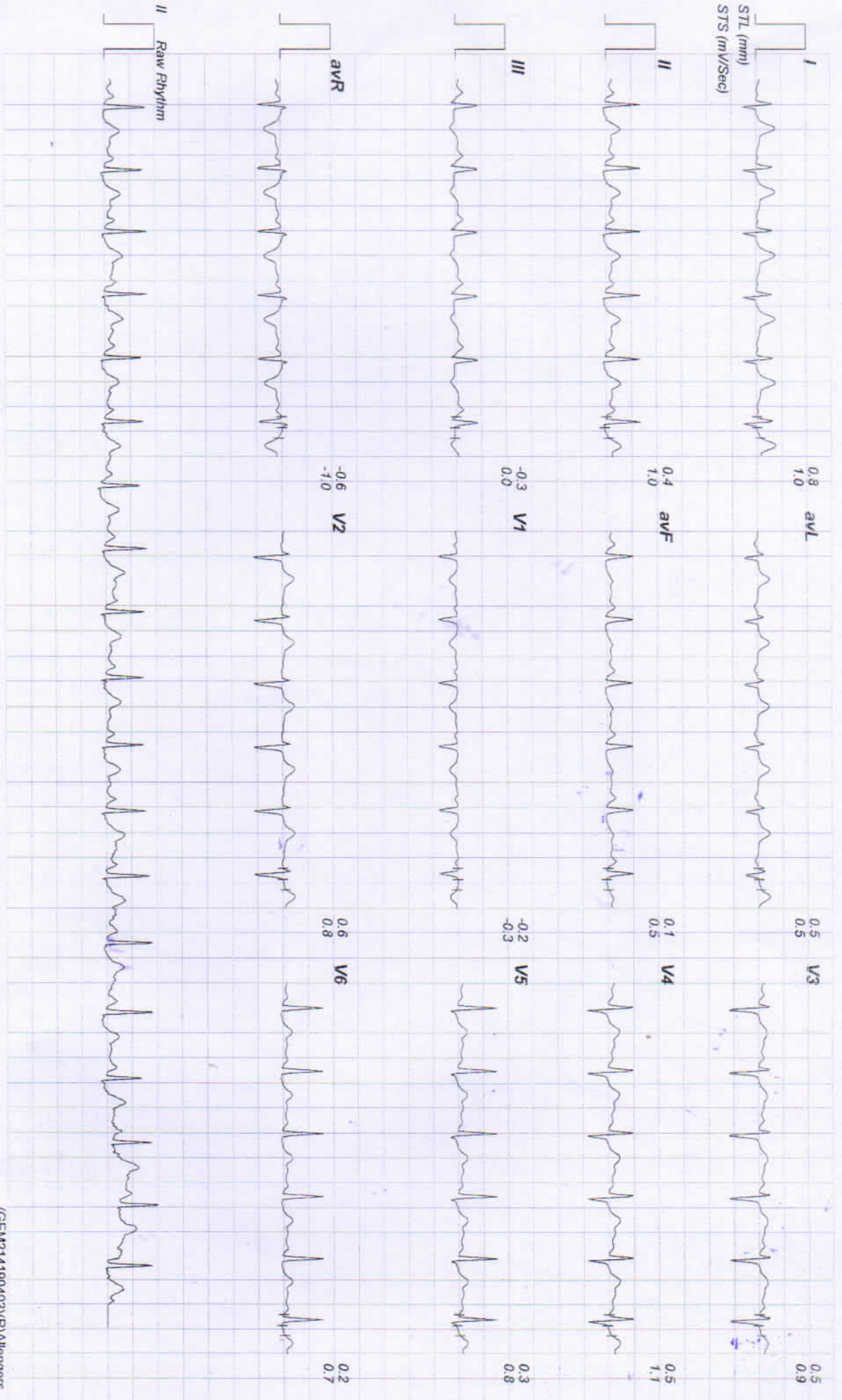


(GEM214:190403)(R)Allengers

132 / NEELAM / 26 Yrs / Female / 158 Cm / 62 Kg

Date: 14 - 05 - 2022 11:45:56 AM METs : 01.00 HR : 115 Target HR : 59% of 194 BP : 132/92 Post J @80mSec ExTime : 03:51 0.0 mph Grade : 00.00 % 25 mm/Sec 1.0 Cm/mV

### Linked Medians Report Recovery(2:00)



(GEM214190403)(R)Allergens



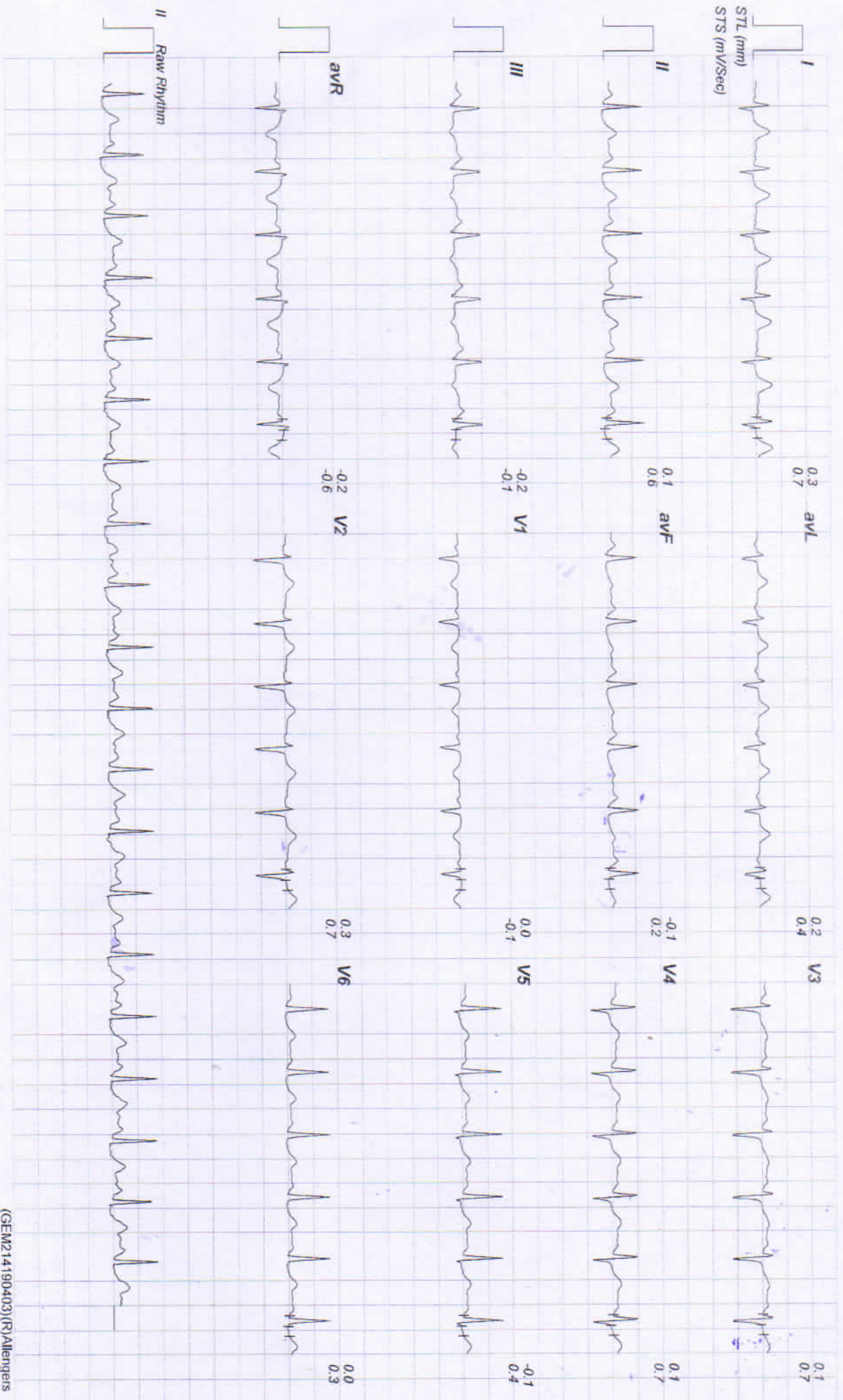
# Linked Medians Report



Recovery(3:00)

132 / NEELAM / 26 Yrs / Female / 158 Cm / 62 Kg

Date: 14 - 05 - 2022 11:45:56 AM METs : 01.00 HR : 119 Target HR : 61% of 194 BP : 130/90 Post J @80mSec ExTime : 03:51 0.0 mph Grade : 00.00 % 25 mm/Sec. 1.0 Cm/mV



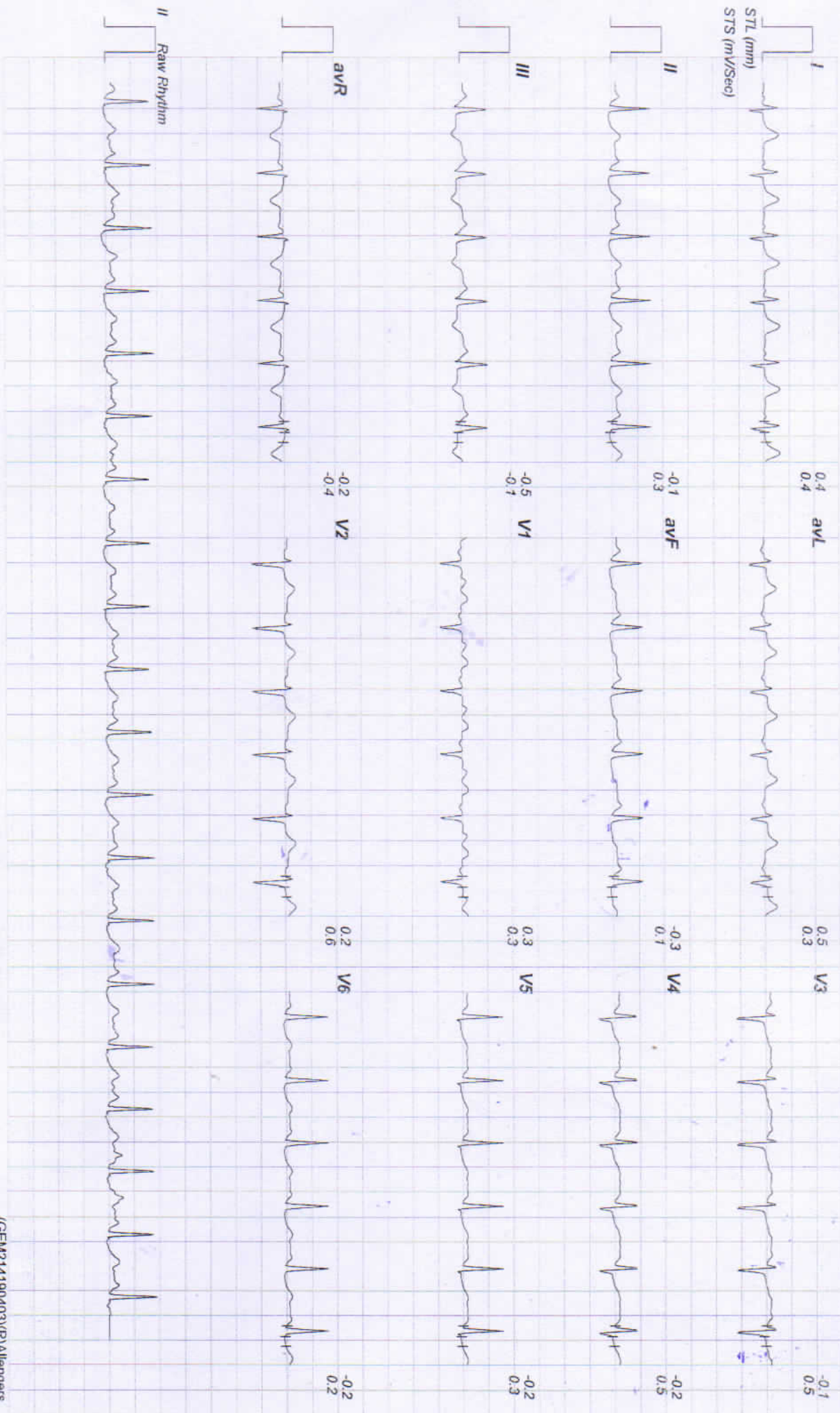
(GEM214190403)(R)Allengers

132 / NEELAM / 26 Yrs / Female / 158 Cm / 62 Kg

Date: 14 - 05 - 2022 11:45:56 AM METs : 01.00 HR : 117 Target HR : 60% of 194 BP : 128/88 Post J @80mSec

### Linked Medians Report

Recovery(4:00)





आयकर विभाग  
INCOME TAX DEPARTMENT

भारत सरकार  
GOVT. OF INDIA

स्थायी लेखा संख्या कार्ड  
Permanent Account Number Card

नाम / Name  
NEELAM KUMARI

पिता का नाम / Father's Name  
RAJ KUMAR

जन्म की तारीख / Date of Birth  
11/07/1995

नीलम  
हस्ताक्षर / Signature

01112017



नीलम



Female

14.05.2022 11:51:16  
RAJASTHANI DIAGNOSTICS CENTRE  
JHUNJHUNU RAJ

Location:

Room:

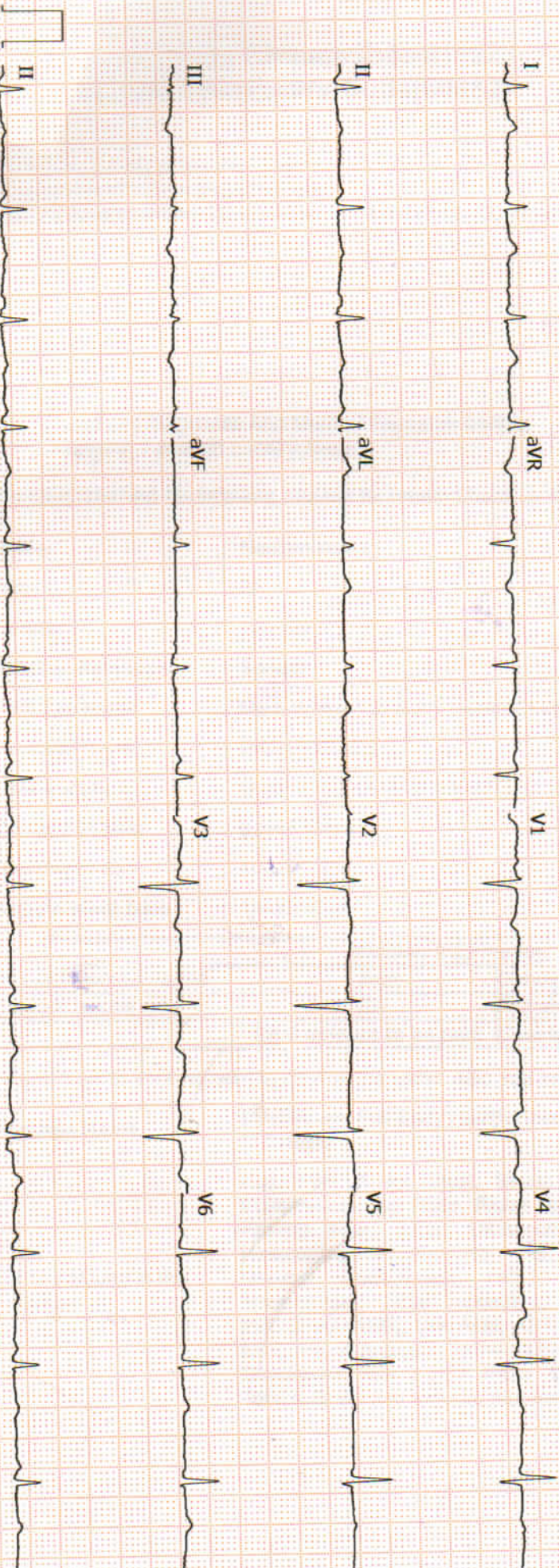
78 bpm  
--/-- mmHg

Technician:  
Ordering Ph:  
Referring Ph:  
Attending Ph:

Order Number:  
Visit:  
Indication:  
Medication 1:  
Medication 2:  
Medication 3:

QRS : 72 ms  
QT / QTcBaz : 394 / 449 ms  
PR : 126 ms  
P : 94 ms  
RR / PP : 770 / 769 ms  
P / QRS / T : 76 / 45 / 25 degrees

Normal sinus rhythm  
Normal ECG  
*stc/ra*





# RAJASTHANI DIAGNOSTIC & MRI CENTRE

FULLY COMPUTERISED PATHOLOGY LABORATORY

MRI CT SCAN TMT SONOGRAPHY X-RAY ECG MAMMOGRAPHY

NAME	NEELAM KUMARI	AGE-	SEX: F
REF/BY:	MEDIWHEEL HEALTH CHECK-UP	DATE	14-May-22

## ULTRASONOGRAPHY WHOLE ABDOMEN

**Liver:** is normal in size, shape and echotexture. No IHBR dilatation is seen. No focal mass seen. Portal vein and hepatic veins are normal in diameter. Common bile duct is normal in diameter and lumen is clear.

**Gall bladder:** is normal in size shape, location with echo free lumen. Wall thickness is normal. No echogenic shadow suggestive of calculus is seen. No focal mass or lesion is seen.

**Pancreas:** is normal in size, shape and echotexture. No focal mass or lesion is detected. Pancreatic duct is not dilated

**Rt. Kidney:** is normal in size, shape, position and echotexture. Corticomedullary differentiation is well maintained. No evidence of definite calculus/ hydronephrosis is seen.

**Lt. Kidney:** is normal in size, shape, position and echotexture. Corticomedullary differentiation is well maintained. No evidence of definite calculus/ hydronephrosis is seen.

**Spleen:** is normal in size, regular in shape and echo texture. No focal lesion is seen. Splenic vessels are seen normal.

**Urinary Bladder:** is partial filled. Outline of bladder is regular. Wall thickness is normal. No focal mass is seen. No echogenic shadow suggestive of calculus is seen.

**Uterus:** is normal in size, regular in shape and outline. Uterus is anteverted and ante flexed. Endometrium is normal in thickness. No sonolucent or echogenic mass lesion seen.

**Adenexa:** Both adenexal regions are seen normal. No focal mass or lesion is seen. Both ovaries are seen normal in size shape and outline.

No evidence of ascites is seen. No significant Lymphadenopathy is seen. No obvious bowel pathology is seen. Retroperitoneum including aorta, IVC is unremarkable.

### IMPRESSION:

❖ NORMAL SONOGRAPHY STUDY

Advised: clinicopathological correlation

**DR. B S GUPTA**  
MD RADIODIAGNOSIS



आपताकालीन सेवाएं

THIS REPORT IS NOT VALID FOR MEDICO LEGAL PUROSE



B-110, Indra Nagar, Jhunjhunu (Raj.) Ph. No. 01592 294977