



24-Sep-2022 8:54:37 am
priyanshi



भारत सरकार

GOVERNMENT OF INDIA



प्रियंशी मेहता

Priyanshi Mehta

जन्म तारीख/DOB: 13/05/1992

लिंग/ FEMALE

Mobile No: 8128128111

9517 9580 8260

VID : 9188 9702 2197 6885

भारी अधिकार, भारी जालना

Paid Amount

Up

Other

Pulmonary

Audiomet

Retinal Sc

Radiology

X-Ray Ch

USG

Mammogr

Other

ure

09



Ctrl

Shift

REVIVAL DIAGNOSTICS



HEALTH CHECK-UP SUMMARY

Name: Priyanshi mehta

Date: 24/09/2022

Email ID:

Sex: F Age: 30 Years Contact No: 8128128111 Remarks:

Under-weight	-
Normal	✓
Over-weight	-

i> **BMI**

Height (in Cm): <u>155</u>	Weight (in Kg): <u>58</u>	BMI: <u>24.01</u>	
----------------------------	---------------------------	-------------------	--

ii> **Blood Pressure & Pulse**

110/72 mm/hg.
84/min.

If high or low, whether the person is on medication : YES / NO

iii> **Blood Tests & Lung Function Remarks**

RS
CVS }
CNS

If abnormal, whether the person is on medication : YES / NO

iv> **Eye Test Remarks**

Eye test Ⓛ 6/6 Ⓡ 6/6 with specs.
Color Vision: 2

v> **Heart Disease**

Whether any specific heart ailment detected (ECG findings):
normal

vi> **Any other problems needing attention / Overall Assessment :**

no

Revival Diagnostic

401, Aqua Corridor,
B/s. Star Bazar, Surat-395009
Mo. 91062-28601

Signature of the Doctor

Dr. Chirag Patel
M.B.B.S. G-49432

Priya

Laboratory Test Result are Subject to technical limitation and should be clinically correlate for final diagnosis

4th Floor, Aqua Corridor, Hazira Road, Adajan Paal, Surat-395009.

0261 2747788

revivaldiagnostics.surat@gmail.com

www.revivaldiagnostics.com

This medical report is not intended for medico-legal purposes.



NAME: Priyanshi Mehta SEX: F
BIRTHDATE: 13/05/1992 AGE: 30

DEPARTMENT OF OPHTHALMOLOGY

EYE TEST:

1. VISION:

RIGHT EYE - 6/6 } with specs.
LEFT EYE - 6/6

2. COLOR VISION:

RIGHT EYE - (P)
LEFT EYE - (P)

3. FUNDUS:

RIGHT EYE - (N)
LEFT EYE - (N)

REMARKS:

Priyanshi

Revival Diagnostic
401, Aqua Corridor,
Ophthalmologist/Optometrist
Mo. 91062-28601

Laboratory Test Result are Subject to technical limitation and should be clinically correlate for final diagnosis



Dental Assessment Form

NAME
AGE

Priyanshi mehta
30

DATE
SEX

29/09/2022
F

* CHIEF COMPLAINT

A CLINICAL FEATURES :- (2)

- 1 CAVIES :-
 - 2 MISSING TOOTH :-
 - 3 MALOCCLUSION :-
 - 4 FILLING :-
- } (2)

B DIAGNOSIS :- normal

C PERSONAL HISTORY :- Hygienic

D PROVISIONAL D/G :- (2)

E MEDICAL HISTORY :-

F FINAL D/G :- (2)

G TREATMENT PLAN :- NO

CLINT SIGN

Priyanshi

Revival Diagnostic
401, Aqua Corridor,
B/s. Star Bazar, Surat-395009
Mo. 91062-28601

Laboratory Test Result are Subject to technical limitation and should be clinically correlate for final diagnosis

4th Floor, Aqua Corridor, Hazira Road, Adajan Paal, Surat-395009.

0261 2747788

revivaldiagnostics.surat@gmail.com

www.revivaldiagnostics.com

This medical report is not intended for medico-legal purposes.



Name	PRIYANSHI MEHTA	Age/Gender	30Yrs/Female
Reg No.	1941/22	Receipt No	1639
Referred By	BOB - MEDI WHEEL(PKG10000241)	Mode of Payment	CREDIT
Collection Type	CENTER	Collection DateTime	24-Sep-2022 08:56 AM

BLOOD GROUP - 24092242 Released at 24-Sep-2022 12:19 PM

Parameter	Result	Biological Ref.Range	Method
-Blood Group	"A"		
-Rh Factor	POSITIVE		

CBC - 24092240 Released at 24-Sep-2022 11:57 AM

Parameter	Result	Biological Ref.Range	Method
-Haemoglobin	10.5 gm/dL	L (12 - 16 gm/dL)	Auto
-RBC Count	4.48 mill/cumm	(4.2 - 5.4 mill/cumm)	Auto
-Total WBC Count	5500 /cumm	(4000 - 10000 /cumm)	Auto
-Platelet Count	2.62 lakh/cumm	(1.5 - 4.5 lakh/cumm)	Auto

Blood Indices

-HCT	34.8 %	L (40 - 55 %)	Auto
-MCV	77.7 fl	L (80 - 92 fl)	Auto
-MCH	23.5 pg	L (27 - 31 pg)	Auto
-MCHC	30.2 gm/dL	L (32 - 36 gm/dL)	Auto
-RDW	13.3 %	(11 - 15 %)	Auto

Diff WBC Count

-Polymorphs	60 %	(40 - 80 %)	Microscopically
-Lymphocytes	35 %	(20 - 40 %)	Microscopically
-Eosinophils	03 %	(1 - 6 %)	Microscopically
-Monocytes	02 %	(2 - 7 %)	Microscopically
-Basophils	00 %	(0 - 1 %)	Microscopically
-PLATELET ON SMEAR	Adequate		Microscopically
-MALARIAL PARASITES	Malarial Parasites Not Detected		Microscopically

[Test performed on Fully Automated Hematology Analyzer ERBA H-360]

Revival Diagnostic

401, Aqua Corridor,
B/s. Star Bazar, Surat-395009.
Mo. 91062-28601

Dr. Mihir Icecreamwala
M.B.B.S., DPB.(PATH AND BACT)

Laboratory Test Result are Subject to technical limitation and should be clinically correlate for final diagnosis

4th Floor, Aqua Corridor, Hazira Road, Adajan Paal, Surat-395009.

0261 2747788

revivaldiagnostics.surat@gmail.com

www.revivaldiagnostics.com

This medical report is not intended for medico-legal purposes.

REVIVAL DIAGNOSTICS



Name	PRIYANSHI MEHTA	Age/Gender	30Yrs/Female
Reg No.	1941/22	Receipt No	1639
Referred By	BOB - MEDI WHEEL(PKG10000241)	Mode of Payment	CREDIT
Collection Type	CENTER	Collection DateTime	24-Sep-2022 08:56 AM

ESR - 24092240 Released at 24-Sep-2022 11:57 AM

Parameter	Result	Biological Ref.Range	Method
-E.S.R	07 mm/hr	(3 - 15 mm/hr)	



DIAGNOSTICS

Revival Diagnostic
401, Aqua Corridor,
B/s. Star Bazar, Surat-395009.
Mo. 91062-28601

Dr. Mihir Icecreamwala
M.B.B.S., DPB.(PATH AND BACT)

Laboratory Test Result are Subject to technical limitation and should be clinically correlate for final diagnosis

📍 4th Floor, Aqua Corridor, Hazira Road, Adajan Paal, Surat-395009.
☎ 0261 2747788 ✉ revivaldiagnostics.surat@gmail.com 🌐 www.revivaldiagnostics.com

This medical report is not intended for medico-legal purposes.

REVIVAL DIAGNOSTICS



Name	PRIYANSHI MEHTA	Age/Gender	30Yrs/Female
Reg No.	1941/22	Receipt No	1639
Referred By	BOB - MEDI WHEEL(PKG10000241)	Mode of Payment	CREDIT
Collection Type	CENTER	Collection DateTime	24-Sep-2022 08:56 AM

FBS (Fasting Blood Sugar) - 24092241 Released at 24-Sep-2022 11:57 AM

Parameter	Result	Biological Ref.Range	Method
-Fasting Blood Sugar (FBS)	100 mg/dL	70-100 mg/dl Impaired Tolerance:100-125 Diabetes Mellitus:>=126 (On more than one occasion) (American diabetes association guidelines 2022)	GOD POD
-Fasting Urine Sugar	Absent		Dipstick Benedict
-Fasting Urine Acetone	Absent		Dipstick Rothera

[Test performed on Fully Automated Biochemistry Analyzer ERBA EM200]

HBA1C - 24092240 Released at 24-Sep-2022 11:57 AM

Parameter	Result	Biological Ref.Range	Method
-HBA1C	5.3 %	HbA1C Degree of Glucose Control <5.6 % Non Diabetics 5.7 - 6.4 % Prediabetics > =6.5 % Diabetics (REF:Wallace, 11th Edition) REMARKS: 6 - 7 % Excellent Control 7 - 8 % Good Control 8 - 10 % Unsatisfactory Control >10 % Poor Control	Boronate Affinity
-Method[]	High Performance Liquid Chromatography (HPLC)		

Revival Diagnostic
401, Aqua Corridor,
B/s. Star Bazar, Surat-395009.
Mo. 91062-28601

Dr. Mihir Icecreamwala
M.B.B.S., DPB.(PATH AND BACT)

Laboratory Test Result are Subject to technical limitation and should be clinically correlate for final diagnosis

📍 4th Floor, Aqua Corridor, Hazira Road, Adajan Paal, Surat-395009.
☎ 0261 2747788 ✉ revivaldiagnostics.surat@gmail.com 🌐 www.revivaldiagnostics.com

This medical report is not intended for medico-legal purposes.



Name	PRIYANSHI MEHTA	Age/Gender	30Yrs/Female
Reg No.	1941/22	Receipt No	1639
Referred By	BOB - MEDI WHEEL(PKG10000241)	Mode of Payment	CREDIT
Collection Type	CENTER	Collection DateTime	24-Sep-2022 08:56 AM

LIVER FUNCTION TEST (LFT) - 24092242 Released at 24-Sep-2022 11:57 AM

Parameter	Result	Biological Ref.Range	Method
-Serum Total Bilirubin	0.2 mg/dL	(0 - 1.3 mg/dL)	Diazo
-Serum Direct Bilirubin	0.1 mg/dL	(0 - 0.4 mg/dL)	Diazo
-Serum InDirect Bilirubin	0.1 mg/dL	(0.1 - 1.3 mg/dL)	Calculated
-Total Protein (TP)	6.6 gm/dL	(6.4 - 8.3 gm/dL)	Biuret
-Albumin (ALB)	3.9 gm/dL	(3.5 - 5.2 gm/dL)	BCG
-Globulin	2.7 gm/dL	(2.3 - 3.6 gm/dL)	Calculated
-A/G Ratio	1.44 gm/dL	(1 - 2.3 gm/dL)	Calculated
-SGPT(ALT)	10 U/L	(5 - 45 U/L)	IFCC, Kinetic without Pyridoxal Phosphate
-SGOT (AST)	12 U/L	(0 - 35 U/L)	IFCC, Without Pyridoxal Phosphate
-Alkaline Phosph.	54 U/L	(42 - 128 U/L)	ALP-AMP
-GGT	15 U/L	(5 - 50 U/L)	Glupa-C

[Test performed on Fully Automated Biochemistry Analyzer ERBA EM200]

Revival Diagnostic
401, Aqua Corridor,
B/s. Star Bazar, Surat-395009.
Mo. 91062-28601

Dr. Mihir Icecreamwala
M.B.B.S., DPB.(PATH AND BACT)

Laboratory Test Result are Subject to technical limitation and should be clinically correlate for final diagnosis

REVIVAL DIAGNOSTICS



Name	PRIYANSHI MEHTA	Age/Gender	30Yrs/Female
Reg No.	1941/22	Receipt No	1639
Referred By	BOB - MEDI WHEEL(PKG10000241)	Mode of Payment	CREDIT
Collection Type	CENTER	Collection DateTime	24-Sep-2022 08:56 AM

Creatinine - 24092242 Released at 24-Sep-2022 11:57 AM

Parameter	Result	Biological Ref.Range	Method
-Creatinine	0.6 mg/dL	(0.6 - 1.14 mg/dL)	ENZYMATIC

BUN - 24092242 Released at 24-Sep-2022 11:57 AM


Parameter	Result	Biological Ref.Range	Method
-Blood Urea Nitrogen (BUN)	14 mg/dL	(6 - 20 mg/dL)	Calculated

Uric Acid - 24092239 Released at 24-Sep-2022 11:57 AM

Parameter	Result	Biological Ref.Range	Method
-Uric Acid	3.9 mg/dL	(3.5 - 7.2 mg/dL)	Uricase-POD

DIAGNOSTICS

Revival Diagnostic
401, Aqua Corridor,
B/s. Star Bazar, Surat-395009.
Mo. 91062-28601


Dr. Mihir Icecreamwala
M.B.B.S., DPB.(PATH AND BACT)

Laboratory Test Result are Subject to technical limitation and should be clinically correlate for final diagnosis

📍 4th Floor, Aqua Corridor, Hazira Road, Adajan Paal, Surat-395009.
☎ 0261 2747788 ✉ revivaldiagnostics.surat@gmail.com 🌐 www.revivaldiagnostics.com

This medical report is not intended for medico-legal purposes.



Name	PRIYANSHI MEHTA	Age/Gender	30Yrs/Female
Reg No.	1941/22	Receipt No	1639
Referred By	BOB - MEDI WHEEL(PKG10000241)	Mode of Payment	CREDIT
Collection Type	CENTER	Collection DateTime	24-Sep-2022 08:56 AM

Lipid Profile - 24092242 Released at 24-Sep-2022 11:57 AM

Parameter	Result	Biological Ref.Range	Method
-Serum Cholesterol	121 mg/dL	Desirable < 200 mg/dl Borderline High : 200-239 mg/dl High : > 240 mg/dl	CHOD-PAP
-Serum Triglyceride	56 mg/dL	Normal < 150 mg/dl Borderline High : 150 - 159 mg/dl High : 200 - 499 mg/dl Very High : 500 mg/dl	GPO-POD Method
-Serum HDLD(Direct)	44 mg/dL	Normal :> 55 mg/dl Borderline : 35-55 mg/dl Undesirable: < 35 mg/dl	PVS-PEGME Precipitation with CHOD-POD
-Serum VLDL	11 mg/dL	(5 - 30 mg/dL)	Calculated
-Serum LDL(Direct)	66 mg/dL	Optimal:< 100 mg/dl Above Optimal : 100- 129 mg/dl Borderline High : 130-159 mg/dl High : > 160-189mg/dl Very High : >190 mg/dl	Calculated
-Chol/HDL	2.75	Low risk: <3.8 Medium Risk: 3.8 to 5.9 High Risk: > 6	Calculated
-LDL/Chol	1.84	Low risk: <3.55 Medium Risk: 3.55 to 4.0 High Risk: > 6	Calculated

[Test performed on Fully Automated Biochemistry Analyzer ERBA EM200]

Revival Diagnostic
401, Aqua Corridor,
B/s. Star Bazar, Surat-395009.
Mo. 91062-28601

Dr. Mihir Icecreamwala
M.B.B.S., DPB.(PATH AND BACT)

Laboratory Test Result are Subject to technical limitation and should be clinically correlate for final diagnosis



Name	PRIYANSHI MEHTA	Age/Gender	30Yrs/Female
Reg No.	1941/22	Receipt No	1639
Referred By	BOB - MEDI WHEEL(PKG10000241)	Mode of Payment	CREDIT
Collection Type	CENTER	Collection DateTime	24-Sep-2022 08:56 AM

Urine Routine & Micro Examination - 24092244 Released at 24-Sep-2022 12:33 PM

Parameter	Result	Biological Ref.Range	Method
Physical Examination			
-Quantity	30		Manual
-Colour	Pale Yellow	Pale Yellow	Manual
-Appearance	Clear	Clear	Manual
-Reaction (pH)	Acidic		Dipstick
-Specific Gravity	1.005		Dipstick
Chemical Examination			
-Proteins.	Absent		Dipstick
-Sugar	Absent		Dipstick
-Acetone.	Absent		Dipstick
-Bile Salts	Absent	Absent	Dipstick
-Bile Pigments	Absent	Absent	Dipstick
-Occult Blood Test (OBT).	Negative		Dipstick
Microscopic Examination			
-Pus Cells	1-2		Microscopically
-Red Blood Cells	Absent		Microscopically
-Epithelial Cells	2-3		Microscopically
-Bacteria.	Absent		Microscopically
-Crystals	Absent	Absent	Microscopically
-Others	NIL	Absent	Microscopic Examination

Revival Diagnostic
401, Aqua Corridor,
B/s. Star Bazar, Surat-395009.
Mo. 91062-28601

Dr. Mihir Icecreamwala
M.B.B.S., DPB.(PATH AND BACT)

Laboratory Test Result are Subject to technical limitation and should be clinically correlate for final diagnosis

REVIVAL DIAGNOSTICS



Name	PRIYANSHI MEHTA	Age/Gender	30Yrs/Female
Reg No.	1941/22	Receipt No	1639
Referred By	BOB - MEDI WHEEL(PKG10000241)	Mode of Payment	CREDIT
Collection Type	CENTER	Collection DateTime	24-Sep-2022 08:56 AM

Total T3 T4 TSH - 24092242 Released at 24-Sep-2022 12:18 PM

Parameter	Result	Biological Ref.Range	Method
-Total T3	0.94 ng/ml	(0.87 - 1.78 ng/ml)	Fluorescence Enzyme Immunoassay
-Total T4	8.05 ug/dl	(4.6 - 11 ug/dl)	Fluorescence Enzyme Immunoassay
-TSH	0.70 uIU/ml	0.50 - 5.50 uIU/ml 5.5 to 15 ul U/ml - Suggested Clinical co-relation or Repeat test with new sample as physiological factors can give falsely high TSH Above 15uIU/ml Hypothyroid PREGNANT WOMEN normal ranges for TSH: 1st Trimester : 0.0878 - 2.8293 uIU/ml 2nd Trimester : 0.1998 - 2.7915 uIU/ml 3rd Trimester : 0.307 - 2.9028 uIU/ml Ref: TIETZ Fundamentals of Clinical Chemistry	Fluorescence Enzyme Immunoassay

[Test performed on Fully Automated Immunology Analyzer Maglumi-600]

Revival Diagnostic
401, Aqua Corridor,
B/s. Star Bazar, Surat-395009.
Mo. 91062-28601

Dr. Mihir Icecreamwala
M.B.B.S., DPB.(PATH AND BACT)

Laboratory Test Result are Subject to technical limitation and should be clinically correlate for final diagnosis

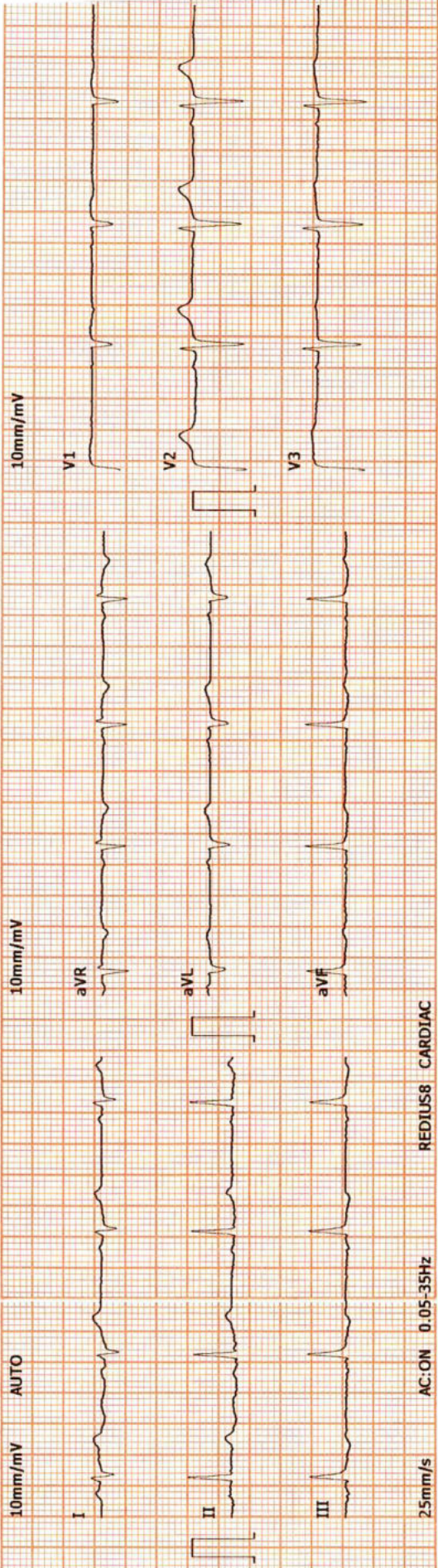
4th Floor, Aqua Corridor, Hazira Road, Adajan Paal, Surat-395009.

0261 2747788

revivaldiagnostics.surat@gmail.com

www.revivaldiagnostics.com

This medical report is not intended for medico-legal purposes.



10mm/mV V4	10mm/mV V5	10mm/mV V6	10mm/mV I	10mm/mV II	10mm/mV III	2022-9-24 9:21:59	ID: 00003104
10mm/mV aVR	10mm/mV aVL	10mm/mV aVF	10mm/mV V1	10mm/mV V2	10mm/mV V3	ID Card:	Gender: Female
10mm/mV V4	10mm/mV V5	10mm/mV V6	10mm/mV aVR	10mm/mV aVL	10mm/mV aVF	Name: PRIYANSHI	Height(cm): 155
10mm/mV V4	10mm/mV V5	10mm/mV V6	10mm/mV aVR	10mm/mV aVL	10mm/mV aVF	Age: 30	BP(mmHg): /
10mm/mV V4	10mm/mV V5	10mm/mV V6	10mm/mV aVR	10mm/mV aVL	10mm/mV aVF	Weight(Kg): 58	HR.....bpm 73
10mm/mV V4	10mm/mV V5	10mm/mV V6	10mm/mV aVR	10mm/mV aVL	10mm/mV aVF		P-R.....ms 100
10mm/mV V4	10mm/mV V5	10mm/mV V6	10mm/mV aVR	10mm/mV aVL	10mm/mV aVF		Q-R-S.....ms 86
10mm/mV V4	10mm/mV V5	10mm/mV V6	10mm/mV aVR	10mm/mV aVL	10mm/mV aVF		QT/QTc.....ms 346/380
10mm/mV V4	10mm/mV V5	10mm/mV V6	10mm/mV aVR	10mm/mV aVL	10mm/mV aVF		P/QRS/T AXES.....deg 51/97/51
10mm/mV V4	10mm/mV V5	10mm/mV V6	10mm/mV aVR	10mm/mV aVL	10mm/mV aVF		RV5/SV1.....mV 1.04/0.36
10mm/mV V4	10mm/mV V5	10mm/mV V6	10mm/mV aVR	10mm/mV aVL	10mm/mV aVF		RV5+SV1.....mV 1.40
10mm/mV V4	10mm/mV V5	10mm/mV V6	10mm/mV aVR	10mm/mV aVL	10mm/mV aVF		*The result must be confirmed by doctor!
10mm/mV V4	10mm/mV V5	10mm/mV V6	10mm/mV aVR	10mm/mV aVL	10mm/mV aVF		Report Confirmed by: DR ADITI PATEL

DR ADITI PATEL
 MB, B.S., D. CARD (MUM)
 CLINICAL CARDIOLOGIST
 REG. NO. G-42501

Revival Diagnostic
 401, Aqua Road,
 B/s. Star Bazar, Mob: 395009
 Mo. 91062-28601





REVIVAL DIAGNOSTICS



Name	PRIYANSHI MEHTA	Age/Gender	30Yrs/Female
Reg No.	1941/22	Receipt No	1639
Referred By	BOB - MEDI WHEEL(PKG10000241)	Mode of Payment	CREDIT
Collection Type	CENTER	Collection DateTime	24-Sep-2022 08:56 AM

ECG

- REPORT :

1. The rhythm is sinus.
2. Heart rate is 73 beats per minute.
3. Normal P,QRS,T wave axis.
4. Normal PR,QRS,Q.T. Duration.
5. No pathological q wave or ST-T changes seen.
6. No evidence of chamber hypertrophy or enlargement seen.

IMPRESSION : ECG WITHIN NORMAL LIMITS

Signature

Revival Diagnostic
401, Aqua Corridor,
B/s. Star Bazar, Surat-395009
No. 91062-28601

DR. ADITI PATEL
M.B.B.S., D. CARD (MUM)
CLINICAL CARDIOLOGIST
REG.NO.G-42901



0261 2747788, 9825947712



4th Floor, Aqua Corridor, Hazira Road, Adajan Pal, Surat-395009.



revivaldiagnostics.surat@gmail.com



www.revivaldiagnostics.com



2D-ECHOCARDIOGRAPHY & COLOR DOPPLER REPORT

Name:	PRIYANSHI MEHTA	Age/Gender	30Yrs /Female
Referred by.	MEDI WHEEL	Date	24/09/2022

VITALS: BP = 110/72mmHg, PULSE =84 bpm, SPO2 =98%

INDICATION: Preventive Health check up

- **CARDIAC CHAMBERS:** Left Ventricle: Normal size, Left Atrium: Normal size.
- No e/o thrombus in LA/LV.
- **Right Atrium:** Normal size. **Right Ventricle:** Normal size,
- **Normal Right Ventricular function.** (TAPSE=20mm)
- **Normal Left Ventricular systolic function. LVEF = 60% ,**
No regional wall abnormality. No thinning / scarring / dyskinesia of LV wall.
- **No Concentric Left Ventricular Hypertrophy.** (IVSd= 11 mm),
- **LV Compliance :**
No Left Ventricular Diastolic Dysfunction [LVDD]. No Doppler e/o raised LVEDP.
- **VALVES:**
- Structurally Normal Mitral valve/ Aortic valve/Tricuspid valve/ Pulmonary valve .
No significant Valvular Stenosis.
- **Doppler findings:** AV max = 1.21 m/s, PV max = 0.9 m/s.
Trivial Pulmonary Regurgitation, Trivial Tricuspid regurgitation.
- **No Pulmonary Arterial Hypertension. PASP** by TRjet vel.method = 23 mmHg.
- **SEPTAE:** IAS / IVS Appear Intact.
- **IVC :** Normal in dimension and shows good inspiratory 15mm collapse.
- **OTHERS:** No e/o Pericardial effusion / vegetation.

IMPRESSION:

**NORMAL LV SYSTOLIC FUNCTION, LVEF= 60 %, NO RWMA,
NO LVH , NO LVDD ,NO TRIVIAL PR/TR, NO PAH.**

Revival Diagnostic

401, Aqua Corridor,
8/s. Star Bazar, Surat-395009
Mo. 91062-28601

DR. SUSHIL YADAV
CONSULTING & CLINICAL
CARDIOLOGIST



0261 2747788, 9825947712



4th Floor, Aqua Corridor, Hazira Road, Adajan Pal, Surat-395009.



revivaldiagnostics.surat@gmail.com



www.revivaldiagnostics.com



Revival Diagnostic

401 Aqua corridor Beside star Bazaar, Opp Cable Bridge,
Adajan Hajira main road, Pal Adajan, Surat-395009
Ph : 0261 2747788, 9825947712

Name	PRIYANSHI MEHTA	Age/Gender	30Yrs/Female
Reg No.	1941/22	Receipt No	1639
Referred By	BOB - MEDI WHEEL(PKG10000241)	Mode of Payment	CREDIT
Collection Type	CENTER	Collection DateTime	24-Sep-2022 08:56 AM

USG OF ABDOMEN & PELVIS

LIVER:

Liver is normal in size, shape and echotexture.

No evidence of focal SOL or dilatation of IHBR seen.

Portahepatis appear normal.

GALLBLADDER:

Gallbladder is distended and appears normal.

No e/o calculus, mass lesion or changes of cholecystitis seen.

PANCREAS:

Pancreas appears normal in size, shape and echotexture.

No e/o focal lesion, mass or changes of pancreatitis seen.

SPLEEN:

Spleen appears normal in size, shape and echotexture.

PARAAORTIC REGION:

Aorta grossly appears normal. No e/o paraaortic lymphnodes seen.

KIDNEYS:

Both kidneys appear normal in size, shape, position and echotexture.

Cortex and collecting system of both kidneys appear normal.

No evidence of calculus or obstructive uropathy on either side.

URINARY BLADDER:

Bladder is distended and appears normal.

No calculus, mass lesion or changes of cystitis is seen.

UTERUS:

Dr. Chirag K. Patel
MBBS-DMPD
Reg. No. G-23509
Revival Diagnostic
4th Floor, Aqua Corridor,
Nr. Star Bazar, Hazira Main Road,
Adajan, Surat-395009.
Mo. 97266 726683



Revival Diagnostic

401 Aqua corridor Beside star Bazaar, Opp Cable Bridge,
Adajan Hajira main road, Pal Adajan, Surat-395009
Ph : 0261 2747788, 9825947712

Name	PRIYANSHI MEHTA	Age/Gender	30Yrs/Female
Reg No.	1941/22	Receipt No	1639
Referred By	BOB - MEDI WHEEL(PKG10000241)	Mode of Payment	CREDIT
Collection Type	CENTER	Collection DateTime	24-Sep-2022 08:56 AM

Retroverted, Normal in size, shape and echotexture with empty central uterine cavity.

Cervix appears normal.

No e/o focal SOL. Endometrial thickness is normal

OVARIES:

Both adnexal region appear normal.

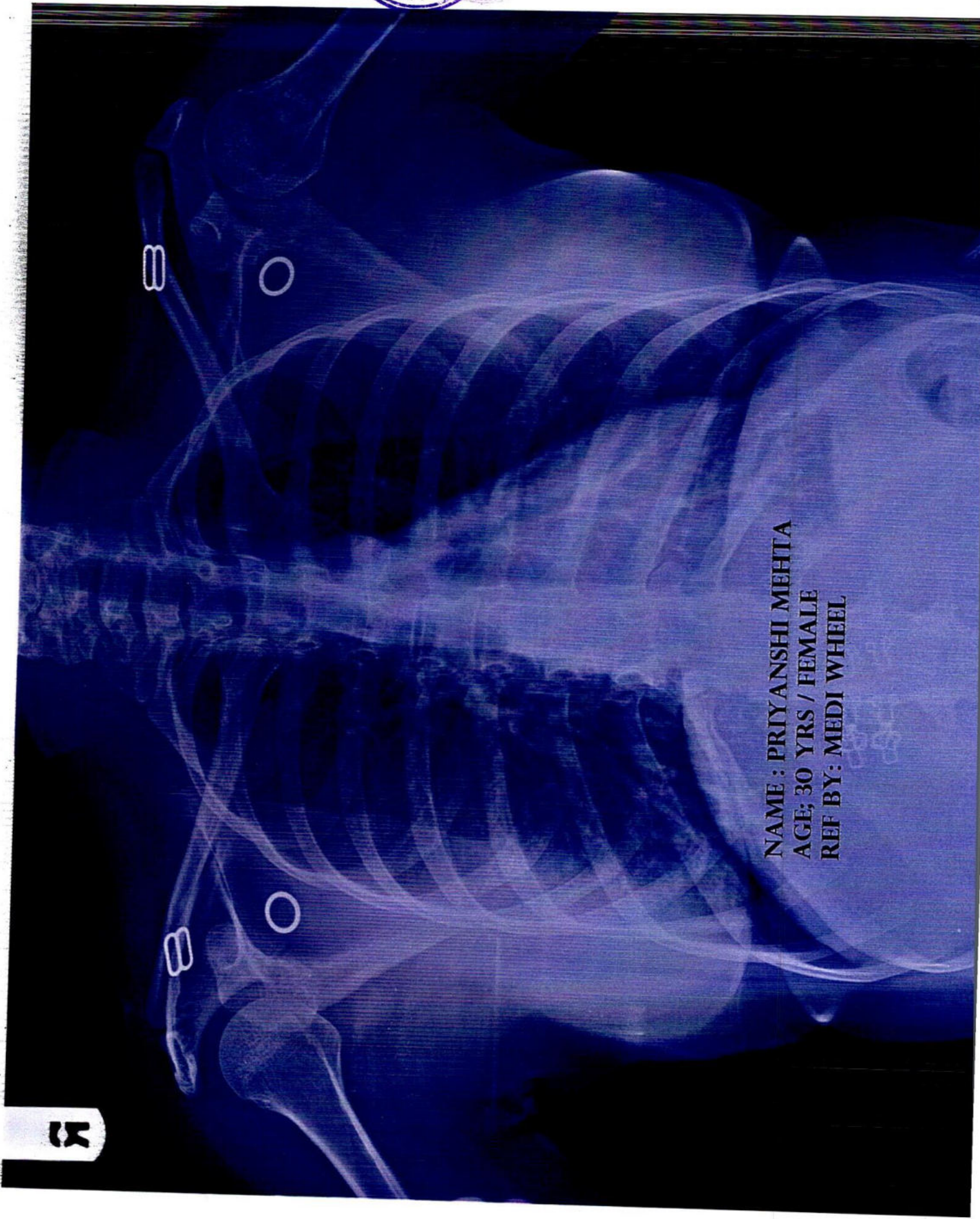
left ovarian complex cyst 49 x 39 mm

No evidence of free fluid seen in pelvis.

COMMENTS:

left ovarian complex cyst 49 x 39 mm

Dr. Chirag K. Patel
MBBS-DMPD
Reg. No. G-23509
Reviva Diagnostic
4th Floor, Aqua Corridor,
Nr. Star Bazar, Adajan, Surat-395009.
Radiologist
Mo. 97266 726683



NAME : PRIYANSHI MEHTA
AGE; 30 YRS / FEMALE
REF BY: MEDI WHEEL

15



Name	PRIYANSHI MEHTA	Age/Gender	30Yrs/Female
Reg No.	1941/22	Receipt No	1639
Referred By	BOB - MEDI WHEEL(PKG10000241)	Mode of Payment	CREDIT
Collection Type	CENTER	Collection DateTime	24-Sep-2022 08:56 AM

CHEST RADIOGRAPH (PA VIEW)

- Hilar shadows are within normal limits.
- Pulmonary vasculature appears normal.
- Cardiac appears normal in size.
- Both domeh of the diaphragm are smooth.
- Both costophrenic recesses are clear.
- Both lung fields appear normal.
- Visualized bones and soft tissue shadows appear normal.

IMPRESSION: NORMAL STUDY.

DR.CHIRAG K PATEL
RADIOLOGIST

REVIVAL
DIAGNOSTICS

Dr. Chirag K. Patel
MBBS-DMPD
Reg. No. G-23509
Revival Diagnostic
4th Floor, Aqua Corridor,
Nr. Star Bazar, Hazira Main Road,
Adajan, Surat-395009.
Mo. 97266 726683

Laboratory Test Result are Subject to technical limitation and should be clinically correlate for final diagnosis




भारतीय जनसंख्या प्रमाणन प्राधिकरण
UNIQUE IDENTIFICATION AUTHORITY OF INDIA

સરનામું :

D/O: પ્રવિન ભાઈ, 40, જોગાની નગર-2, સૂર્ય વીર
કેસ રોડ, સૂર્ય વીર રોડ, સુરત શીટી, સુરત,
ગુજરાત - 395009

Address :

D/O: Pravin Bhal, 40, jogani nagar-2,
opp new water tank, new rander road,
Surat City, Surat,
Gujarat - 395009



1947

help@uidai.gov.in



www.uidai.gov.in

WWW

P.O. Box No. 1947
Bengaluru-560 001