

**Facilities:**

All clinical Biomedical & Hematology Investigations including Bone Marrow Examination VPT, Podiascan & Complete Foot Care (First Time in Purvanchal) All Hormonal Investigation by Chemiluminescent Method Visceral Fat by (AB-140) Ambulatory BP Monitoring CGMS & Insulin Pump Available PFT, 2D-ECHO (Color Doppler), Holter, TMT, Cardiac-3 available VIA, VILI, Colposcopy available Special Endocrinological Investigation Protocols.

ISO 9001:2008 Certified  
Mobile: 9389994334, 9554572190, 9453837595



**Panacea Pathology**  
**Clinical Reference Lab**  
Persistence, Preparedness and Precision  
EQAS (CMC Vellore Attached) & IQAS System  
पूर्वांचल की सर्वोत्तम गुणवत्ता वाली पैथोलॉजी

PATIENT NAME : BIMLA ARYA

AGE/GENDER : 48YRS/FEMALE

REFD BY DR. : ARCO FEMI HEALTHCARE LTD.

RECEIVED DATE : 25-03-2023 (09:00 AM)

SAMPLE : BLOOD & URINE

REPORT DATE : 25-03-2023 (07:00 PM)

## PATHOLOGY REPORT

### COMPLETE BLOOD COUNT (CBC)

TEST	LAB TEST VALUES	NORMAL RANGE
<b>HEMOGRAM</b>		
HEMOGLOBIN (FLOW CYTOMETRY)	11.3	13 – 16 gm/dl
TOTAL LEUCOCYTE COUNT (TLC)	6,700	4000 – 11000
RBC COUNT	4.51	3.5 – 5.5
PCV (HCT)	38.0	37 – 47
MCV	84.3	80 – 95
MCH	25.1	28 – 34
MCHC	29.8	30 – 36
PLATELET COUNT	2,12,000	1,50,000 – 4,00,000
E.S.R. (WINTROBE FIRST HOURS)	12.0	20 mm/1 <sup>st</sup> hr
<b>DIFFERENTIAL LEUCOCYTE</b>		
NEUTROPHILS	59	40 – 75%
LYMPHOCYTES	37	20 – 45%
EOSINOPHILS	02	1 – 6%
MONOCYTES	02	2 – 8%
BASOPHILS	00	< 2%

### RANDOM/FASTING BLOOD SUGAR

TEST	LAB TEST VALUES	NORMAL RANGE
<b>RBS/FBS</b>		
RANDOM BLOOD SUGAR	142.0	125-140 mg/dl
FASTING BLOOD SUGAR	93.0	70-125 mg/dl

### GLYCOSYLATED HEMOGLOBIN (HBA1C)

TEST	LAB TEST VALUES	NORMAL RANGE
HBA1C	6.3	Normal : <5.97 % Good Control : 5.97 – 6.81% Fair Control : 6.81 – 7.65% Poor Control : >7.65%

PAGE 1

Lab Technician

**PANACEA HOSPITAL**  
(A UNIT OF ARCO HEALTH CARE PVT. LTD)  
REG. NO.: AL-1500  
B.36/44 B-4 KABIR NAGAR  
DURGAKUND, VARANASI  
M.D. Pathology

Timing : 8.00 a.m. to 9.00 p.m. (Sunday 8.00 a.m. to 3.00 p.m.)

This Report is not valid for medico legal purpose

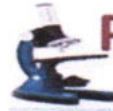**Note:** These tests have technical limitations. Clinico-pathological interpretation is necessary. In case of any disparity test may be repeated immediately.

Address : 36/44 FK Kabir Nagar, Durgakund, Varanasi – 221005

Email: [dramishra@gmail.com](mailto:dramishra@gmail.com), [drpallaviojha@gmail.com](mailto:drpallaviojha@gmail.com) Website: [panaceahospital.org](http://panaceahospital.org)

ies:  
 Clinical Biomedical & Hematology Investigations  
 including Bone Marrow Examination  
 VPT, Podiascan & Complete Foot Care (First Time in Purvanchal)  
 All Hormonal Investigation by Chemiluminescent Method  
 Visceral Fat by (AB-140) Ambulatory BP Monitoring  
 CGMS & Insulin Pump Available  
 PFT, 2D-ECHO (Color Doppler), Holter, TMT, Cardiac-3 available  
 VIA, VILI, Colposcopy available  
 Special Endocrinological Investigation Protocols.

ISO 9001:2008 Certified  
 Mobile: 9389994334, 9554572190, 9453837595



# Panacea Pathology

## Clinical Reference Lab

Persistence, Preparedness and Precision  
 EQAS (CMC Vellore Attached) & IQAS System  
 पूर्वीचल की सर्वोत्तम गुणवत्ता वाली पैथोलॉजी

PATIENT NAME : BIMLA ARYA

AGE/GENDER : 48YRS/FEMALE

REFD BY DR. : ARCO FEMI HEALTHCARE LTD.

RECEIVED DATE : 25-03-2023 (09:00 AM)

SAMPLE : BLOOD & URINE

REPORT DATE : 25-03-2023 (07:00 PM)

### PATHOLOGY REPORT

#### LIPID PROFILE, SERUM

TEST	LAB TEST VALUES	NORMAL RANGE
<b>BLOOD CHEMISTRY</b>		
TOTAL CHOLESTEROL (SERUM)	178.0	Desirable:- &lt; 200 mg/dl Borderline:- 200 – 239 mg/dl High:- &gt; 240 mg/dl
TRIGLYCERIDES (SERUM)	165.0	35 – 170 mg/dl
HDL CHOLESTEROL (SERUM)	44.0	35.30 – 79.50 mg/dl
LDL CHOLESTEROL (SERUM)	101.0	&lt; 130 mg/dl
VLDL	33.0	&lt; 40 mg/dl
CHOLESTROL/HDL RATIO	4.0	&lt; 3.0 Low Risk Ratio 3.0 – 5.0 Avg Risk &lt; 5.0 High Risk
LDL/HDL RATIO	2.2	&lt; 3 Ratio

#### BLOOD GROUP

TEST	LAB TEST VALUES
<b>BLOOD GROUP ABO &amp; RH FACTOR</b>	
BLOOD GROUP	"B"
RH FACTOR	POSITIVE

#### LIVER PROFILE TEST, SERUM

TEST	LAB TEST VALUES	NORMAL RANGE
<b>BIO CHEMISTRY</b>		
TOTAL BILIRUBIN	0.62	0.0 – 1.1 mg/dl
DIRECT BILIRUBIN	0.22	0.0 – 0.2 mg/dl
INDIRECT BILIRUBIN	0.40	< 0.90 mg/dl
SGOT (AST)	25.0	0 – 52 mg/dl
SGPT (ALT)	27.0	0 – 39 mg/dl
GGT (GYT)	23.0	< 55 U/L

#### THYROID PROFILE (T3, T4, TSH)

TEST	LAB TEST VALUES	NORMAL RANGE
<b>THYROID FUNCTION TEST</b>		
T3	0.92	0.60 – 1.81 ng/ml
T4	8.14	4.50 – 10.90 ug/dl
TSH	1.37	0.39 – 6.10 uIU/ml

PAGE 2

Lab Technician

**PANACEA HOSPITAL**  
 (A UNIT OF AAROHAN HEALTHCARE PVT. LTD.)  
 REG. NO. DL-1500  
 B.36/44 M.D. Pathology  
 DURGAKUND, VARANASI

Timing : 8.00 a.m. to 9.00 p.m. (Sunday 8.00 a.m. to 3.00 p.m.)

This Report is not valid for medico legal purpose

**Note:** These tests have technical limitations. Clinico-pathological interpretation is necessary. In case of any disparity test may be repeated immediately.

Address : 36/44 FK Kabir Nagar, Durgakund, Varanasi – 221005

Email: [dramishra@gmail.com](mailto:dramishra@gmail.com), [drpallaviojha@gmail.com](mailto:drpallaviojha@gmail.com) Website: [panaceahospital.org](http://panaceahospital.org)

Services:  
 Clinical Biomedical & Hematology Investigations  
 including Bone Marrow Examination  
 VPT, Podiascan & Complete Foot Care (First Time in Purvanchal)  
 All Hormonal Investigation by Chemiluminescent Method  
 Visceral Fat by (AB-140) Ambulatory BP Monitoring  
 CGMS & Insulin Pump Available  
 PFT, 2D-ECHO (Color Doppler), Holter, TMT, Cardiac-3 available  
 VIA, VILI, Colposcopy available  
 Special Endocrinological Investigation Protocols.

ISO 9001:2008 Certified  
 Mobile: 9389994334, 9554572190, 9453837595



# Panacea Pathology

## Clinical Reference Lab

Persistence, Preparedness and Precision  
 EQAS (CMC Vellore Attached) & IQAS System  
 पूर्वांचल की सर्वोत्तम गुणवत्ता वाली पैथोलॉजी

PATIENT NAME : BIMLA ARYA

AGE/GENDER : 48YRS/FEMALE

REFD BY DR. : ARCO FEMI HEALTHCARE LTD.

RECEIVED DATE : 25-03-2023 (09:00 AM)

SAMPLE : BLOOD & URINE

REPORT DATE : 25-03-2023 (07:00 PM)

## PATHOLOGY REPORT

### RENAL & KIDNEY PROFILE, SERUM

TEST	LAB TEST VALUES	NORMAL RANGE
<b>RENAL FUNCTION TESTS</b>		
BLOOD UREA NITROGEN (BUN)	10.7	10 – 50 mg/dl
SERUM CREATININE	0.75	0.60 – 1.60 mg/dl
URIC ACID	4.41	3.60 – 7.70 mg/dl
ALKALINE PHOSPHATASE (ALP)	71.0	142 – 353 mg/dl
TOTAL PROTIENS	7.42	0 – 39 mg/dl
ALBUMIN	4.20	3.8 – 5.4 mg/dl
SERUM GLOBULIN	3.22	2.1 – 3.5 mg/dl
AG RATIO	1.30	-
CALCIUM	9.0	8.80 – 10.20
PHOSPHORUS	3.02	2.50 – 5.00
SERUM SODIUM NA+	138.0	135.00 – 155.00 mEq/Ltr
SERUM POTASIUUM K+	4.38	3.60 – 5.50 mEq/Ltr
ICALCIUM	1.24	1.10 – 1.35 mmol/L
SERUM CHLORIDE CL+	109.2	98.00 – 110.00 mEq/Ltr

### URINE ROUTINE EXAMINATION

TEST	LAB TEST VALUES	NORMAL RANGE
<b>PHYSICAL EXAMINATION</b>		
QUANTITY	30	ML
COLOUR	STRAW	PALE YELLOW
APPEARANCE	CLEAR	CLEAR
SPECIFIC GRAVITY	1.010	1.01 – 1.03
PH	6.5	4.7 – 7.5
<b>CHEMICAL EXAMINATION</b>		
GLUCOSE	Not Detected	Not Detected
PROTEIN	NIL	Not Detected
<b>MICROSCOPIC EXAMINATION</b>		
PUS CELLS	NIL	0-5
RBC	Not Detected	Not Detected
EPITHELIAL CELLS	01-05	0-5
CASTS	Not Detected	Not Detected
CRYSTALS	Not Detected	Not Detected
BACTERIA	Not Detected	Not Detected

----- End of Report -----

Lab Technician

**PANACEA HOSPITAL**  
 (A UNIT OF AAROA HEALTHCARE PVT. L)  
 REG. NO.: AL-1500  
 B.36/44, B.M. K. NAGAR  
 DURGAKUND, VARANASI

Timing : 8.00 a.m. to 9.00 p.m. (Sunday 8.00 a.m. to 3.00 p.m.)

This Report is not valid for medico legal purpose

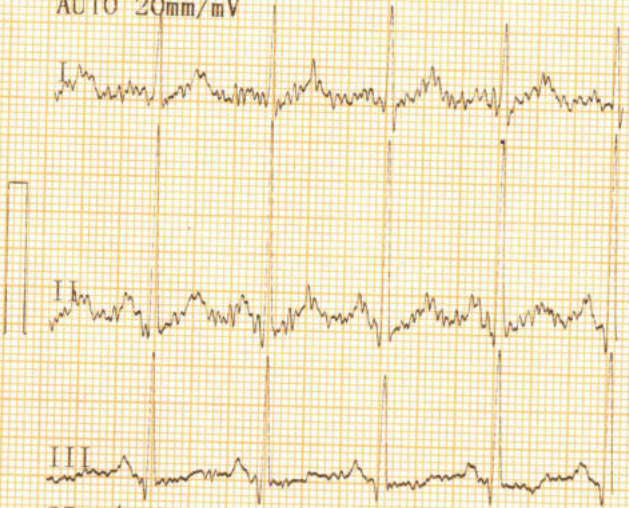
**Note:** These tests have technical limitations. Clinico-pathological interpretation is necessary. In case of any disparity test may be repeated immediately.

**Address :** 36/44 FK Kabir Nagar, Durgakund, Varanasi – 221005

**Email:** [dramishra@gmail.com](mailto:dramishra@gmail.com), [drpallaviojha@gmail.com](mailto:drpallaviojha@gmail.com) **Website:** [panaceahospital.org](http://panaceahospital.org)

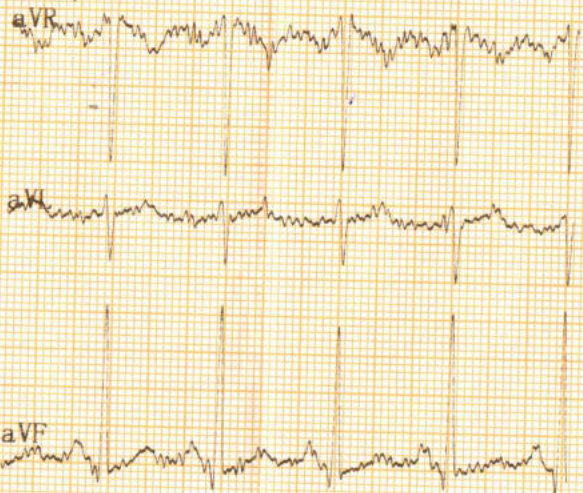BPL

AUTO 20mm/mV

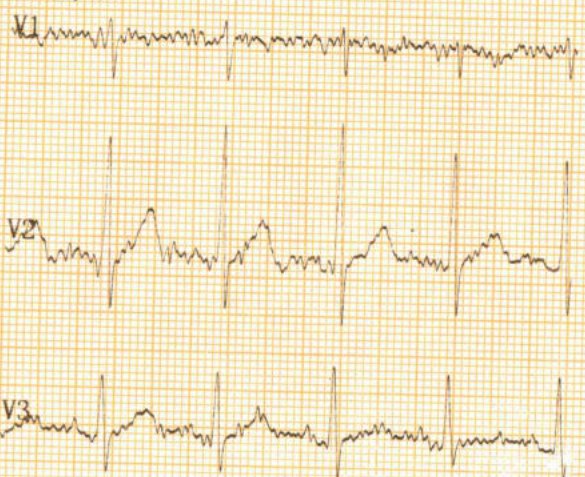

25mm/s AC50Hz+EMG35Hz+DFT

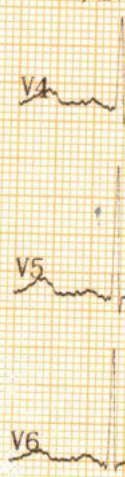20mm/mV



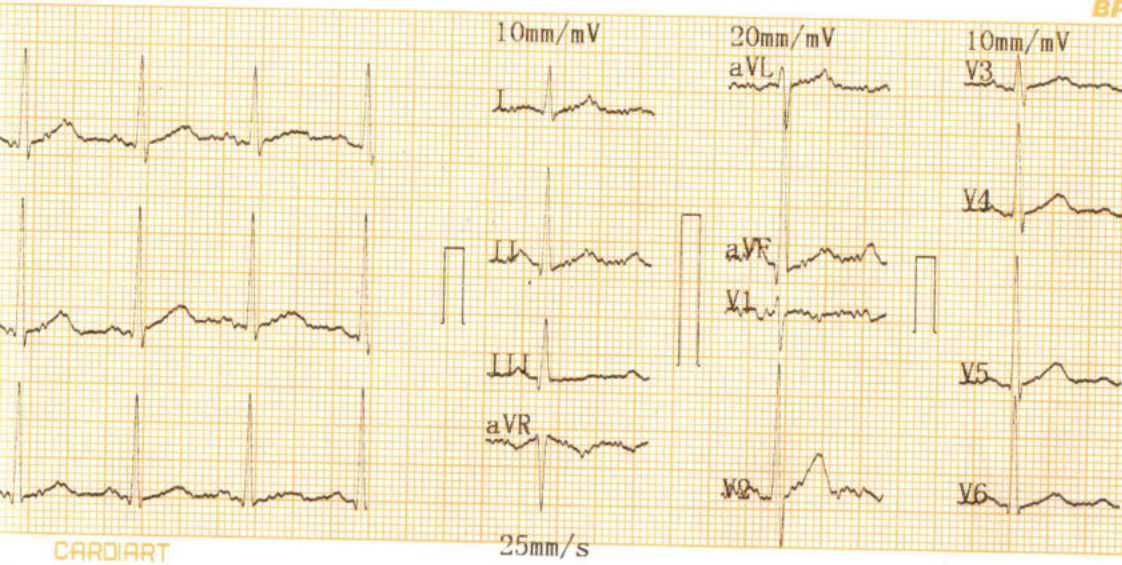
20mm/mV



10mm/mV



BPL



2022-03-25 11:46

<< Conclusions >>

ID :  
 Name : **Vinla Aarya**  
 Sex : **F**      Age : **47y**  
 Height :      Weight :      kg  
 SYS :  
 DIA :

Normal Sinus Rhythm,  
 Cardiac electric axis normal;  
 \*\*Report need physician confirm\*\*

HR      bpm : 98  
 PR Interval      ms : 168  
 P Duration      ms : 120  
 QRS Duration      ms : 70  
 T Duration      ms : 247  
 QT/QTc      ms : 367/469  
 P/QRS/T Axis      deg : 64.0/65.7/32.3  
 R(V5)/S(V1)      mV : 1.73/0.23  
 R(V5)+S(V1)      mV : 1.96

*Pallavi*  
**DR. PALLAVI MISHRA**  
 MBBS, MD (GENERAL MEDICINE)  
 MCI Reg.No. 52033

Physician \_\_\_\_\_

CARDIART



Call Now - 1800-123-3070

# PANACEA HOSPITAL

*A shelter for many hearts A Home for many lives*

(An ISO 9001:2008 Certified Organisation)

Lab Attached with CMC Vellore Under EQAS Scheme

PATIENT'S NAME : VIMLA ARYA

AGE/SEX: 47 Y/F

REF. BY : Dr. ASHUTOSH MISHRA(MD)

Saturday, March 25, 2023

## Echo - Cardiography

MITRAL VALVE Doppler	AML - normal morphology MV Flow - E - 0.7 A-0.6 E/A=1.23	PML - normal morphology MVA - 3.0 cm <sup>2</sup> Mitral Regurgitation - <b>Trivial MR</b>
TRICUSPID VALVE Doppler	Normal TV Flow -No	Tricuspid Regurgitation - <b>No</b>
PULMONARY VALVE Doppler	Normal PV Flow -No	Pulmonary Regurgitation - No
AORTIC VALVE Doppler	Trileaflet-No AV Flow - no	Aortic Regurgitation - no
MEASUREMENT	Aorta - 28.6 (20-38) mm IVS ed - 8.6 (6 -12) mm LVID ed - 60.0 (35 - 55) mm LVPW ed - 6.9 (6 -12) mm OA - 7 (> 5) mm	LA - 34.8 (24-32) mm IVS es -14.8 (6 - 12) mm LVID es - 40.5 (24 - 40) mm LVPW es - 19.4 (6 -12) mm EPSS - 4 (< 9) mm

CONCLUSION All cardiac chamber dimensions are WNL  
**Trivial MR & rest other valve are WNL**  
Good LV systolic function present Modified Simpson's method (4C, 2C) (LVEF-60%)  
**NO diastolic dysfunction present (E/A = 1.23) by tissue Doppler (E/e'=6.8)**  
Rest all other finding are WNL

IMPRESSION All cardiac chamber dimensions are WNL  
**Trivial MR & rest other valve are WNL**  
Good LV systolic function present Modified Simpson's method (4C, 2C) (LVEF-60%)  
**NO diastolic dysfunction present (E/A = 1.23) by tissue Doppler (E/e'=6.8)**  
Rest all other finding are WNL

Normal Echocardiogram

Niraj Mishra  
Physician Assistant  
(PIIRE)

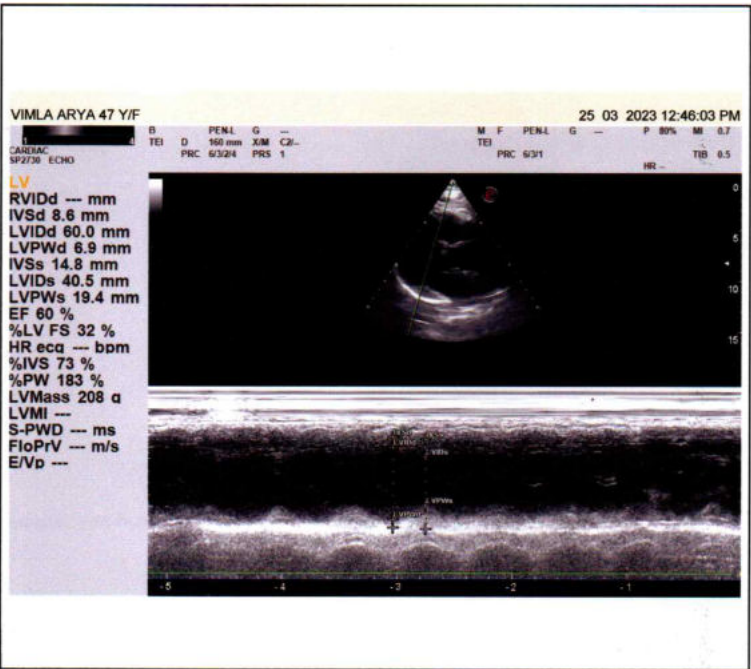
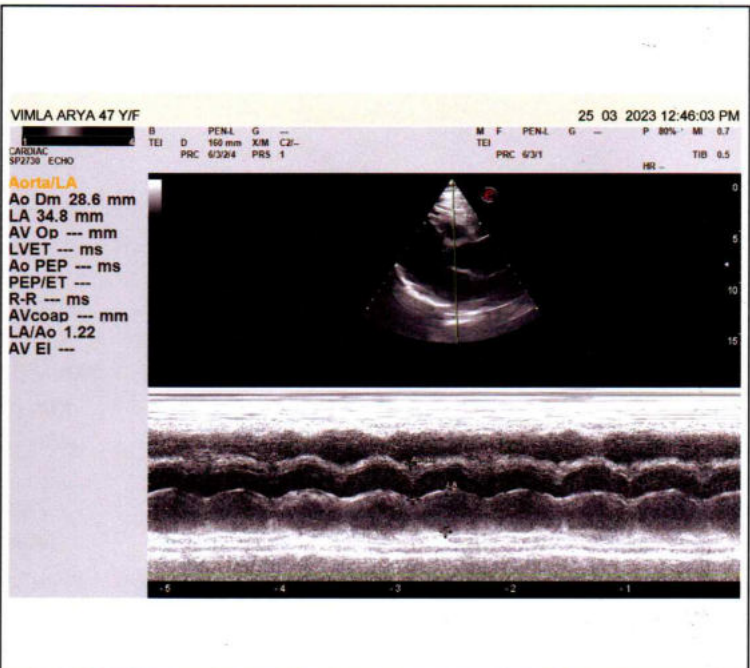
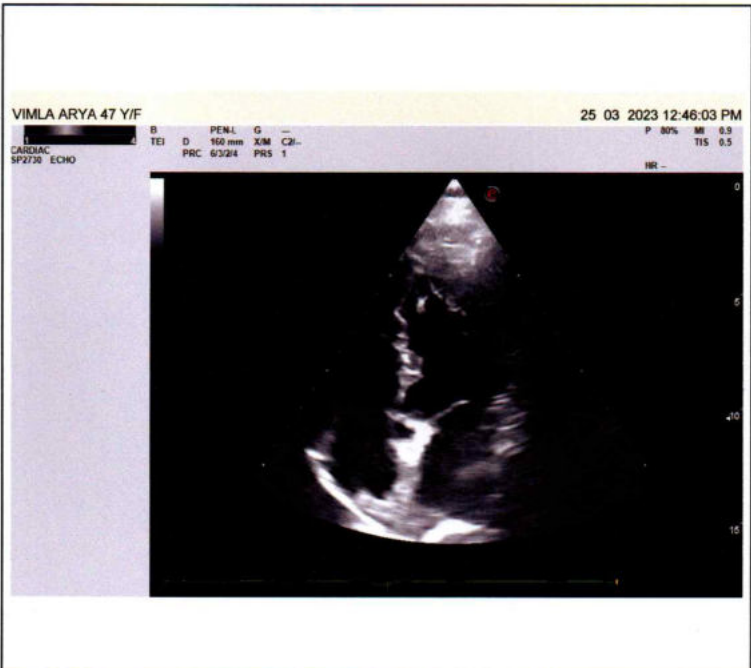
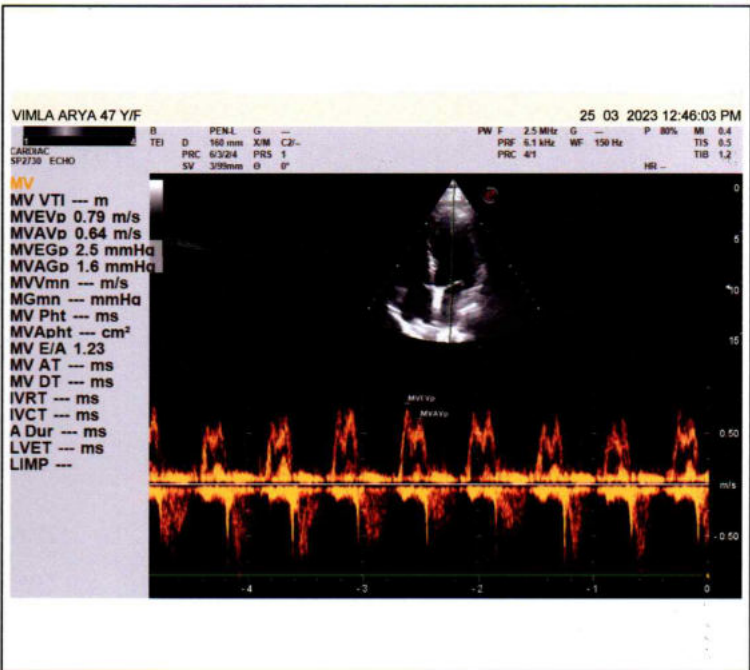
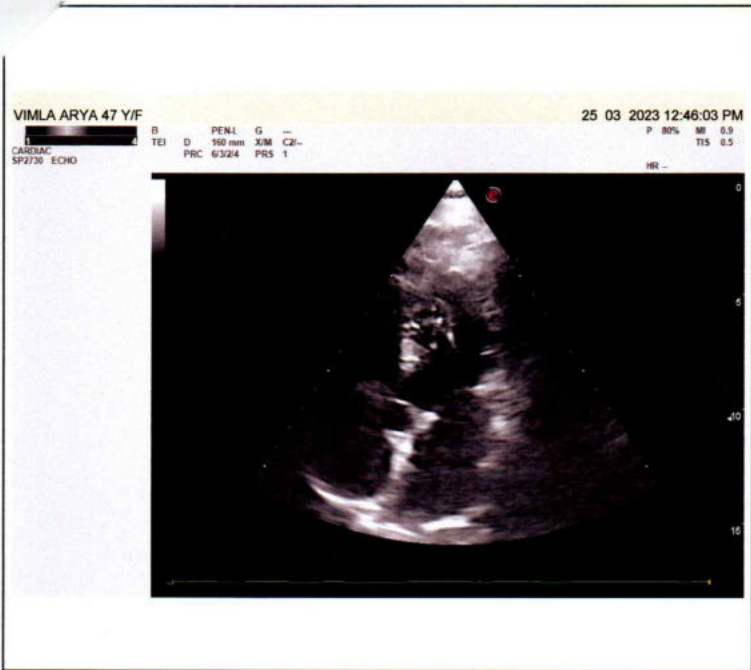Dr. Pallavi Mishra  
MBBS, MD (MED) Lucknow  
Echocardiography Specialist, MIAE  
Non-invasive cardiologist

**DR. PALLAVI MISHRA**  
MBBS, MD (GENERAL MEDICINE)  
MCI Reg.No. 52033

Address : Kabir Nagar (Near Sanjay Shiksha Niketan), Durgakund, Varanasi

Mobile : 9554572190 / 9453837595 / Recpn. 9389994334

E-mail : dramishra@gmail.com, drpallaviojha@gmail.com, Website: www.piire.org





# PANACEA HOSPITAL


*A shelter for many hearts A Home for many lives*

(An ISO 9001:2008 Certified Organisation)

PATIENT'S NAME: **Vinlayya** AGE/SEX: **47 Y/F**  
 Lab Attached with: **CMC Vellore Under EQAS Scheme**  
 REF. BY: **Dr. ASHUTOSH MISHRA (MBBS, M.S.)** Saturday, March 25, 2023

## U/S. WHOLE ABDOMEN

- LIVER** : Liver is normal in size, shape & echotexture. Intra hepatic biliary radicals are normal. Portal venous channels are normal.
- C.B.D.** : C.B.D. is normal in caliber.
- PANCREAS** : Pancreas is normal in size, shape and echotexture. No evidence of any inflammatory disease or mass.
- SPLEEN** : Spleen is normal in size, shape and echotexture.
- Rt. KIDNEY** : Normal in size, shape and echotexture. Renal sinus is normal  
Cortico medullary differentiation is normal. P. C. system is normal.
- Lt. KIDNEY** : Normal in size, shape and echotexture. Renal sinus is normal  
Cortico medullary differentiation is normal. P. C. system is normal.
- URI. BLADDER** : Urinary bladder is normal in size, position. Wall thickness normal.  
No evidence of calculus or mass.
- UTERUS** : Normal in size, shape & echotexture. Endometrial echo is normal.
- OVARIES** : Rt. Ovary:- Normal in size.  
Lt. Ovary:- Normal in size.  
No free fluid seen in P. O. D.
- IMPRESSION** : **NO OBVIOUS SONOLOGICAL ABNORMALITY SEEN.**

  
**DR. R. TIWARI**  
 (M.B.B.S, M.D.(KGMU, LKO)  
 (RADIODIAGNOSIS).

*Thanks for reference.*

Address : Kabir Nagar (Near Sanjay Shiksha Niketan), Durgakund, Varanasi

Mobile : 9554572190 / 9453837595 / Recpn. 9389994334

E-mail : dramishra@gmail.com, drpallaviojha@gmail.com, Website: www.piire.org



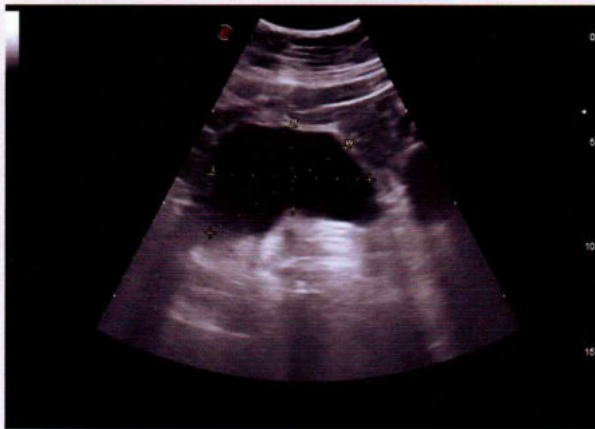VIMLA ARYA 47Y/F

25 03 2023 10:01:20 AM

ABDOMINAL AC2541 KIDNEY  
B D GEN.M G  
TEI D 169 mm XM C2-  
PRC 242/3/5 PRS 6

P 60% MI 0.9

**Urinary Bladder**  
L 75.6 mm  
H 39.3 mm  
W 76.1 mm  
Vol 118.3 ml



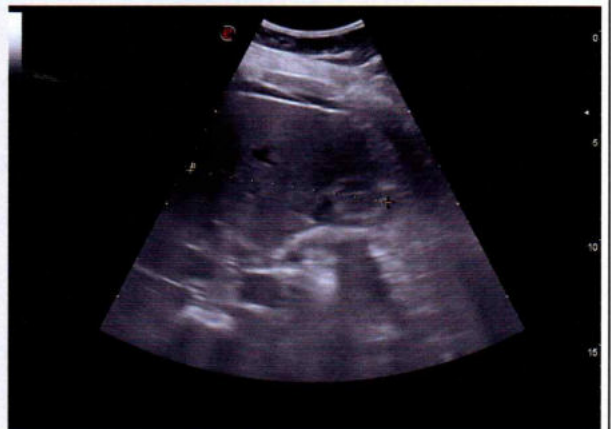VIMLA ARYA 47Y/F

25 03 2023 10:01:20 AM

ABDOMINAL AC2541 KIDNEY  
B D GEN.M G  
TEI D 169 mm XM C2-  
PRC 242/3/5 PRS 6

P 60% MI 0.9

**Liver Long Dist**  
D 95.9 mm



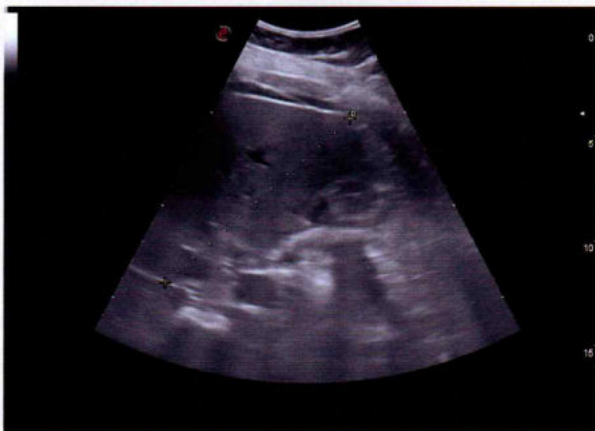VIMLA ARYA 47Y/F

25 03 2023 10:01:20 AM

ABDOMINAL AC2541 KIDNEY  
B D GEN.M G  
TEI D 169 mm XM C2-  
PRC 242/3/5 PRS 6

P 60% MI 0.9

**Liver Transv Dist**  
D 118.0 mm

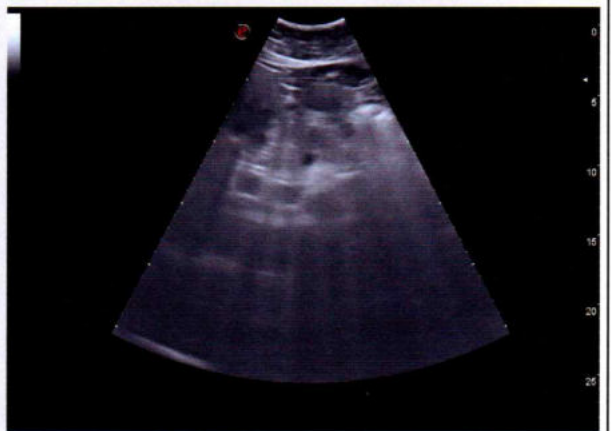

VIMLA ARYA 47Y/F

25 03 2023 10:01:20 AM

ABDOMINAL AC2541 KIDNEY  
B D GEN.M G  
TEI D 257 mm XM C2-  
PRC 242/3/5 PRS 6

P 60% MI 0.9

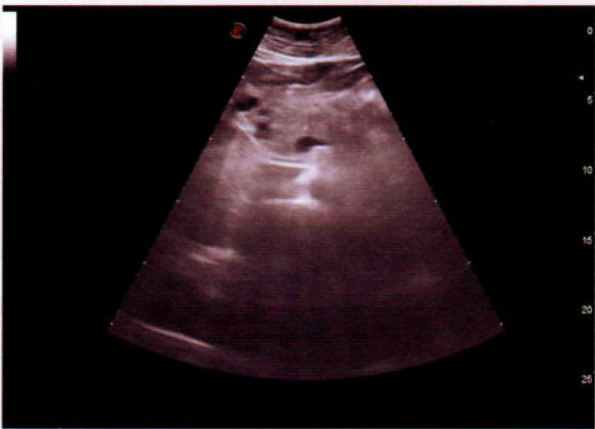

VIMLA ARYA 47Y/F

25 03 2023 10:01:20 AM

ABDOMINAL AC2541 KIDNEY  
B D GEN.M G  
TEI D 257 mm XM C2-  
PRC 242/3/5 PRS 6

P 60% MI 0.9





Call Now - 1800-123-3070

# PANACEA HOSPITAL

*A shelter for many hearts A Home for many lives*

(An ISO 9001:2008 Certified Organisation)

Lab Attached with CMC Vellore Under EQAS Scheme

**NAME:VIMLA ARYA**

**AGE/SEX: 47 YRS /FEMALE**

**REFBY:DR.ASHUTOSH MISHRA(MD)**

**DATE:29/03/2023**

## X-RAY CHEST PA

### BOTH LUNG FIELDS AND PLEURAE:

Both lungs show normal bronchovascular pattern.

Right & left hila are normal

No focal mass or calcification is seen

There is no evidence of any fluid in the both the pleural cavities.

Both domes of diaphragms are normal in position.

### MEDIASTINUM:

Trachea is central in position.

Cardiac silhouette is of normal size and configuration.

No evidence of pericardial effusion.

No significant lymphadenopathy is seen.

Visualized skeleton is normal.

-----  
NO SIGNIFICANT RADIOGRAPHIC ABNORMALITY.

*[Signature]*  
**REPORTED BY**

**DR. Rahul Kumar Tiwari**

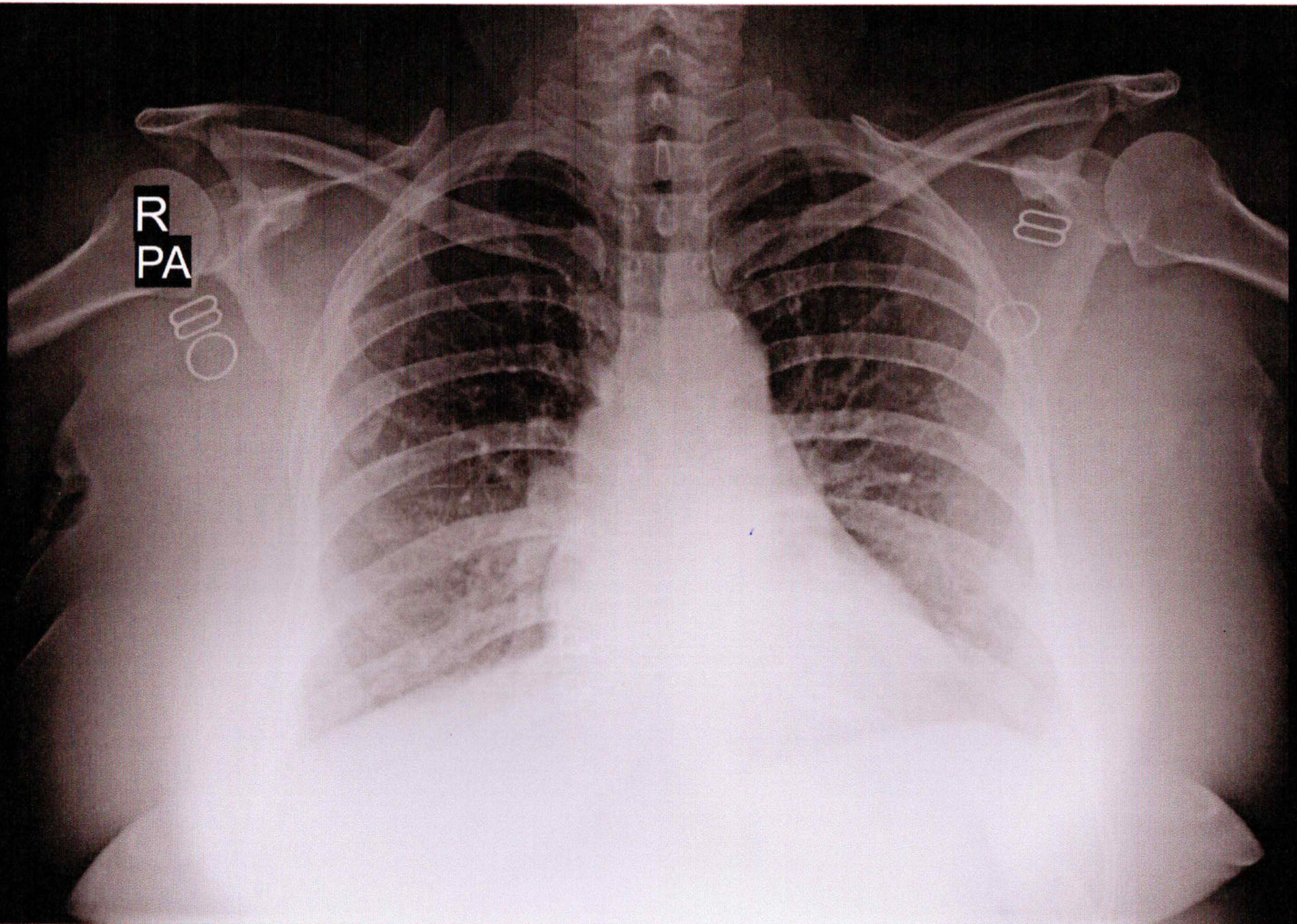
MBBS, MD (Radio Diagnosis)

Reg.No. 57557

**Address : Kabir Nagar (Near Sanjay Shiksha Niketan), Durgakund, Varanasi**

**Mobile : 9554572190 / 9453837595 / Recpn. 9389994334**

**E-mail : dramishra@gmail.com, drpallaviojha@gmail.com, Website: www.piire.org**



VIMLA ARYA 47Y\F 4163 O CHEST P.A. 25-Mar-23 10:57 AM

PANACEA HOSPITAL, KABIR NAGAR, DURGAKUND, VARANASI