



भारत सरकार
GOVERNMENT OF INDIA



पुरोहित वीवेककुमार दीपकभाई
Purohit Vivekkumar Deepakbhai
DOB: 01-09-1991
Gender: Male



9835 8104 3387

आधार - आम आदमी का अधिकार



भारतीय विशिष्ट पहचान प्राधिकरण
UNIQUE IDENTIFICATION AUTHORITY OF INDIA

दीपकभाई पुरोहित, अ/22, शरदा
सोसायटी, मोतीनगर पास, जलाराम
हॉस्पिटल सामे, वरसिया, वडोदरा,
फतेपुरा, वडोदरा, गुजरात, 390006

Address:
S/o, Deepakbhai Purohit, A/22,
Sharda Society, Near Motinagar,
Opposite Jalaram Hospital, Varsia,
Vadodara, Fatepura, Vadodara,
Gujarat, 390006



1947
1800 300 1947

help@uidai.gov.in

www
www.uidai.gov.in

P.O. Box No. 1947,
Bengaluru-560 001



बैंक ऑफ़ बड़ौदा
Bank of Baroda


नाम
Name


विवेककुमार डी. पुरोहित
VIVEKKUMAR D. PUROHIT

कार्यकारी कूट क्र.
E.C. No.

122948




जारीकर्ता प्राधिकारी
Issuing Authority


धारक के हस्ताक्षर
Signature of Holder

Compose

Inbox

93

Starred

Snoozed

Sent

Drafts

9

More

Labels

Fwd: Health Check up Booking Confirmed Request(bobE34581),Package Code-F Beneficiary Code-31682

Inbox x



vivek purohit <vivekresearch97@gmail.com>
to me

----- Forwarded message -----

From: **Mediwheel** <wellness@mediwheel.in>

Date: Tue, Mar 21, 2023, 1:26 PM

Subject: Health Check up Booking Confirmed Request(bobE34581),Package Code-F Beneficiary Code-31682

To: <vivekresearch97@gmail.com>

Cc: <customercare@mediwheel.in>



Mediwheel
...Your wellness partner

Dear **MR. PUROHIT VIVEKKUMAR DEEPAKBHAI**,
Please find the confirmation for following request.

- Booking Date** : 20-03-2023
- Package Name** : Medi-wheel Full Body Health Checkup
- Name of Diagnostic/Hospital** : Savita Superspeciality Hospital
- Address of Diagnostic/Hospital** : Parivar Char Rasta, Dabhoi - Ward No. 1, Kendranagar - 390019
- Contact Details** : 7574078561
- City** : Vadodara
- State** : Gujarat
- Pincode** : 390019
- Appointment Date** : 25-03-2023
- Confirmation** : - - -

LETTER OF APPROVAL / RECOMMENDATION

To,

The Coordinator,
Mediwheel (Arcofemi Healthcare Limited)
Helpline number: 011- 41195959

Dear Sir / Madam,

Sub: Annual Health Checkup for the employees of Bank of Baroda

This is to inform you that the following employee wishes to avail the facility of Cashless Annual Health Checkup provided by you in terms of our agreement.

PARTICULARS	EMPLOYEE DETAILS
NAME	MR. PUROHIT VIVEKKUMAR DEEPAKBHAI
EC NO.	122948
DESIGNATION	SINGLE WINDOW OPERATOR A
PLACE OF WORK	RAJUPURA
BIRTHDATE	01-09-1991
PROPOSED DATE OF HEALTH CHECKUP	25-03-2023
BOOKING REFERENCE NO.	22M122948100050798E

This letter of approval / recommendation is valid if submitted along with copy of the Bank of Baroda employee id card. This approval is valid from **20-03-2023** till **31-03-2023** The list of medical tests to be conducted is provided in the annexure to this letter. Please note that the said health checkup is a **cashless facility** as per our tie up arrangement. We request you to attend to the health checkup requirement of our employee and accord your top priority and best resources in this regard. The EC Number and the booking reference number as given in the above table shall be mentioned in the invoice, invariably.

We solicit your co-operation in this regard.

Yours faithfully,

Sd/-

Chief General Manager
HRM Department
Bank of Baroda

(Note: This is a computer generated letter. No Signature required. For any clarification, please contact Mediwheel (Arcofemi Healthcare Limited))

SUGGESTIVE LIST OF MEDICAL TESTS

FOR MALE	FOR FEMALE
CBC	CBC
ESR	ESR
Blood Group & RH Factor	Blood Group & RH Factor
Blood and Urine Sugar Fasting	Blood and Urine Sugar Fasting
Blood and Urine Sugar PP	Blood and Urine Sugar PP
Stool Routine	Stool Routine
Lipid Profile	Lipid Profile
Total Cholesterol	Total Cholesterol
HDL	HDL
LDL	LDL
VLDL	VLDL
Triglycerides	Triglycerides
HDL / LDL ratio	HDL / LDL ratio
Liver Profile	Liver Profile
AST	AST
ALT	ALT
GGT	GGT
Bilirubin (total, direct, indirect)	Bilirubin (total, direct, indirect)
ALP	ALP
Proteins (T, Albumin, Globulin)	Proteins (T, Albumin, Globulin)
Kidney Profile	Kidney Profile
Serum creatinine	Serum creatinine
Blood Urea Nitrogen	Blood Urea Nitrogen
Uric Acid	Uric Acid
HBA1C	HBA1C
Routine urine analysis	Routine urine analysis
USG Whole Abdomen	USG Whole Abdomen
General Tests	General Tests
X Ray Chest	X Ray Chest
ECG	ECG
2D/3D ECHO / TMT	2D/3D ECHO / TMT
Stress Test	Thyroid Profile (T3, T4, TSH)
PSA Male (above 40 years)	Mammography (above 40 years) and Pap Smear (above 30 years).
Thyroid Profile (T3, T4, TSH)	Dental Check-up consultation
Dental Check-up consultation	Physician Consultation
Physician Consultation	Eye Check-up consultation
Eye Check-up consultation	Skin/ENT consultation
Skin/ENT consultation	Gynaec Consultation



Savita

Superspeciality Hospital

(A Unit of Solace Healthcare Pvt. Ltd.)

Parivar Char Rasta, Waghodia-Dabhoi Ring Road, Vadodara-390019

☎ 0265-2578844 / 2578849 ✉ mh@savitahospital.com 🌐 savitahospital.com

Bill of Supply (Interim Bill)



Patient ID : 20230309279
Age / Sex : 31y / M
Patient Name : VIVEK D PUROHIT
Dr. Name : DR SAURABH JAIN
Referred By : self
City/Village : Vadodara
Class : Contract
PAN Card : AAQCS5566G

Visit No. : OPD20230328059(OPD)
Bill No. : OPD20230328059
Bill Date : N/A
Speciality : Internal Medicine
Company Name : Mediwheel Health Check Up
GSTIN : 24AAQCS5566G2ZW
Mobile No. : 9898293762

Expense Details		Qty	Rate	Gross Amount	Waive	Net Amount
Visit Charge						
25/03/2023	Physician First Consultation OPD	1.0	0.0	0.00	0.0	0.00
	Ophthalmologist First Consultation OPD	1.0	0.0	0.00	0.0	0.00
Visit Charge (Subtotal)				0.0	0.0	0.00
PATHOLOGY						
25/03/2023	CBC, ESR	1.0			0.0	
	Urine R/M	1.0			0.0	
	STOOL EXAMINATION	1.0			0.0	
	Blood Group	1.0			0.0	
	TFT (Thyroid Function Test)	1.0			0.0	
	Lipid Profile	1.0			0.0	
	RENAL FUNCTION TEST	1.0			0.0	
	LFT (Liver Function Test)	1.0			0.0	
	FBS & PPBS	1.0			0.0	
	HBA1C	1.0	2000.0	2000.00	0.0	2000.00
	MediWheel Full Body Health Check-Up(Male Below 40)	1.0		2000.0	0.0	2000.00
PATHOLOGY (Subtotal)						
Radiology						
25/03/2023	X-RAY CHEST PA	1.0			0.0	
	USG WHOLE ABDOMEN SCREENING	1.0			0.0	
	X-RAY CHEST PA	1.0	0.0	0.00	0.0	0.00
	USG WHOLE ABDOMEN SCREENING	1.0	0.0	0.00	0.0	0.00
Radiology (Subtotal)					0.0	0.00
Non Invasive Cardiology						
25/03/2023	ECG Charge(OPD Base)	1.0	0.0	0.00	0.0	0.00
	ECHO COLOUR DOPPLER SCREENING	1.0	0.0	0.00	0.0	0.00
Non Invasive Cardiology (Subtotal)					0.0	0.00
				Total Bill Amount		2000.00
				Net payable amount		2000.00
				Bill Outstanding		2000.00

Received With Thanks From VIVEK D PUROHIT of Rs 0.0 /-
(Rs Zero Only)

Printed By : (Nikhil Rathod)
For : Savita Hospital-Live





Savita

Superspeciality Hospital
(A Unit of Solace Healthcare Pvt. Ltd.)

Parivar Char Rasta, Waghodia-Dabhoi Ring Road, Vadodara-390019

☎ 0265-2578844 / 2578849 ✉ mh@savitahospital.com 🌐 savitahospital.com

PHYSICIAN EXAMINATION

Name :	VIVEK D PUROHIT	Age :	31/MALE
Reg.No :	20230309279	DOE :	25/03/2023

Physical Examination:

Height:	166CM	Weight:	62 KG	PULSE:	80	Temperature:	NORMAL
----------------	--------------	----------------	------------------	---------------	-----------	---------------------	---------------

BMI :	22.4	BP :	124/80	SPO2	99%
--------------	-------------	-------------	---------------	-------------	------------

Chief Complaint :	NO COMPLAINTS
Past History :	NO SIGNIFICANT
General Examination :	NAD
Systemic Examination :	NAD
INVESTIGATION :	NAD
ADVICE :	TAB: NAXDOM (500), TAB SOS.



DR. SAURABH JAIN



Examination By Ophthalmologist

Name :	VIVEK D PUROHIT	Age :	31/MALE
Reg.No :	20230309279	DOE :	25/03/2023


Present Complaints :	NO FRESH COMPLAINT
Medical History :	NAD
Examination Of Eye :	NAD

External Examination :	NAD	NAD
Ati Seg Examination :	WNL	WNL
Schiotz Tonometry IOP :	RRRL	RRRL
Fundus :	NILL	
Without Glass	Distant Vision :	
	Near Vision :	
With Glass	Distant Vision : 6/6WITH -4.50DSPH	6/6WITH -5.0DSPH
	Near Vision :N6	N6
Colour Vision (With Ishihara Chart) :	WNL	
Advice :	NIL	




DR CHETAN CHAUHAN



Patient Name :	Vivek D Purohit	Sample No. :	20230316719 
Patient ID :	20230309279	Visit No. :	OPD20230328059
Age / Sex :	31y/Male	Call. Date :	25/03/2023 08:58
Consultant :	DR SAURABH JAIN	S. Coll. Date :	25/03/2023 09:35
Ward :	-	Report Date :	25/03/2023 12:31


CBC, ESR

Investigation	Result	Normal Value
Hemoglobin :	13.1 gm/dl [L]	13.5 to 18.0 gm/dl
P.C.V. :	40.1 % [L]	42.0 to 52.0 %
M.C.V. :	84.2 fL	78 to 100 fL
M.C.H. :	27.5 pg	27 to 31 pg
M.C.H.C. :	32.7 g/dl	32 to 36 g/dl
RDW :	13 %	11.5 to 14.0 %
RBC Count :	4.76 X 10 ⁶ /cumm	4.7 to 6.0 X 10 ⁶ /cumm
Polymorphs :	75 % [H]	38 to 70 %
Lymphocytes :	21 %	15 to 48 %
Eosinophils :	2 %	0 to 6 %
Monocytes :	2 % [L]	3 to 11 %
Basophils :	0 %	0.0 to 1.0 %
Total :	100	< 100 > 100
WBC Count :	6700 /cmm	4000 to 10000 /cmm
Platelets Count :	236000 /cmm	1,50,000 to 4,50,000 /cmm
ESR - After One Hour :	14 mm/hr [H]	1 to 13 mm/hr



Dr. Mehul Desai
M.B.D.C.P
Reg.No.G-9521



Patient Name :	Vivek D Purohit	Sample No. :	20230316719 
Patient ID :	20230309279	Visit No. :	OPD20230328059
Age / Sex :	31y/Male	Call. Date :	25/03/2023 08:58
Consultant :	DR SAURABH JAIN	S. Coll. Date :	25/03/2023 09:35
Ward :	-	Report Date :	25/03/2023 15:49

FBS & PPBS

Investigation	Result	Normal Value
Blood Sugar (FBS) :	107 mg/dl [H]	74 - 100 mg/dl
Urine Sugar (FUS) :	Nil	
Blood Sugar (PP2BS) :	96 mg/dl	70 to 120 mg/dl
Urine Sugar (PP2US) :	Nil	


HBA1C

Investigation	Result	Normal Value
Glycosylated Hb :	5.7 %	Near Normal Glycemia : 6 to 7 Excellent Control : 7 to 8 Good Control : 8 to 9 Fair Control : 9 to 10 Poor Control : > 10
Average Plasma Glucose of Last 3 Months :	116.89	




Dr. Mehul Desai
M.B.D.C.P
Reg.No.G-9521



Patient Name :	Vivek D Purohit	Sample No. :	20230316719 
Patient ID :	20230309279	Visit No. :	OPD20230328059
Age / Sex :	31y/Male	Call. Date :	25/03/2023 08:58
Consultant :	DR SAURABH JAIN	S. Coll. Date :	25/03/2023 09:35
Ward :	-	Report Date :	25/03/2023 12:31

Blood Group

Investigation	Result	Normal Value
BLOOD GROUP :		
ABO	A	
Rh	Positive	



Dr. Mehul Desai
M.B.D.C.P
Reg.No.G-9521



Patient Name : Vivek D Purohit

Sample No. : 20230316719



Patient ID : 20230309279

Visit No. : OPD20230328059

Age / Sex : 31y/Male

Call. Date : 25/03/2023 08:58

Consultant : DR SAURABH JAIN

S. Coll. Date : 25/03/2023 09:35

Ward : -

Report Date : 25/03/2023 12:31

RENAL FUNCTION TEST

Investigation	Result	Normal Value
Creatinine :	0.9 mg/dl	0.6 - 1.4 mg/dl
Urea :	22 mg/ dl	13 - 45 mg/dl
Uric Acid :	5.8 mg/dl	3.5 - 7.2 mg/dl
Calcium :	9 mg/dl	8.5 - 10.5
Phosphorus :	4.2 mg/dl	1.5 - 6.8

Dr. Mehul Desai
M.B.D.C.P
Reg.No.G-9521



Patient Name : Vivek D Purohit

Sample No. : 20230316719



Patient ID : 20230309279

Visit No. : OPD20230328059

Age / Sex : 31y/Male

Call. Date : 25/03/2023 08:58

Consultant : DR SAURABH JAIN

S. Coll. Date : 25/03/2023 09:35

Ward : -

Report Date : 25/03/2023 12:31

Lipid Profile

Investigation	Result	Normal Value
Sample :	Fasting	
Sample Type :	Normal	
Cholesterol (Chol) :	174 mg/dl	Low risk : < 200 Moderate risk : 200 - 239 High risk : > or = 240
Triglyceride :	90 mg/dl	Normal : < 200.0 High : 200 - 499 Very High : > or = 500
HDL Cholesterol :	31 mg/dl [L]	Low risk: >or = 60 mg/dL High risk : Up to 35 mg/dL
LDL :	125 mg/dl [L]	131.0 to 159.0(N) < 130.0(L) > 159.0(H)
VLDL :	18 mg/dl	Up to 0 to 34 mg/dl
LDL/HDL Ratio :	4.03	Low risk : 0.5 to 3.0 Moderate risk : 3.0 to 6.0 Elevted level high > 6.0
Total Chol / HDL Ratio :	5.61	Low Risk : 3.3 to 4.4 Average Risk : 4.4 to 7.1 Moderate Risk : 7.1 to 11.0 High Risk : > 11.0
Total Lipids :	595 mg/dl	400 to 700 mg/dl

Note :- Lipemic samples give high triglyceride value and falsely low LDL value.

Dr. Mehul Desai
M.B.D.C.P
Reg.No.G-9521



Patient Name : Vivek D Purohit

Sample No. : 20230316719



Patient ID : 20230309279

Visit No. : OPD20230328059

Age / Sex : 31y/Male

Call. Date : 25/03/2023 08:58

Consultant : DR SAURABH JAIN

S. Coll. Date : 25/03/2023 09:35

Ward : -

Report Date : 25/03/2023 12:31

LFT (Liver Function Test)

Investigation	Result	Normal Value
Total Bilirubin :	0.2 mg/dl	0.2 to 1.0 mg/dl
Direct Bilirubin :	0.1 mg/dl	0.0 to 0.2 mg/dl
Indirect Bilirubin :	0.1 mg/dl	0.0 to 0.8 mg/dl
AST (SGOT) :	14 U/L	5 to 34 U/L
ALT (SGPT) :	19 U/L	0 to 55 U/L
Total Protein (TP) :	7 g/dL	6.4 to 8.3, g/dl
Albumin (ALB) :	4.2 g/dl	3.5 to 5.2 g/dl
Globulin :	2.8 g/dl	2.3 to 3.5 g/dl
A/G Ratio :	1.5	
Alkaline Phosphatase (ALP) :	104 U/L	40 to 150 U/L
GAMMA GT. :	22 U/L	7 to 35 U/L

Dr. Mehul Desai
M.B.D.C.P
Reg.No.G-9521



Unipath Specialty Laboratory (Baroda) LLP- Platinum Complex, Opp. HDFC Bank, Nr. Radha Krishna char rasta, Akota, Vadodara - 390020
Mobile: 9998724579 / 8155028222 | Email: info.baroda@unipathllp.in



TEST REPORT

Reg. No. : 30301014551	Reg. Date : 25-Mar-2023 12:41	Collected On : 25-Mar-2023 12:41
Name : Mr. VIVEK PUROHIT		Approved On : 25-Mar-2023 14:06
Age : 31 Years	Gender : Male	Dispatch At :
Ref. By :	Ref. No. :	Tele No. :
Location : SAVITA SUPERSPECIALTY HOSPITAL @ WAGHODIYA ROAD		

Test Name	Results	Units	Bio. Ref. Interval
THYROID FUNCTION TEST			
T3 (triiodothyronine) <i>Method:CLIA</i>	1.28	ng/mL	0.6 - 1.81
T4 (Thyroxine) <i>Method:CLIA</i>	10.70	µg/dL	4.5 - 12.6
TSH (ultra sensitive) <i>Method:CLIA</i>	1.618	µIU/mL	0.55 - 4.78
Sample Type:Serum			

Comments:

Thyroid stimulating hormone (TSH) is synthesized and secreted by the anterior pituitary in response to a negative feedback mechanism involving concentrations of FT3 (free T3) and FT4 (free T4). Additionally, the hypothalamic tripeptide, thyrotropin-releasing hormone (TRH), directly stimulates TSH production. TSH stimulates thyroid cell production and hypertrophy, also stimulate the thyroid gland to synthesize and secrete T3 and T4. Quantification of TSH is significant to differentiate primary (thyroid) from secondary (pituitary) and tertiary (hypothalamus) hypothyroidism. In primary hypothyroidism, TSH levels are significantly elevated, while in secondary and tertiary hypothyroidism, TSH levels are low.

TSH levels During Pregnancy :

- First Trimester : 0.1 to 2.5 µIU/mL
- Second Trimester : 0.2 to 3.0 µIU/mL
- Third trimester : 0.3 to 3.0 µIU/mL

Reference : Carl A.Burtis,Edward R.Ashwood,David E.Bruns. Tietz Textbook of Clinical Chemistry and Molecular Diagnostics. 5th Edition. Philadelphia: WB Saunders,2012:2170

----- End Of Report -----

This is an electronically authenticated report.

Test done from collected sample.

Printed On: 25-Mar-2023 14:08

Dr. Vishal Jhaveri
M.B.B.S, D.C.P
Reg. G-13041

Page 1 of 1



Patient Name : Vivek D Purohit

Sample No. : 20230316719



Patient ID : 20230309279

Visit No. : OPD20230328059

Age / Sex : 31y/Male

Call. Date : 25/03/2023 08:58

Consultant : DR SAURABH JAIN

S. Coll. Date : 25/03/2023 09:35

Ward : -


Report Date : 25/03/2023 12:31

Urine R/M

Investigation	Result	Normal Value
Quantity - :	20 ml	
Colour - :	Pale Yellow	
Reaction (pH) :	5.0	4.6-8.0
Turbidity :	Clear	
Deposit :	Absent	Absent
Sp.Gravity :	1.030	1.005-1.010
Protein :	Absent	Absent
Glucose :	Absent	Absent
Bile Salts :	Absent	Absent
Bile pigments :	Absent	Absent
Ketones :	Absent	Absent
Urobilinogen :	Absent	
Blood :	Absent	Absent
Crystals :	Calcium oxalate	Absent
Pus Cells :	0-2 /hpf	0-5/hpf
Red Blood Cells :	0-1 /hpf	Absent
Epithelial Cells :	1-2 /hpf	


Dr.Mehul Desai
M.B.D.C.P
Reg.No.G-9521



Patient Name :	Vivek D Purohit	Sample No. :	20230316719 
Patient ID :	20230309279	Visit No. :	OPD20230328059
Age / Sex :	31y/Male	Call. Date :	25/03/2023 08:58
Consultant :	DR SAURABH JAIN	S. Coll. Date :	25/03/2023 09:35
Ward :	-	Report Date :	25/03/2023 12:31

STOOL EXAMINATION

Investigation	Result	Normal Value
Quantity :	5 GM	
Colour :	Yellow	
Consistency :	Semi Solid	
Mucus :	Present	
Blood :	Absent	
Pus :	Absent	
Occult Blood :	Negative	
Pus Cells :	Absent /hpf	
RBCs Cells :	Absent /hpf	
Epithelial Cells :	1-2 /hpf	
Vegetable Cells :	Present	
Reducing Sab. :	Negative	



Dr. Mehul Desai
M.B.D.C.P
Reg.No.G-9521

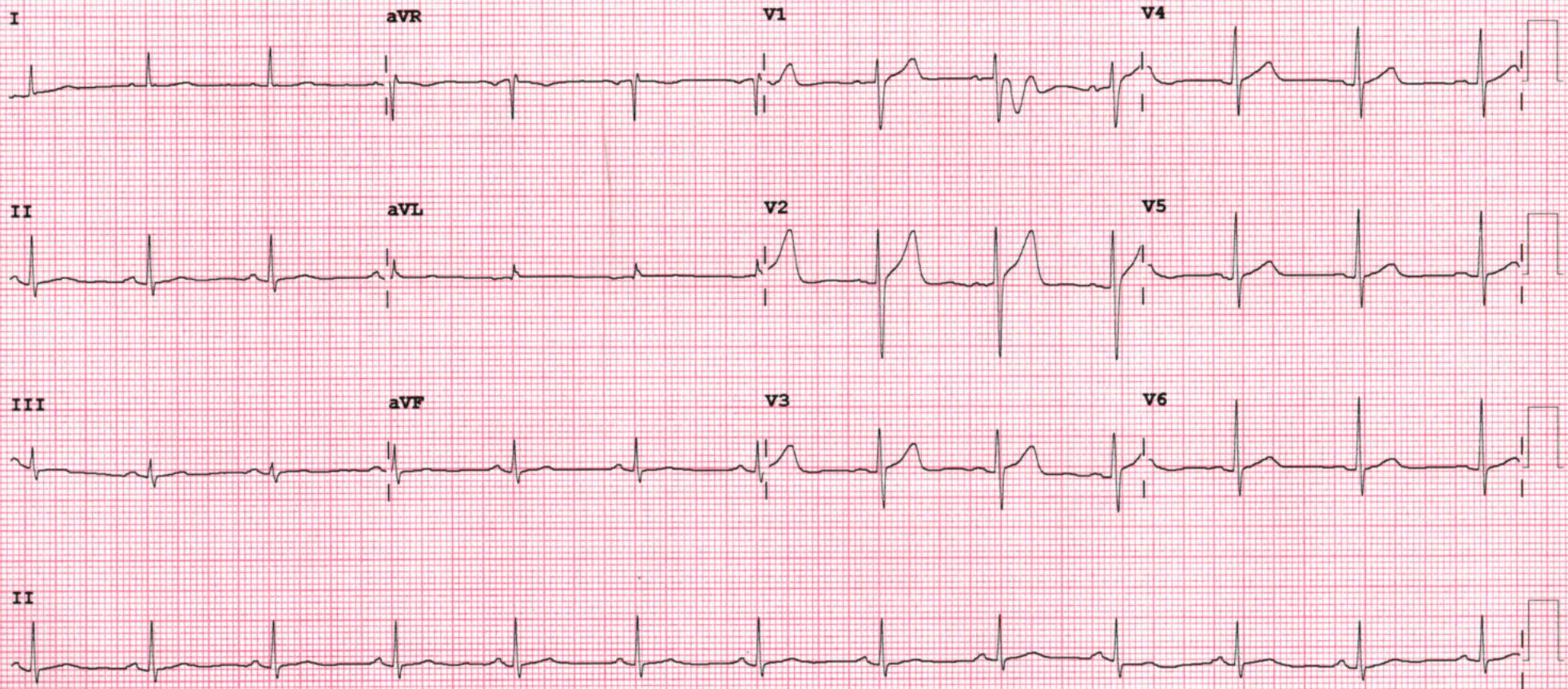
31 Years

Rate 75
PR 156
QRSD 70
QT 348
QTc 389

--AXIS--

P 71
QRS 26
T 27

12 Lead; Standard Placement



Device:

Speed: 25 mm/sec

Limb: 10 mm/mV

Chest: 10.0 mm/mV

F 50~ 0.50-150 Hz W

PH09

P?



2D-ECHOCARDIOGRAPHY AND COLOR DOPPLER REPORT

NAME: MR. VIVEK PUROHIT

AGE/SEX: 31YRS/MALE

DATE: 25/03/2023

OBSERVATION:

- NORMAL LV SIZE WITH NORMAL LV SYSTOLIC FUNCTION. LVEF = 58%.
- NO RWMA AT REST.
- NORMAL LV DIASTOLIC FUNCTION.
- NORMAL MITRAL VALVE; TRIVIAL MR. NO MS.
- NORMAL AORTIC VALVE; NO AR. NO AS.
- TRIVIAL TR. NO PAH.
- NORMAL SIZED LA, RA & RV WITH NORMAL RV SYSTOLIC FUNCTION.
- NORMAL SIZED MPA, RPA & LPA.
- INTACT IAS & IVS
- NO E/O INTRACARDIAC CLOT/VEGETATION/PE.
- NORMAL IVC.
- NORMAL PERICARDIUM.

LA: 33MM

AO: 27MM

IVS: 10/16MM

LVPW: 10/15MM

LVID: 46/25MM

CONCLUSION:

- NORMAL LV/RV SIZE AND GOOD LV SYSTOLIC FUNCTION.
- NO RWMA AT REST
- NORMAL LV DIASTOLIC FUNCTION
- TRIVIAL MR, TRIVIAL TR, NO PAH

DR.NIRAV BHALANI
[CARDIOLOGIST]

DR.ARVIND SHARMA
[CARDIOLOGIST]

DR. CHIRAG SHETH
[CARDIOLOGIST]

DR PRUTHVIRAJ PWAR
[CARDIOLOGIST]





Patient name	VIVEK PUROHIT
Age / Sex	31Y/M
Date	Saturday, 25 March 2023

ULTRASOUND OF ABDOMEN

LIVER appears normal in size (11.4 cm) and shows normal parenchymal echogenicity. No evidence of focal lesion. No evidence of dilated IHBR or portal vein. CBD appears normal.

GALL BLADDER is distended. No e/o wall thickening or calculus within.

VISUALIZED PART OF PANCREAS appears normal. MPD is WNL

SPLEEN appears normal in size (7.8 cm) and shows normal parenchymal echogenicity. No evidence of focal lesion.

BOTH KIDNEYS appear normal in size (RK: 8.9 cm & LK: 9.8 cm) and position. Show normal cortical echogenicity. Corticomedullary differentiation is maintained. No calculus or hydronephrosis on either side.

URINARY BLADDER is full. No e/o wall thickening or calculus within.

PROSTATE appears normal in size. No evidence of focal lesion noted.

BOWEL LOOPS appear normal and show normal peristalsis
No evidence of LYMPHADENOPATHY noted.
No evidence of ASCITES or PLEURAL EFFUSION noted.

IMPRESSION:

- NO SIGNIFICANT ABNORMALITY NOTED IN PRESENT SCAN.



DR SHARAD RUNGTA
MD RADIOLOGY

Not all pathologies can be detected on radiograph. Further radiographic evaluation is suggested if required.



NAME: VIVEK PUROHIT	AGE/SEX: 31 YRS/M
DATE: Saturday, March 25, 2023	

CHEST XRAY (PA)

Both lung fields appear normal.

Both hila appear normal

Bilateral costo-phrenic angles appear grossly clear

Mediastinum and cardiac shadow appear normal

Bony thorax appears unremarkable

No evidence of free gas under domes of diaphragm

IMPRESSION:

- NO SIGNIFICANT ABNORMALITY NOTED IN LUNG FIELDS
- NORMAL CARDIAC SHADOW



DR SHARAD RUNGTA
MD RADIOLOGY

Not all pathologies can be detected on radiograph. Further radiographic evaluation is suggested if required.