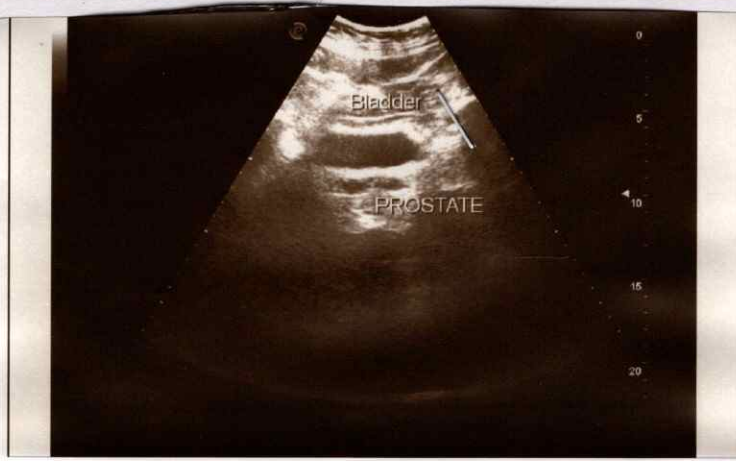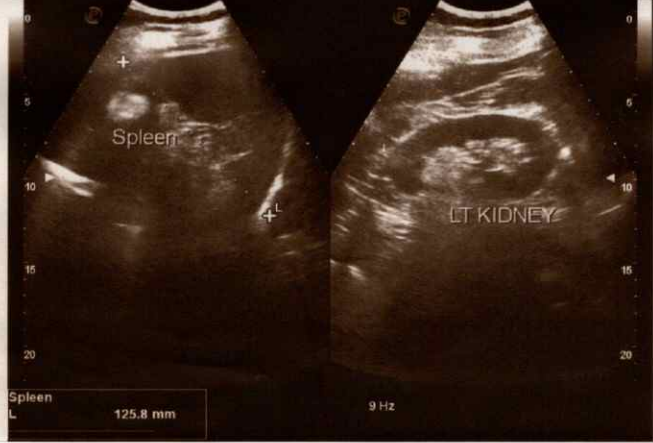




ASHMEE CARE ULTRASOUND & PATHOLOGY CENTRE KANPUR  
 MRS ANIL KUMAR 31/MALE 19/Oct/2021 12:22:48

01 08s L G 50% P 100% MI 1.1  
 IT1 D 225 mm XM C1/ FNC 8/0/36 FMS 6

Abdominal  
 AC2541 General



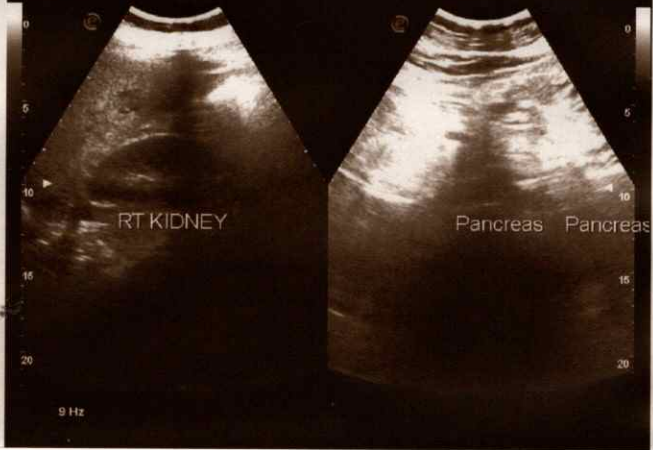
Spleen  
 L 125.8 mm

9 Hz

ASHMEE CARE ULTRASOUND & PATHOLOGY CENTRE KANPUR  
 MRS ANIL KUMAR 31/MALE 19/Oct/2021 12:22:14

01 08s L G 50% P 100% MI 1.1  
 IT1 D 225 mm XM C1/ FNC 8/0/36 FMS 6

Abdominal  
 AC2541 General

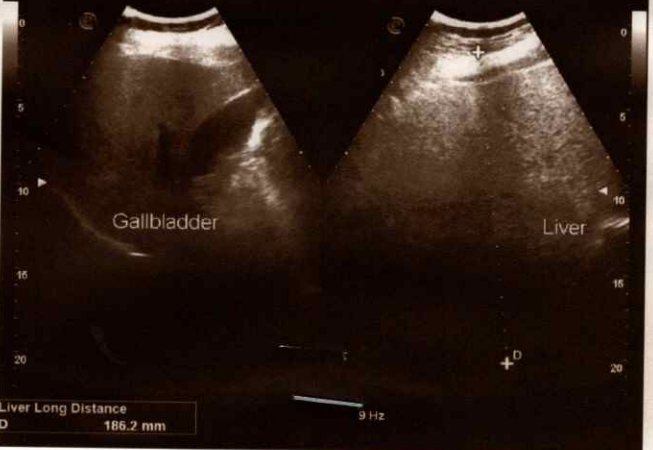


9 Hz

ASHMEE CARE ULTRASOUND & PATHOLOGY CENTRE KANPUR  
 MRS ANIL KUMAR 31/MALE 19/Oct/2021 12:21:47

01 08s L G 50% P 100% MI 1.1  
 IT1 D 225 mm XM C1/ FNC 8/0/36 FMS 6

Abdominal  
 AC2541 General



Liver Long Distance  
 D 186.2 mm

9 Hz