

भारत सरकार
GOVERNMENT OF INDIA



तपस्या विपीन कुमार भट्ट
Tapasya Vipin Kumar Bhatt
जन्म वर्ष / Year of Birth : 1978
स्त्री / Female



4248 8357 9768

आधार -- सामान्य माणसाचा अधिकार

2
Ⓟ Bhatt

45/F

D.O.B 20/12/78

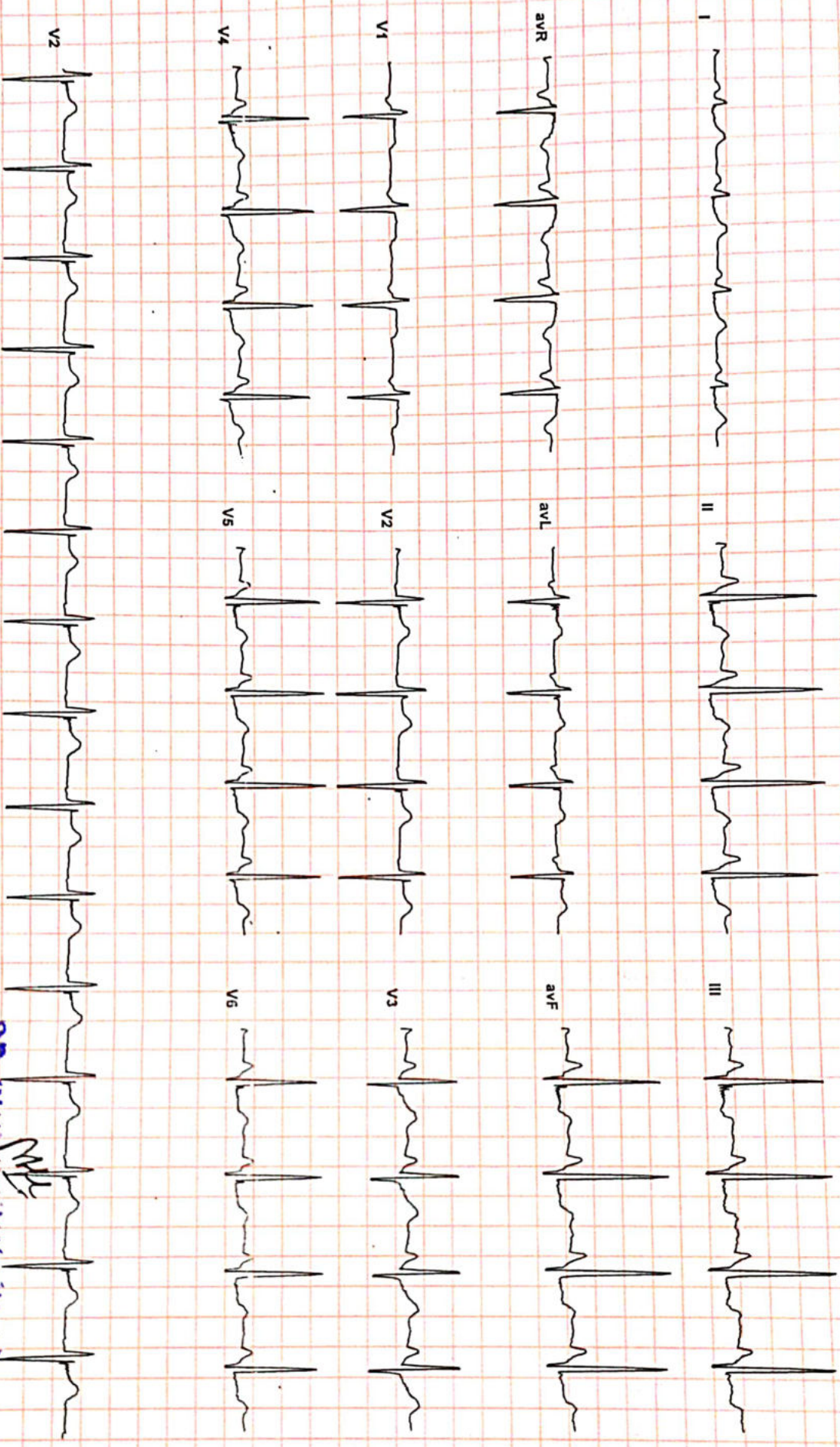
DR. HARI CHHABLANI
M.B.B.S.F.C.C.P.(RESP MEDICINE) PGDMM, FGDMLS
FELLOW INTENSIVE CARE
MMC REG. NO. - 91702

'DR. PLUS HEALTHCARE CENTRE'
NATHANI HEIGHTS', B-WING,
42, MUMBAI CENTRAL (EAST)

DR PLUS HEALTHCARE CENTRE- MUMBAI CENTRAL

ECG

2248 / TAPASYA BHATT / 45 Yrs / F
Heart Rate : 91 bpm / Tested On : 08-Oct-22 09:40:54 / HF 0.05 Hz - LF 100 Hz / Notch 50 Hz / Sn 1.00 Cm/mV / Sw 25 mm/s
/ Refd By: DR.HARI CHHABLANI



DR PURVI CHHABLANI

MBBS, DNB, Medicine.

Repealed: DR.HARI CHHABLANI

REG NO. 7769F

WPL



Dr-Plus Healthcare Centre

NATHANI HEIGHTS, B-Wing, Shop No. 51, Ground Floor, Opp. Mumbai Central Station (East), Mumbai - 400 008.

Patient's Name : TAPASYA BHATT

Report Date : 08/10/2022

Referred By : SELF

Age : 45 Years

Sex : FEMALE

X- RAY CHEST

BOTH THE LUNG FIELED ARE CLEAR.

THE HILAR SHADOWS APPEAR NORMAL.

THE COSTO-PHRENIC ANGELS ARE CLEAR.

THE CARDIAC SHADOWS APPEAR NORMAL.

THE TRACHEAL IS CENTRAL IN POSITION.

THE BONY CAGE APPEARS NORMAL.

IMPRESSION : THE ABOVE EXAMINATION IS WITHIN NORMAL LIMITS.

DR. A. J. MAZUMDAR

MD. DMRE, MDRD

DR. PLUS HEALTHCARE CENTRE
NATHANI HEIGHTS', B-WING.
42, MUMBAI CENTRAL (EAST)

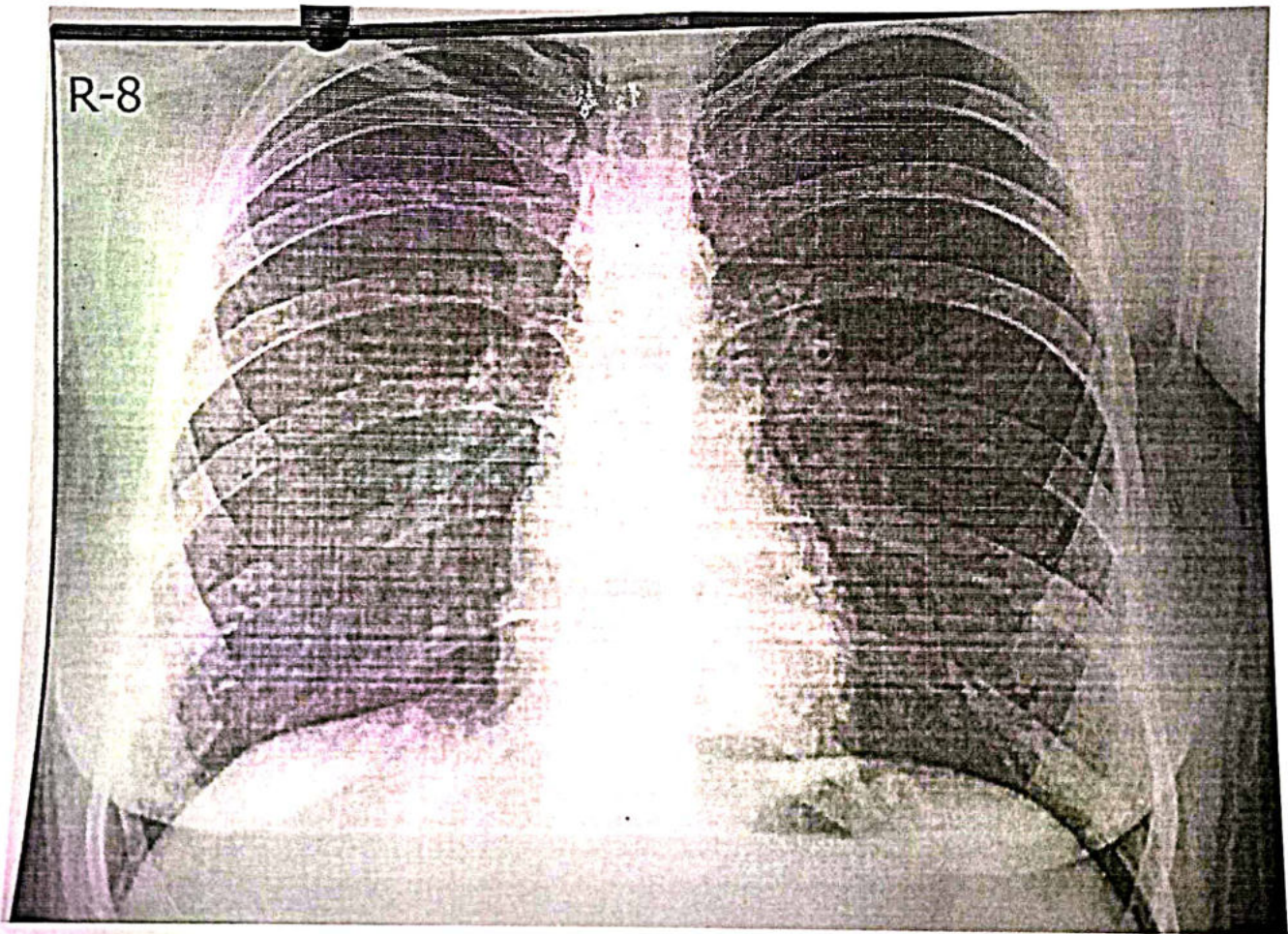
Patient's Name : TAPASYA BHATT

Report Date : 08/10/2022

Referred By : SELF

Age : 45 Years

Sex : FEMALE



DR. PLUS HEALTHCARE CENTRE
NATHANI HEIGHTS', B-WING,
42, MUMBAI CENTRAL (EAST)



Dr-Plus Healthcare Centre

NATHANI HEIGHTS, B-Wing, Shop No. 51, Ground Floor, Opp. Mumbai Central Station (East), Mumbai - 400 008.

Patient Name	:	TAPASYA BHATT	Sex:	FEMALE
Doctor's Name	:	DR. HARI CHHABLANI	Age:	45
Date	:	08/10/2022		

ULTRASONOGRAPHY OF THE ABDOMEN AND THE PELVIS:

The relevant sonographic findings include the following:

HEPATOBIILIARY APPARATUS

The liver is normal in size and echogenicity. No obvious focal parenchymal lesion is seen. Intrahepatic biliary radicals are not dilated.

The portal vein and the common bile duct are normal.

GALL BLADDER

The gall bladder is adequately distended. The wall thickness is normal.

No echogenic contents are noted in its lumen. There is no pericholecystic collection noted.

PANCREAS

The pancreas shows normal echogenicity and size.

No focal or diffuse lesions are noted. No evidence of calcification is noted.

SPLEEN

The spleen appears normal in size and echogenicity.

No focal or diffuse lesions are noted. No evidence of calcification is noted.

KIDNEYS

Right kidney measures 10.1 x 4.6 cm, Left kidney measures : 10.5 x 5.0 cm.

Both the kidneys appear normal in size, shape and echogenicity. Both the pelvicalyceal system is normal and both corticomedullary differentiations are well maintained. There is no obvious focal or diffuse lesion noted.

No evidence of any calculus seen in either kidney.

URINARY BLADDER

The urinary bladder shows anechoic contents. Its wall thickness appears normal.

UTERUS

Uterus measures = 5.8 x 2.6 x 3.3 cms.

The uterus is anteverted and normal in size. There are no focal or diffuse lesions noted.

The endometrium appears normal (6.2 mm).

OVARIES

Both the ovaries appear normal in size.

Right ovary measures : 5.6 x 3.4 Cm, Left ovary measures : 4.8 x 3.3 cm

There is no obvious evidence of abdominal or pelvic lymphadenopathy or ascites.
No other obvious pelvic mass is seen. No probe-tenderness is noted.

IMPRESSION: No significant abnormality is detected.

Dr. VICTOR X. COUTINHO
MBBS, DMRE
Radio-Sonologist

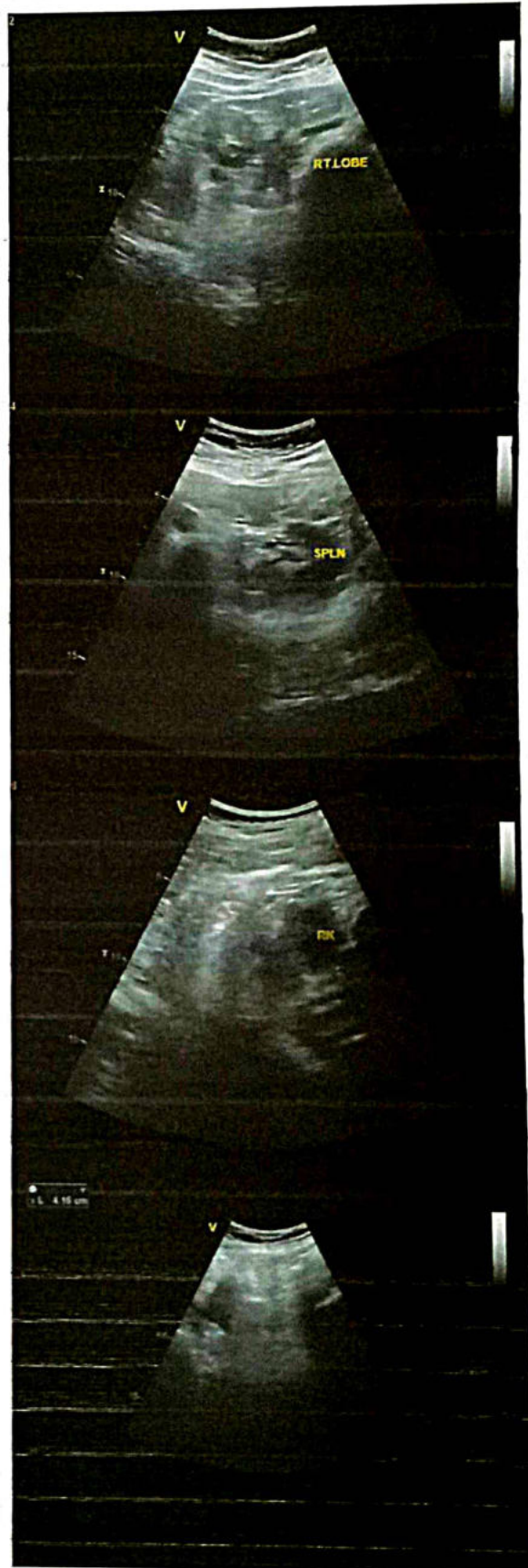
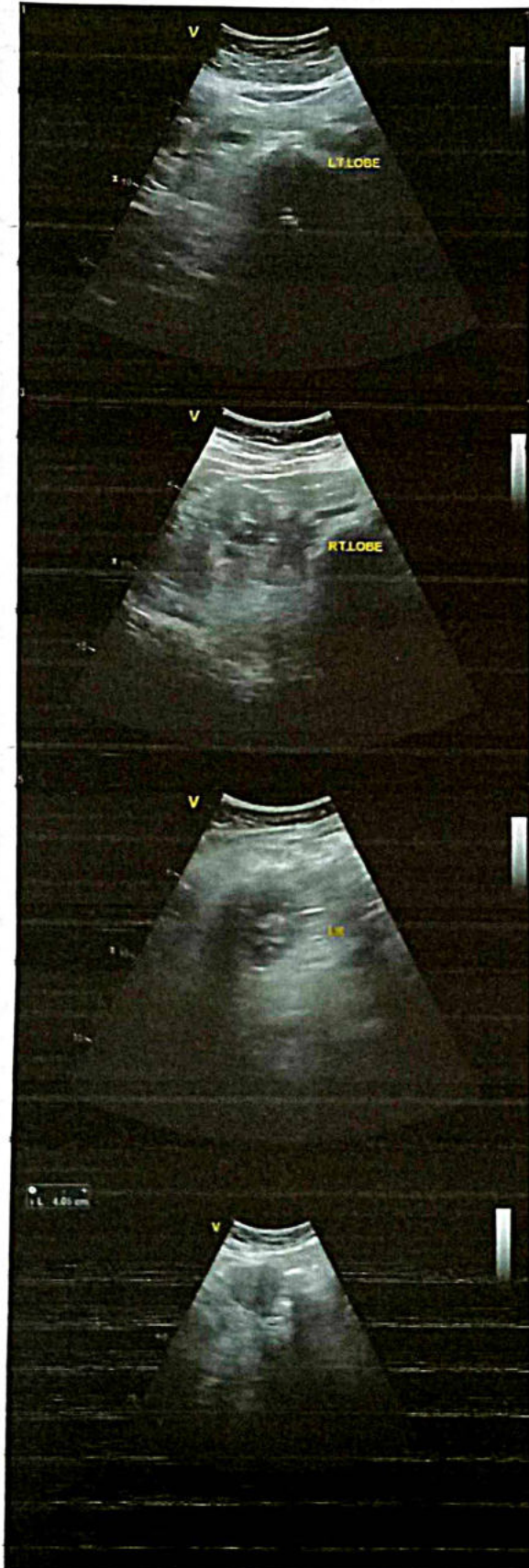
DR. PLUS HEALTHCARE CENTRE
NATHANI HEIGHTS, B-WING
42, MUMBAI CENTRAL (EAST)

Name TAPASYA BHATT

Sex Female

Age 45

Date 08/10/2022





NAME : TAPASYA BHATT

45/F


DATE:08/10/2022

REF BY : SELF

2D-ECHO. AND COLOR DOPPLER REPORT

- NORMAL CARDIAC VALVES WITH TRIVIAL TR.
- NORMAL CARDIAC CHAMBERS
- NO E/O REGIONAL WALL MOTION, ABNORMALITY. WITH NORMAL LVEF OF 60 %.
- NO E/O PULMONARY HYPERTENSION .PASP 30 mmHg by TR jet.
- E/O MILD LEFT VENTRICULAR HYPERTROPHY.
- NO E/O DIASTOLIC DYSFUNCTION.
- NO E/O PERICARDIAL EFFUSION.
- NO E/O INTRACARDIAC CLOT OR VEGETATION
- INTACT IAS / IVS
- **CONVENTIONL DOPPLER :**
 - E TO A RATIO IS MORE THAN ONE IN LV INFLOW.
 - THERE IS NO GRADIENT ACROSS AV,LVOT OR RVOT
 - PASP FROM TR JET IS 30 mm OF Hg.
- **COLOUR DOPPLER:**
 - TRIVIAL TR

EF Slope	107	85-120 mm/sec		
Opening Amplitude	20			
Posterior leaflet				
E.P.S.S	02	mm		
Mitral valve prolapse				
Vegetations				
TRICUSPID VALVE	OBSERVED	NORMAL VALUES		
PULMONARY VALVE	OBSERVED	NORMAL VALUES		
EF Slope				
'A' Wave				
Midsystolic notch				
Flutter				
Other Findings				
AORTIC VALVE	OBSERVE	NORMAL VALUES		
Cuspal opening	17	mm		
Closure line	Central			
Eccentricity index	1			
Other Findings				
DIMENSIONS	OBSERVED	NORMAL VALUES		
1. Lvd (Diastolic)	31	26-52		
2. Lvd (Systolic)	22	24-42mm		
3. RVD (Diastolic)	17	7-23mm		
4. IVST (Diastolic)	11	6-11mm		
5. IVST (Systolic)	15			
6. LVPWT (Diastolic)	11	6-11mm		
7. LVPWT (Systolic)	16			
8. Aortic root	15	22-37mm		
9. left Atrium	26	19-40mm		
	STRUCTURE	REGURG GRADING	VELOCITY m/sec	STENOSIS GRADIENT mm/Hg
			Max mean	Peak mean
MITRAL VALVE	NORMAL	0/3	/	/
TRICUSPID VELVE	NORMAL	TRIVIAL	/	/
PULMONARY VELVE	NORMAL	0/4	/	/
AORTIV VALVE	NORMAL	0/4	/	/


DR. P.H. CHHABLANI
 M.B.B.S, DNB.(MEDICINE)
 CONSULTANT PHYSICIAN AND CARDIOLOGIST.

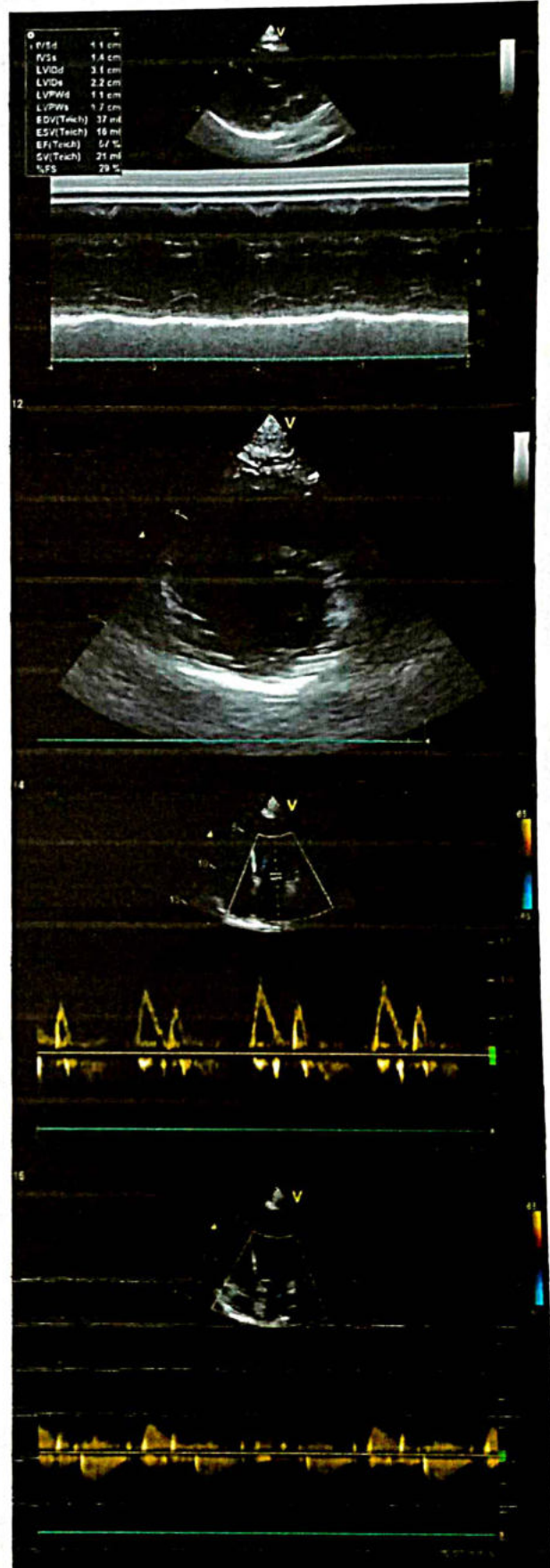
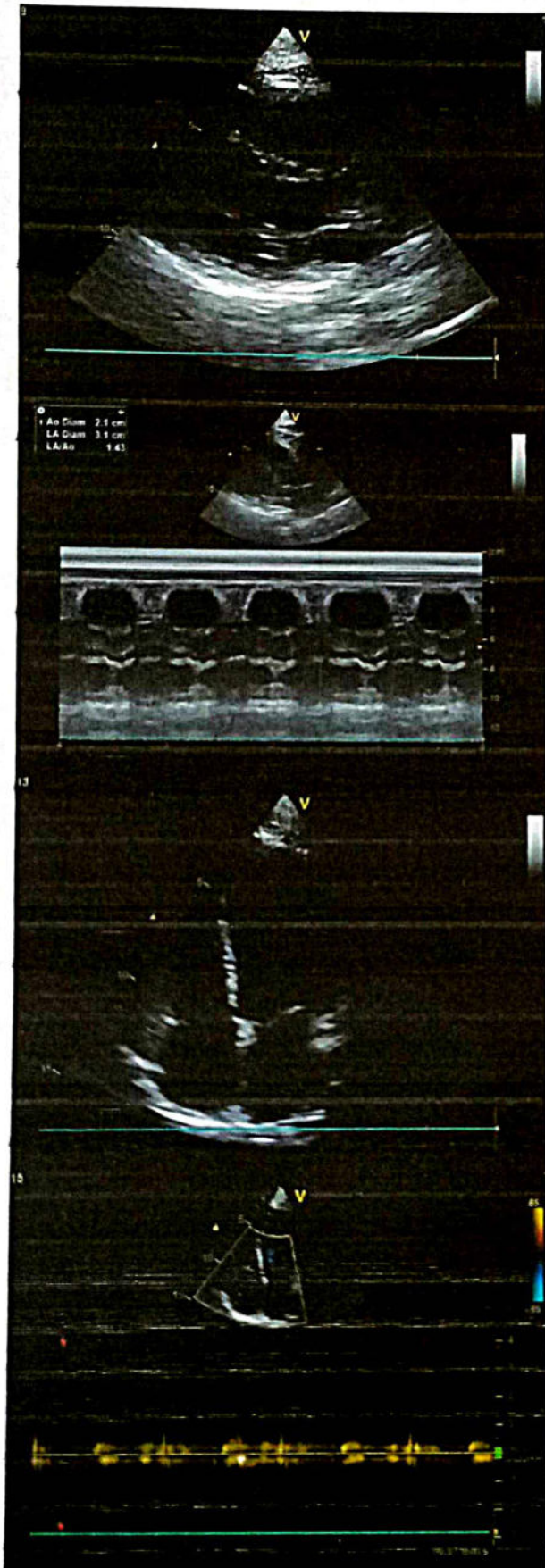
DR. PURVI CHHABLANI
 MBBS, DNB (Medicine,
 Consultant Physician And Intensive
 Reg No 77606

Name TAPASYA BHATT

Sex Female

Age 45

Date 08/10/2022





Dr. Hari Chhablani

Cardiometabolic Physician & Intensivist
M.B.B.S., F.C.C.P. (RESP. MED.), PGDHMM,
PGDMLS, FELLOW INTENSIVE CARE MED.

ATTACHED TO : Wockhardt Hospital • Saifee Hospital • Apollo Spectra Hospital

NATHANI HEIGHTS, B-Wing, Shop No. 42, Ground Floor, Opp. Mumbai Central Station (East),
Mumbai - 400 008. • Cell : 98206 46163 • E : drharichhablani@gmail.com

PHYSICIAN REPORT

NAME : TAPASYA BHATT

DATE: 08/10/2022

AGE: 45 SEX: F

PRESENTING COMPLAINS: K/C/O ULCERATIVE COLITIS SINCE 12 YEARS.

PAST HISTORY: OPERATED FOR ULCERATIVE COLITIS IN 2021 , HISTOPATH REPORT NOT AVAILABLE.

TREATMENT HISTORY : NIL .

FAMILY HISTORY: NOT SIGNIFICANT

ADDICTION: NA

P: 90 /MIN

BP: 122/80

RS: CLEAR

CVS: S1,S2 REGULAR

PA: SOFT

CNS: CLINICALLY NAD

DENTAL EXAMINATION :

ECG: WNL

CHEST X-RAY: WNL

SONOGRAPHY : WNL

LABS: ATTACHED

EYE EXAMINATION : NEAR VISION - B/E-N8, DISTANT VISION B/L - 6/6 COLOUR VISION - NORMAL

IMPRESSION :UNFIT ON CLINICAL MEDICAL EXAMINATION.

ADVICE: GET HISTOPATH REPORT OF LARGE BOWEL SURGERY.

DR. HARI CHHABLANI
DR. HARI CHHABLANI
M.B.B.S.;F.C.C.P.(RESP MEDICINE) PGDHMM, PGDMLS
FELLOW INTENSIVE CARE
MMC REG. NO. - 91702



Dr-Plus Healthcare Centre

NATHANI HEIGHTS, B-Wing, Shop No. 51, Ground Floor, Opp. Mumbai Central Station (East), Mumbai - 400 008.

Full Name

TAPASYA BHATT

45/F

08/10/2022

Life to be assured:

	Type of Test	Actual Reading	Normal Range
1	Fasting Blood Sugar	91.2	70-100 mg%
2	PPBS	117.3	110 TO 140 mg%
3	Total Cholesterol	171.2	120-200 mg%
4	VERY LOW DENSITY LEVEL(VLDL)	18.2	10-30 mg/dl
5	High Density Lipid (HDL)	52.7	40-60 mg%
6	Low Density Lipid (LDL)	100.3	Upto 150
7	S. Triglycerides	120.7	50-150 mg%
8	CHOL/HDL	3.2	Upto 5
9	HDL/LDL	0.5	
10	S. Creatinine	0.8	0.5-1.2 mg%
11	Blood Urea Nitrogen (BUN)	20.5	7-21 mg%
12	BUN/CREAT RATIO	25.6	
13	S. Proteins	6.9	6.0-7.9 mg%
14	(a) Albumin	3.8	3.5-5.5 mg%
15	(b) Globulin	3.1	2.0-3.5 mg%
16	A/G RATIO	1.2	
17	S. Bilirubin	1.1	0.3-1.3mg%
18	(a) Direct	0.7	0.0-0.8 mg%
19	(b) Indirect	0.4	0.0-0.5 mg%
20	SGOT (AST)	28.6	05-34 IU
21	SGPT (ALT)	31.4	05-40 IU
22	GGTP (GGT)	42.8	05-50 IU
23	SGOT/SGPT	0.9	
24	HBA1C	5.1	UPTO 6.5
25	S. Alkaline Phosphatase	95.7	30-115 IU
26	T3	120.4	80-180ng/dl
27	T4	6.2	4.6-12 ug/dl
28	TSH	3.1	0.4-4.0 mIU/L
29	SERUM URIC ACID	5.9	2.5-7.2mg/dl
30	URINE SUGAR PP	ABSENT	
31	URINE SUGAR FASTING	ABSENT	
32	BLOOD GROUP	"AB"NEGATIVE "	

DR. RAKESH PATKAR
M.D., D.N.B. (Pathology)
Reg. No. 2013/05/1660



GPS Map Camera

Mumbai, Maharashtra, India

Shop No 65, Nathani Heights, Marzban Parsi Colony, Dalal Estate, Mumbai Central, Mumbai, Maharashtra 400008, India

Lat 18.968791°

Long 72.819974°

08/10/22 09:11 AM GMT +05:30

