

**Facilities:**

All clinical Biomedical & Hematology Investigations  
including Bone Marrow Examination  
VPT, Podiascan & Complete Foot Care (First Time in Purvanchal)  
All Hormonal Investigation by Chemiluminescent Method  
Visceral Fat by (AB-140) Ambulatory BP Monitoring  
CGMS & Insulin Pump Available  
PFT, 2D-ECHO (Color Doppler), Holter, TMT, Cardiac-3 available  
VIA, VILI, Colposcopy available  
Special Endocrinological Investigation Protocols.

ISO 9001:2008 Certified  
Mobile: 9389994334, 9554572190, 9453837595



# Panacea Pathology

## Clinical Reference Lab

Persistence, Preparedness and Precision  
EQAS (CMC Vellore Attached) & IQAS System  
पूर्वाचल की सर्वोत्तम गुणवत्ता वाली पैथोलॉजी

PATIENT NAME : MEENA MEHTA

AGE/GENDER : 50 YRS/FEMALE

REFD BY DR. : ARCO FEMI HEALTHCARE LTD.

RECEIVED DATE : 28-11-2022 (09:45 AM)

SAMPLE : BLOOD & URINE

REPORT DATE : 28-11-2022 (18:15 PM)

## PATHOLOGY REPORT

### COMPLETE BLOOD COUNT (CBC)

TEST	LAB TEST VALUES	NORMAL RANGE
<b>HEMOGRAM</b>		
HEMOGLOBIN (FLOW CYTOMETRY)	11.2	13 – 16 gm/dl
TOTAL LEUCOCYTE COUNT (TLC)	5,000	4000 – 11000
RBC COUNT	4.55	3.5 – 5.5
PCV (HCT)	34.1	37 – 47
MCV	95.9	80 – 95
MCH	31.4	28 – 34
MCHC	32.8	30 – 36
PLATELET COUNT	1,80,000	1,50,000 – 4,00,000
E.S.R. (WINTROBE FIRST HOURS)	18.0	20 mm/1 <sup>st</sup> hr
<b>DIFFERENTIAL LEUCOCYTE</b>		
NEUTROPHILS	63	40 – 75%
LYMPHOCYTES	31	20 – 45%
EOSINOPHILS	04	1 – 6%
MONOCYTES	02	2 – 8%
BASOPHILS	00	< 2%

### RENAL & KIDNEY PROFILE, SERUM

TEST	LAB TEST VALUES	NORMAL RANGE
<b>RENAL FUNCTION TESTS</b>		
BLOOD UREA NITROGEN (BUN)	12.0	10 – 50 mg/dl
SERUM CREATININE	0.80	0.60 – 1.60 mg/dl
URIC ACID	3.96	3.60 – 7.70 mg/dl
ALKALINE PHOSPHATASE (ALP)	88.0	142 – 353 mg/dl
TOTAL PROTIENS	7.12	0 – 39 mg/dl
ALBUMIN	4.00	3.8 – 5.4 mg/dl
SERUM GLOBULIN	3.12	2.1 – 3.5 mg/dl
CALCIUM	9.6	8.80 – 10.20
PHOSPHORUS	3.94	2.50 – 5.00
SERUM SODIUM NA+	145.0	135.00 – 155.00 mEq/Ltr
SERUM POTASIUM K+	4.18	3.60 – 5.50 mEq/Ltr
ICALCIUM	1.25	1.10 – 1.35 mmol/L
SERUM CHLORIDE CL+	103.3	98.00 – 110.00 mEq/Ltr

PAGE 1

Lab Technician

**PANACEA HOSPITAL**

UNIT OF ARCO FEMI HEALTH CARE PVT. LTD.

M.D. Pathology 1500

B.36/44 B-4, KABIR NAGAR

DURGAKUND, VARANASI

Timing : 8.00 a.m. to 9.00 p.m. (Sunday 8.00 a.m. to 3.00 p.m.)

This Report is not valid for medico legal purpose

**Note:** These tests have technical limitations. Clinico-pathological interpretation is necessary. In case of any disparity test may be repeated immediately.

**Address :** 36/44 FK Kabir Nagar, Durgakund, Varanasi – 221005

**Email:** [dramishra@gmail.com](mailto:dramishra@gmail.com), [drpallaviojha@gmail.com](mailto:drpallaviojha@gmail.com) **Website:** [panaceahospital.org](http://panaceahospital.org)

**Facilities:**

All clinical Biomedical & Hematology Investigations including Bone Marrow Examination  
VPT, Podiascan & Complete Foot Care (First Time in Purvanchal)  
All Hormonal Investigation by Chemiluminescent Method  
Visceral Fat by (AB-140) Ambulatory BP Monitoring  
CGMS & Insulin Pump Available  
PFT, 2D-ECHO (Color Doppler), Holter, TMT, Cardiac-3 available  
VIA, VILI, Colposcopy available  
Special Endocrinological Investigation Protocols.

ISO 9001:2008 Certified  
Mobile: 9389994334, 9554572190, 9453837595



# Panacea Pathology

## Clinical Reference Lab

Persistence, Preparedness and Precision  
EQAS (CMC Vellore Attached) & IQAS System  
पूर्वांचल की सर्वोत्तम गुणवत्ता वाली पैथोलॉजी

PATIENT NAME : MEENA MEHTA

AGE/GENDER : 50 YRS/FEMALE

REFD BY DR. : ARCO FEMI HEALTHCARE LTD.

RECEIVED DATE : 28-11-2022 (09:45 AM)

SAMPLE : BLOOD & URINE

REPORT DATE : 28-11-2022 (18:15 PM)

### PATHOLOGY REPORT

#### LIPID PROFILE, SERUM

TEST	LAB TEST VALUES	NORMAL RANGE
<b>BLOOD CHEMISTRY</b>		
TOTAL CHOLESTEROL (SERUM)	168.0	Desirable:- < 200 mg/dl Borderline:- 200 – 239 mg/dl High:- > 240 mg/dl
TRIGLYCERIDES (SERUM)	155.0	35 – 170 mg/dl
HDL CHOLESTEROL (SERUM)	44.0	35.30 – 79.50 mg/dl
LDL CHOLESTEROL (SERUM)	93.0	< 130 mg/dl
VLDL	31.0	< 40 mg/dl
NON HDL	72.0	0.00 – 100.00 mg/dl
CHOLESTROL/HDL RATIO	3.81	< 3.0 Low Risk Ratio 3.0 – 5.0 Avg Risk > 5.0 High Risk
LDL/HDL RATIO	2.11	< 3 Ratio

#### BLOOD GROUP

TEST	LAB TEST VALUES
<b>BLOOD GROUP ABO &amp; RH FACTOR</b>	
BLOOD GROUP	"B"
RH FACTOR	POSITIVE

#### GLYCOSYLATED HEMOGLOBIN (HBA1C)

TEST	LAB TEST VALUES	NORMAL RANGE
HBA1C	5.6	Normal : <5.97 % Good Control : 5.97 – 6.81% Fair Control : 6.81 – 7.65% Poor Control : >7.65%

#### THYROID PROFILE (T3, T4, TSH)

TEST	LAB TEST VALUES	NORMAL RANGE
<b>THYROID FUNCTION TEST</b>		
T3	1.16	0.60 – 1.81 ng/ml
T4	8.12	4.50 – 10.90 ug/dl
TSH	2.71	0.39 – 6.10 uIU/mL

PAGE 2

Lab Technician

**PANACEA HOSPITAL**  
: UNIT OF AAROH HEALTH CARE PVT. LTD.  
REG. NO. AL-1500  
B.36/44 B-4 KABIR NAGAR  
DURGAKUND, VARANASI  
M.D. Pathology

Timing : 8.00 a.m. to 9.00 p.m. (Sunday 8.00 a.m. to 3.00 p.m.)

This Report is not valid for medico legal purpose

**Note:** These tests have technical limitations. Clinico-pathological interpretation is necessary. In case of any disparity test may be repeated immediately.

Address : 36/44 FK Kabir Nagar, Durgakund, Varanasi – 221005

Email: [dramishra@gmail.com](mailto:dramishra@gmail.com), [drpallaviojha@gmail.com](mailto:drpallaviojha@gmail.com) Website: [panaceahospital.org](http://panaceahospital.org)

**Facilities:**

All clinical Biomedical & Hematology Investigations including Bone Marrow Examination VPT, Podiascan & Complete Foot Care (First Time in Purvanchal) All Hormonal Investigation by Chemiluminescent Method Visceral Fat by (AB-140) Ambulatory BP Monitoring CGMS & Insulin Pump Available PFT, 2D-ECHO (Color Doppler), Holter, TMT, Cardiac-3 available VIA, VILI, Colposcopy available Special Endocrinological Investigation Protocols.

ISO 9001:2008 Certified  
Mobile: 9389994334, 9554572190, 9453837595



# Panacea Pathology

## Clinical Reference Lab

Persistence, Preparedness and Precision  
EQAS (CMC Vellore Attached) & IQAS System  
पूर्वांचल की सर्वोत्तम गुणवत्ता वाली पैथोलॉजी

PATIENT NAME : MEENA MEHTA

AGE/GENDER : 50 YRS/FEMALE

REFD BY DR. : ARCO FEMI HEALTHCARE LTD.

RECEIVED DATE : 28-11-2022 (09:45 AM)

SAMPLE : BLOOD & URINE

REPORT DATE : 28-11-2022 (18:15 PM)

## PATHOLOGY REPORT

### LIVER PROFILE TEST, SERUM

TEST	LAB TEST VALUES	NORMAL RANGE
<b>BIO CHEMISTRY</b>		
TOTAL BILIRUBIN	0.71	0.0 – 1.1 mg/dl
DIRECT BILIRUBIN	0.29	0.0 – 0.2 mg/dl
INDIRECT BILIRUBIN	0.42	< 0.90 mg/dl
SGOT (AST)	26.4	0 – 52 mg/dl
SGPT (ALT)	22.0	0 – 39 mg/dl
GGT (GYT)	32.0	< 55 U/L
AG RATIO	1.96	-

### URINE ROUTINE EXAMINATION

TEST	LAB TEST VALUES	NORMAL RANGE
<b>PHYSICAL EXAMINATION</b>		
QUANTITY	29	ML
COLOUR	STRAW	PALE YELLOW
APPEARANCE	CLEAR	CLEAR
SPECIFIC GRAVITY	1.005	1.01 – 1.03
PH	5.0	4.7 – 7.5
<b>CHEMICAL EXAMINATION</b>		
GLUCOSE	Not Detected	Not Detected
PROTEIN	NIL	Not Detected
<b>MICROSCOPIC EXAMINATION</b>		
PUS CELLS	1-2	0-5
RBC	Not Detected	Not Detected
EPITHELIAL CELLS	1-2	0-5
CASTS	Not Detected	Not Detected
CRYSTALS	Not Detected	Not Detected
BACTERIA	Not Detected	Not Detected

### FASTING/RANDOM BLOOD SUGER

TEST	LAB TEST VALUES	NORMAL RANGE
<b>FBS/RBS</b>		
FASTING BLOOD SUGER	82.5	110-125 mg/dl
RANDOM BLOOD SUGER	104.0	125-140 mg/dl

PAGE 3

----- End of Report -----

Lab Technician

**PANACEA HOSPITAL**  
UNIT OF AAROH HEALTH CARE PVT. LTD.  
REG. NO. AL-1500  
M.D. Pathology  
B.36/44, B-4, KABIR NAGAR  
DURGAKUND, VARANASI

Timing : 8.00 a.m. to 9.00 p.m. (Sunday 8.00 a.m. to 3.00 p.m.)

This Report is not valid for medico legal purpose

**Note:** These tests have technical limitations. Clinico-pathological interpretation is necessary. In case of any disparity test may be repeated immediately.

**Address :** 36/44 FK Kabir Nagar, Durgakund, Varanasi – 221005

**Email :** [dramishra@gmail.com](mailto:dramishra@gmail.com), [drpallaviojha@gmail.com](mailto:drpallaviojha@gmail.com) **Website:** [panaceahospital.org](http://panaceahospital.org)



# PANACEA HOSPITAL

B 36/44 F.K KABIR NAGAR, DURGAKUND  
TOLLFREE NO-18001233070.  
Whatsapp No - 8795832852  
www.piire.org



## OP Slip

Print Date : 28-Nov-2022 02:15PM



UHID No	:- UD-22230002713	OP No	:- OP-22230010282	OP Date	:- 28 Nov 2022 2:14PM
Patient Name	:- Mrs MEENA MEHTA	Age/Sex	:- 50 Y/Female	Mobile No	:- 9532921112
Husband	:- RAKESH MEHTA	Department	:- OBST. & GYNAECOLOGY		
Pay Type	:- Cash	Consultant	:- Dr Tusharika Rai (MBBS,MS)		
Token No	:- NOR. - 5	Paid/Bal	:- 0.00 /530.00		
Patient Type	:- Normal				
Address	:- VNS, varanasi				

BP :-  
height :-  
Weight (kg) :-  
BMI :-

Rx

40 → watery discharge P/V:  
on & off.

LMP-24/11/22.

Pit+L1 - ♂ NVD.

LS-25y.

itching P/V.  
No urinary complaints.  
NO H/O DM, HTN.

Pap smear taken.

adv

Tab flucon 150 x stal.  
P/V with pap smear report.

Printed By : Mr NITIN YADAV  
Created By : Mr NITIN YADAV



# PANACEA HOSPITAL

*A shelter for many hearts A Home for many lives*

(An ISO 9001:2008 Certified Organisation)

Lab Attached with CMC Vellore Under EQAS Scheme

Name	MR.MEENA MEHTA	Sex /Age	50Y/F	Date	28/11/2022
Ref. by	DR.PALLAVI MISHRA(MD)	BSA - m <sup>2</sup>		Echo window	fair

## Echo - Cardiography

MITRAL VALVE Doppler	AML - normal morphology MV Flow - E - 0.7 A-0.4 E/A=1.65	PML - normal morphology MVA - 3.0 cm <sup>2</sup> Mitral Regurgitation - <b>No</b>
TRICUSPID VALVE Doppler	Normal TV Flow -No	Tricuspid Regurgitation - <b>No</b>
PULMONARY VALVE Doppler	Normal PV Flow -No	Pulmonary Regurgitation - No
AORTIC VALVE Doppler	Trileaflet-No AV Flow - no	Aortic Regurgitation - <b>No</b>
MEASUREMENT	Aorta - 22.8 (20-38) mm IVS ed - 12.0 (6 -12) mm LVID ed - 22.8 (35 - 55) mm LVPW ed - 15.4 (6 -12) mm OA - 7 (> 5) mm	LA -22.3 (24-32) mm IVS es -14.8 (6 - 12) mm LVID es - 16.0 (24 - 40) mm LVPW es - 16.0 (6 -12) mm EPSS - 06 (< 9) mm

## CONCLUSION

*All cardiac chamber dimension are WNL  
No valvular abnormalities  
Good LV systolic function present Modified Simpson's method (4C, 2C) (LVEF-60%)  
No diastolic dysfunction present (E/A = 1.65) by tissue Doppler (E/e'=6.8)  
No RWMA  
No pericardial effusion  
Intact IAS / IV  
No PAH  
No intra cardiac mass /thrombus /vegetation*

## IMPRESSION

*Normal Echocardiogram*

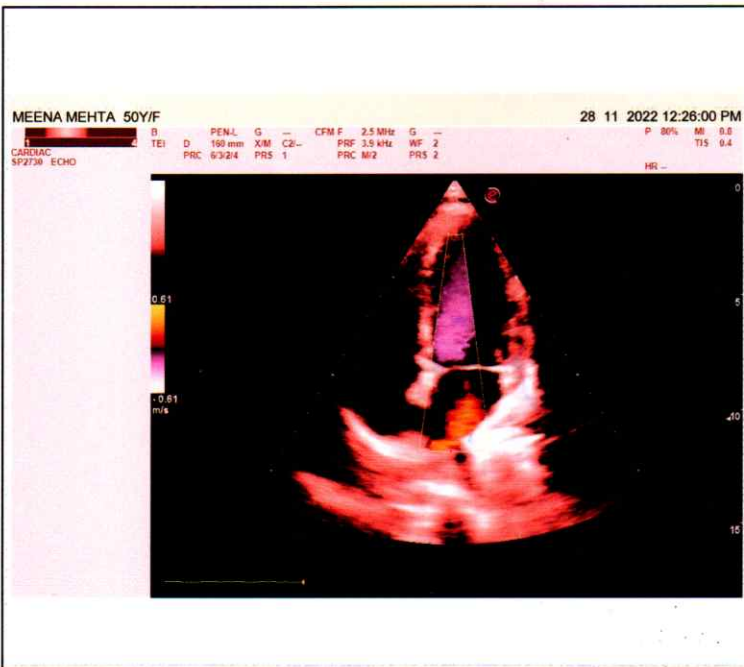
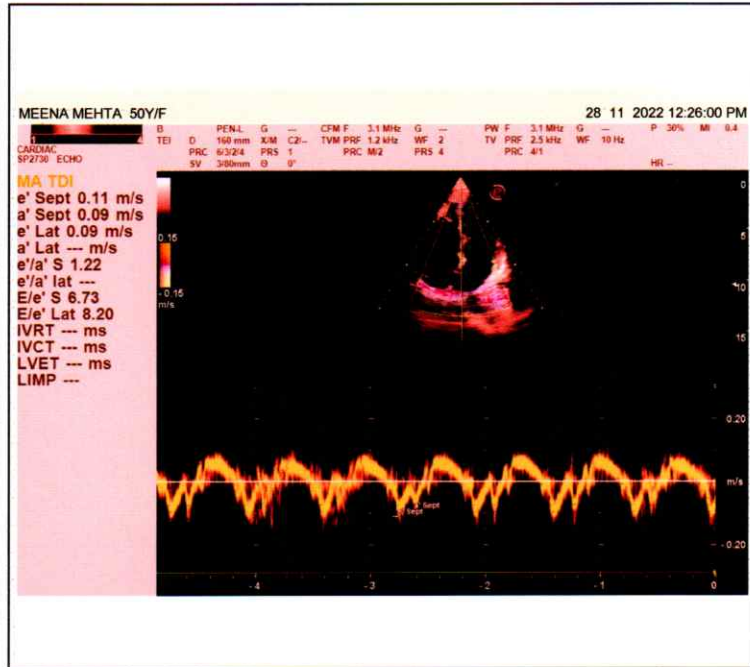
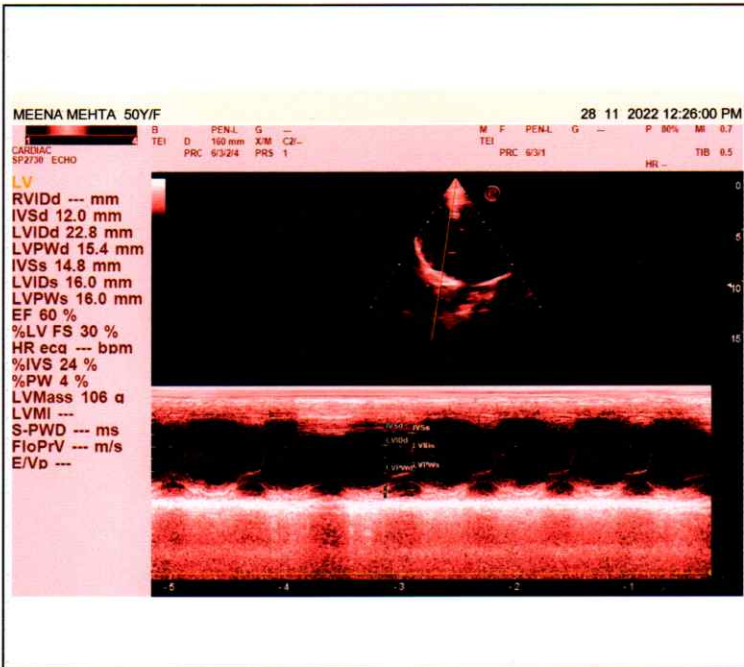
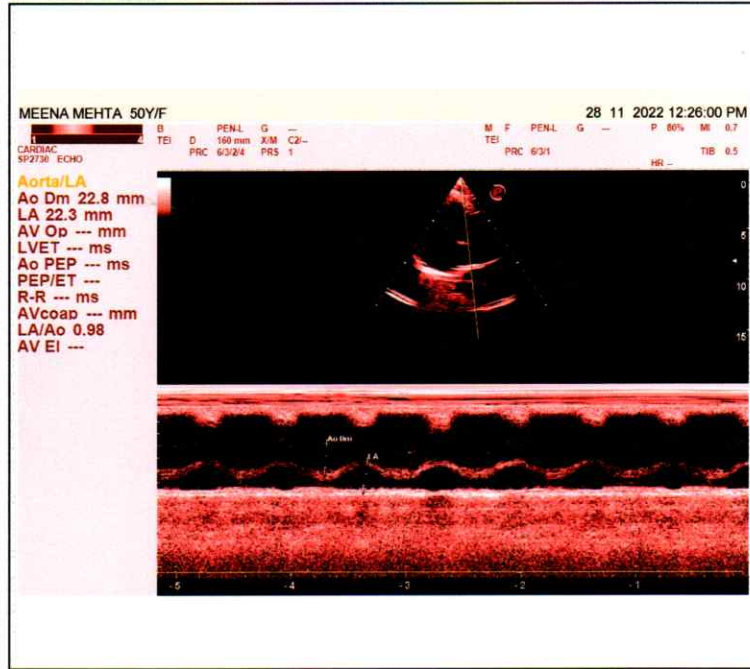
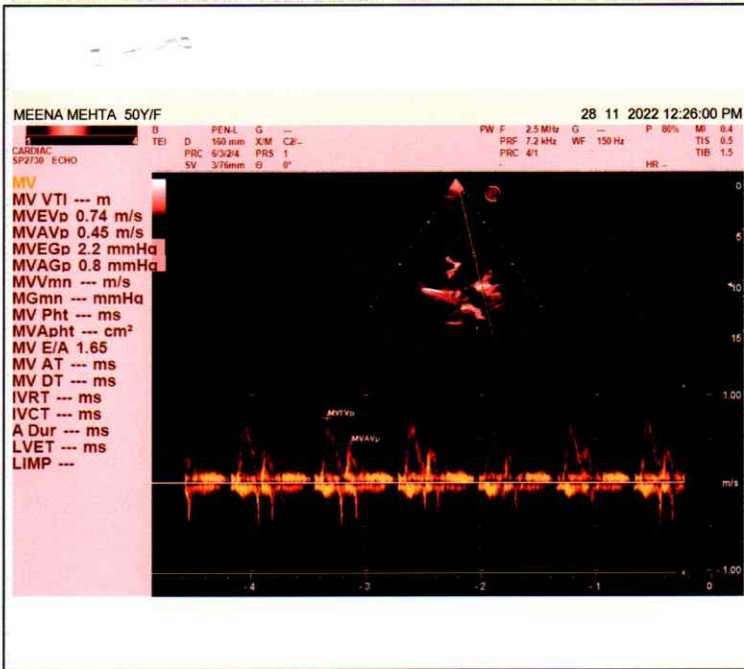
  
Dr. Pallavi Mishra  
Physician Assistant  
(PIIRE)

Dr. Pallavi Mishra  
MBBS, MD (MED) Lucknow  
Echocardiography Specialist, MIAE  
Non-invasive cardiologist  
Women Cardiologist  
Diabetocardiologist

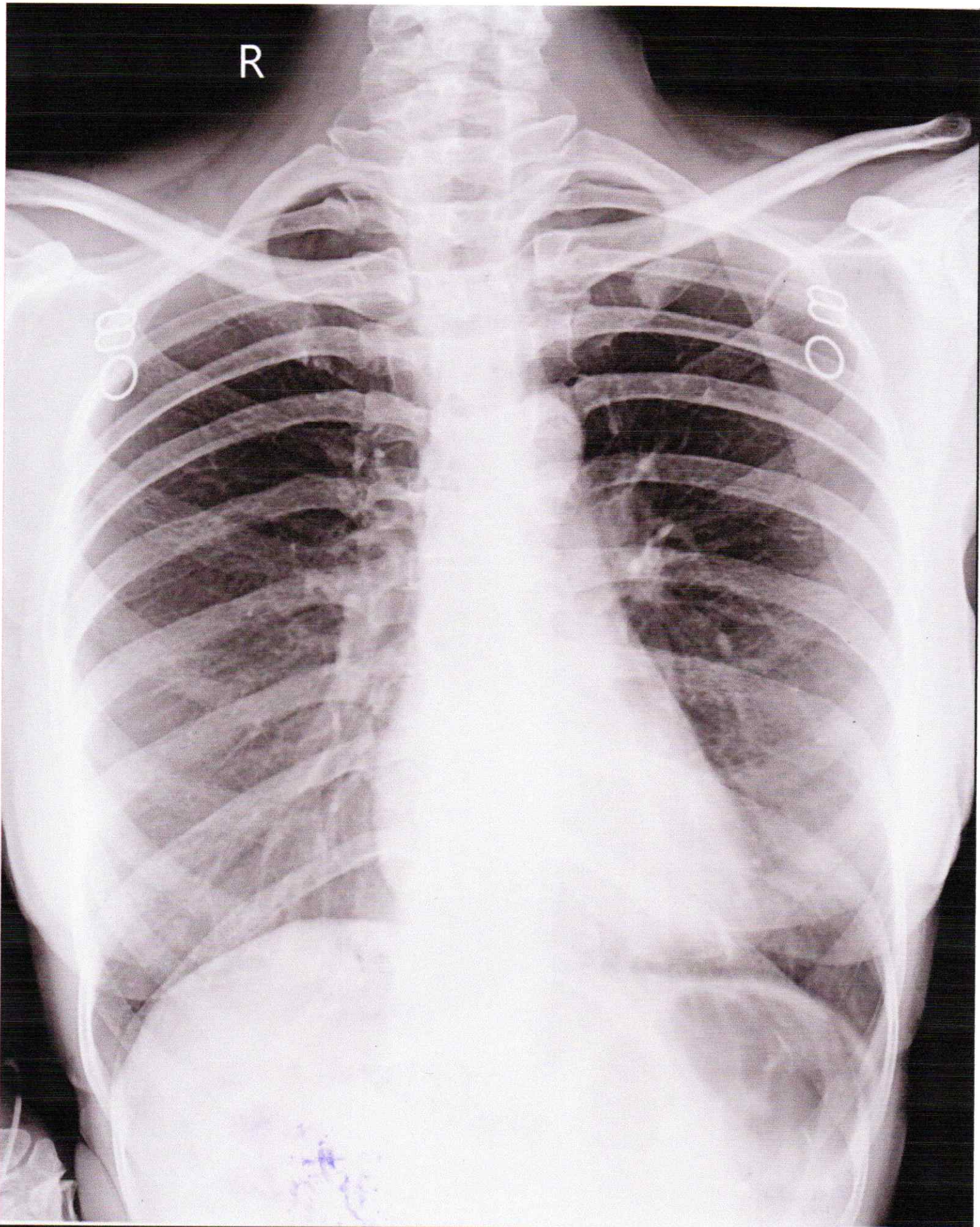
Address : Kabir Nagar (Near Sanjay Shiksha Niketan), Durgakund, Varanasi

Mobile : 9554572190 / 9453837595 / Recpn. 9389994334

E-mail : dramishra@gmail.com, drpallaviojha@gmail.com, Website: www.piire.org



R



MEENA MEHTA 50Y/F 2541 O CHEST P.A. 28-Nov-22 01:43 PM

PANACEA HOSPITAL, KABIR NAGAR, DURGAKUND, VARANASI



# PANACEA HOSPITAL

*A shelter for many hearts A Home for many lives*

(An ISO 9001:2008 Certified Organisation)

Lab Attached with CMC Vellore Under EQAS Scheme

**NAME:** MRS. MEENA MEHTA

**AGE/SEX:** 50 YRS / FEMALE

**REF BY:** DR. ASHUTOSH MISHRA (MD)

**DATE:** 28/11/2022

## ULTRA SOUND FOR ABDOMAN REPORT

- Liver:** Normal in shape and size(9.9cm) and shows smooth and regular margin.  
No diffuse/focal lesion seen.
- Gall bladder** Partially distended with normal wall thickness and echo-free lumen.
- CBD** Visualized part normal in course & caliber.
- Pancreas:** Normal in size, shape & echogenicity.  
Margins are smooth & regular.  
No diffuse/ focal lesion seen. Pancreatic tail obscured.
- Spleen:** Normal in size(8.0 cm) shape & echogenicity.  
Margins are smooth & regular. No diffuse / focal lesion seen.  
Splenic vessels at hilum is normal.
- Kidney:** Right kidney: 7.4 X 3.3cm  
Left kidney: 7.3 X3.7 cm  
Normal cortical echogenicity with well maintained Cortical-medullary differentiation.  
Pelvicalyceal system normal.  
No calculus/mass lesion seen.  
No hydronephrosis/ hydroureter seen.

**Address :** Kabir Nagar (Near Sanjay Shiksha Niketan), Durgakund, Varanasi

**Mobile :** 9554572190 / 9453837595 / Recpn. 9389994334

**E-mail :** dramishra@gmail.com, drpallaviojha@gmail.com, Website: www.piire.org





# PANACEA HOSPITAL

*A shelter for many hearts A Home for many lives*

(An ISO 9001:2008 Certified Organisation)  
Lab Attached with CMC Vellore Under EQAS Scheme

**Urinary bladder:** Normally distended, wall thickness is normal.  
No echogenic foci lumen or diverticula seen.  
Both VUJ appears normal.  
No E.R. calculus / mass lesion seen.

**Uterus:** Uterus normal in size shape, & echogenicity.  
Margins are smooth & regular.  
Endometrial thickness within normal limits .

**Ovary:** Right ovary normal in size and shows normal morphology.  
Left ovary normal in size and shows normal morphology.

**Others:** No free fluid in peritoneal cavity.  
No free fluid in bilateral pleural cavity.

**IMPRESSION:**

- **NO SIGNIFICANT SONOLOGICAL ABNORMALITY DETECTED.**

---

Please correlate clinically and further investigations.

**DR. PALLAVI MISHRA**  
MBBS MD(MED) Lucknow  
Echocardiography specialist, MIAE  
Non invasive cardiologist  
Women cardiologist

  
**Radiologist**

**Dr. Tusharika Rai**  
MBBS MS

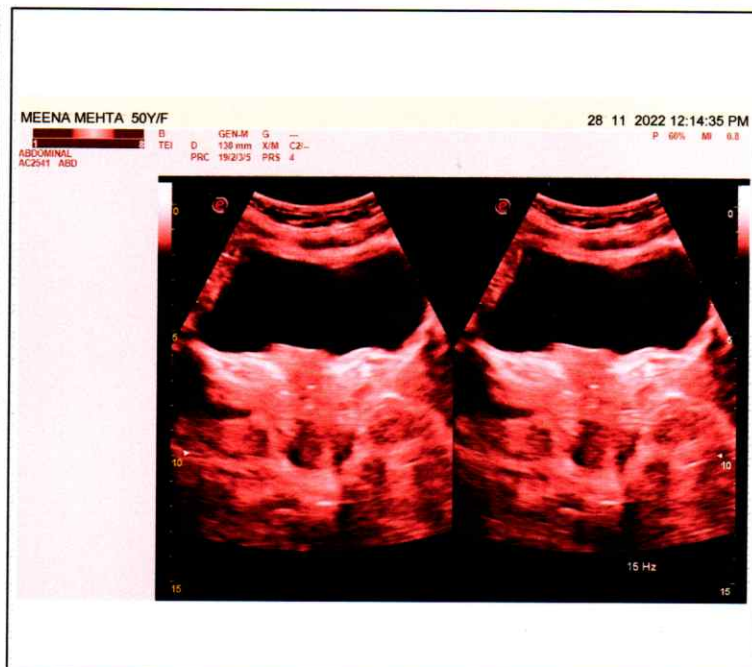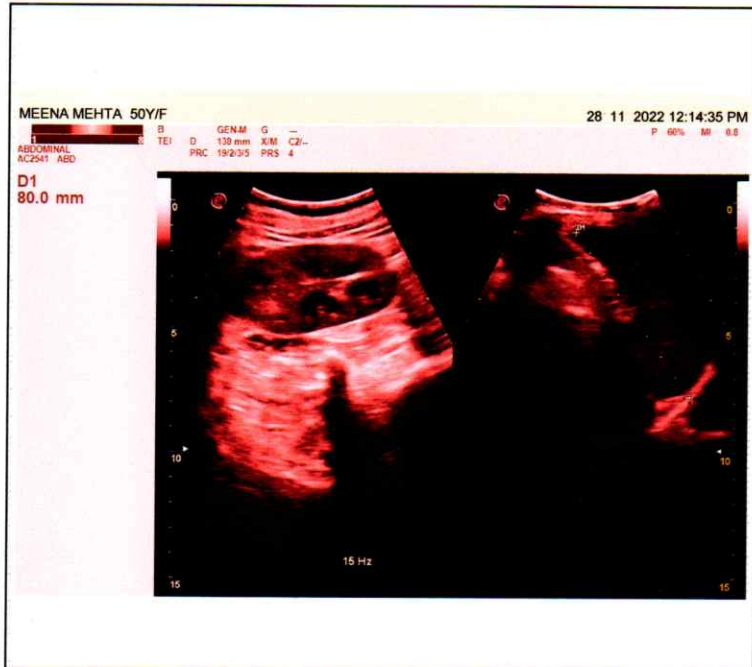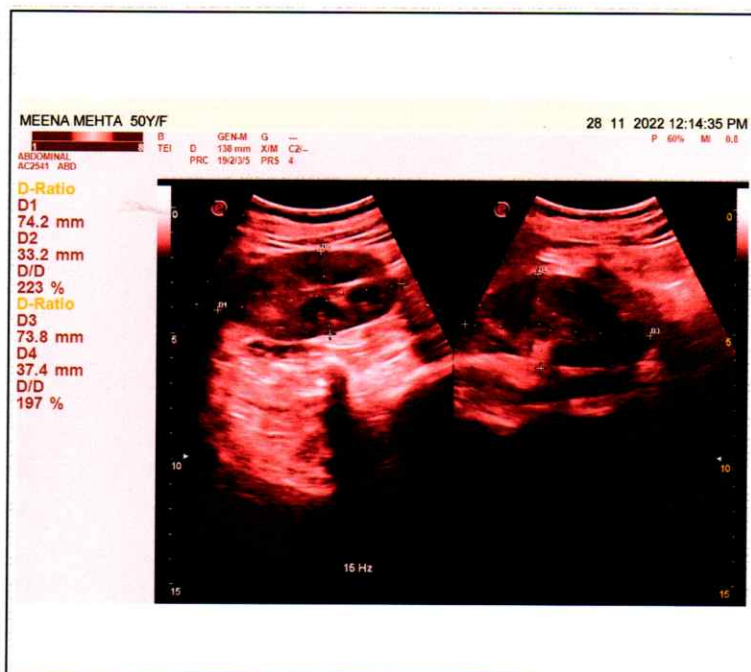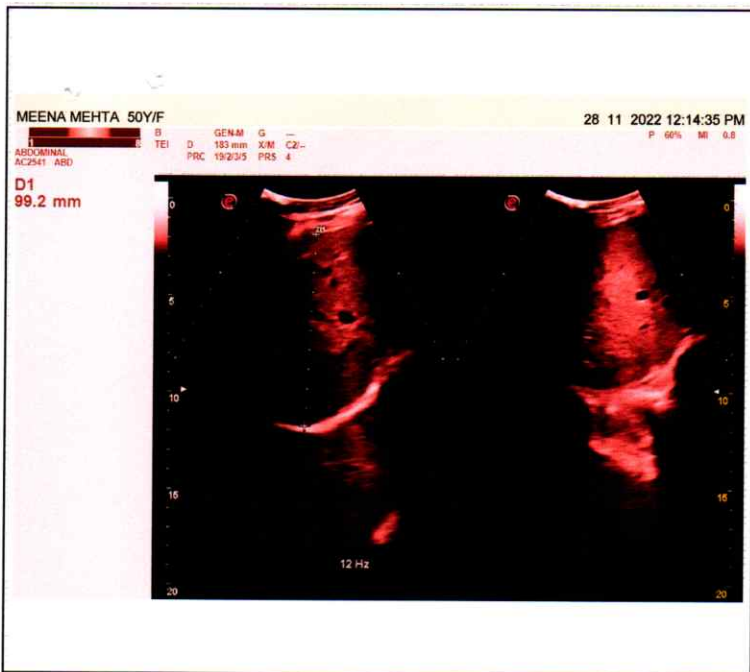---

Note: (1) This report is not valid for medico-legal purposes.  
(2) In case of any discrepancy due typing error, please get it Rectified immediately.

**Address : Kabir Nagar (Near Sanjay Shiksha Niketan), Durgakund, Varanasi**

**Mobile : 9554572190 / 9453837595 / Recpn. 9389994334**

**E-mail : dramishra@gmail.com, drpallaviojha@gmail.com, Website: www.piire.org**





Call Now - 1800-123-3070

# PANACEA HOSPITAL

*A shelter for many hearts A Home for many lives*

(An ISO 9001:2008 Certified Organisation)

Lab Attached with CMC Vellore Under EQAS Scheme

**NAME:** MRS. MEENA MEHTA

**AGE/SEX:** 50 YRS/FEMALE

**REF BY:** DR.ASHUTOSH MISHRA(MD)

**DATE:** 28/11/2022

## X-RAY CHEST PA

### BOTH LUNG FIELDS AND PLEURAE:

Both lungs show normal bronchovascular pattern.

Right & left hila are normal

No focal mass or calcification is seen

There is no evidence of any fluid in the both the pleural cavities.

Both domes of diaphragms are normal in position.

### MEDIASTINUM:

Trachea is central in position.

Cardiac silhouette is of normal size and configuration.

No evidence of pericardial effusion.

No significant lymphadenopathy is seen.

Visualized skeleton is normal.

-----  
NO SIGNIFICANT RADIOGRAPHIC ABNORMALITY.

**REPORTED BY**

**DR. ALPANA PATHAK**

**MBBS (HONS, GOLD MEDALIST) PMCH , PATNA  
MD RADIODIAGNOSIS (GOLD MEDALIST) IMS BHU  
EX-SR, IMS BHU, VARANASI**

**Address :** Kabir Nagar (Near Sanjay Shiksha Niketan), Durgakund, Varanasi

**Mobile :** 9554572190 / 9453837595 / Recpn. 9389994334

**E-mail :** dramishra@gmail.com, drpallaviojha@gmail.com, Website: www.piire.org