
  
**ભારત સરકાર**  
 Government of India

**વિજયકુમાર**  
 Vijaykumar  
 જન્મ તારીખ / DOB : 23/05/1978  
 પુરુષ / Male

  
**8723 4655 3000**

**આધાર - સામાન્ય મારાસળી અધિકાર**

**Dr. NITIN AGARWAL**  
 MBBS, MD  
 Regn. No. DMCR-1436

**ONEPLUS ULTRASOUND LAB**  
 17, Hareh Vihar, Pitam Pura,  
 Delhi-110034  
 011-4710101, 011-26561305  
 www.oneplusultrasound.com  
 Email: oneplusul@oneplusul.com

*[Handwritten Signature]*

**ભારતીય વિશિષ્ટ ઓળખાણ પ્રાધિકાર**  
**Unique Identification Authority of India**

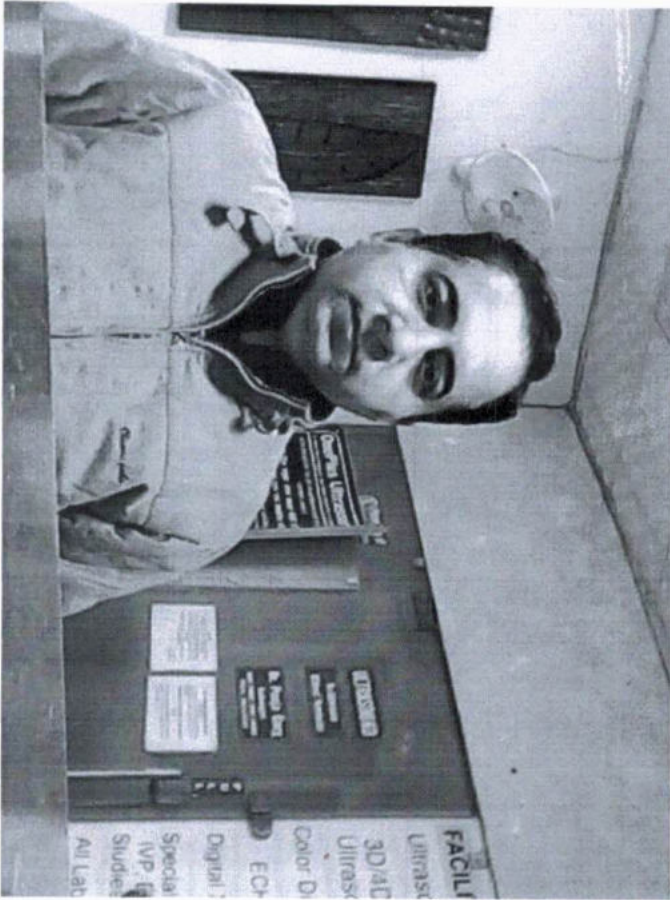
**સરનામું:** S/O: જગદીશ રામ, મોહલા  
 કચ્છીયારી કલોહ સરાઈ પાસે, કલોહ, કલો  
 (145), કલો, ઉના, હિમાચલ પ્રદેશ, 177201

**Address:** S/O: Jagdish Ram, Mohalla  
 Kachhiani, Near Kaloh sarai, Kaloh, Kaloh  
 (145), Kaloh, Una, Himachal Pradesh,  
 177201

**8723 4655 3000**

help@uidai.gov.in  
 www.uidai.gov.in





DR. NITIN AGARWAL  
MBBS, MD  
Regn. NO. DMC-R-1436

ONEPLUS ULTRASOUND LAB  
47, Harsh Vihar, Pitam Pura,  
Delhi-110034  
Ph. 011-47130101, 9509913051  
E-mail: oneplusul@gmail.com



# ONEPLUS ULTRASOUND LAB

47, HARSH VIHAR, PITAMPURA, DELHI- 110034

Mr. VIJAY KUMAR  
 Age : 44/M  
 Ref. by : MEDIWHEEL  
 Indication 1 :  
 Indication 2 :  
 Indication 3 :  
 COMMENTS : Normal ECG

ID : 2060  
 HWV1 : 194/55  
 Recorded : 29-12-2022 8:31  
 Medication 1 :  
 Medication 2 :  
 Medication 3 :

BPM : 79  
 BP : 128/80  
 P Axis : 66 deg  
 QRS Axis : 48 deg  
 T Axis : 65 deg

P duration : 86 msec  
 PR duration : 120 msec  
 QRS duration : 93 msec  
 QT interval : 300 msec  
 QTc interval : 333 msec

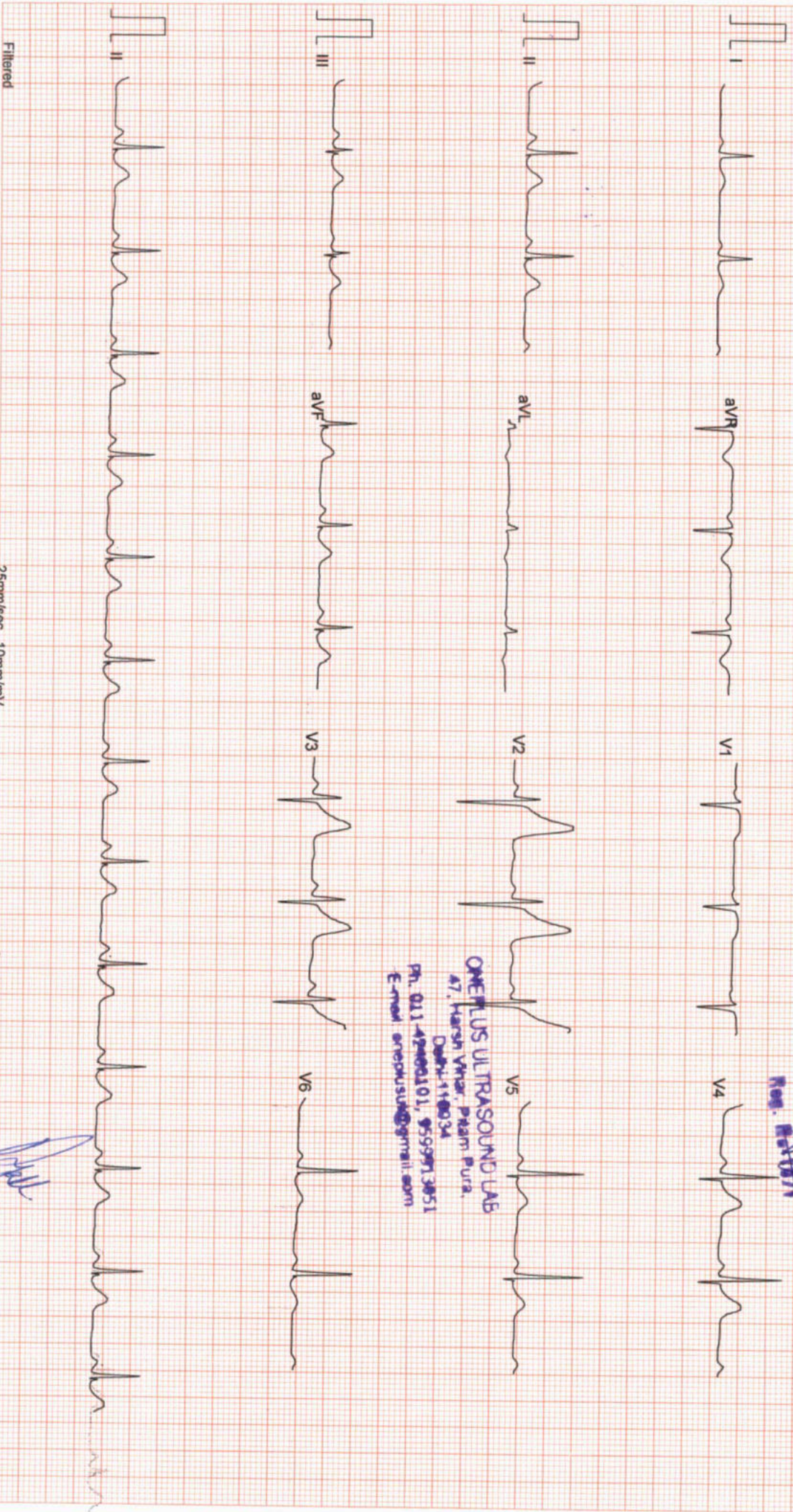
Raw E.C.G.(Seq)

Unconfirmed Report Reviewed By:

Cardiologist

**Dr. Anshu Gupta**  
 Reg. No. 1071

ONEPLUS ULTRASOUND LAB  
 47, Harsh Vihar, Pitampura,  
 Delhi-110034  
 Ph. 011-42000101, 95999713051  
 E-mail onepusul@gmail.com



Filtered

25mm/sec 10mm/mV

CardiCom, INDIA



# ONEPLUS ULTRASOUND LAB

47, HARSH VIHAR PITAMPURA DELHI 110034

**MR. VIJAY KUMAR**  
 Age/Sex : 44/M  
 Ref. by : MEDIVHEEL  
 Indication1 :  
 Indication2 :  
 Indication3 :

ID : 995  
 H/Wt : 154/55  
 Recorded : 29-12-2022 8:36

**TREADMILL TEST SUMMARY REPORT**  
 Protocol : BRUCE  
 History :

Medication1 :  
 Medication2 :  
 Medication3 :

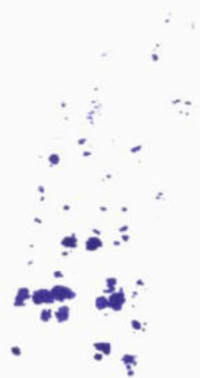PHASE	PHASE TIME	STAGE TIME	SPEED (Km./Hr.)	GRADE (%)	H.R. (BPM)	B.P. (mmHg)	RRP X100	II	ST LEVEL (mm) V2	V5	METS
STANDING SUPINE					82	128/80	104	0.4	5.6	0.6	
STAGE 1	2:59	2:59	2.70	10.00	82	128/80	104	0.4	5.6	0.5	
STAGE 2	5:59	2:59	4.00	12.00	113	140/82	158	0.6	5.9	0.8	4.80
STAGE 3	6:59	0:59	5.40	14.00	128	150/86	192	0.4	5.7	0.5	7.10
PEAK EXER	7:13	1:13			148	150/86	222	-0.1	5.0	0.3	8.06
RECOVERY	2:59	2:59	0.00	0.00	155	162/90	251	0.3	4.8	0.0	
					86	130/82	111	-0.5	3.4	-0.3	8.28

**RESULTS**  
 Exercise Duration : 7.13 Minutes  
 Max Heart Rate : 155 bpm  
 Max Blood Pressure : 162/90 mmHg  
 Max Work Load : 8.28 METS  
 Reason of Termination :

Negative for ischemia

**DR. P.K. GUPTA**  
**MBBS, MD**  
 Reg. No. 1071  
 Cardiologist

**ONEPLUS ULTRASOUND LAB**  
 47, Harsh Vihar, Pitam Pura,  
 Delhi-110034  
 Ph: 011-42400101, 9559913051  
 Email: onepusuk@gmail.com





# ONEPLUS ULTRASOUND LAB

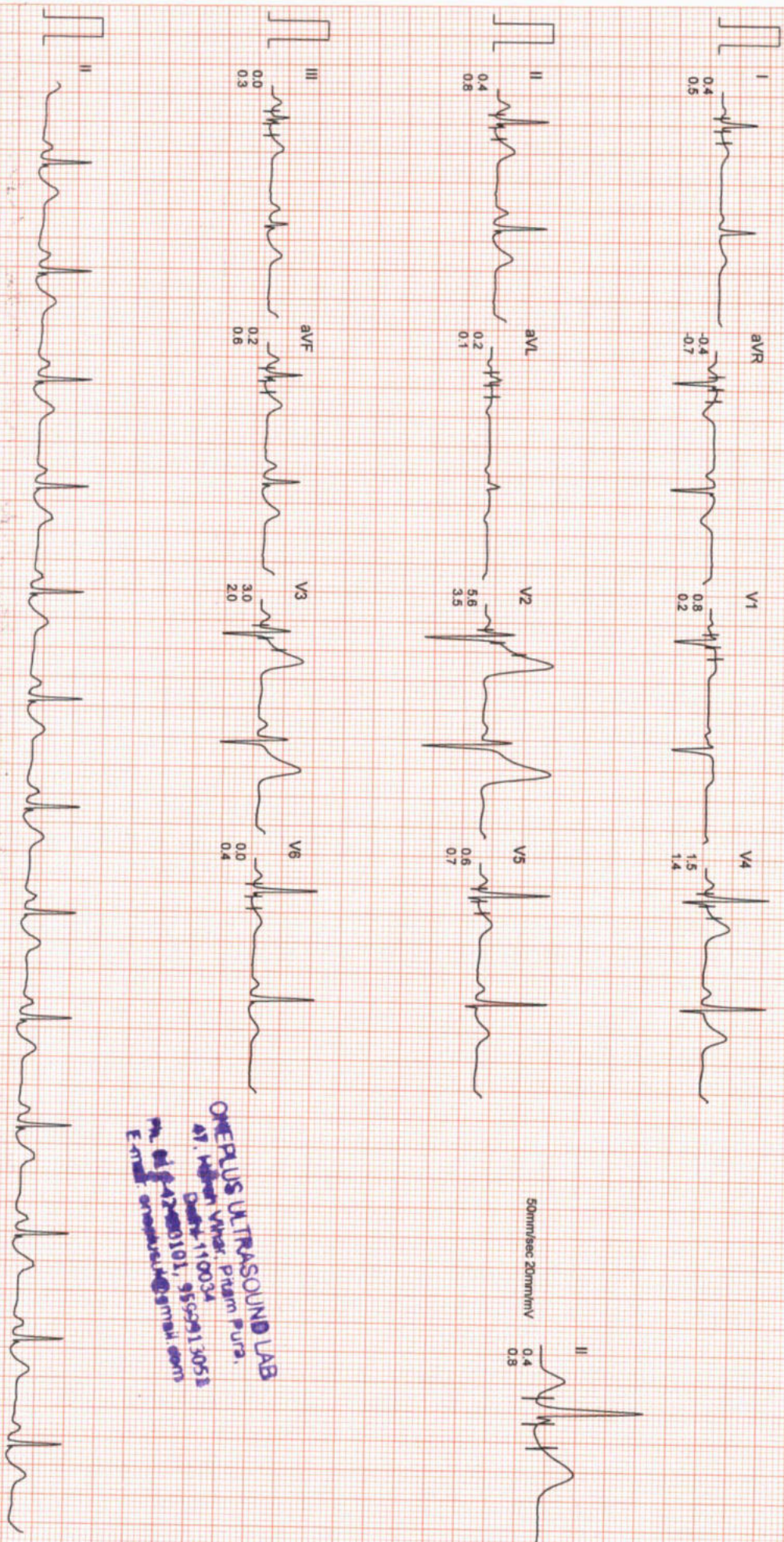
STANDING  
PRETEST

ST @ 10mm/mV  
80ms PostJ

MR. VIJAY KUMAR  
I.D. : 995  
AGE/SEX : 44/M  
RECORDED : 29-12-2022 8:36

RATE : 82 BPM  
B.P. : 128/80 mmHg

LINKED MEDIUM



ONEPLUS ULTRASOUND LAB  
A1, Indiran Vihar, Pritham Pura,  
Gurgaon-110034  
Mobile: 9109913053  
Ph: 012-2680101, 9509913053  
Email: onepusul@siml.com



Mr. VIJAY KUMAR  
I.D. : 995  
AGE/SEX : 44/M

RECORDED : 29-12-2022 8:36

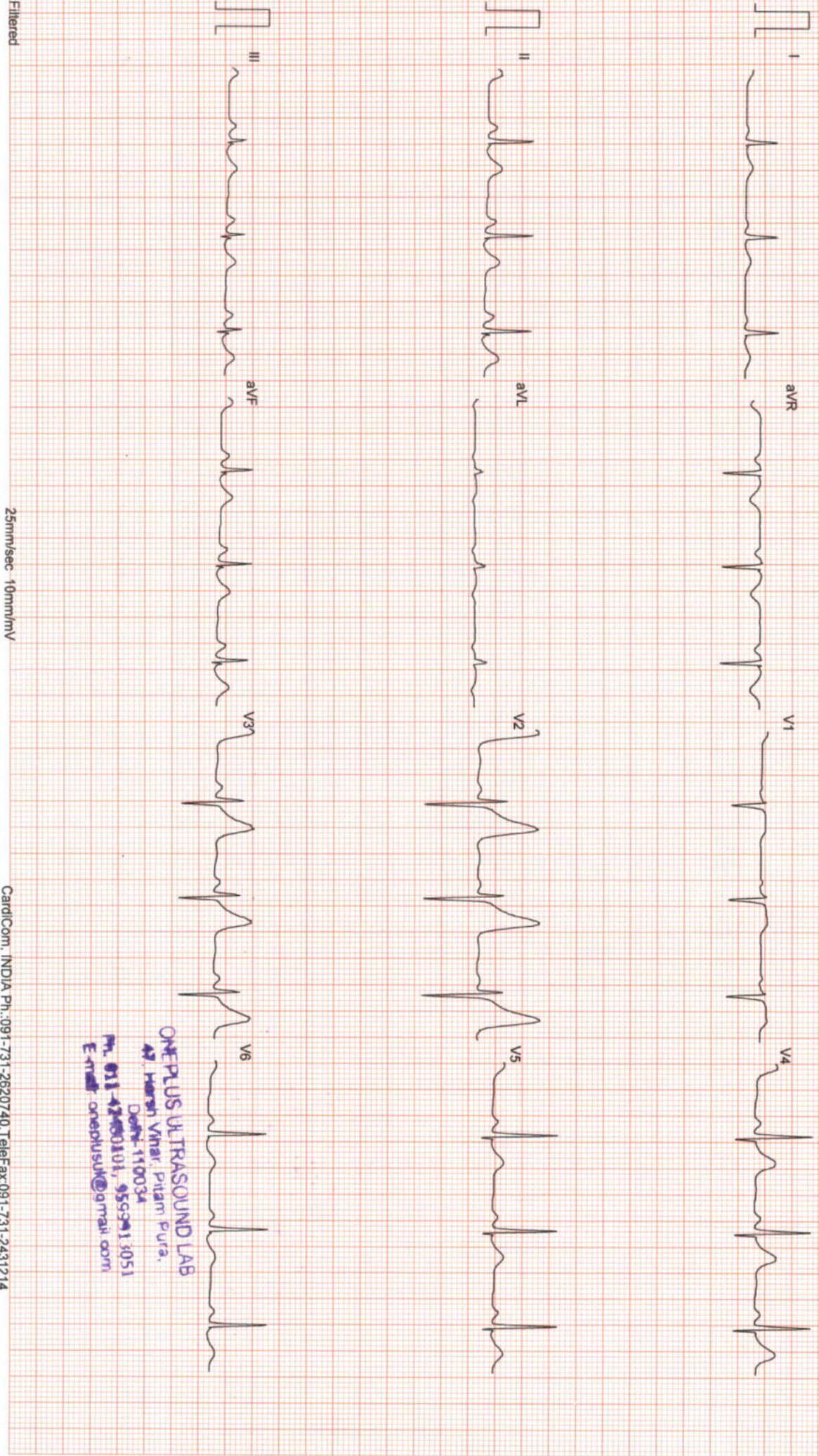
RATE : 82 BPM  
B.P. : 128/80 mmHg

# ONEPLUS ULTRASOUND LAB

SUPINE  
PRETEST

ST @ 10mm/mV  
80ms PostJ

RAW E.C.G.



ONEPLUS ULTRASOUND LAB  
47, Mahesh Vihar, Pitampura, Delhi-110034  
Ph. 011-42660804, 9559913051  
E-mail: onepusult@gmail.com



# ONEPLUS ULTRASOUND LAB

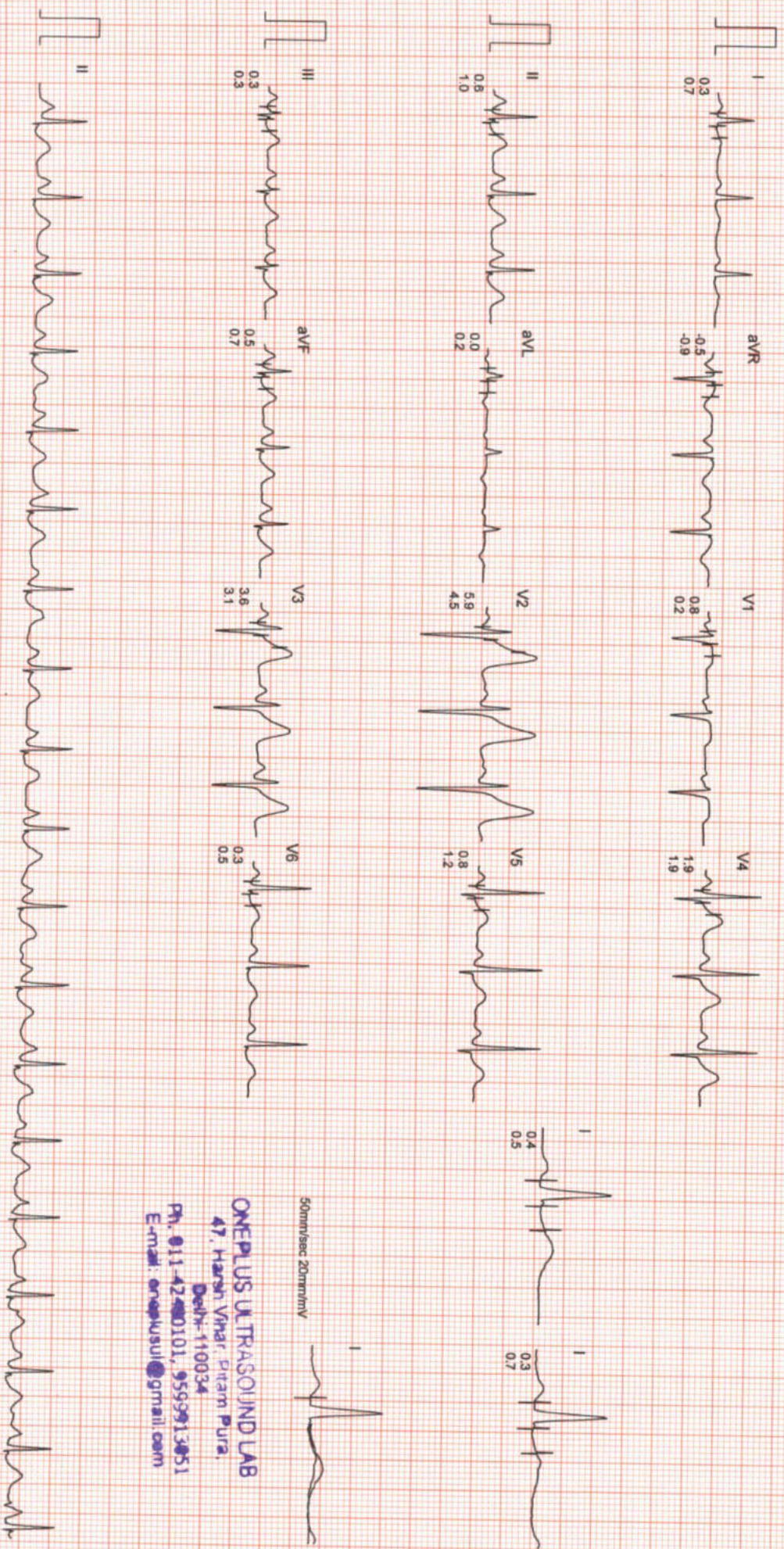
Mr. VIJAY KUMAR  
 I.D. : 995  
 AGESEX : 44/M  
 RECORDED : 29-12-2022 8:36

RATE : 113 BPM  
 B.P. : 140/82 mmHg

BRUCE  
 EXERCISE 1  
 PHASE TIME : 2:59  
 STAGE TIME : 2:59

ST @ 10mm/mV  
 80ms PostJ  
 SPEED : 2.7 Km./Hr.  
 GRADE : 10.0 %

LINKED MEDIAN



50mm/sec 20mm/mV

**ONEPLUS ULTRASOUND LAB**  
 47, Harsan Vihar, Pitam Pura,  
 Delhi-110034  
 Ph. 011-42480101, 9599913051  
 E-mail: oneplusul@gmail.com



# ONEPLUS ULTRASOUND LAB

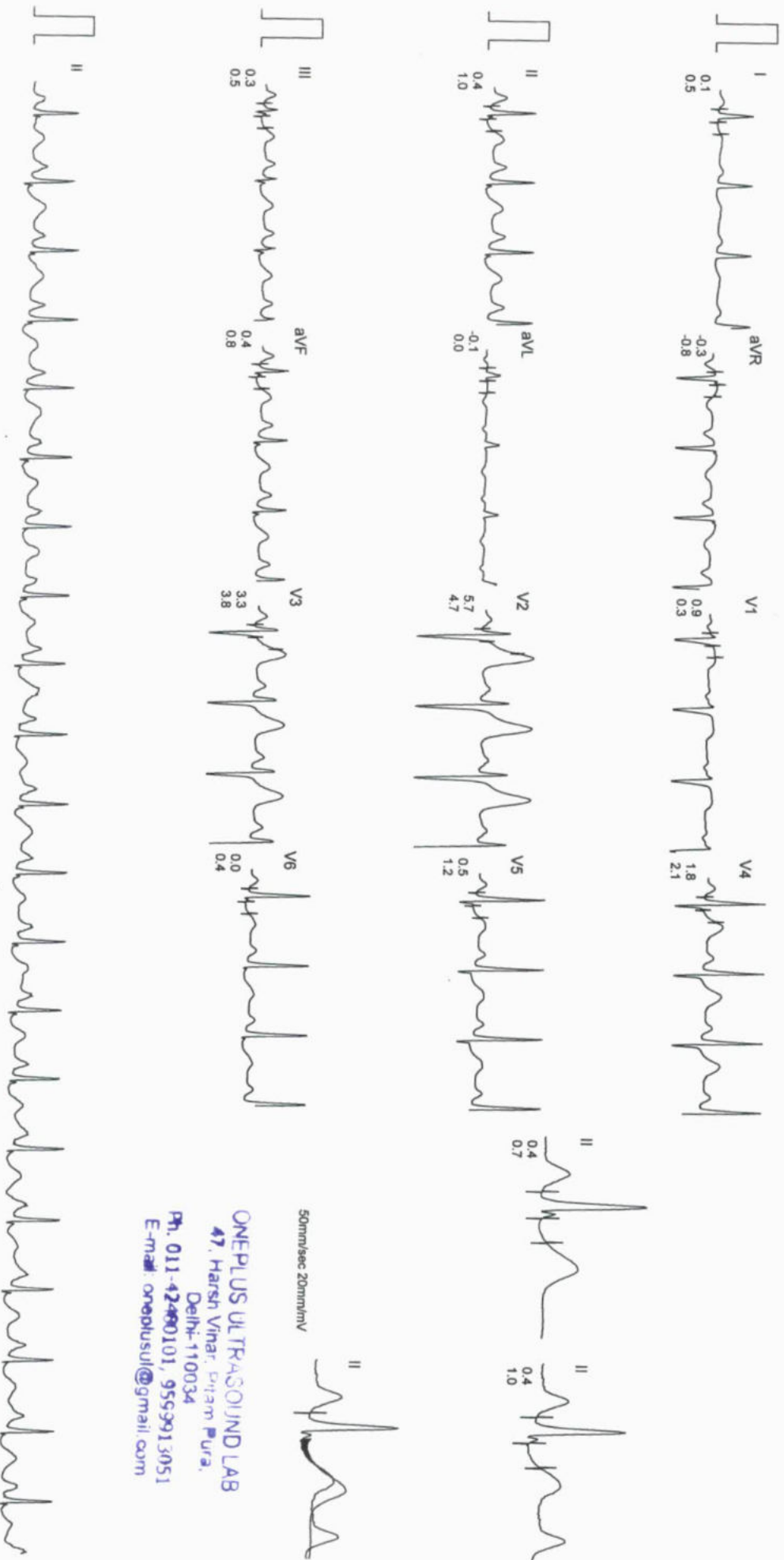
Mr. VIJAY KUMAR  
I.D. : 995  
AGE/SEX : 44/M  
RECORDED : 29-12-2022 8:36

RATE : 128 BPM  
B.P. : 150/86 mmHg

BRUCE  
EXERCISE 2  
PHASE TIME : 5:59  
STAGE TIME : 2:59

ST @ 10mm/mV  
80ms PostJ  
SPEED : 4.0 Km./hr.  
GRADE : 12.0 %

LINKED MEDIAN



50mm/sec 20mm/mV

ONEPLUS ULTRASOUND LAB  
47, Harsh Vihar, Durgam Pura,  
Delhi-110034  
Ph. 011-4240101, 9559913051  
E-mail: oneplusul@gmail.com





# ONEPLUS ULTRASOUND LAB

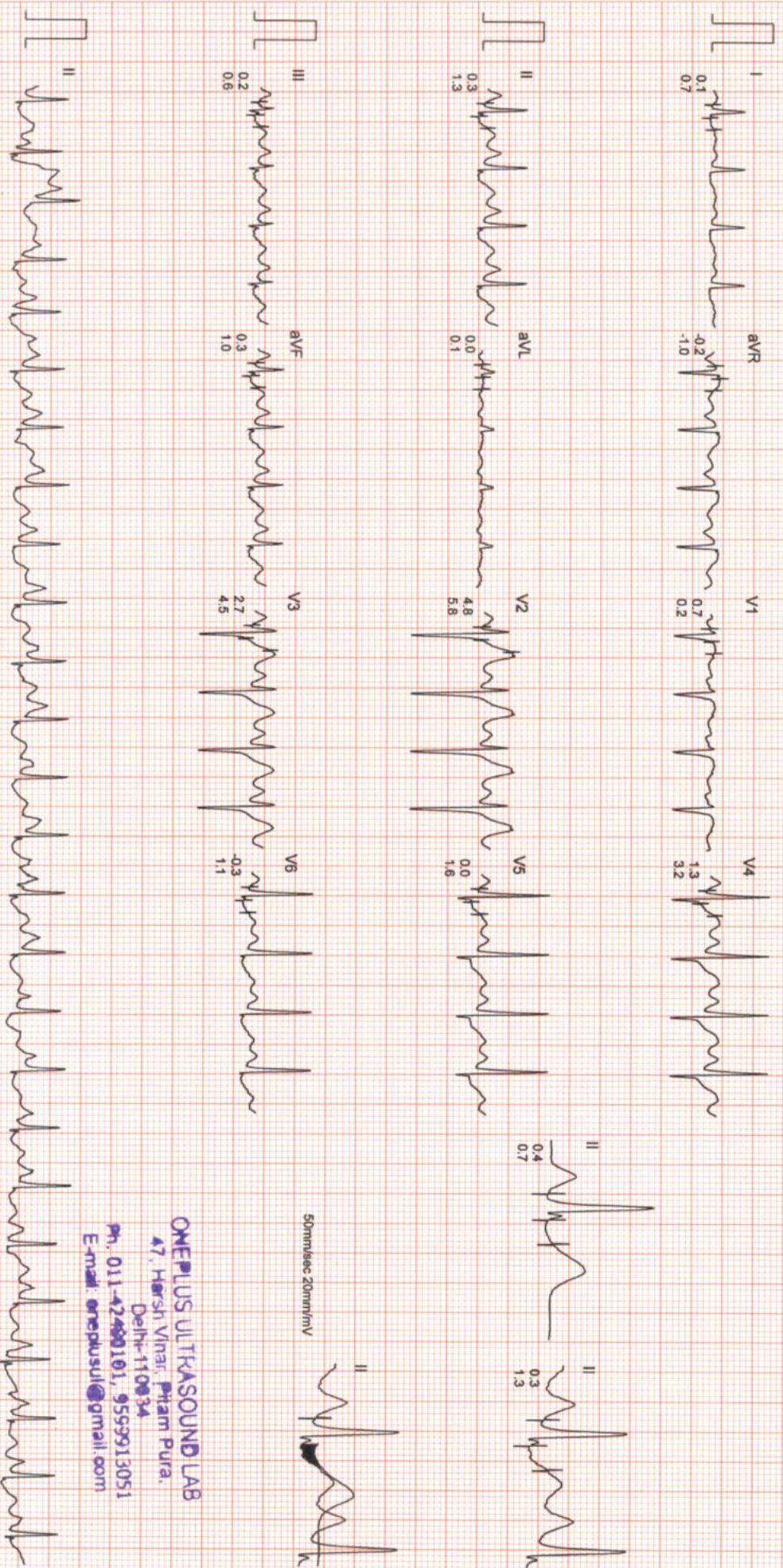
Mr. VIJAY KUMAR  
I.D. : 995  
AGE/SEX : 44/M  
RECORDED : 29-12-2022 8:36

RATE : 155 BPM  
B.P. : 162/90 mmHg

BRUCE  
PEAK EXER  
PHASE TIME : 7:13  
STAGE TIME : 1:13

ST @ 10mm/mV  
80ms PostJ  
SPEED : 5.4 Km./HR.  
GRADE : 14.0 %

LINKED MEDIAN



50mmsec 20mm/mV

ONEPLUS ULTRASOUND LAB  
47, Hersh Vihar, Pitam Pura,  
Delhi-110034  
Ph. 011-42460101, 9559913051  
E-mail: oneplusul@gmail.com



# ONEPLUS ULTRASOUND LAB

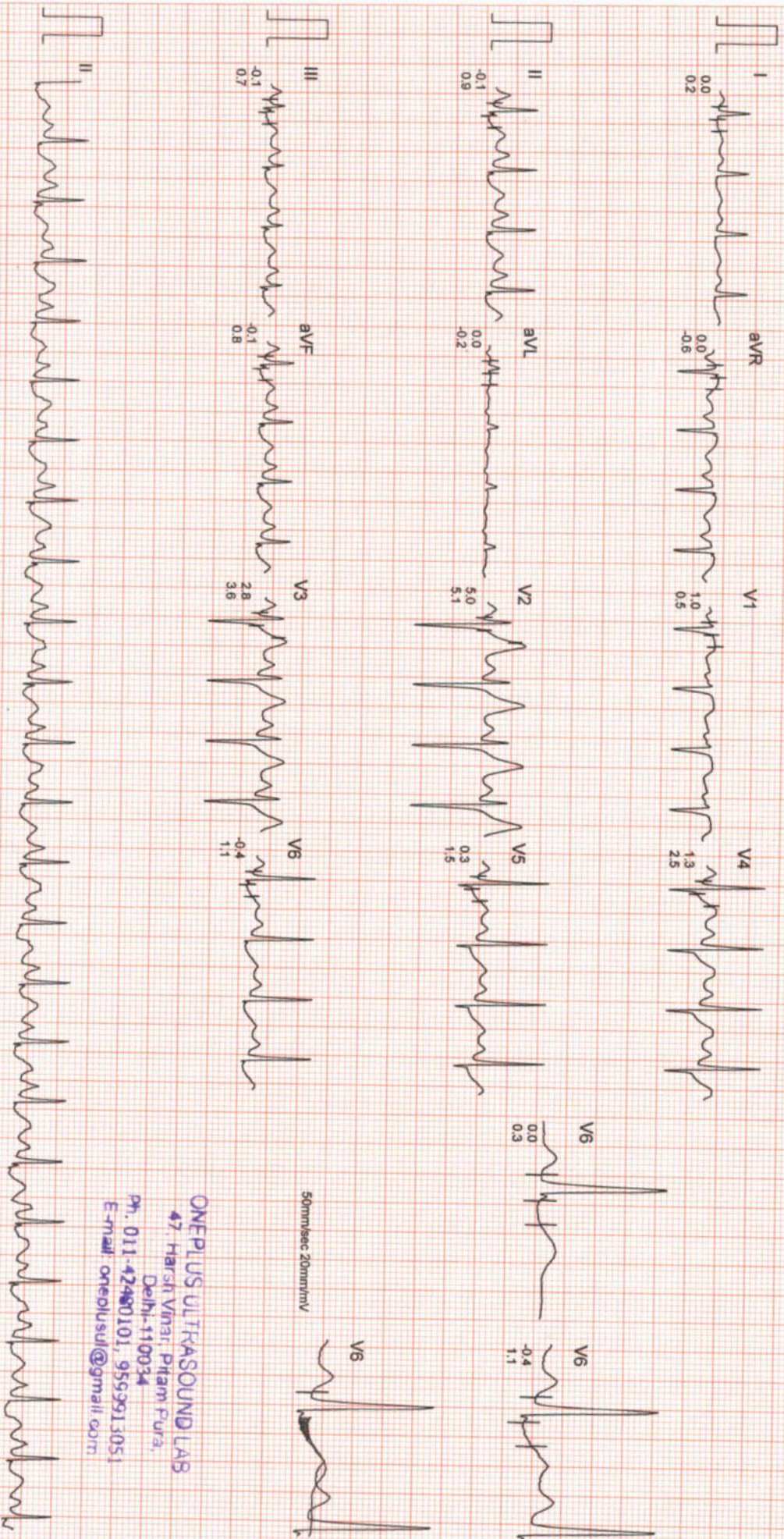
Mr. VIJAY KUMAR  
 I.D. : 995  
 AGE/SEX : 44/M  
 RECORDED : 29-12-2022 8:36

RATE : 148 BPM  
 B.P. : 150/86 mmHg

BRUCE  
 EXERCISE 3  
 PHASE TIME : 6:59  
 STAGE TIME : 0:59

ST @ 10mm/mV  
 80ms PostJ  
 SPEED : 5.4 Km./Hr.  
 GRADE : 14.0 %

LINKED MEDIAN



Filtered Computer Corrected Baseline 25mm/sec 10mm/mV CardCom, INDIA Ph: 091-731-2620740, Tel: 091-731-2433114

ONEPLUS ULTRASOUND LAB  
 47, Harsh Vihar, Pitam Pur, Delhi-110034  
 Ph. 011-42480101, 95593913051  
 E-mail: oneplusul@gmail.com



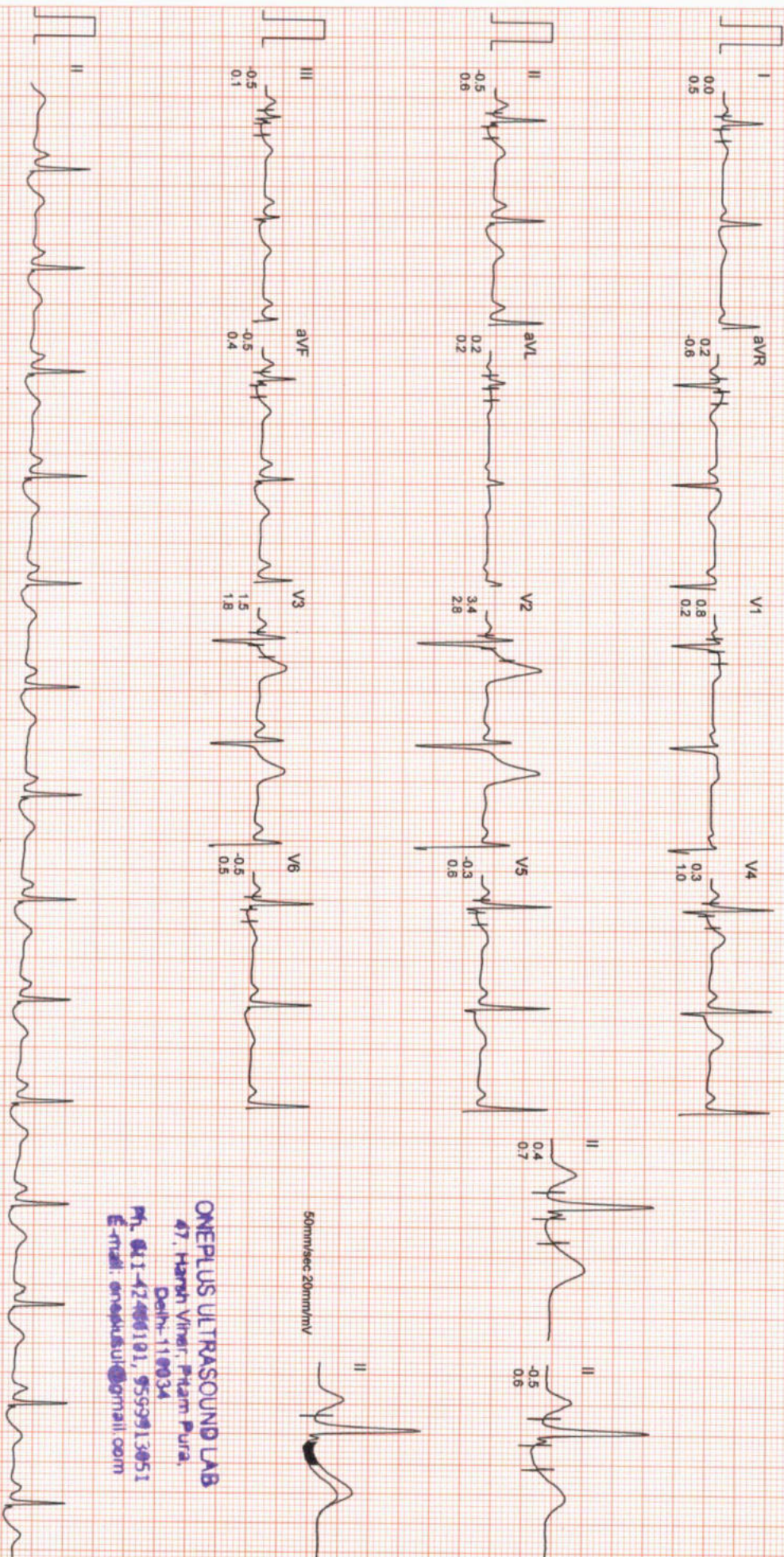
# ONEPLUS ULTRASOUND LAB

Mr. VIJAY KUMAR  
I.D. : 995  
AGE/SEX : 44/M  
RECORDED : 29-12-2022 8:36

RATE : 86 BPM  
B.P. : 130/82 mmHg

BRUCE  
RECOVERY  
PHASE TIME : 2:59

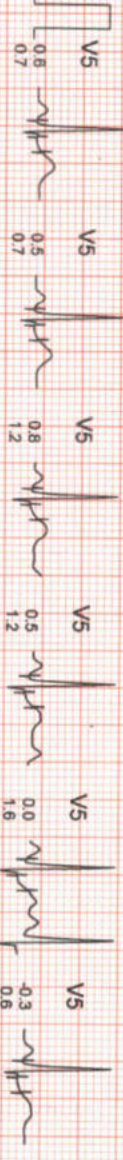
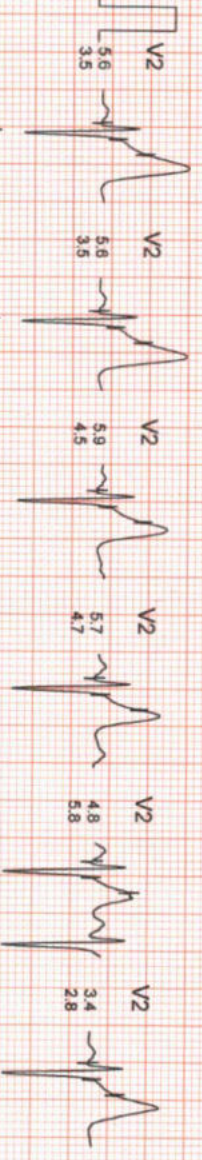
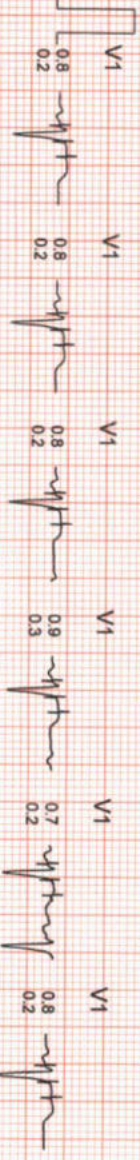
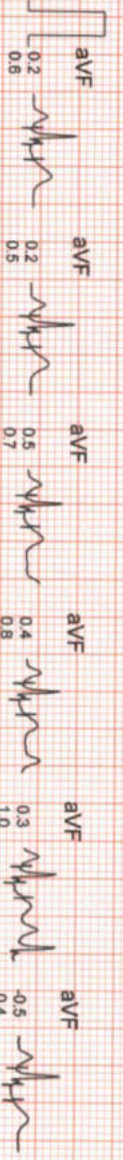
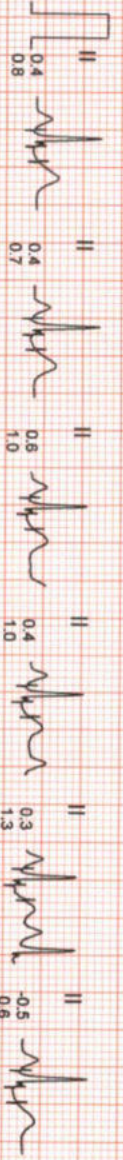
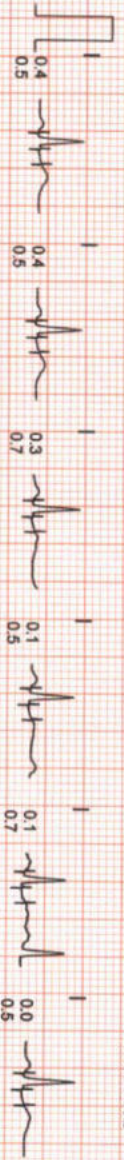
ST @ 10mm/mV  
80ms PostJ  
SPEED : 0.0 Km./Hr.  
GRADE : 0.0 %  
LINKED MEDIAN



ONEPLUS ULTRASOUND LAB  
47, Hansh Vinair, Pitam Pura,  
Delhi-110034  
Ph: 811-4246181, 959913651  
E-mail: oneplusul@gmail.com

11  
12  
13  
14  
15  
16  
17  
18  
19  
20  
21  
22  
23  
24  
25  
26  
27  
28  
29  
30  
31  
32  
33  
34  
35  
36  
37  
38  
39  
40  
41  
42  
43  
44  
45  
46  
47  
48  
49  
50  
51  
52  
53  
54  
55  
56  
57  
58  
59  
60  
61  
62  
63  
64  
65  
66  
67  
68  
69  
70  
71  
72  
73  
74  
75  
76  
77  
78  
79  
80  
81  
82  
83  
84  
85  
86  
87  
88  
89  
90  
91  
92  
93  
94  
95  
96  
97  
98  
99  
100

STANDING	SUPINE	STAGE 1	STAGE 2	PEAK EXERCISE	RECOVERY
0.0kmph 82 bpm B.P. 128/80 80ms PostU	0.0kmph 82 bpm B.P. 128/80 80ms PostU	2.59 2.59 2.7kmph 10.0% 113 bpm B.P. 140/82 80ms PostU	5.59 2.59 4.0kmph 12.0% 128 bpm B.P. 150/86 80ms PostU	7.13 1.13 5.4kmph 14.0% 155 bpm B.P. 162/90 80ms PostU	2.59 0.0kmph 0.0% 86 bpm B.P. 130/82 80ms PostU

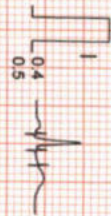


ONEPLUS ULTRASOUND LAB  
 A7, Harsh Vihar, Piliam Pura,  
 Delhi-110034  
 Ph. 011-4244101, 9599913051  
 E-mail onepulsul@gmail.com







SUPINE  
0.0Kmph  
0.0%  
82 bpm  
B.P. 128/80  
80ms PostJ



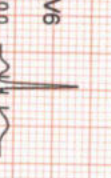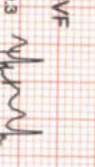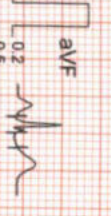
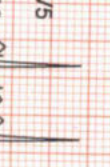


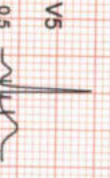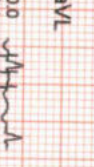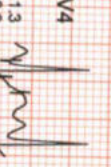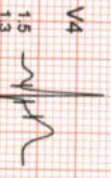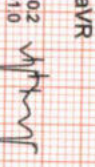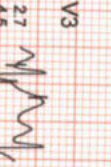
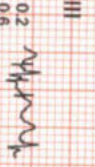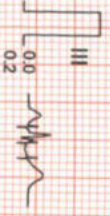
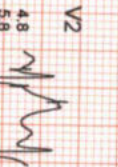
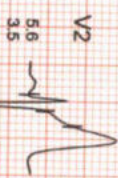

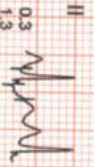PEAK EXERCISE  
7-13  
1-13  
5.4Kmph  
14.0%  
155 bpm  
B.P. 162/90  
80ms PostJ

SUPINE

0.0Kmph  
0.0%  
82 bpm  
B.P. 128/80  
80ms PostJ



PEAK EXERCISE  
7-13  
1-13  
5.4Kmph  
14.0%  
155 bpm  
B.P. 162/90  
80ms PostJ



ONEPLUS ULTRASOUND LAB  
47 Harsh Vihar, DITM Puri,  
Delhi-110034  
Ph. 011-42487101, 9569915951  
E mail onepplus1@gmail.com



Name	: Mr. VIJAY KUMAR	Age/Sex	: 44 YRS/Male
Ref. By	: Dr. MEDIWHEEL	Lab No	: 012212290003
Date	: 29-Dec-2022	Patient ID	: LSHHI106954

### X-ray-Chest PA view

Bony cage and soft tissues are normal.  
Cardiothoracic ratio is normal.  
Mediastinum is normal.  
Both hila are normal.  
Both costophrenic angles are clear.  
Both domes of diaphragm are normal.  
Lung fields are clear. No parenchymal lesion seen.

**IMPRESSION: Normal Study.**

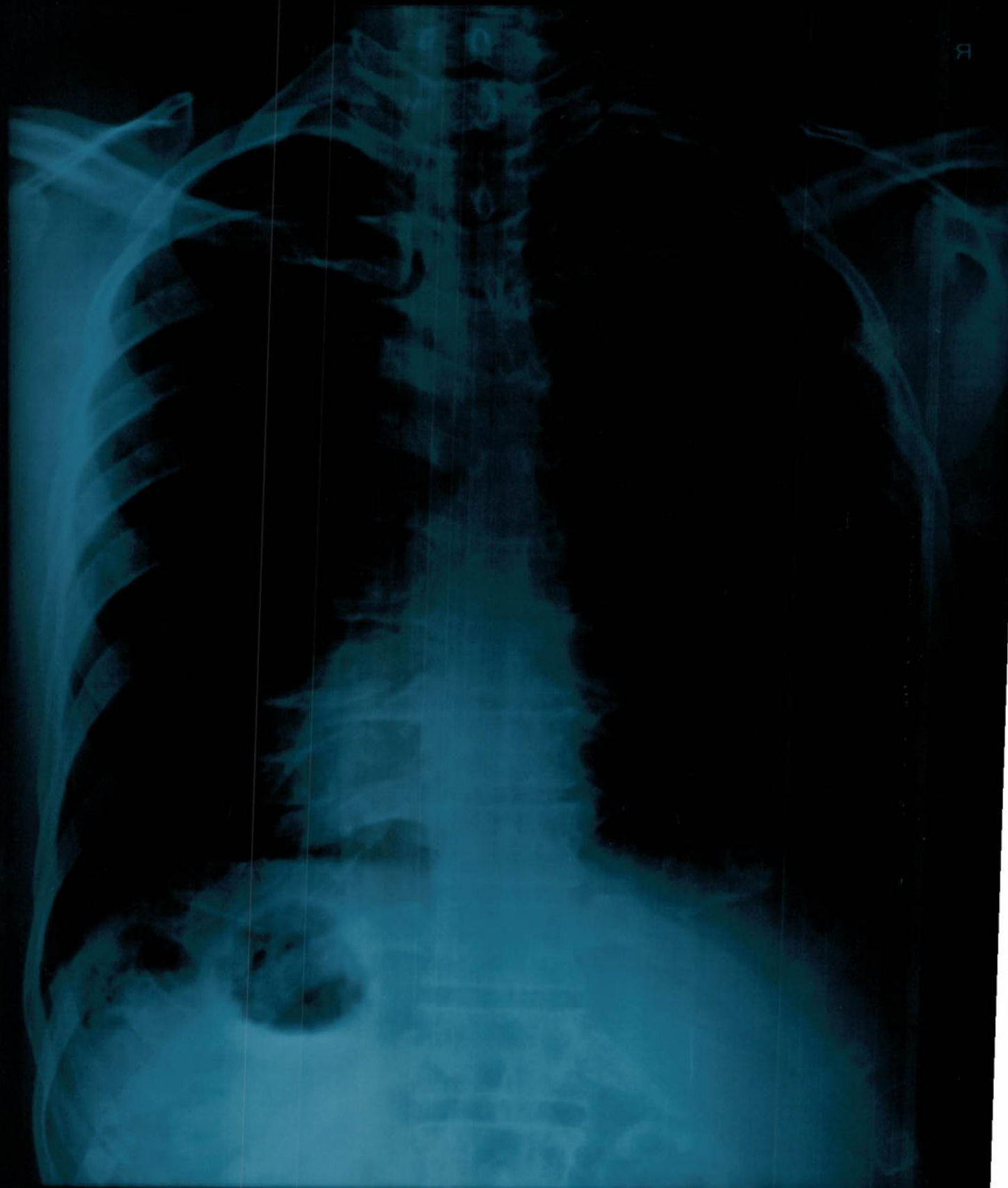
  
DR. POOJA GARG  
RADIOLOGIST  
REG. NO. MAMC/R/03398  
Radiologist

Type By : pooja

47, Harsh Vihar, Pitampura, New Delhi-110034 | Ph.: 011-42480101, 9599913051

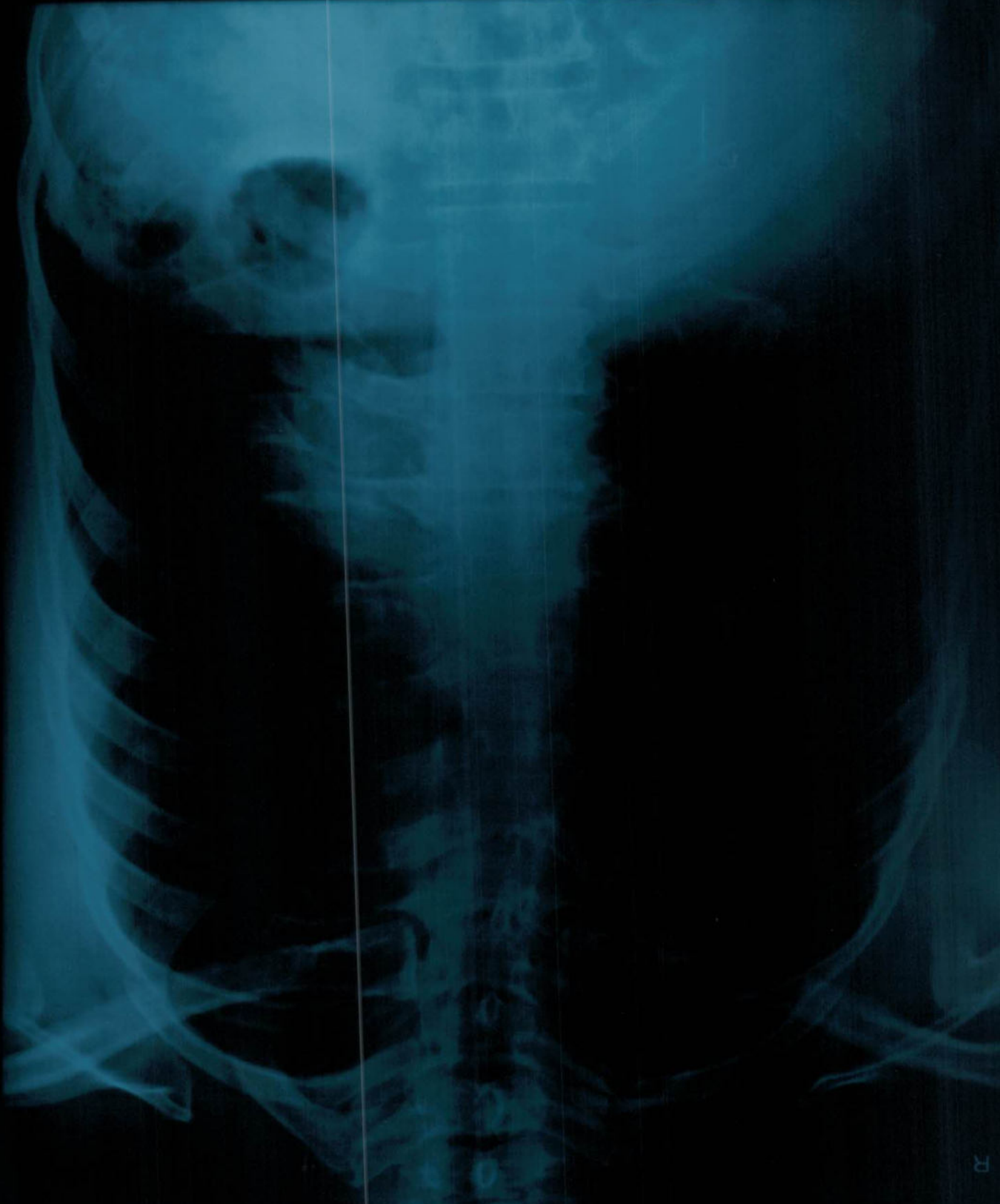E-mail: [oneplusul@gmail.com](mailto:oneplusul@gmail.com) | Web.: [www.oneplusul.in](http://www.oneplusul.in)

R



MR. VIJAY KUMAR 44 YRS 58M212022 M CHEST PA VIEW  
ONEPLUS ULTRASOUND LAB. AT HARSH VIHAR PITAMPURA

MR. VIJAY KUMAR 44 YRS 28/12/2022 M CHEST PA VIEW  
ONEPLUS ULTRASOUND LAB 47 HARSH VIHAR PITAMPURA



R



**OnePLUS**  
Ultrasound Lab  
— QUALITY FIRST... ALWAYS! —

**Dr. Nitin Agarwal**  
Pathologist & Director  
Ex. Sr. Res. MAMC  
& Lok Nayak Hospital  
Ex. Chief of Lab Dr. Lal Path Labs.

**Dr. Pooja (Garg) Agarwal**  
Radiologist & Director  
MAMC & Lok Nayak Hospital

<b>Name</b>	: Mr. VIJAY KUMAR	<b>Age/Sex</b>	: 44 YRS/Male
<b>Ref. By</b>	: Dr. MEDIWHEEL	<b>Lab No</b>	: 012212290003
<b>Date</b>	: 29-Dec-2022	<b>Patient ID</b>	: LSHHI106954

### ULTRASOUND EXAMINATION----WHOLE ABDOMEN

**Liver** is normal in size and outline with normal echopattern. Intrahepatic biliary radicles are not dilated. No abscess or mass lesion seen. Hepatic veins, portal vein, IVC and aorta are normal. CBD is normal in caliber.

**Gall bladder** is well distended with anechoic lumen. Wall thickness is normal.

**Both kidneys** are normal in size, shape, position, outline and echopattern. Corticomedullary differentiation is maintained. No pelvicalyceal dilation or mass lesion is seen. **A concretion is seen at mid pole of right kidney .A calculus (4.8mm) is seen at mid pole calyx of left kidney.**

**Spleen** is normal in size and echotexture. No mass lesion seen.

**Pancreas** is normal in size, outline and echotexture .

**Urinary bladder** is normal in shape and position. No evidence of intravesical stone or mass seen.

**Prostate** is **mildly enlarged in size**, normal in shape and echopattern.

**Prostate measures** 4.8 x 3.8 x 3.1 cm. **Weight of prostate is 28.9 grams.**

No abnormal bowel wall thickening seen in right iliac fossa.  
No free fluid seen anywhere in abdomen.

#### IMPRESSION:

- Mild prostatic hypertrophy.
- B/L renal concretion / calculi.

**DR. POOJA GARG**  
**RADIOLOGIST**  
REG NO- DMC/R/03398  
Reg No. DMC/R/03398  
Radiologist


Type By : pooja

47, Harsh Vihar, Pitampura, New Delhi-110034 | Ph.: 011-42480101, 9599913051  
E-mail: oneplusul@gmail.com | Web.: www.oneplusul.in

WYVONA MR VALDY 4488  
20 002 DR135 F48 P90 Frg Cam - 18.0cm

Quipus Ultrasound Lab  
CA17A / Abdomen / FR 20Hz Tls 0.1 102727 AM

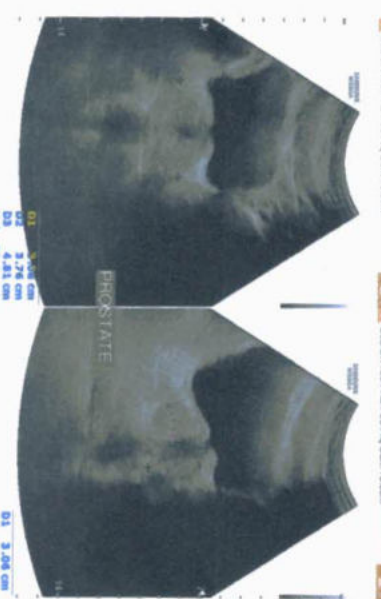
MR 1.4 28-12-2022  
10:27:27 AM



WYVONA MR VALDY 4488  
20 002 DR135 F48 P90 Frg Cam - 18.0cm

Quipus Ultrasound Lab  
CA17A / Abdomen / FR 20Hz Tls 0.1 102745 AM

MR 1.4 28-12-2022  
10:27:45 AM

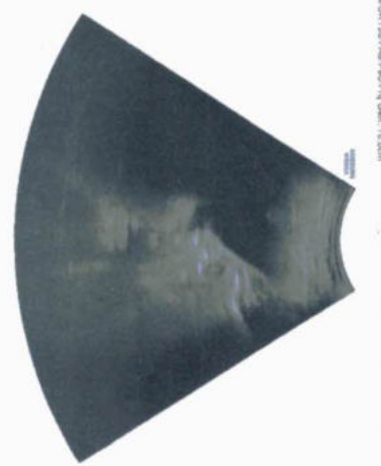


01 2.98 cm  
02 2.78 cm  
Vtl 28.81 ml

WYVONA MR VALDY 4488  
20 002 DR135 F48 P90 Frg Cam - 18.0cm

Quipus Ultrasound Lab  
CA17A / Abdomen / FR 20Hz Tls 0.1 102810 AM

MR 1.4 28-12-2022  
10:28:10 AM



WYVONA MR VALDY 4488  
20 006 DR135 F48 P90 Frg Cam - 18.0cm

Quipus Ultrasound Lab  
CA17A / Abdomen / FR 20Hz Tls 0.1 102817 AM


MR 1.4 28-12-2022  
10:28:17 AM



WYVONA MR VALDY 4488  
20 006 DR135 F48 P90 Frg Cam - 18.0cm

Quipus Ultrasound Lab  
CA17A / Abdomen / FR 20Hz Tls 0.1 102833 AM

MR 1.4 28-12-2022  
10:28:33 AM



WYVONA MR VALDY 4488  
20 006 DR135 F48 P90 Frg Cam - 18.0cm

Quipus Ultrasound Lab  
CA17A / Abdomen / FR 20Hz Tls 0.1 102844 AM

MR 1.4 28-12-2022  
10:28:44 AM



01 0.48 cm

WYVONA MR VALDY 4488  
20 006 DR135 F48 P90 Frg Cam - 18.0cm

Quipus Ultrasound Lab  
CA17A / Abdomen / FR 20Hz Tls 0.1 102859 AM

MR 1.4 28-12-2022  
10:28:59 AM



WYVONA MR VALDY 4488  
20 006 DR135 F48 P90 Frg Cam - 18.0cm

Quipus Ultrasound Lab  
CA17A / Abdomen / FR 20Hz Tls 0.1 102859 AM

MR 1.4 28-12-2022  
10:28:59 AM



WYVONA MR VALDY 4488  
20 006 DR135 F48 P90 Frg Cam - 18.0cm

Quipus Ultrasound Lab  
CA17A / Abdomen / FR 20Hz Tls 0.1 102844 AM

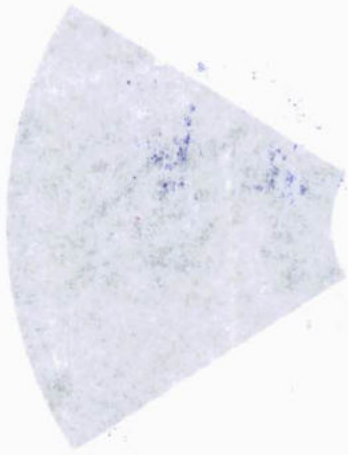
MR 1.4 28-12-2022  
10:28:44 AM



01 0.34 cm

Regard Agent huusacatu

2022-05-11 11:30  
Matti Huusacatu  
Matti Huusacatu  
Matti Huusacatu



2022-05-11 11:30  
Matti Huusacatu  
Matti Huusacatu  
Matti Huusacatu



2022-05-11 11:30  
Matti Huusacatu  
Matti Huusacatu  
Matti Huusacatu

2022-05-11 11:30  
Matti Huusacatu  
Matti Huusacatu  
Matti Huusacatu



2022-05-11 11:30  
Matti Huusacatu  
Matti Huusacatu  
Matti Huusacatu

2022-05-11 11:30  
Matti Huusacatu  
Matti Huusacatu  
Matti Huusacatu



2022-05-11 11:30  
Matti Huusacatu  
Matti Huusacatu  
Matti Huusacatu

2022-05-11 11:30  
Matti Huusacatu  
Matti Huusacatu  
Matti Huusacatu



2022-05-11 11:30  
Matti Huusacatu  
Matti Huusacatu  
Matti Huusacatu

2022-05-11 11:30  
Matti Huusacatu  
Matti Huusacatu  
Matti Huusacatu



2022-05-11 11:30  
Matti Huusacatu  
Matti Huusacatu  
Matti Huusacatu

2022-05-11 11:30  
Matti Huusacatu  
Matti Huusacatu  
Matti Huusacatu




2022-05-11 11:30  
Matti Huusacatu  
Matti Huusacatu  
Matti Huusacatu

2022-05-11 11:30  
Matti Huusacatu  
Matti Huusacatu  
Matti Huusacatu



2022-05-11 11:30  
Matti Huusacatu  
Matti Huusacatu  
Matti Huusacatu

2022-05-11 11:30  
Matti Huusacatu  
Matti Huusacatu  
Matti Huusacatu



2022-05-11 11:30  
Matti Huusacatu  
Matti Huusacatu  
Matti Huusacatu





# OnePLUS Ultrasound Lab

QUALITY FIRST... ALWAYS!

**Dr. Nitin Agarwal**

Pathologist & Director  
Ex. Sr. Res. MAMC  
& Lok Nayak Hospital  
Ex. Chief of Lab Dr. Lal Path Labs.

**Dr. Pooja (Garg) Agarwal**

Radiologist & Director  
MAMC & Lok Nayak Hospital



NAME	:Mr. VIJAY KUMAR	Barcode No	:10134630
AGE/GENDER	:44 YRS/Male	SPECIMEN DATE	:29/Dec/2022 08:03AM
PATIENT ID	:106954	SPECIMEN RECEIVED	:29/Dec/2022 08:14AM
REFERRED BY	:Dr. MEDIWHEEL	REPORT DATE	:29/Dec/2022 11:13AM
CENTRE NAME	:ONEPLUS ULTRASOUND LAB	LAB NO.	:012212290003

Test Name	Result	Unit	Ref. Range
-----------	--------	------	------------

## HAEMATOLOGY

### Health checkup 2 Male

<b>Glycosylated Hemoglobin (HbA1c)</b>	5.6	%	Non Diabetic adults <5.7 Prediabetic (at risk) 5.7-6.4 Diabetes >6.4
--	-----	---	--

<b>Estimated average blood glucose (eag)</b>	114
--	-----

Reference range (mg/dl):

90 - 120:Excellent control, 121 - 150:Good Control, 151 - 180:Average Control, 181 - 210:Action Suggested

>211:Panic value

<b>BLOOD GROUP (ABO)</b>	B
<b>Rh typing</b>	POSITIVE

### NOTE :

- \* Apart from major A,B,H antigens which are used for ABO grouping and Rh typing, many minor blood group antigens exist. Agglutination may also vary according to titre of antigen and antibody.
- \* So before transfusion, reconfirmation of blood group as well as cross-matching is needed.
- \* Presence of maternal antibodies in newborns, may interfere with blood grouping.
- \* Auto agglutination (due to cold antibody, falciparum malaria, sepsis, internal malignancy etc.) may also cause erroneous result.

## CBC

Haemoglobin	14.0	g/dl	13.0-17.0
Total Leucocyte Count	8500	/cumm	4000-10000
<b>Differential leucocyte count</b>			
Neutrophils	70.1	%	40-80
Lymphocyte	22.90	%	20-40
Monocytes	4.00	%	2-10
Eosinophils	2.2	%	1-6
Basophils	0.8	%	0-2
RBC Count	4.40	million/cumm	4.5 - 5.5

Checked By.

DR. NITIN AGARWAL  
DR. NITIN AGARWAL (In)  
MBBS, MD (DIPLOMA)  
DMB, FC (PATHOLOGIST)

47, Harsh Vihar, Pitampura, New Delhi-110034 | Ph.: 011-42480101, 9599913051

E-mail: oneplusul@gmail.com | Web.: www.oneplusul.in

Page 1 of 5

Clinical correlation is essential for final diagnosis. \* If test results are unsatisfactory please contact personally or on phone. \* This report is for perusal of doctors only. \* All disputes Subject to Delhi Jurisdiction only. \* Not for medicolegal purposes. \* All congenital anomalies in a foetus may not be diagnosed in routine obstetric ultrasound.





# OnePLUS

## Ultrasound Lab

QUALITY FIRST... ALWAYS!

**Dr. Nitin Agarwal**  
Pathologist & Director  
Ex. Sr. Res. MAMC  
& Lok Nayak Hospital  
Ex. Chief of Lab Dr. Lal Path Labs.

**Dr. Pooja (Garg) Agarwal**  
Radiologist & Director  
MAMC & Lok Nayak Hospital



NAME	:Mr. VIJAY KUMAR	Barcode No	:10134630
AGE/GENDER	:44 YRS/Male	SPECIMEN DATE	:29/Dec/2022 08:03AM
PATIENT ID	:106954	SPECIMEN RECEIVED	:29/Dec/2022 08:14AM
REFERRED BY	:Dr. MEDIWHEEL	REPORT DATE	:29/Dec/2022 11:13AM
CENTRE NAME	:ONEPLUS ULTRASOUND LAB	LAB NO.	:012212290003

Test Name	Result	Unit	Ref. Range
PCV(Hematocrit)	44.7	%	40-50
MCV	<b>102.5</b>	fL	83-101
MCH	32.0	Pg	27-32
MCHC	<b>31.2</b>	G/dL	32-35
Platelet count	301000	/cumm	150000-450000
RDW-CV	12.6	%	11.4-14.0
ESR(WESTEGRENs METHOD)	10	mm in 1st hr	0-20

### BIOCHEMISTRY

<b>Blood sugar fasting</b>	111	mg/dL	70-110
<b>Bun (blood urea nitrogen )</b>	12.30	mg/dl	8.9-21.6
<b>Uric acid, serum</b>	4.3	mg/dl	3.5-7.2
<b>Creatinine, serum</b>	0.7	mg/dl	0.60-1.2

### LFT(LIVER FUNCTION TEST)

Bilirubin Total	0.65	mg/dl	0.1-1.2
Bilirubin Conjugated	0.23	mg/dl	0-0.4
Bilirubin Unconjugated	0.42	mg/dl	up to 0.7
SGOT (AST)	31	U/L	0-46
SGPT (ALT)	38	U/L	0-49
Alkaline phosphatase	95	U/L	40-129
Gamma glutamyl transpeptidase	26	U/L	10-45
Total Protein	6.8	gm/dl	6.60 - 8.70
Albumin serum	3.8	g/dL	3.0-5.2
Globulin	3.00	gm/dl	1.8-3.4
Albumin/Globulin Ratio	1.27		1.10 - 2.50

### LIPID PROFILE

Cholesterol	219	mg/dl	50-200
Triglycerides	157	mg/dL	25-150
HDL Cholesterol	45	mg/dL	40 - 60

Checked By.

**Dr. NITIN AGARWAL**  
DR. NITIN AGARWAL  
MBBS, MD (PATHOLOGIST)

47, Harsh Vihar, Pitampura, New Delhi-110034 | Ph.: 011-42480101, 9599913051

E-mail: [oneplusul@gmail.com](mailto:oneplusul@gmail.com) | Web.: [www.oneplusul.in](http://www.oneplusul.in)

Page 2 of 5

Clinical correlation is essential for final diagnosis. • If test results are unsatisfactory please contact personally or on phone. • This report is for perusal of doctors only.  
• All disputes Subject to Delhi Jurisdiction only. • Not for medicolegal purposes. • All congenital anomalies in a foetus may not be diagnosed in routine obstetric ultrasound.





# OnePLUS Ultrasound Lab

— QUALITY FIRST... ALWAYS! —

**Dr. Nitin Agarwal**

Pathologist & Director  
Ex. Sr. Res. MAMC  
& Lok Nayak Hospital  
Ex. Chief of Lab Dr. Lal Path Labs.

**Dr. Pooja (Garg) Agarwal**

Radiologist & Director  
MAMC & Lok Nayak Hospital



NAME	:Mr. VIJAY KUMAR	Barcode No	:10134630
AGE/GENDER	:44 YRS/Male	SPECIMEN DATE	:29/Dec/2022 08:03AM
PATIENT ID	:106954	SPECIMEN RECEIVED	:29/Dec/2022 08:14AM
REFERRED BY	:Dr. MEDIWHEEL	REPORT DATE	:29/Dec/2022 11:13AM
CENTRE NAME	:ONEPLUS ULTRASOUND LAB	LAB NO.	:012212290003

Test Name	Result	Unit	Ref. Range
LDL cholesterol	143	mg/dL	<130
VLDL cholesterol	31.4	mg/dL	5-40
Cholesterol/HDL Ratio	4.9		Low Risk 3.3-4.97 Average Risk 4.4-7.1 Moderate Risk 7.1-11.0 High Risk >11.0
LDL/HDL Ratio	3.2		0 - 3.55

According to ATP III and NCEP guidelines

Parameter	Normal	Desirable	Borderline	High
Total cholesterol	<200		200-239	240
Triglycerides	<150	150-199	200-499	500
LDL	Optimal <100 Near Optimal 100-129	130-159	160-180	190
HDL	<40 : LOW 60 : HIGH			

## ENDOCRINOLOGY

### PSA TOTAL

Prostatic specific antigen, Total 1.97 ng/ml <4.0

< 40 years	0.21 to 1.72 ng/ml
40 - 49	0.27 to 2.19 ng/ml
50 - 59	0.27 to 3.42 ng/ml
60 - 69	0.22 to 6.16 ng/ml
> 69	0.21 to 6.77 ng/ml

### Notes:

PSA is principally produced by the glandular epithelium of the prostate, and is secreted in the seminal fluid. PSA is also present in

Checked By.

Dr. Nitin Agarwal  
MAMC & Lok Nayak Hospital  
MBBS, MD, PATHOLOGIST

47, Harsh Vihar, Pitampura, New Delhi-110034 | Ph.: 011-42480101, 9599913051

E-mail: [oneplusul@gmail.com](mailto:oneplusul@gmail.com) | Web.: [www.oneplusul.in](http://www.oneplusul.in)

Page 3 of 5

Clinical correlation is essential for final diagnosis. • If test results are unsatisfactory please contact personally or on phone. • This report is for perusal of doctors only. • All disputes Subject to Delhi Jurisdiction only. • Not for medicolegal purposes. • All congenital anomalies in a foetus may not be diagnosed in routine obstetric ultrasound.





**OnePLUS**  
Ultrasound Lab

QUALITY FIRST... ALWAYS!

**Dr. Nitin Agarwal**

Pathologist & Director  
Ex. Sr. Res. MAMC  
& Lok Nayak Hospital  
Ex. Chief of Lab Dr. Lal Path Labs.

**Dr. Pooja (Garg) Agarwal**

Radiologist & Director  
MAMC & Lok Nayak Hospital



NAME	:Mr. VIJAY KUMAR	Barcode No	:10134630
AGE/GENDER	:44 YRS/Male	SPECIMEN DATE	:29/Dec/2022 08:03AM
PATIENT ID	:106954	SPECIMEN RECEIVED	:29/Dec/2022 08:14AM
REFERRED BY	:Dr. MEDIWHEEL	REPORT DATE	:29/Dec/2022 11:13AM
CENTRE NAME	:ONEPLUS ULTRASOUND LAB	LAB NO.	:012212290003

Test Name	Result	Unit	Ref. Range
-----------	--------	------	------------

urine and blood. PSA acts on seminal fluid to fluidify and increase sperm mobility. PSA levels rise in prostatic pathologies such as benign prostatic hyperplasia (BPH) or prostate cancer.

#### THYROID PROFILE(T3,T4,TSH)

Triiodothyronine total [t3]	0.84	ng/dl	0.52-1.9
Thyroxine total [t4]	7.60	µg/dl	4.4 - 10.8
TSH (Thyroid Stimulating Hormone)	5.10	µIU/ml	0.25-5.0

#### AGE WISE VARIATION IN TSH

AGE	TSH(µIU/ml)	AGE	TSH(µIU/ml)
1-4 weeks	1.00 - 19.0	16-20 yrs	0.25 - 5.0
1-12 mths	1.70 - 9.1	21 - 80 yrs	0.25 - 5.0
1-5 yrs	0.80 - 8.2	I <sup>st</sup> trimester	0.25 - 5.0
6-10 yrs	0.25 - 5.0	II <sup>nd</sup> trimester	0.50 - 5.0
11-15 yrs	0.25 - 5.0	II <sup>rd</sup> trimester	0.4 - 6.0

#### Reference ranges - Interpretation of Diagnostic tests - (Jacques Wallach)

1. Primary hypothyroidism is accompanied by depressed serum T3 and T4 values and elevated serum TSH level.
2. Primary hyperthyroidism is accompanied by elevated serum T3 and T4 levels along with depressed TSH values.
3. Slightly elevated T3 levels may be found in pregnancy and estrogen therapy, while depressed levels may be encountered in severe illness, renal failure and during therapy with drugs like propranolol and propyl thiouracil.
4. Although elevated TSH levels are nearly always indicative of primary hypothyroidism, and may be seen in secondary thyrotoxicosis

#### CLINICAL PATHOLOGY

##### URINE ROUTINE

##### Physical examination

Quantity	20	ML
Colour	PALE YELLOW	
Transparency	CLEAR	CLEAR
Sp.gravity	1.015	1.010-1.030
pH	6.00	
Reaction	ACIDIC	ACIDIC

Checked By.

Dr. NITIN AGARWAL  
MRBC, MD (Path)  
DMC/R/01436  
MBBS, MD (PATHOLOGIST)

47, Harsh Vihar, Pitampura, New Delhi-110034 | Ph.: 011-42480101, 9599913051

E-mail: [oneplusul@gmail.com](mailto:oneplusul@gmail.com) | Web.: [www.oneplusul.in](http://www.oneplusul.in)

Page 4 of 5

Clinical correlation is essential for final diagnosis. \* If test results are unsatisfactory please contact personally or on phone. \* This report is for perusal of doctors only. \* All disputes Subject to Delhi Jurisdiction only. \* Not for medicolegal purposes. \* All congenital anomalies in a foetus may not be diagnosed in routine obstetric ultrasound.



# OnePLUS Ultrasound Lab

— QUALITY FIRST... ALWAYS! —

**Dr. Nitin Agarwal**

Pathologist & Director  
Ex. Sr. Res. MAMC  
& Lok Nayak Hospital  
Ex. Chief of Lab Dr. Lal Path Labs.

**Dr. Pooja (Garg) Agarwal**

Radiologist & Director  
MAMC & Lok Nayak Hospital




NAME	:Mr. VIJAY KUMAR	Barcode No	:10134630
AGE/GENDER	:44 YRS/Male	SPECIMEN DATE	:29/Dec/2022 08:03AM
PATIENT ID	:106954	SPECIMEN RECEIVED	:29/Dec/2022 08:14AM
REFERRED BY	:Dr. MEDIWHEEL	REPORT DATE	:29/Dec/2022 11:13AM
CENTRE NAME	:ONEPLUS ULTRASOUND LAB	LAB NO.	:012212290003

Test Name	Result	Unit	Ref. Range
<b><u>Chemical examination</u></b>			
Urine protein	NIL		NIL
Urine sugar	NIL		NIL
Bilirubin, urine	NEGATIVE		NEGATIVE
Urobilinogen	NORMAL		NORMAL
Ketones	NEGATIVE		NEGATIVE
<b><u>Microscopic examination</u></b>			
<b>Pus cells.</b>	1-2	/HPF	0-2
Epithelial cells	1-2	/HPF	NIL
R.B.C.	NIL	/HPF	NIL
Casts	NIL	/HPF	NIL
Crystals	NIL	/HPF	NIL
Bacteria	NIL	/HPF	NIL
Others.	NIL	NIL	NIL

\*\*\* End Of Report \*\*\*

Checked By.

  
DR. NITIN AGARWAL  
MBBS, MD (PATHOLOGIST)

47, Harsh Vihar, Pitampura, New Delhi-110034 | Ph.: 011-42480101, 9599913051

E-mail: [oneplusul@gmail.com](mailto:oneplusul@gmail.com) | Web.: [www.oneplusul.in](http://www.oneplusul.in)

Page 5 of 5

Clinical correlation is essential for final diagnosis. • If test results are unsatisfactory please contact personally or on phone. • This report is for perusal of doctors only.  
• All disputes Subject to Delhi Jurisdiction only. • Not for medicolegal purposes. • All congenital anomalies in a foetus may not be diagnosed in routine obstetric ultrasound.







# OnePLUS Ultrasound Lab

QUALITY FIRST... ALWAYS!

**Dr. Nitin Agarwal**

Pathologist & Director  
Ex. Sr. Res. MAMC  
& Lok Nayak Hospital  
Ex. Chief of Lab Dr. Lal Path Labs.

**Dr. Pooja (Garg) Agarwal**

Radiologist & Director  
MAMC & Lok Nayak Hospital



NAME	:Mr. VIJAY KUMAR	Barcode No	:10134630
AGE/GENDER	:44 YRS/Male	SPECIMEN DATE	:29/Dec/2022 08:03AM
PATIENT ID	:106954	SPECIMEN RECEIVED	:29/Dec/2022 08:14AM
REFERRED BY	:Dr. MEDIWHEEL	REPORT DATE	:29/Dec/2022 03:26PM
CENTRE NAME	:ONEPLUS ULTRASOUND LAB	LAB NO.	:012212290003

Test Name	Result	Unit	Ref. Range
-----------	--------	------	------------

### BIOCHEMISTRY

#### Health checkup 2 Male

<u>Blood sugar pp</u>	167	mg/dL	70.0-140.0
-----------------------	-----	-------	------------

\*\*\* End Of Report \*\*\*

Checked By.

**DR. NITIN AGARWAL**  
MBBS, MD (PATHOLOGY)  
DMCRA, DRCRA

47, Harsh Vihar, Pitampura, New Delhi-110034 | Ph.: 011-42480101, 9599913051

E-mail: [oneplusul@gmail.com](mailto:oneplusul@gmail.com) | Web.: [www.oneplusul.in](http://www.oneplusul.in)

Page 1 of 1

Clinical correlation is essential for final diagnosis. • If test results are unsatisfactory please contact personally or on phone. • This report is for perusal of doctors only.  
• All disputes Subject to Delhi Jurisdiction only. • Not for medicolegal purposes. • All congenital anomalies in a foetus may not be diagnosed in routine obstetric ultrasound.





**OnePLUS**  
Ultrasound Lab  
— QUALITY FIRST... ALWAYS! —

**Dr. Nitin Agarwal**  
Pathologist & Director  
Ex. Sr. Res. MAMC  
& Lok Nayak Hospital  
Ex. Chief of Lab Dr. Lal Path Labs.

**Dr. Pooja (Garg) Agarwal**  
Radiologist & Director  
MAMC & Lok Nayak Hospital



NAME	:Mr. VIJAY KUMAR	Barcode No	:10134630
AGE/GENDER	:44 YRS/Male	SPECIMEN DATE	:29/Dec/2022 08:03AM
PATIENT ID	:106954	SPECIMEN RECEIVED	:29/Dec/2022 08:14AM
REFERRED BY	:Dr. MEDIWHEEL	REPORT DATE	:29/Dec/2022 03:34PM
CENTRE NAME	:ONEPLUS ULTRASOUND LAB	LAB NO.	:012212290003

Test Name	Result	Unit	Ref. Range
-----------	--------	------	------------

**CLINICAL PATHOLOGY**

**Health checkup 2 Male**

**STOOL ROUTINE**

**Physical examination**

Colour	BROWNISH		
Consistency	SEMI LOOSE		Semi Formed
Blood	ABSENT		Absent
Mucus	ABSENT		Absent

**Chemical examination, stool**

pH	7.50		
----	------	--	--

**Microscopic examination**

Pus cells	0-1	/HPF	
R.B.C.	NIL	/HPF	NIL
Ova	NIL		NIL
Cysts	NIL		NIL
Bacteria	PRESENT	/HPF	NIL
Others	NIL		

\*\*\* End Of Report \*\*\*

Checked By.

Dr NITIN AGARWAL  
MBBS, MD (Path)  
DMC/R/01436

DR. NITIN AGARWAL  
MBBS, MD (PATHOLOGIST)

47, Harsh Vihar, Pitampura, New Delhi-110034 | Ph.: 011-42480101, 9599913051

E-mail: oneplusul@gmail.com | Web.: www.oneplusul.in

Page 1 of 1

Clinical correlation is essential for final diagnosis. • If test results are unsatisfactory please contact personally or on phone. • This report is for perusal of doctors only. • All disputes Subject to Delhi Jurisdiction only. • Not for medicolegal purposes. • All congenital anomalies in a foetus may not be diagnosed in routine obstetric ultrasound.