


**भारत सरकार**  
**भारत**


**AADHAAR**

**पता:**  
 S/O हरफूल चंद अग्रवाल, आई-११, परवना विहार, प्लॉट  
 न-५२, सेक्टर-९, रोहिणी, नॉर्थ वेस्ट, दिल्ली  
 दिल्ली - 110085

**Address :**  
 S/O Harphool Chand Aggarwal,  
 I-11, Parvana Vihar, Plot No-52, Sector-9,  
 Rohini, North West Delhi,  
 Delhi - 110085



**5331 0457 7229**


 1947 | 
  [help@uidai.gov.in](mailto:help@uidai.gov.in) | 
  [www.uidai.gov.in](http://www.uidai.gov.in)

*Handwritten signature*

*Handwritten signature: Nitesh Aggarwal*

**Dr. NITESH AGGARWAL**  
 MBBS, MD  
 Regn. No. [unclear] [unclear]

**ONEPLUS ULTRASOUND LAB**  
 47, Marsh Vihar, Pitam Pura  
 Delhi-110034  
 Ph. 011-47000901, 47000905  
 E-mail: [oneplusultrasound@gmail.com](mailto:oneplusultrasound@gmail.com)


**भारत सरकार**



**आधार**



निलेश अग्रवाल  
 Nitesh Aggarwal  
 जन्म तिथि/DOB: 20/07/1987  
 पुरुष/ MALE  
 Mobile No: 9811337511

**5331 0457 7229**

मेरा आधार, मेरी पहचान



11

**Dr. NITIN KUMAR**  
MBBS, MD  
Regn. No. 123456


**ONEPLUS ULTRASOUND LAB**  
47, Harsh Vihar, Pitaha Pura,  
CC-3,  
Ph. 011-262212051  
E-mail: dr.nitin@oneplus.com



*[Handwritten signature]*

Dr. NITIN AGARWAL  
MBBS, MD  
Regn. No. 14136

ONEPLUS ULTRASOUND LAB  
47, Harsh Vihar, Pitam Pura,  
Delhi - 110034  
Ph. 011-43511959  
E-mail: [oneplusultrasound.com](mailto:oneplusultrasound.com)



# ONEPLUS ULTRASOUND LAB

SUPINE  
PRETEST

ST @ 10mm/mV  
80ms PostU

Mr. NILESH AGGARWAL  
I.D. : 980  
AGE/SEX : 34/M  
RECORDED : 14-8-2021 9:54

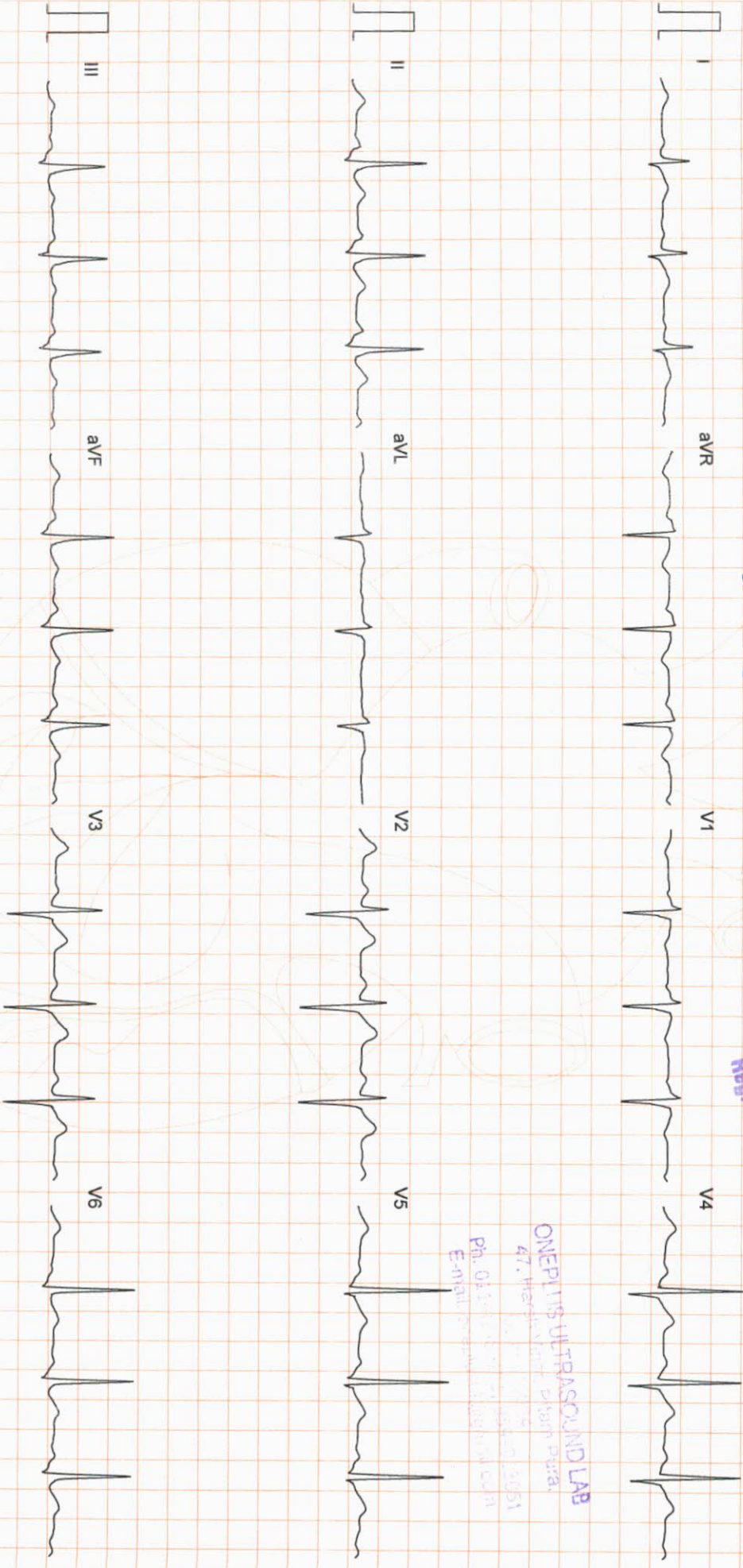
RATE : 95 BPM  
B.P. : 134/86 mmHg

RAW E.C.G.

*Sullivan*  
*Aggarwal*

*P.K. Gupta*  
DR. P.K. GUPTA  
MBBS, MD  
REG. No-1071

ONEPLUS ULTRASOUND LAB  
47, Huda Road, Okhla Phase II, New Delhi-110025  
Ph. 011-26101111, 26101112, 26101113  
E-mail: [oneplusultrasound@gmail.com](mailto:oneplusultrasound@gmail.com)



Filtered Computer Corrected Baseline

25mm/sec 10mm/mV

CardCom, INDIA Ph..091-731-2620740, TeleFax:091-731-2431214



# ONEPLUS ULTRASOUND LAB

47, HARSH VIHAR PITAMPURA DELHI 110034

Mr. NILESH AGGARWAL  
 Age/Sex : 34/M  
 Ref by : MEDIWHEEL  
 Indication1 :  
 Indication2 :  
 Indication3 :

ID : 980  
 H/Wt : 174/86  
 Recorded : 14- 8-2021 9:54

TREADMILL TEST SUMMARY REPORT  
 Protocol: BRUCE  
 History:  
 Medication1 :  
 Medication2 :  
 Medication3 :

PHASE	PHASE TIME	STAGE TIME	SPEED (Km./Hr.)	GRADE (%)	H.R. (BPM)	B.P. (mmHg)	RPP X100	II	ST LEVEL (mm) V2	V5	METS
SUPINE											
STANDING											
STAGE 1	2:59	2:59	2.70	10.00	105	134/86	127	0.7	1.8	0.7	4.80
STAGE 2	5:59	2:59	4.00	12.00	118	134/86	128	1.1	2.2	1.0	7.10
STAGE 3	8:59	2:59	5.40	14.00	133	146/88	153	0.9	2.6	1.5	10.00
STAGE 4	10:29	1:29	6.70	16.00	165	156/90	184	0.7	2.7	1.6	11.99
PEAK EXER	10:31	1:31			166	166/92	293	0.3	4.0	1.3	
RECOVERY	2:59	2:59	0.00	0.00	109	178/96	295	0.2	4.0	1.3	12.03
						136/88	148	0.3	2.1	0.7	

**RESULTS**  
 Exercise Duration : 10:31 Minutes  
 Max Heart Rate : 166 bpm 89 % of target heart rate 186 bpm  
 Max Blood Pressure : 178/96 mmHg  
 Max Work Load : 12.03 METS  
 Reason of Termination :  
 IMPRESSIONS : *Negative for ischemic change*

*[Signature]*  
 Cardiologist  
**Dr. P.K. GUPTA**  
 MBBS, MD  
 Reg. No:11071

*[Signature]*  
**Dr. Nishu Aggarwal**

ONEPLUS ULTRASOUND LAB  
 47, Harsh Vihar Pitampura,  
 Delhi 110034  
 Ph: 011-2620740, 9559613051  
 E-mail: onepuslab@gmail.com

# ONEPLUS ULTRASOUND LAB

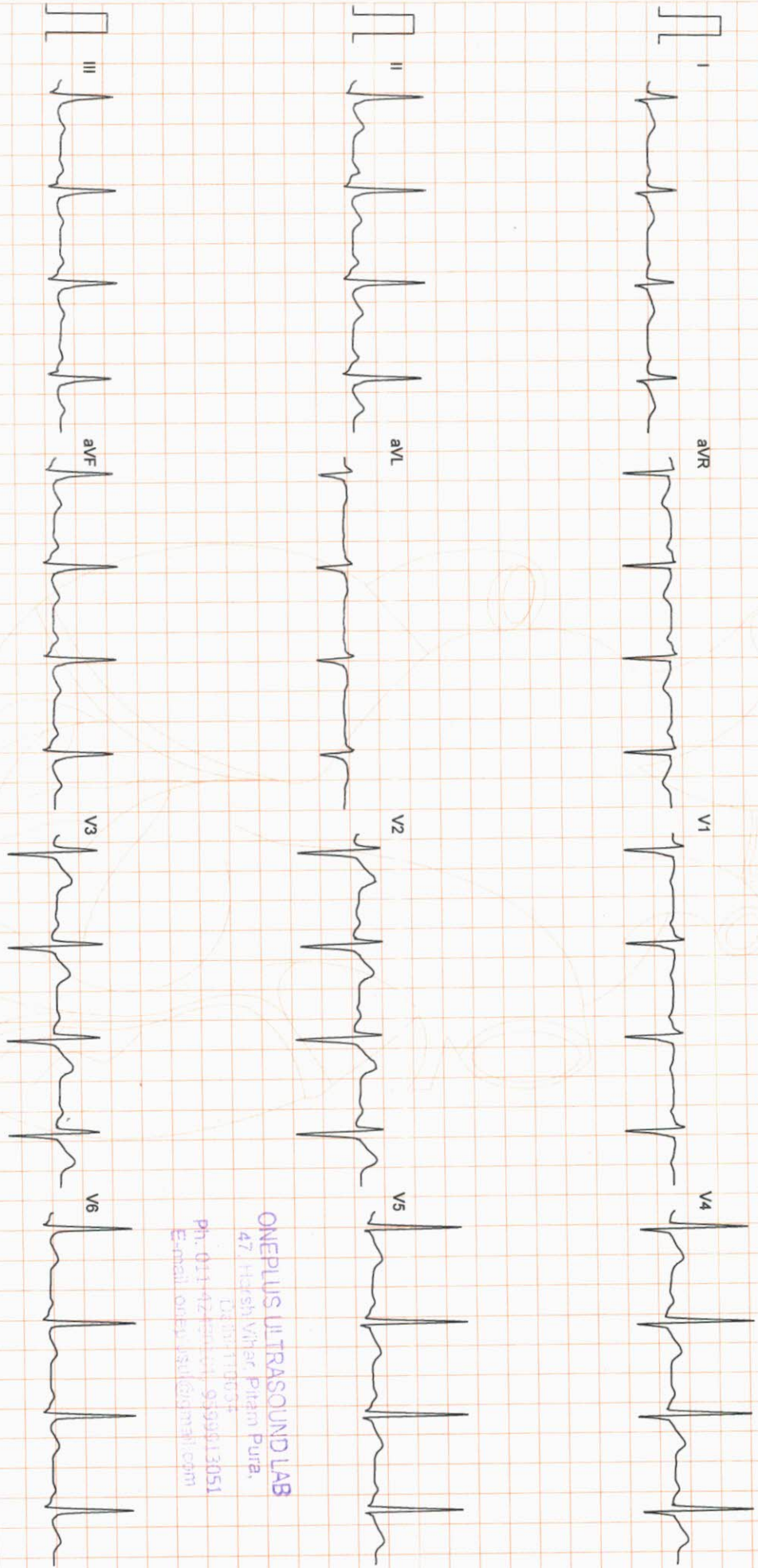
SUPINE  
PRETEST

ST @ 10mm/mV  
80ms PostU

Mr. NILESH AGGARWAL  
I.D. : 980  
AGE/SEX : 34/M  
RECORDED : 14-8-2021 9:54

RATE : 95 BPM  
B.P. : 134/86 mmHg

RAW E.C.G.



ONEPLUS ULTRASOUND LAB  
47, Hitesh Vihar, Pitam Pura,  
Gurgaon, Haryana  
Ph. 011-42191141, 9199813051  
Email: oneplusultrasound@gmail.com

Filtered 25mm/sec 10mm/mV

ARRV

CardiCom, INDIA Ph.:091-731-2620740, TeleFax:091-731-2431214

# ONEPLUS ULTRASOUND LAB

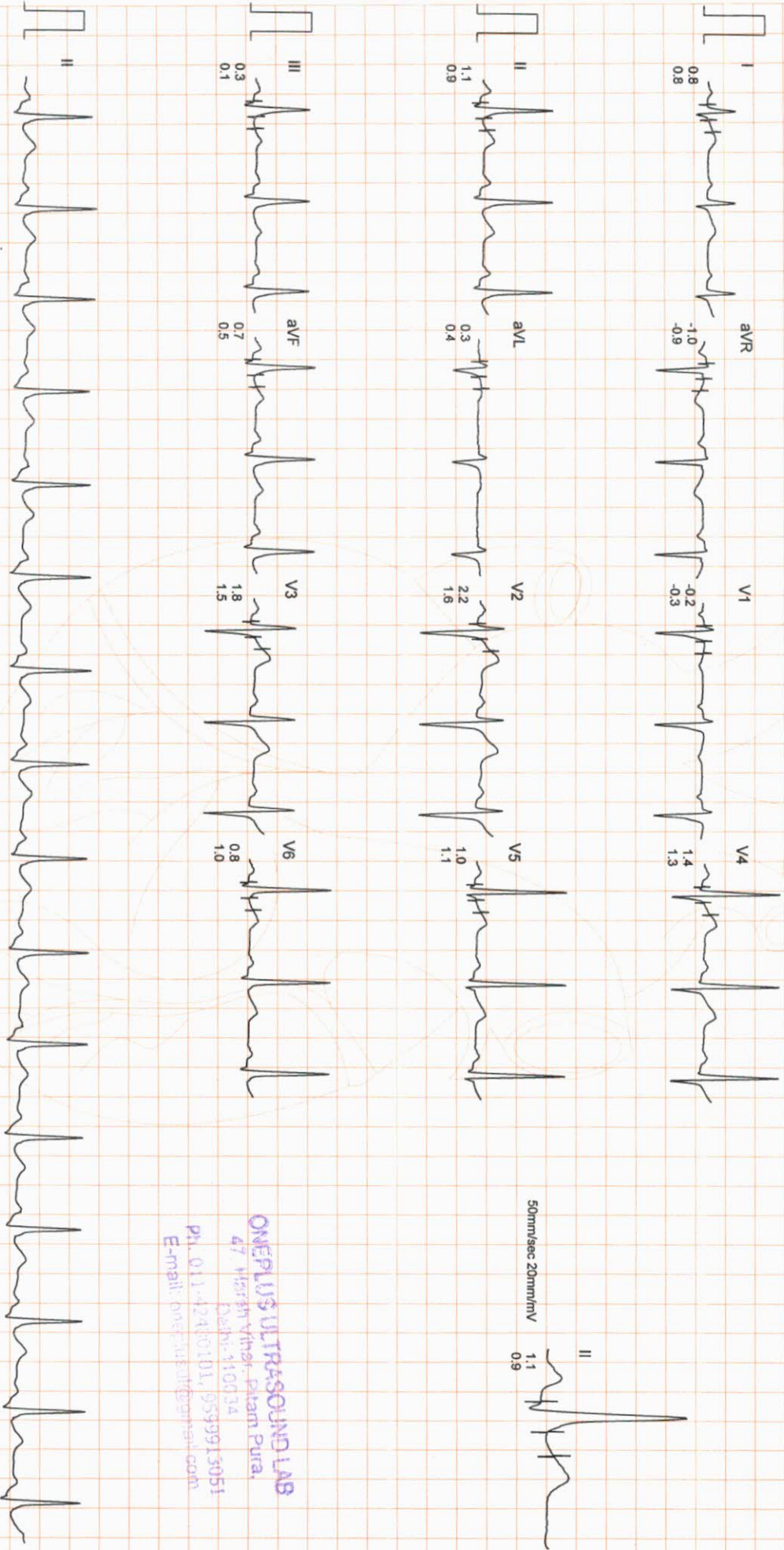
STANDING  
PRETEST

ST @ 10mm/mV  
80ms PostJ

Mr. NILESH AGGARWAL  
I.D. : 980  
AGE/SEX : 34/M  
RECORDED : 14-8-2021 9:54

RATE : 96 BPM  
B.P. : 134/86 mmHg

LINKED MEDIAN



**ONEPLUS ULTRASOUND LAB**  
47, Hiranagar Vihar, Pham Pura,  
Delhi-110034  
Ph. 011-42410101, 9599913051  
E-mail: onepplusul@gmail.com

# ONEPLUS ULTRASOUND LAB

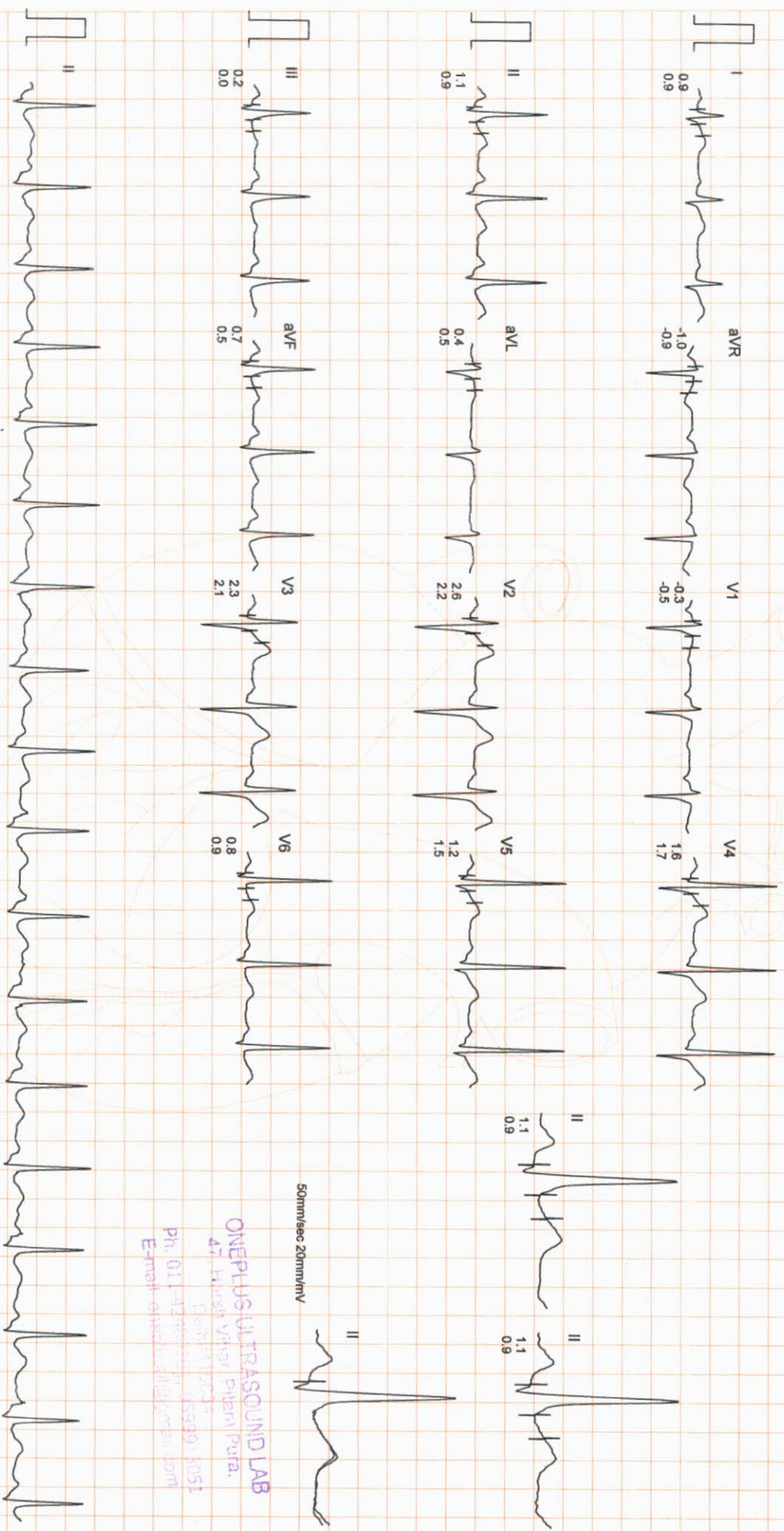
Mr. NILESH AGGARWAL  
 I.D. : 980  
 AGE/SEX : 34/M  
 RECORDED : 14-8-2021 9:54

RATE : 105 BPM  
 B.P. : 146/88 mmHg

BRUCE  
 EXERCISE 1  
 PHASE TIME : 2:59  
 STAGE TIME : 2:59

ST @ 10mm/mV  
 80ms PostJ  
 SPEED : 2.7 Km./Hr.  
 GRADE : 10.0 %

LINKED MEDIAN



Filtered Computer Corrected Baseline 25mm/sec 10mm/mV CardCom, INDIA Ph.:091-731-2620740,TeleFax:091-731-2431214

50mm/sec 20mm/mV  
**ONEPLUS ULTRASOUND LAB**  
 47, Harek Vihar, Extnal Purfa.  
 Ph. 011-42201101, 42201105  
 Email: onestudio@oneplus.com



# ONEPLUS ULTRASOUND LAB

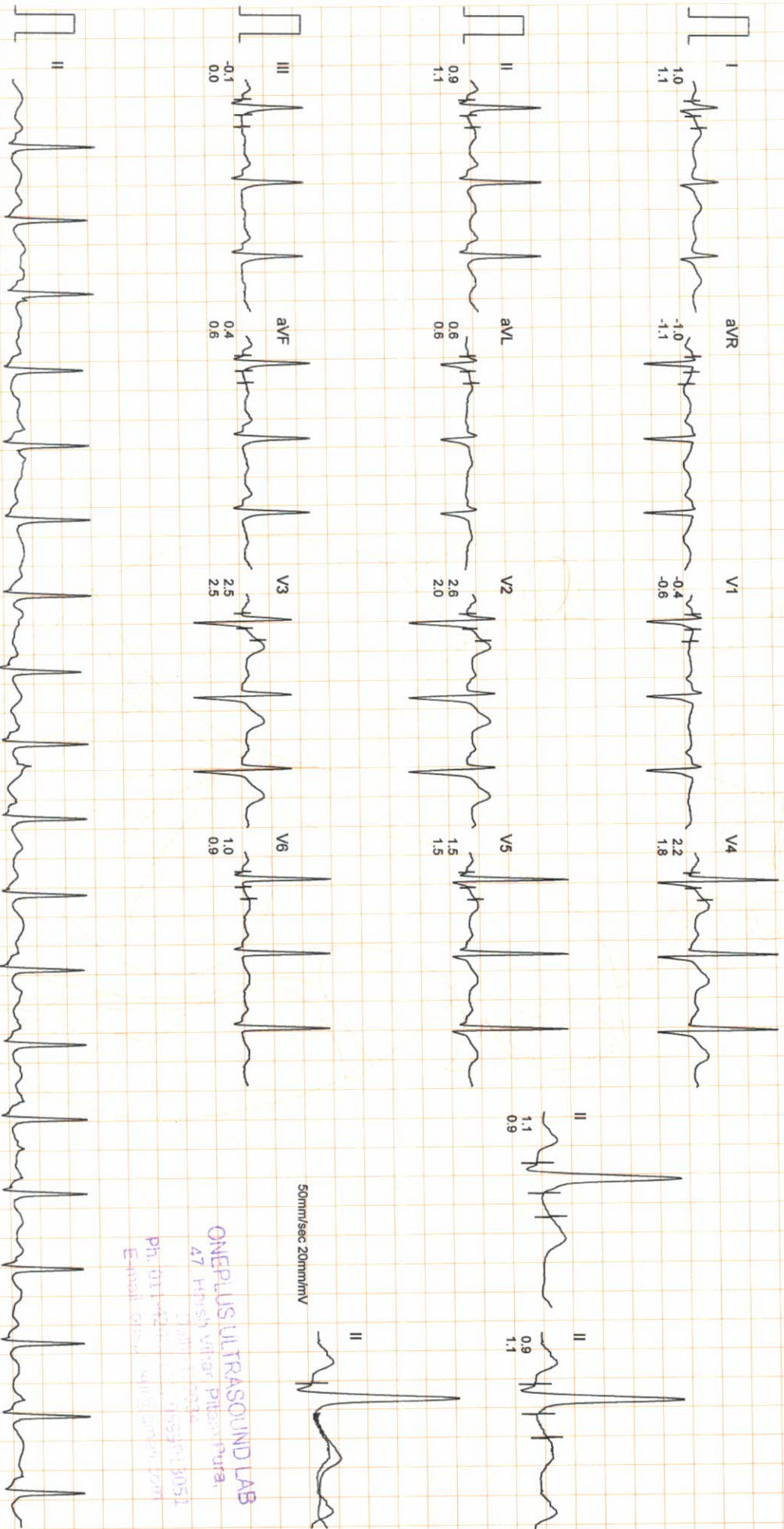
Mr. NILESH AGGARWAL  
I.D. : 980  
AGE/SEX : 34/M  
RECORDED : 14-8-2021 9:54

RATE : 118 BPM  
B.P. : 156/90 mmHg

BRUCE  
EXERCISE 2  
PHASE TIME : 5:59  
STAGE TIME : 2:59

ST @ 10mm/mV  
80ms PostJ  
SPEED : 4.0 Km./Hr.  
GRADE : 12.0 %

LINKED MEDIAN



50mm/sec 20mm/mV

ONEPLUS ULTRASOUND LAB  
47 Hrishikesh Vihar PUNE, India  
Ph: 011-2620740, 2620740, 2620740  
E-mail: oneplus@oneplus.com

Filtered

Computer Corrected Baseline

25mm/sec 10mm/mV

AVG

CardiCom, INDIA Ph.:091-731-2620740, TeleFax:091-731-2431214

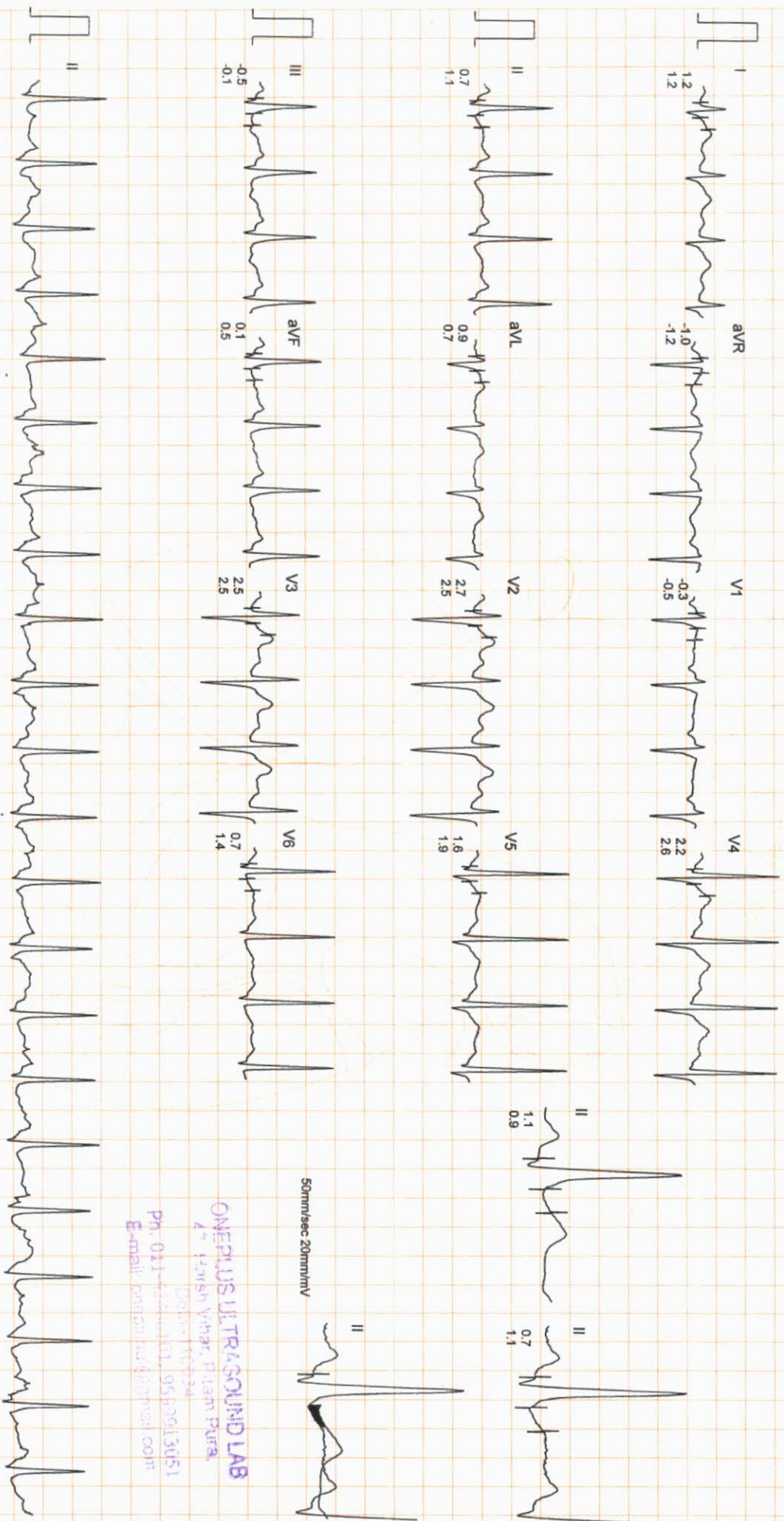
# ONEPLUS ULTRASOUND LAB

**Mr. NILESH AGGARWAL**  
 I.D. : 980  
 AGE/SEX : 34/M  
 RECORDED : 14-8-2021 9:54  
 RATE : 133 BPM  
 B.P. : 166/92 mmHg

**BRUCE**  
 EXERCISE 3  
 PHASE TIME : 8:59  
 STAGE TIME : 2:59

ST @ 10mm/mV  
 80ms PostJ  
 SPEED : 5.4 Km./Hr.  
 GRADE : 14.0 %

LINKED MEDIAN



**ONEPLUS ULTRASOUND LAB**  
 45, Kashi Vihar, Pusa, Patna  
 Distt: Patna  
 Ph: 011-4244101, 9589913051  
 E-mail: onepusul@ymail.com

# ONEPLUS ULTRASOUND LAB

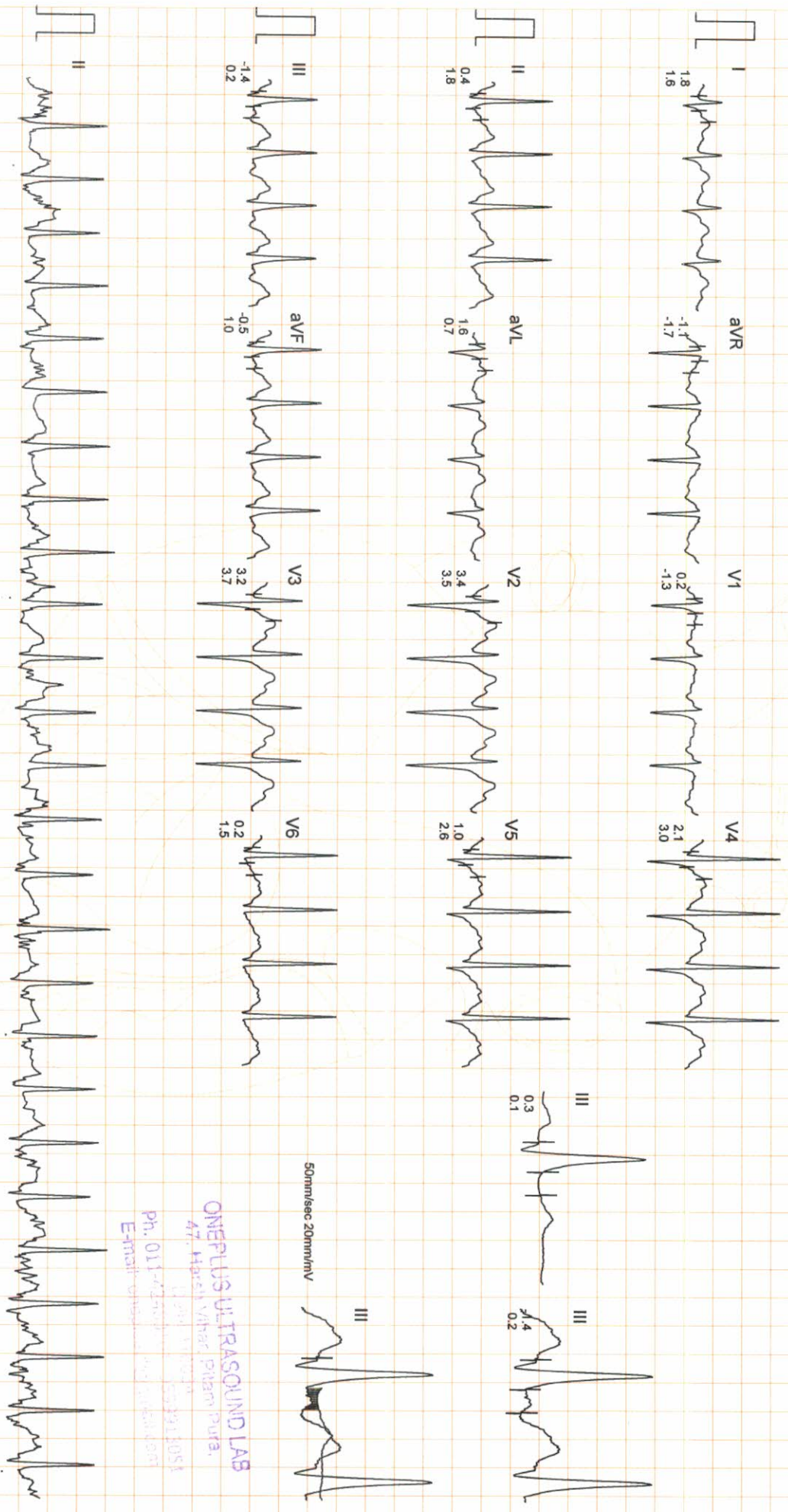
Mr. NILESH AGGARWAL  
 I.D. : 980  
 AGE/SEX : 34/M  
 RECORDED : 14-8-2021 9:54

RATE : 161 BPM  
 B.P. : 178/96 mmHg

BRUCE  
 EXERCISE 4  
 PHASE TIME : 10:14  
 STAGE TIME : 1:14

ST @ 10mm/mV  
 80ms PostJ  
 SPEED : 6.7 Km./Hr.  
 GRADE : 16.0 %

LINKED MEDIAN



ONEPLUS ULTRASOUND LAB  
 47, Mohan Vihar, Pitam Pura,  
 Delhi 110051  
 Ph. 011-43500000, 43500007  
 E-mail: onep@oneplusultrasound.com

# ONEPLUS ULTRASOUND LAB

Mr. NILESH AGGARWAL

I.D. : 980

AGE/SEX : 34/M

RECORDED : 14-8-2021 9:54

RATE : 166 BPM

B.P. : 178/96 mmHg

BRUCE

PEAK EXER

PHASE TIME : 10:31

STAGE TIME : 1:31

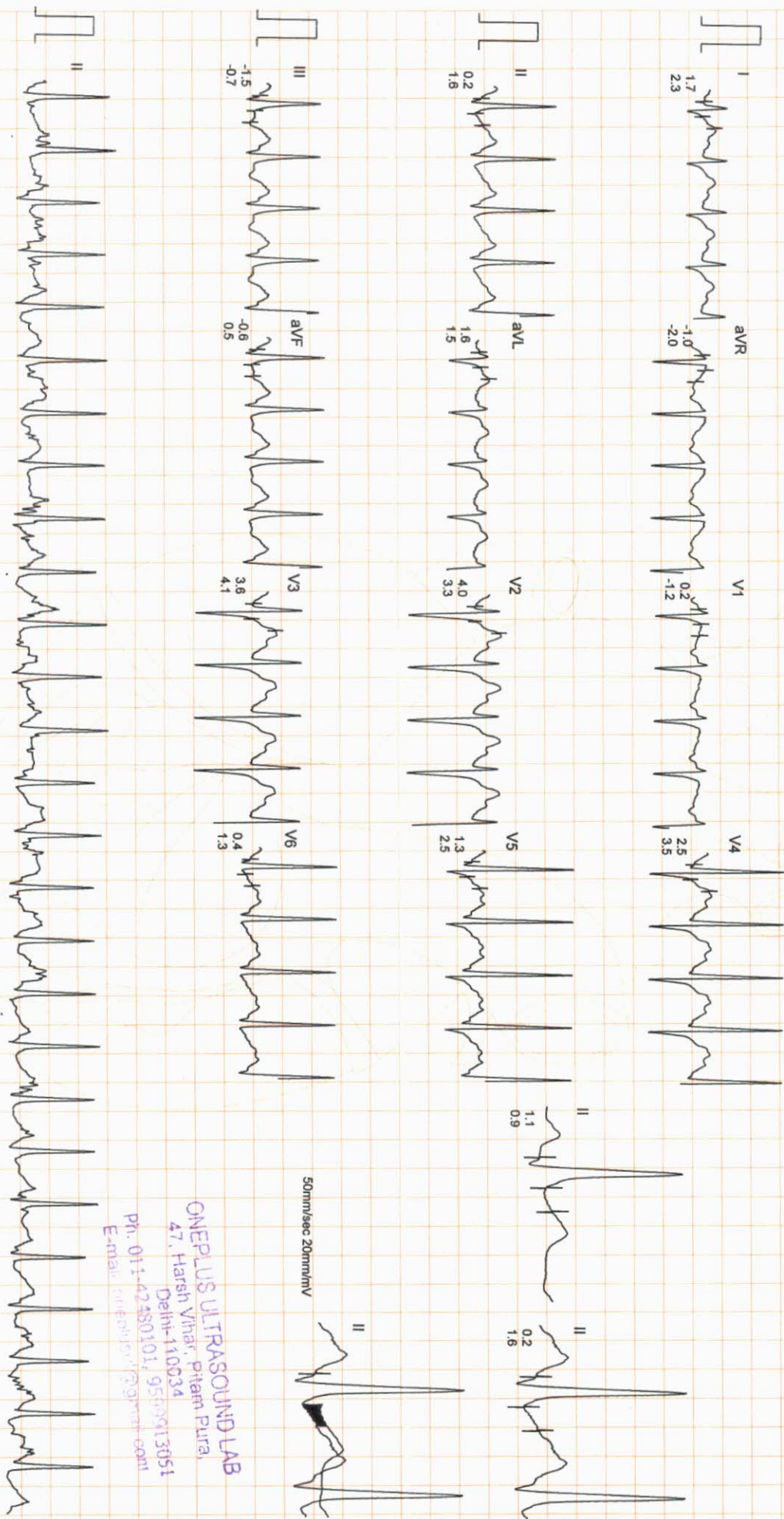
ST @ 10mm/mv

80ms PostJ

SPEED : 6.7 Km./Hr.

GRADE : 16.0 %

LINKED MEDIAN



ONEPLUS ULTRASOUND LAB  
47, Harsh Vihar, Pitam Pur,  
Delhi-110034  
Ph: 011-42480101, 9509913051  
E-mail: info@oneplusultrasound.com

Filtered

Computer Corrected Baseline

25mm/sec 10mm/mV

ANALOG

CardiCom, INDIA Ph.:091-731-2620740, TeleFax:091-731-2431214

# ONEPLUS ULTRASOUND LAB

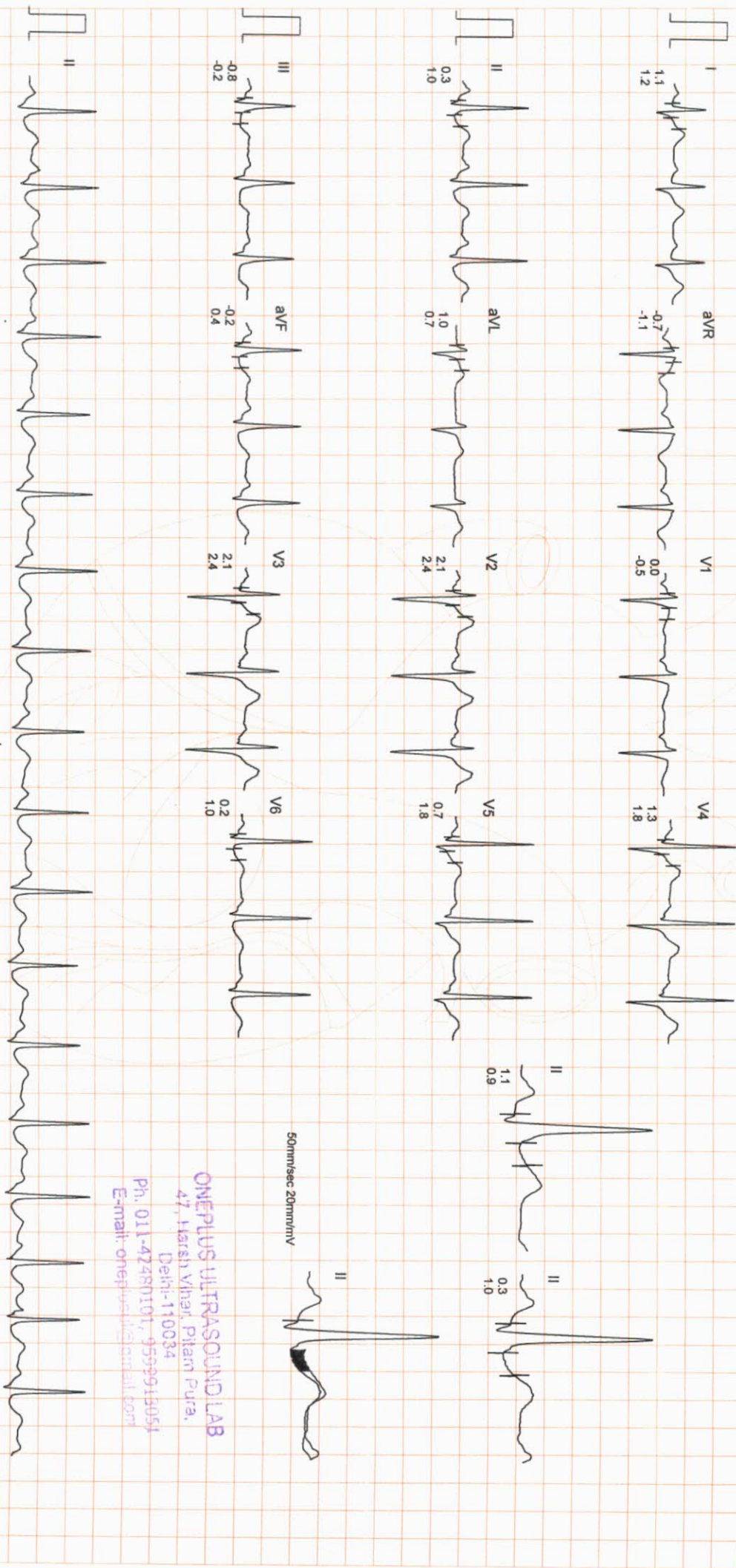
Mr. NILESH AGGARWAL  
 I.D. : 980  
 AGE/SEX : 34/M  
 RECORDED : 14-8-2021 9:54

RATE : 109 BPM  
 B.P. : 136/88 mmHg

BRUCE  
 RECOVERY  
 PHASE TIME : 2:59

ST @ 10mm/mV  
 80ms PostJ  
 SPEED : 0.0 Km./Hr.  
 GRADE : 0.0 %

LINKED MEDIAN



ONEPLUS ULTRASOUND LAB  
 47, Harsh Vihar, Pitam Pura,  
 Delhi-110034  
 Ph: 011-42481101, 9599915051  
 E-mail: oneplusul@outlook.com

50mm/sec 20mm/mV

Filtered

Computer Corrected Baseline

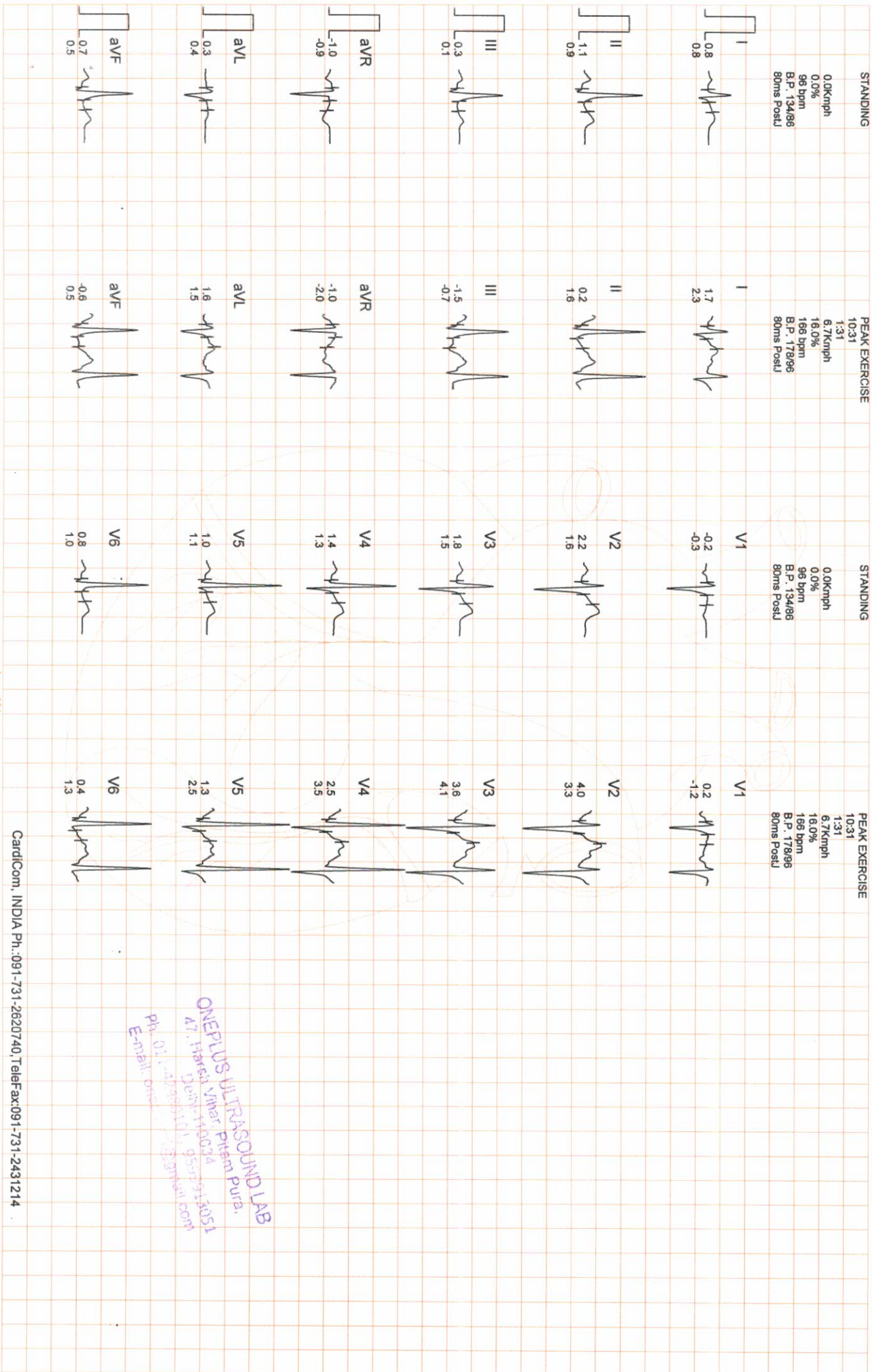
25mm/sec 10mm/mV

ASIA

CardiCom, INDIA Ph.:091-731-2620740, TeleFax:091-731-2431214



ONEPLUS ULTRASOUND LAB  
 47, Marsh Vihar, Patna Pura,  
 Delhi-110034  
 Ph. 011-42733010, 9590918051  
 E-mail: oneplusultrasound@gmail.com



ONEPLUS ULTRASOUND LAB  
 A7, Harcoi Vihar, Pitam Pura,  
 Delhi-110034  
 Phone: 011-47091101, 9507913051  
 Email: oncl@oneplusultrasound.com



**OnePLUS**  
Ultrasound Lab  
— QUALITY FIRST... ALWAYS! —

**Dr. Nitin Agarwal**

Pathologist & Director  
Ex. Sr. Res. MAMC  
& Lok Nayak Hospital  
Ex. Chief of Lab Dr. Lal Path Labs.

**Dr. Pooja (Garg) Agarwal**


Radiologist & Director  
MAMC & Lok Nayak Hospital

Name	: Mr. NILESH AGGARWAL	Age/Sex	: 34 YRS/Male
Ref. By	: Dr. MEDIWHEEL	Lab No	: 012108140009
Date	: 14-Aug-2021	Patient ID	: LSHHI82637

## X-ray-Chest PA view

Bony cage and soft tissues are normal.  
Cardiothoracic ratio is normal.  
Mediastinum is normal.  
Both hila are normal.  
Both costophrenic angles are clear.  
Both domes of diaphragm are normal.  
Lung fields are clear. No parenchymal lesion seen.

**IMPRESSION: Normal Study.**

  
DR. POOJA GARG  
RADIOLOGIST  
REG NO- DMC/R/03398

Dr. POOJA GARG  
M.B.B.S., D.M.R.D.  
Reg No. DMC/R/03398  
Radiologist

Type By : pooja

47, Harsh Vihar, Pitampura, New Delhi-110034 | Ph.: 011-42480101, 9599913051  
E-mail: oneplusul@gmail.com | Web.: www.oneplusul.in

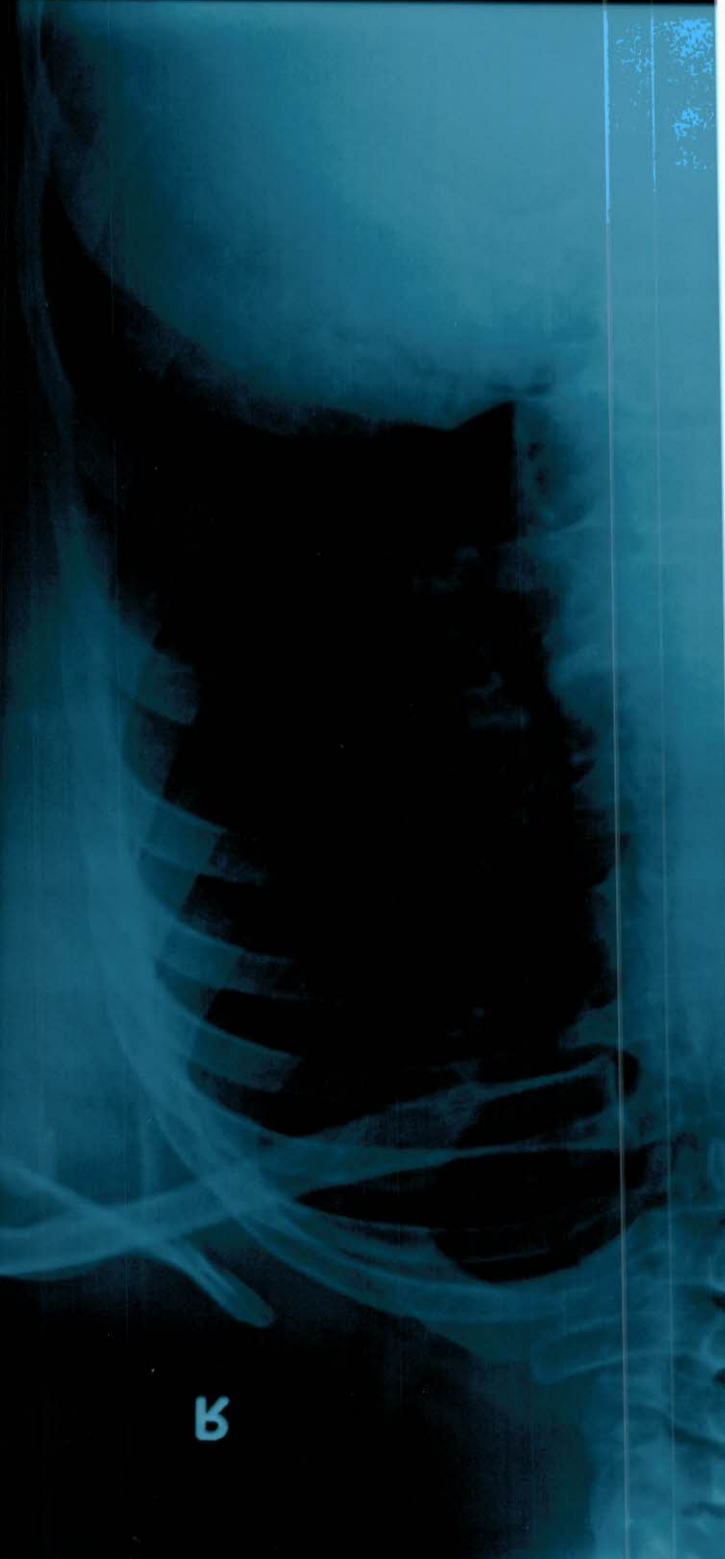

R

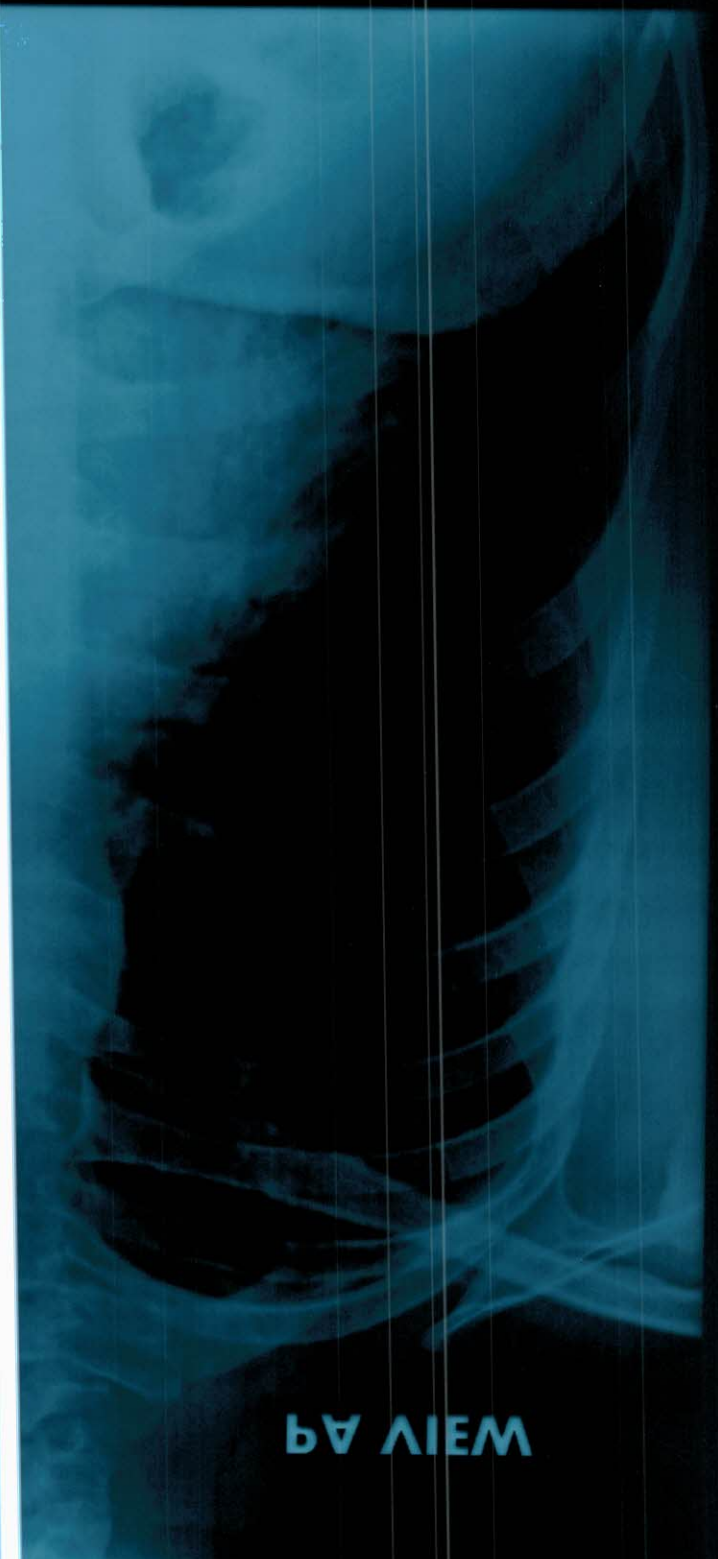
PA VIEW

MR NILESH AGGARWAL AGE 34 YRS 14-8-2021 M CHEST PA  
ONEPLUS ULTRASOUND LAB,47-HARSH VIHAR,PITAMPURA

ОИЕБГУС ПГТРАСОИИД ГАВ, 4-НАР2Н ВНАР, РИТАМЬУРА  
МР ИГЕ2Н АССАРМАГ АСЕ 34 29 14-8-5051 M CHEST PA



B



PA VIEW



**OnePLUS**  
Ultrasound Lab  
— QUALITY FIRST... ALWAYS! —

**Dr. Nitin Agarwal**  
Pathologist & Director  
Ex. Sr. Res. MAMC  
& Lok Nayak Hospital  
Ex. Chief of Lab Dr. Lal Path Labs.

**Dr. Pooja (Garg) Agarwal**  
Radiologist & Director  
MAMC & Lok Nayak Hospital

Name	: Mr. NILESH AGGARWAL	Age/Sex	: 34 YRS/Male
Ref. By	: Dr. MEDIWHEEL	Lab No	: 012108140009
Date	: 14-Aug-2021	Patient ID	: LSHHI82637

**ULTRASOUND EXAMINATION----WHOLE ABDOMEN**

**Liver** is normal in size (15.5 cm) and normal in outline with **altered echopattern. Diffuse increase in echogenicity of liver parenchyma is noted, suggestive of fatty infiltration (grade I).** Intrahepatic biliary radicles are not dilated. No abscess or mass lesion seen. Hepatic veins, portal vein, IVC and aorta are normal. CBD is normal in caliber.

**Gall bladder** is well distended with anechoic lumen. Wall thickness is normal.

**Both kidneys** are normal in size, shape, position, outline and echopattern. Corticomedullary differentiation is maintained. No pelvicalyceal dilation or mass lesion is seen.

**Spleen** is normal in size and echotexture. No mass lesion seen.

**Pancreas** is normal in size, outline and echotexture.

**Urinary bladder** is normal in shape and position. No evidence of intravesical stone or mass seen.

**Prostate** is normal in size, shape and echopattern.


**Prostate measures** 2.9 x 2.9 x 3.1 cm. **Weight of prostate is 13 grams.**

No abnormal bowel wall thickening seen in right iliac fossa.

No free fluid seen anywhere in abdomen.

**IMPRESSION:**

- **Fatty infiltration of liver (grade I) with no hepatomegaly.**

  
**DR. POOJA GARG**  
RADIOLOGIST  
REG NO- DMC/R/03398

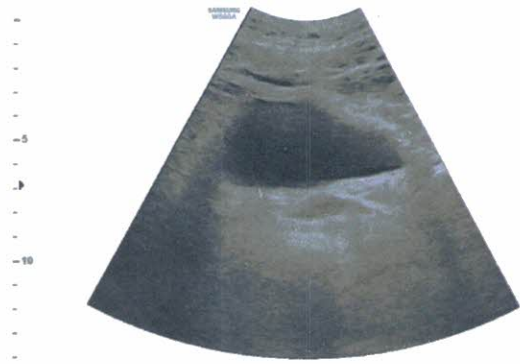
**Dr. POOJA GARG**  
M.B.B.S., D.M.R.D.  
Reg No. DMC/R/03398  
Radiologist

Type By : pooja

47, Harsh Vihar, Pitampura, New Delhi-110034 | Ph.: 011-42480101, 9599913051  
E-mail: oneplusul@gmail.com | Web.: www.oneplusul.in

WS00A MR NILESH 34/M OnePlus Ultrasound Lab MI 1.5 14-08-2021  
CA1-7A / Abdomen / FR 27Hz Tib0.1 11:17:34 AM

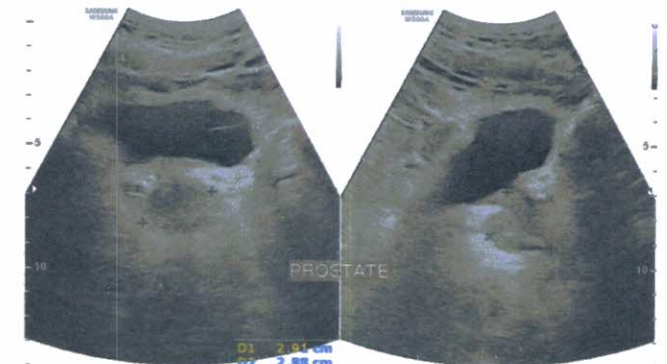20 G51 DR130 FA11 P100 Frq Pen. 14.0cm



WS00A MR NILESH 34/M OnePlus Ultrasound Lab MI 1.5 14-08-2021  
CA1-7A / Abdomen / FR 27Hz Tib0.1 11:17:52 AM

20 G51 DR130 FA11 P100 Frq Pen. 14.0cm

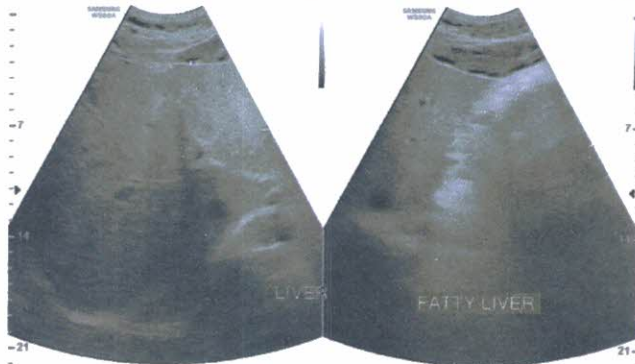20 G51 DR130 FA11 P100 Frq Pen. 14.0cm



WS00A MR NILESH 34/M OnePlus Ultrasound Lab MI 1.5 14-08-2021  
CA1-7A / Abdomen / FR 19Hz Tib0.2 11:18:11 AM

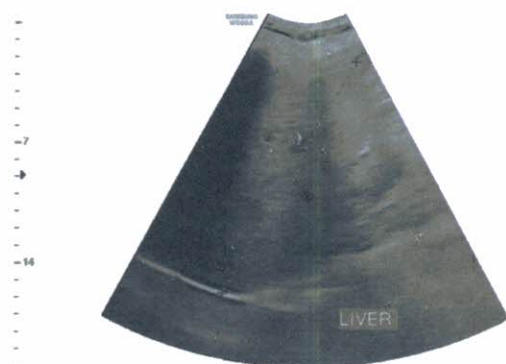
20 G55 DR130 FA11 P100 Frq Pen. 22.0cm

20 G55 DR130 FA11 P100 Frq Pen. 22.0cm



WS00A MR NILESH 34/M OnePlus Ultrasound Lab MI 1.5 14-08-2021  
CA1-7A / Abdomen / FR 20Hz Tib0.1 11:18:23 AM

20 G55 DR130 FA11 P100 Frq Pen. 20.0cm

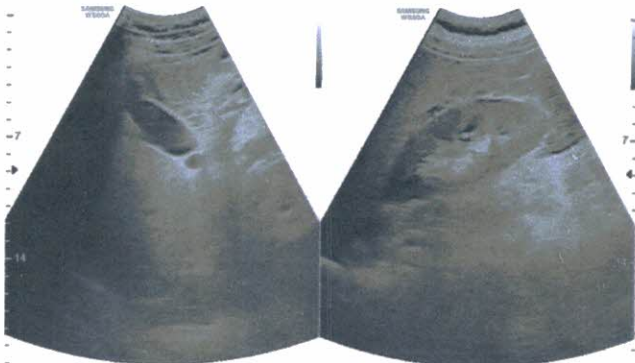

D1 15.52 cm

WS00A MR NILESH 34/M OnePlus Ultrasound Lab MI 1.5 14-08-2021  
CA1-7A / Abdomen / FR 29Hz Tib0.1 11:18:48 AM

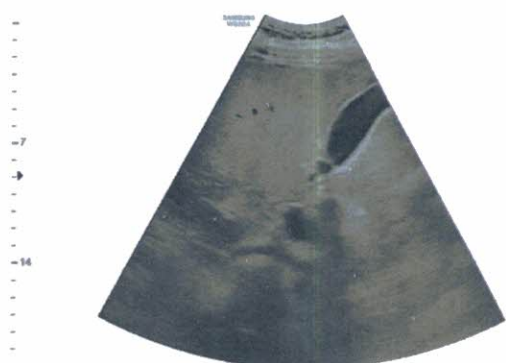
20 G51 DR130 FA11 P100 Frq Pen. 20.0cm

20 G51 DR130 FA11 P100 Frq Pen. 20.0cm



WS00A MR NILESH 34/M OnePlus Ultrasound Lab MI 1.5 14-08-2021  
CA1-7A / Abdomen / FR 20Hz Tib0.1 11:19:02 AM

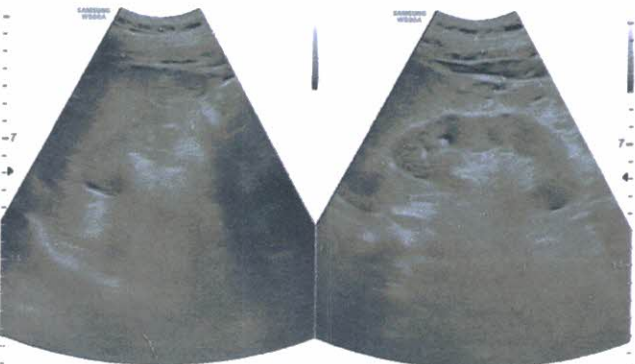
20 G51 DR130 FA11 P100 Frq Pen. 20.0cm



WS00A MR NILESH 34/M OnePlus Ultrasound Lab MI 1.5 14-08-2021  
CA1-7A / Abdomen / FR 20Hz Tib0.1 11:19:16 AM

20 G51 DR130 FA11 P100 Frq Pen. 20.0cm

20 G51 DR130 FA11 P100 Frq Pen. 20.0cm



WS00A MR NILESH 34/M OnePlus Ultrasound Lab MI 1.5 14-08-2021  
CA1-7A / Abdomen / FR 20Hz Tib0.1 11:19:30 AM

20 G51 DR130 FA11 P100 Frq Pen. 20.0cm

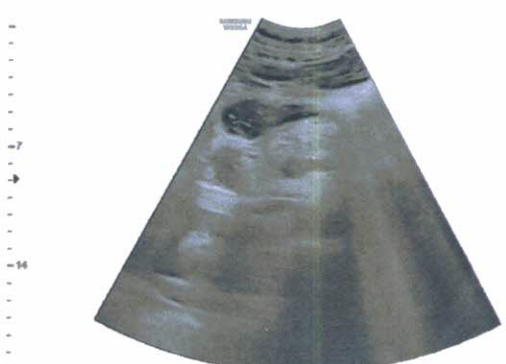




Figure 1. Micrographs of the surface of the sample after 10 minutes of etching.




Figure 2. Micrograph of the surface of the sample after 20 minutes of etching.




Figure 3. Micrographs of the surface of the sample after 30 minutes of etching.




Figure 4. Micrograph of the surface of the sample after 40 minutes of etching.




Figure 5. Micrographs of the surface of the sample after 50 minutes of etching.




Figure 6. Micrograph of the surface of the sample after 60 minutes of etching.




Figure 7. Micrograph of the surface of the sample after 70 minutes of etching.




Figure 8. Micrographs of the surface of the sample after 80 minutes of etching.



# OnePLUS Ultrasound Lab

— QUALITY FIRST... ALWAYS! —

**Dr. Nitin Agarwal**  
Pathologist & Director  
Ex. Sr. Res. MAMC  
& Lok Nayak Hospital  
Ex. Chief of Lab Dr. Lal Path Labs.

**Dr. Pooja (Garg) Agarwal**  
Radiologist & Director  
MAMC & Lok Nayak Hospital



NAME	:Mr. NILESH AGGARWAL	Barcode No	:10102240
AGE/GENDER	:34 YRS/Male	SPECIMEN DATE	:14/Aug/2021 09:41AM
PATIENT ID	:82637	SPECIMEN RECEIVED	:14/Aug/2021 09:44AM
REFERRED BY	:Dr. MEDIWHEEL	REPORT DATE	:14/Aug/2021 01:11PM
CENTRE NAME	:ONEPLUS ULTRASOUND LAB	LAB NO.	:012108140009

Test Name	Result	Unit	Ref. Range
-----------	--------	------	------------

## HAEMATOLOGY

### Health checkup 2 Male

<b>Glycosylated Hemoglobin (HbA1c)</b>	5.2	%	<6.0%
<b>Estimated average blood glucose (eag)</b>	103		

#### Reference range (mg/dl):

90 - 120:Excellent control, 121 - 150:Good Control, 151 - 180:Average Control, 181 - 210:Action Suggested

>211:Panic value

#### REMARKS:-

In vitro quantitative determination of **HbA1C** in whole blood is utilized in long term monitoring of glycemia. The **HbA1C** level correlates with the mean glucose concentration prevailing in the course of the patient's recent history (approx - 6-8 weeks) and therefore provides much more reliable information for glycemia monitoring than do determinations of blood glucose or urinary glucose. It is recommended that the determination of **HbA1C** be performed at intervals of 4-6 weeks during Diabetes Mellitus therapy. On testing of HbA1C by HPLC method the result shows high variant window (93.8%) & no value of HbA1C. Therefore for accurate assay of glycaemic Control Fructosamine assay & for variant analysis Hb electrophoresis should be done.

Assay done by : Bio-Rad : D-10 (HPLC)

<b>BLOOD GROUP (ABO)</b>	AB
<b>Rh typing</b>	POSITIVE

#### NOTE :

- \* Apart from major A,B,H antigens which are used for ABO grouping and Rh typing, many minor blood group antigens exist. Agglutination may also vary according to titre of antigen and antibody.
- \* So before transfusion, reconfirmation of blood group as well as cross-matching is needed.
- \* Presence of maternal antibodies in newborns, may interfere with blood grouping.
- \* Auto agglutination (due to cold antibody, falciparum malaria, sepsis, internal malignancy etc.) may also cause erroneous result.

## CBC

Haemoglobin	14.7	g/dl	13.0-17.0
Total Leucocyte Count	6640	/cumm	4000-10000

#### Differential leucocyte count

Checked By.

DR. NITIN AGARWAL  
MBBS,MD(PATHOLOGIST)

Dr. NITIN AGARWAL

MBBS, MD

Regn. No. DMC-K-1836

Page 1 of 5

47, Harsh Vihar, Pitampura, New Delhi-110034 | Ph.: 011-42480101, 9599913051

E-mail: onepusul@gmail.com | Web.: www.oneplusul.in



# OnePLUS Ultrasound Lab

— QUALITY FIRST... ALWAYS! —

**Dr. Nitin Agarwal**

Pathologist & Director  
Ex. Sr. Res. MAMC  
& Lok Nayak Hospital  
Ex. Chief of Lab Dr. Lal Path Labs.

**Dr. Pooja (Garg) Agarwal**

Radiologist & Director  
MAMC & Lok Nayak Hospital



NAME	:Mr. NILESH AGGARWAL	Barcode No	:10102240
AGE/GENDER	:34 YRS/Male	SPECIMEN DATE	:14/Aug/2021 09:41AM
PATIENT ID	:82637	SPECIMEN RECEIVED	:14/Aug/2021 09:44AM
REFERRED BY	:Dr. MEDIWHEEL	REPORT DATE	:14/Aug/2021 01:11PM
CENTRE NAME	:ONEPLUS ULTRASOUND LAB	LAB NO.	:012108140009

Test Name	Result	Unit	Ref. Range
Neutrophils	54.3	%	40-80
Lymphocyte	35.90	%	20-40
Monocytes	3.90	%	2-10
Eosinophils	5.5	%	1-6
Basophils	0.4	%	0-2
RBC Count	4.76	million/cumm	4.5 - 5.5
PCV(Hematocrit)	45.5	%	40-50
MCV	95.6	fL	83-101
MCH	30.9	Pg	27-32
MCHC	32.3	G/dL	32-35
Platelet count	327000	/cumm	150000-450000
RDW-CV	13.6	%	11.4-14.0
ESR(WESTEGRENs METHOD)	14	mm in 1st hr	0-20

### BIOCHEMISTRY

<b>Blood sugar fasting</b>	96	mg/dL	70-110
<b>Bun (blood urea nitrogen )</b>	14.20	mg/dl	8.9-21.6
<b>Uric acid, serum</b>	4.6	mg/dl	3.4-7.0
<b>Creatinine, serum</b>	0.96	mg/dl	0.60-1.1

### **LFT(LIVER FUNCTION TEST)**

Bilirubin Total	0.85	mg/dl	0.1-1.2
Bilirubin Conjugated	0.24	mg/dl	0-0.4
Bilirubin Unconjugated	0.61	mg/dl	up to 0.7
SGOT (AST)	<b>69</b>	U/L	0-35
SGPT (ALT)	<b>192</b>	U/L	<45.0
Alkaline phosphatase	102	U/L	40-129
Gamma glutamyl transpeptidase	26	U/L	11-61
Total Protein	6.9	gm/dl	6.40 - 8.20
Albumin	3.7	g/dL	3.5-5.5

Checked By.

DR. NITIN AGARWAL  
MBBS, MD(PATHOLOGIST)

Dr. NITIN AGARWAL  
MBBS, MD

Regn. No. DMC B-1436

47, Harsh Vihar, Pitampura, New Delhi-110034 | Ph.: 011-42480101, 9599913051

E-mail: [oneplusul@gmail.com](mailto:oneplusul@gmail.com) | Web.: [www.oneplusul.in](http://www.oneplusul.in)

Page 2 of 5



# OnePLUS

## Ultrasound Lab

— QUALITY FIRST... ALWAYS! —

**Dr. Nitin Agarwal**  
Pathologist & Director  
Ex. Sr. Res. MAMC  
& Lok Nayak Hospital  
Ex. Chief of Lab Dr. Lal Path Labs.

**Dr. Pooja (Garg) Agarwal**  
Radiologist & Director  
MAMC & Lok Nayak Hospital



NAME	:Mr. NILESH AGGARWAL	Barcode No	:10102240
AGE/GENDER	:34 YRS/Male	SPECIMEN DATE	:14/Aug/2021 09:41AM
PATIENT ID	:82637	SPECIMEN RECEIVED	:14/Aug/2021 09:44AM
REFERRED BY	:Dr. MEDIWHEEL	REPORT DATE	:14/Aug/2021 01:11PM
CENTRE NAME	:ONEPLUS ULTRASOUND LAB	LAB NO.	:012108140009

Test Name	Result	Unit	Ref. Range
Globulin	3.20	gm/dl	1.8-3.4
Albumin/Globulin Ratio	1.16		1.10 - 2.50
<b>LIPID PROFILE</b>			
Cholesterol	179	mg/dl	50-240
Triglycerides	89	mg/dL	25-150
HDL Cholesterol	45	mg/dL	30-70
LDL cholesterol	116	mg/dL	<130
VLDL cholesterol	17.8	mg/dL	5-40
Cholesterol/HDL Ratio	4.0		Low Risk 3.3-4.97 Average Risk 4.4-7.1 Moderate Risk 7.1-11.0 High Risk >11.0
LDL/HDL Ratio	2.6		0 - 3.55

According to ATP III and NCEP guidelines

Parameter	Normal	Desirable	Borderline	High
Total cholesterol	<200	200-239		240
Triglycerides	<150	150-199	200-499	500
LDL	Optimal <100 Near Optimal 100-129	130-159	160-180	190
HDL	<40 : LOW 60 : HIGH			

### ENDOCRINOLOGY

#### PSA TOTAL

Prostatic specific antigen, Total 0.52 ng/ml <4.0

< 40 years	0.21 to 1.72 ng/ml
40 - 49	0.27 to 2.19 ng/ml
50 - 59	0.27 to 3.42 ng/ml
60 - 69	0.22 to 6.16 ng/ml

Checked By.

DR. NITIN AGARWAL  
MBBS, MD (PATHOLOGIST)

Dr. NITIN AGARWAL  
MBBS, MD  
Regn. No. DMC-R-1436

47, Harsh Vihar, Pitampura, New Delhi-110034 | Ph.: 011-42480101, 9599913051

E-mail: oneplusul@gmail.com | Web.: www.oneplusul.in

Page 3 of 5





**OnePLUS**  
Ultrasound Lab  
— QUALITY FIRST... ALWAYS! —

**Dr. Nitin Agarwal**  
Pathologist & Director  
Ex. Sr. Res. MAMC  
& Lok Nayak Hospital  
Ex. Chief of Lab Dr. Lal Path Labs.

**Dr. Pooja (Garg) Agarwal**  
Radiologist & Director  
MAMC & Lok Nayak Hospital



NAME	:Mr. NILESH AGGARWAL	Barcode No	:10102240
AGE/GENDER	:34 YRS/Male	SPECIMEN DATE	:14/Aug/2021 09:41AM
PATIENT ID	:82637	SPECIMEN RECEIVED	:14/Aug/2021 09:44AM
REFERRED BY	:Dr. MEDIWHEEL	REPORT DATE	:14/Aug/2021 01:11PM
CENTRE NAME	:ONEPLUS ULTRASOUND LAB	LAB NO.	:012108140009

Test Name	Result	Unit	Ref. Range
> 69	0.21 to 6.77 ng/ml		

**Notes:**

PSA is principally produced by the glandular epithelium of the prostate, and is secreted in the seminal fluid. PSA is also present in urine and blood. PSA acts on seminal fluid to fluidify and increase sperm mobility. PSA levels rise in prostatic pathologies such as benign prostatic hyperplasia (BPH) or prostate cancer.

**THYROID PROFILE(T3,T4,TSH)**

Triiodothyronine total [t3]	0.72	ng/dl	0.52-1.9
Thyroxine total [t4]	6.50	µg/dl	4.4 - 10.8
TSH (Thyroid Stimulating Hormone)	1.60	µIU/ml	0.25-5.0

**AGE WISE VARIATION IN TSH**

AGE	TSH(µIU/ml)	AGE	TSH(µIU/ml)
1-4 weeks	1.00 - 19.0	16-20 yrs	0.25 - 5.0
1-12 mths	1.70 - 9.1	21 - 80 yrs	0.25 - 5.0
1-5 yrs	0.80 - 8.2	I <sup>st</sup> trimester	0.25 - 5.0
6-10 yrs	0.25 - 5.0	II <sup>nd</sup> trimester	0.50 - 5.0
11-15 yrs	0.25 - 5.0	II <sup>rd</sup> trimester	0.4 - 6.0

**Reference ranges - Interpretation of Diagnostic tests - (Jacques Wallach)**

1. Primary hypothyroidism is accompanied by depressed serum T3 and T4 values and elevated serum TSH level.
2. Primary hyperthyroidism is accompanied by elevated serum T3 and T4 levels along with depressed TSH values.
3. Slightly elevated T3 levels may be found in pregnancy and estrogen therapy, while depressed levels may be encountered in severe illness, renal failure and during therapy with drugs like propranolol and propyl thiouracil.
4. Although elevated TSH levels are nearly always indicative of primary hypothyroidism, and may be seen in secondary thyrotoxicosis

**CLINICAL PATHOLOGY**

**URINE ROUTINE**

**Physical examination**

Quantity 20 ML

Checked By.

DR. NITIN AGARWAL  
MBBS,MD(PATHOLOGIST)

Dr. NITIN AGARWAL  
MBBS, MD

47, Harsh Vihar, Pitampura, New Delhi-110034 | Ph.: 011-42480101, 9599918051

E-mail: [oneplusul@gmail.com](mailto:oneplusul@gmail.com) | Web.: [www.oneplusul.in](http://www.oneplusul.in)



# OnePLUS

## Ultrasound Lab

— QUALITY FIRST... ALWAYS! —

**Dr. Nitin Agarwal**  
Pathologist & Director  
Ex. Sr. Res. MAMC  
& Lok Nayak Hospital  
Ex. Chief of Lab Dr. Lal Path Labs.

**Dr. Pooja (Garg) Agarwal**  
Radiologist & Director  
MAMC & Lok Nayak Hospital



NAME	:Mr. NILESH AGGARWAL	Barcode No	:10102240
AGE/GENDER	:34 YRS/Male	SPECIMEN DATE	:14/Aug/2021 09:41AM
PATIENT ID	:82637	SPECIMEN RECEIVED	:14/Aug/2021 09:44AM
REFERRED BY	:Dr. MEDIWHEEL	REPORT DATE	:14/Aug/2021 01:11PM
CENTRE NAME	:ONEPLUS ULTRASOUND LAB	LAB NO.	:012108140009

Test Name	Result	Unit	Ref. Range
Colour	PALE YELLOW		
Transparency	CLEAR		CLEAR
Sp.gravity	1.015		1.010-1.030
pH	6.00		
Reaction	ACIDIC		ACIDIC
<b><u>Chemical examination</u></b>			
Urine protein	NIL		NIL
Urine sugar	NIL		NIL
Bilirubin, urine	NEGATIVE		NEGATIVE
Urobilinogen	NORMAL		NORMAL
Ketones	NEGATIVE		NEGATIVE
<b><u>Microscopic examination</u></b>			
<b>Pus cells.</b>	2-3	/HPF	0-2
Epithelial cells	0-1	/HPF	NIL
R.B.C.	NIL	/HPF	NIL
Casts	NIL	/HPF	NIL
Crystals	NIL	/HPF	NIL
Bacteria	NIL	/HPF	NIL
Others.	NIL	NIL	NIL

\*\*\* End Of Report \*\*\*

Checked By.

DR. NITIN AGARWAL  
MBBS, MD(PATHOLOGIST)

Dr. NITIN AGARWAL

MBBS, MD

Regn. No. DMC-R-1436

47, Harsh Vihar, Pitampura, New Delhi-110034 | Ph.: 011-42480101, 9599913051

E-mail: [oneplusul@gmail.com](mailto:oneplusul@gmail.com) | Web.: [www.oneplusul.in](http://www.oneplusul.in)

Page 5 of 5



# OnePLUS

## Ultrasound Lab

— QUALITY FIRST... ALWAYS! —

**Dr. Nitin Agarwal**  
Pathologist & Director  
Ex. Sr. Res. MAMC  
& Lok Nayak Hospital  
Ex. Chief of Lab Dr. Lal Path Labs.

**Dr. Pooja (Garg) Agarwal**  
Radiologist & Director  
MAMC & Lok Nayak Hospital



NAME	:Mr. NILESH AGGARWAL	Barcode No	:10102240
AGE/GENDER	:34 YRS/Male	SPECIMEN DATE	:14/Aug/2021 09:41AM
PATIENT ID	:82637	SPECIMEN RECEIVED	:14/Aug/2021 03:21PM
REFERRED BY	:Dr. MEDIWHEEL	REPORT DATE	:14/Aug/2021 04:23PM
CENTRE NAME	:ONEPLUS ULTRASOUND LAB	LAB NO.	:012108140009

Test Name	Result	Unit	Ref. Range
<b>BIOCHEMISTRY</b>			
<b>Health checkup 2 Male</b>			
<b>Blood sugar pp</b>	104	mg/dL	70.0-140.0

\*\*\* End Of Report \*\*\*

Checked By.

DR. NITIN AGARWAL  
MBBS,MD(PATHOLOGIST)

47, Harsh Vihar, Pitampura, New Delhi-110034 | Ph.: 011-42480101, 9599913051  
E-mail: [oneplusul@gmail.com](mailto:oneplusul@gmail.com) | Web.: [www.oneplusul.in](http://www.oneplusul.in)

Dr. NITIN AGARWAL  
MBBS, MD  
Regn. No. DMC-R-136