

MYSORE-BALLAL CIRCLE

MEDALL

--- A MEDALL COMPANY ---

Date 11-Jun-2022 7:49 AM

DOB : 20 Jul 1980

Age : 41Y/MALE

Visit ID : 712217616

Phone No : 9964986921

Customer Name : MR.P GIRISH S

Ref Dr Name : MediWheel

Customer Id : MED111148807

Email Id :

Corp Name : MediWheel

Address :

Package Name : Mediwheel Full Body Health Checkup Male Below 40

S.No	Modality	Study	Accession No	Time	Seq	Signature
1	LAB	LIPID PROFILE				
2	LAB	LIVER FUNCTION TEST (LFT)				
3	LAB	URIC ACID				
4	LAB	URINE GLUCOSE - FASTING				
5	LAB	URINE GLUCOSE - POSTPRANDIAL (2 Hrs)				
6	LAB	COMPLETE BLOOD COUNT WITH ESR				
7	LAB	CREATININE				
8	LAB	BUN/CREATININE RATIO				
9	LAB	THYROID PROFILE/ TFT(T3, T4, TSH)				
10	LAB	STOOL ANALYSIS - ROUTINE				
11	LAB	URINE ROUTINE				
12	LAB	BLOOD UREA NITROGEN (BUN)				
13	LAB	GLUCOSE - FASTING				
14	LAB	GLUCOSE - POSTPRANDIAL (2 HRS)				
15	LAB	GLYCOSYLATED HAEMOGLOBIN (HbA1c)				
16	LAB	BLOOD GROUP & RH TYPE				

49 AM

Patient Details Print Page

		(Forward Reverse)			
17	OTHERS	physical examination	MYS2686692102651		
18	US	ULTRASOUND ABDOMEN	MYS2686692103462		2 floor
19	OTHERS	Treadmill 2D Echo	MYS2686692127528		
20	OTHERS	EYE CHECKUP ✓	MYS2686692135592		- Melthada Hospital
21	X-RAY	X RAY CHEST ✓	MYS2686692145199		2 floor
22	OTHERS	Consultation Physician	MYS2686692148004		
23	ECHO	ELECTROCARDIOGRAM ECG ✓	MYS2686692149333		

Ht - 168
Wt - 79.1
Bp - 150/90 mmHg
puls - 72 bpm
Temp - 38
Walt - 36

Registered By
(A.JAYASHREE)

Customer Name	MR.P GIRISH S	Customer ID	MED111148807
Age & Gender	41Y/MALE	Visit Date	11/06/2022
Ref Doctor	MediWheel		

2 D ECHOCARDIOGRAPHIC STUDY

M mode measurement:

AORTA	:	3.0cms
LEFT ATRIUM	:	3.2cms
LEFT VENTRICLE (DIASTOLE)	:	4.5cms
(SYSTOLE)	:	3.0cms
VENTRICULAR SEPTUM (DIASTOLE)	:	1.0cms
(SYSTOLE)	:	1.3cms
POSTERIOR WALL (DIASTOLE)	:	0.9cms
(SYSTOLE)	:	1.2cms
EDV	:	75ml
ESV	:	28ml
FRACTIONAL SHORTENING	:	37%
EJECTION FRACTION	:	63%
RVID	:	1.6cms

DOPPLER MEASUREMENTS:

MITRAL VALVE	:	'E' - 0.81m/s	'A' - 0.29 m/s	NO MR
AORTIC VALVE	:	1.01m/s		NO AR
TRICUSPID VALVE	:	'E' - 0.78m/s	'A' - 0.40 m/s	NO TR
PULMONARY VALVE	:	0.77m/s		NO PR


Patient Name	MR.P GIRISH S	Customer ID	MED111148807
Age & Gender	41Y/MALE	Visit Date	11/06/2022
Referring Doctor	MediWheel		

2D ECHOCARDIOGRAPHY FINDINGS:

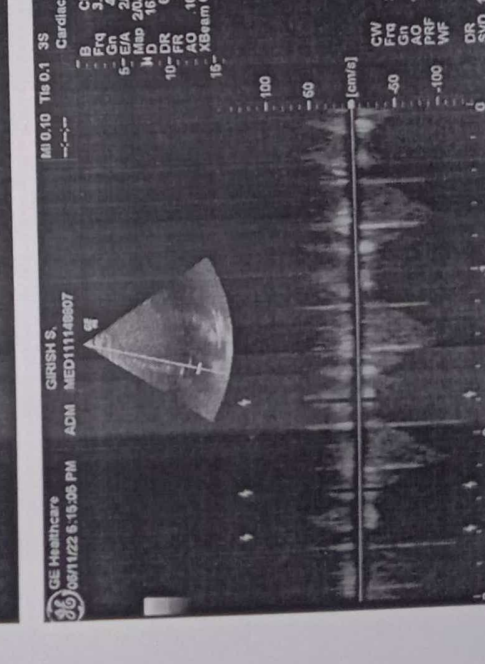
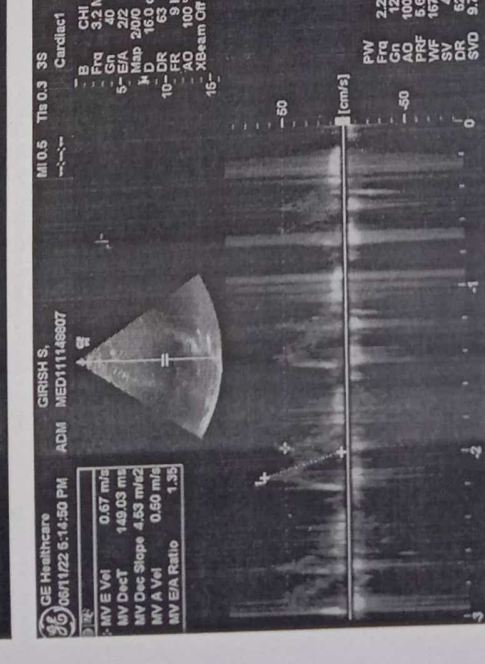
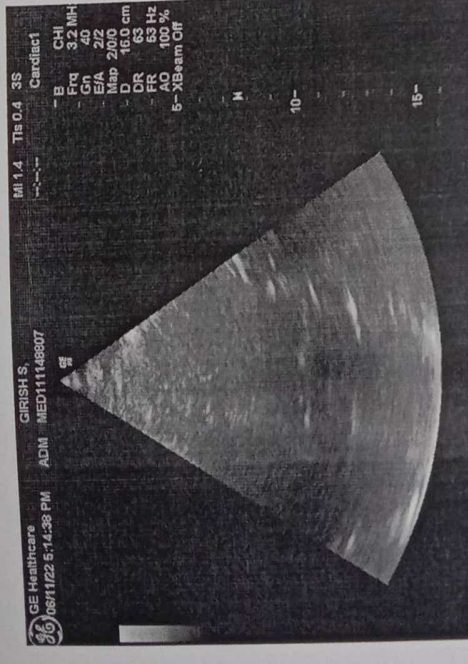
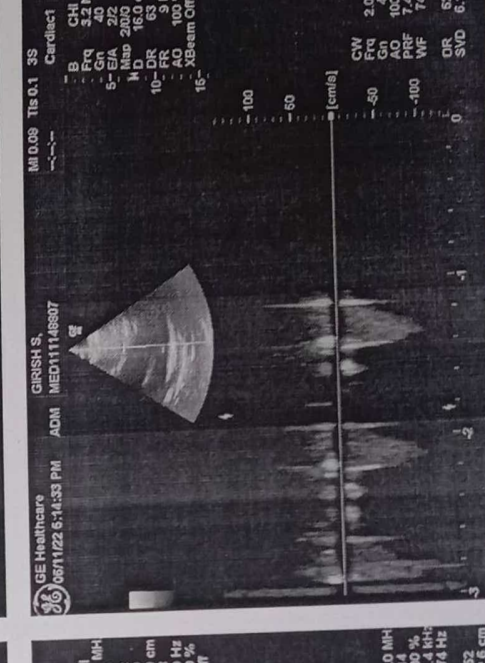
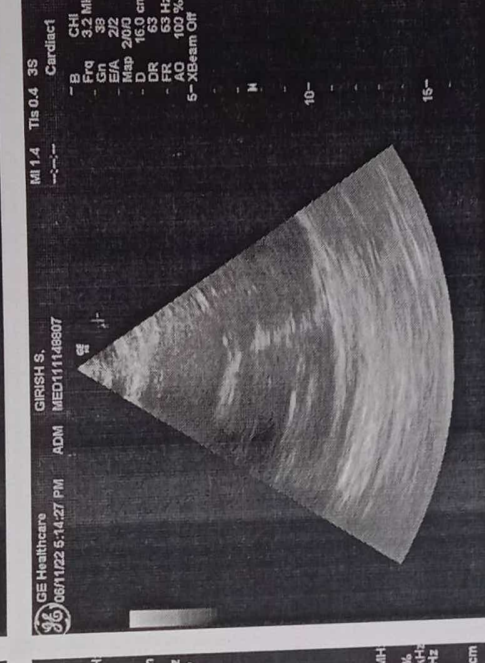
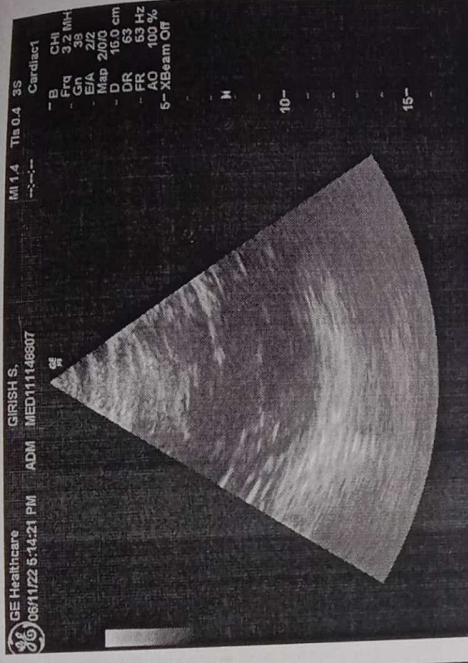
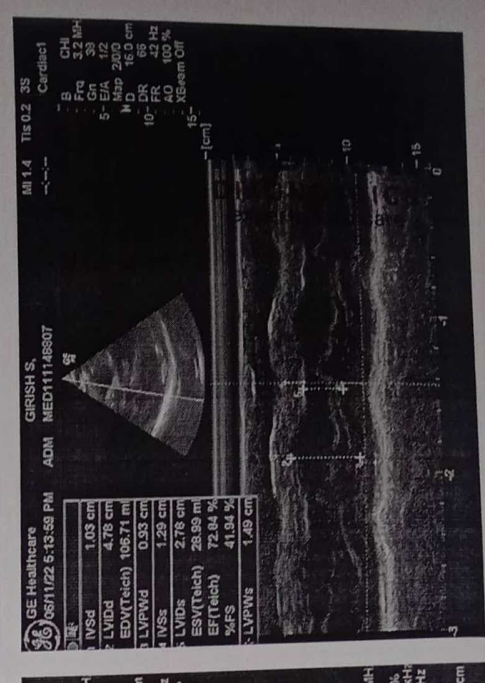
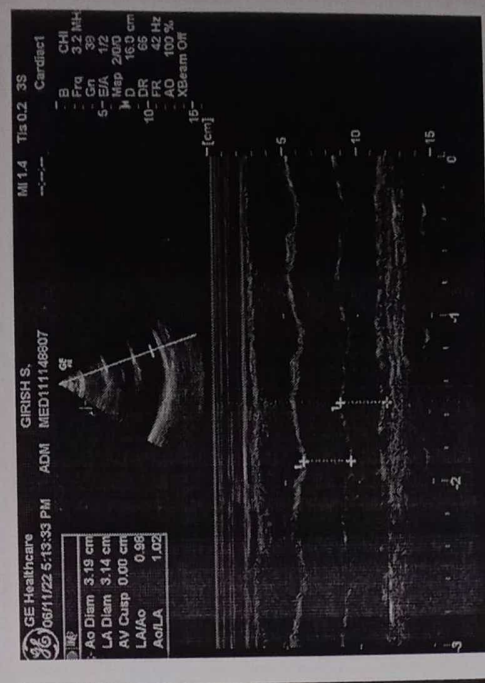
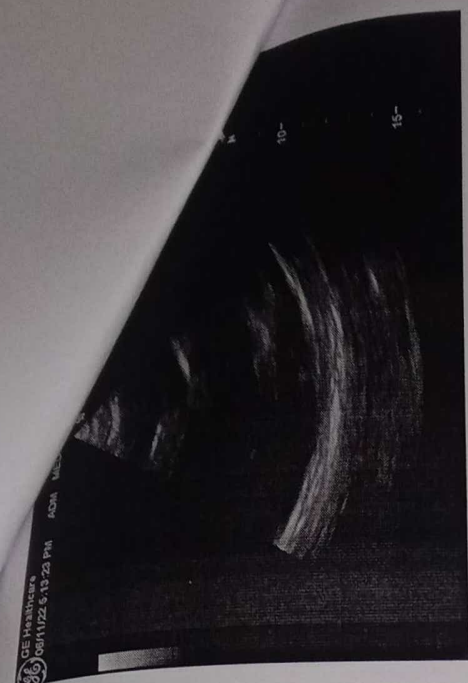Left ventricle	: Normal size, Normal systolic function. No regional wall motion abnormalities.
Left Atrium	: Normal.
Right Ventricle	: Normal.
Right Atrium	: Normal.
Mitral valve	: Normal, No mitral valve prolapsed.
Aortic valve	: Normal, Trileaflet.
Tricuspid valve	: Normal.
Pulmonary valve	: Normal.
IAS	: Intact.
IVS	: Intact.
Pericardium	: No pericardial effusion.

IMPRESSION:

- NORMAL SIZED CARDIAC CHAMBERS.
- NORMAL LV SYSTOLIC FUNCTION. EF: 63%.
- NO REGIONAL WALL MOTION ABNORMALITIES.
- NORMAL VALVES.
- NO CLOTS/ PERICARDIAL EFFUSION VEGETATION.



DR. NIKHIL B
INTERVENTIONAL CARDIOLOGIST
NB/SA



Customer Name	MR.P GIRISH S	Customer ID	MED111148807
Age & Gender	41Y/MALE	Visit Date	11/06/2022
Ref Doctor	MediWheel		

ABDOMINO-PELVIC ULTRASONOGRAPHY

LIVER is normal in size and shows slightly increased echotexture.

No evidence of focal lesion or intrahepatic biliary ductal dilatation.

Hepatic and portal vein radicals are normal.

GALL BLADDER show normal shape and has clear contents.

Gall bladder wall is of normal thickness. CBD is of normal calibre.

PANCREAS has normal shape, size and uniform echopattern.

No evidence of ductal dilatation or calcification.

SPLEEN show normal shape, size and echopattern.

KIDNEYS move well with respiration and have normal shape, size and echopattern.

Cortico- medullary differentiations are well madeout.

No evidence of calculus or hydronephrosis.

	Bipolar length (cms)	Parenchymal thickness (cms)
Right Kidney	11.0	2.0
Left Kidney	10.8	2.0

URINARY BLADDER show normal shape and wall thickness.

It has clear contents. No evidence of diverticula.

PROSTATE shows normal shape, size and echopattern.


No evidence of ascites.

IMPRESSION:

➤ **GRADE I FATTY CHANGES IN LIVER.**

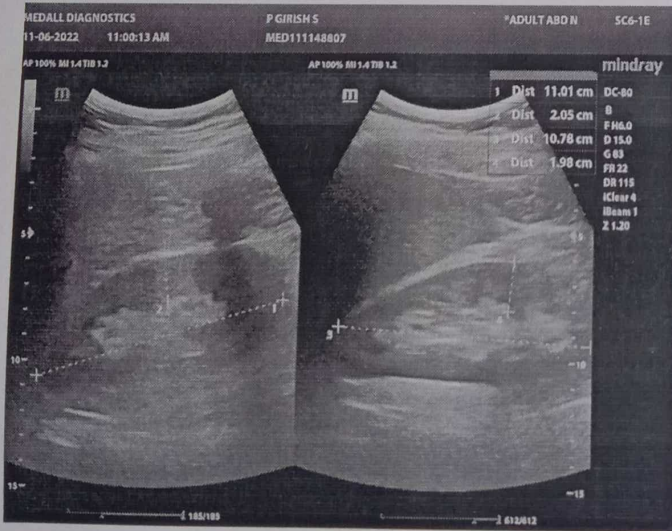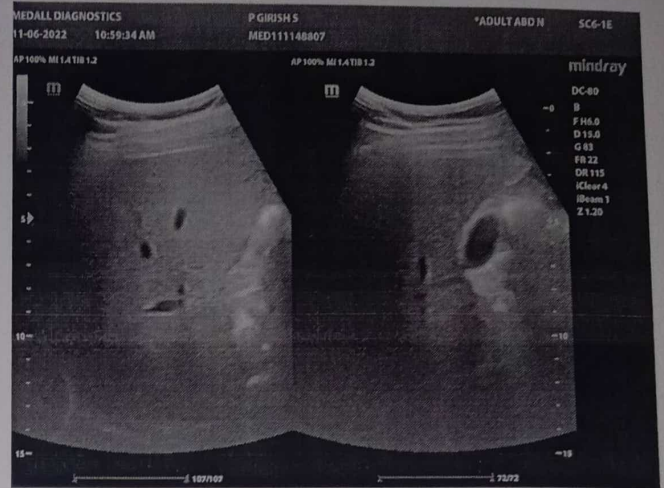
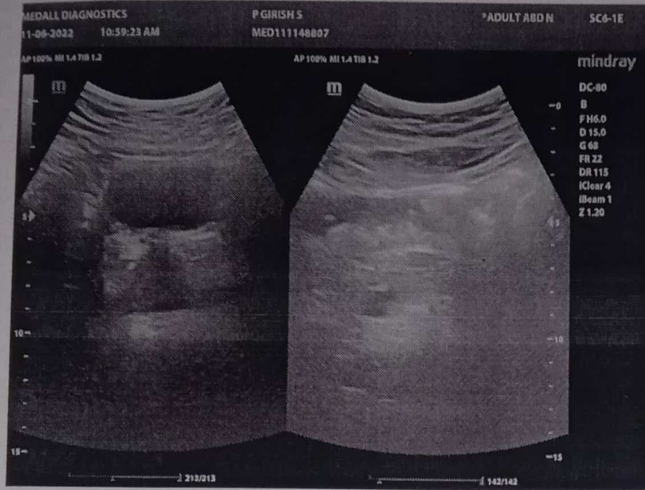CONSULTANT RADIOLOGISTS

DR. ANITHA ADARSH
MB/SV



DR. MOHAN B

Customer Name	MR.P GIRISH S	Customer ID	MED11148807
Age & Gender	41Y/MALE	Visit Date	11/06/2022
Ref Doctor	MediWheel		



T/W

MEDALL



NETHRADHAMA SUPER SPECIALITY EYE HOSPITAL

(A Unit of Nethradhama Hospitals Pvt. Ltd.)

OPD SHEET

Date: 11/06/2022

Patient's Name: Mr. Girish S

OP No. 1197810

4148/M

11:20 AM

NCT < 13
11

Dr. Richa

MBBS, DOMS, DNB
Consultant-vitreous Retina
KMC Reg. No. : 105719

BLVA < 6/6, N6
6/6, N6

color vision - 38/38 - normal on
Ishihare chart

ant segment - normal
fundus - normal

BE - CO - 0.3, PR +

add

exam finished
R/A 1 yr 1505

Jayanagar Branch : 080-26088000 / 2663 3533 / 2663 3609 / 2245 Mobile : 94480 71816

Rajajinagar Branch : 080-4333 4111 / 2313 2777 / Mobile : 99728 53918

Indiranagar Branch : 080-4333 2555 Mobile : 81973 51609

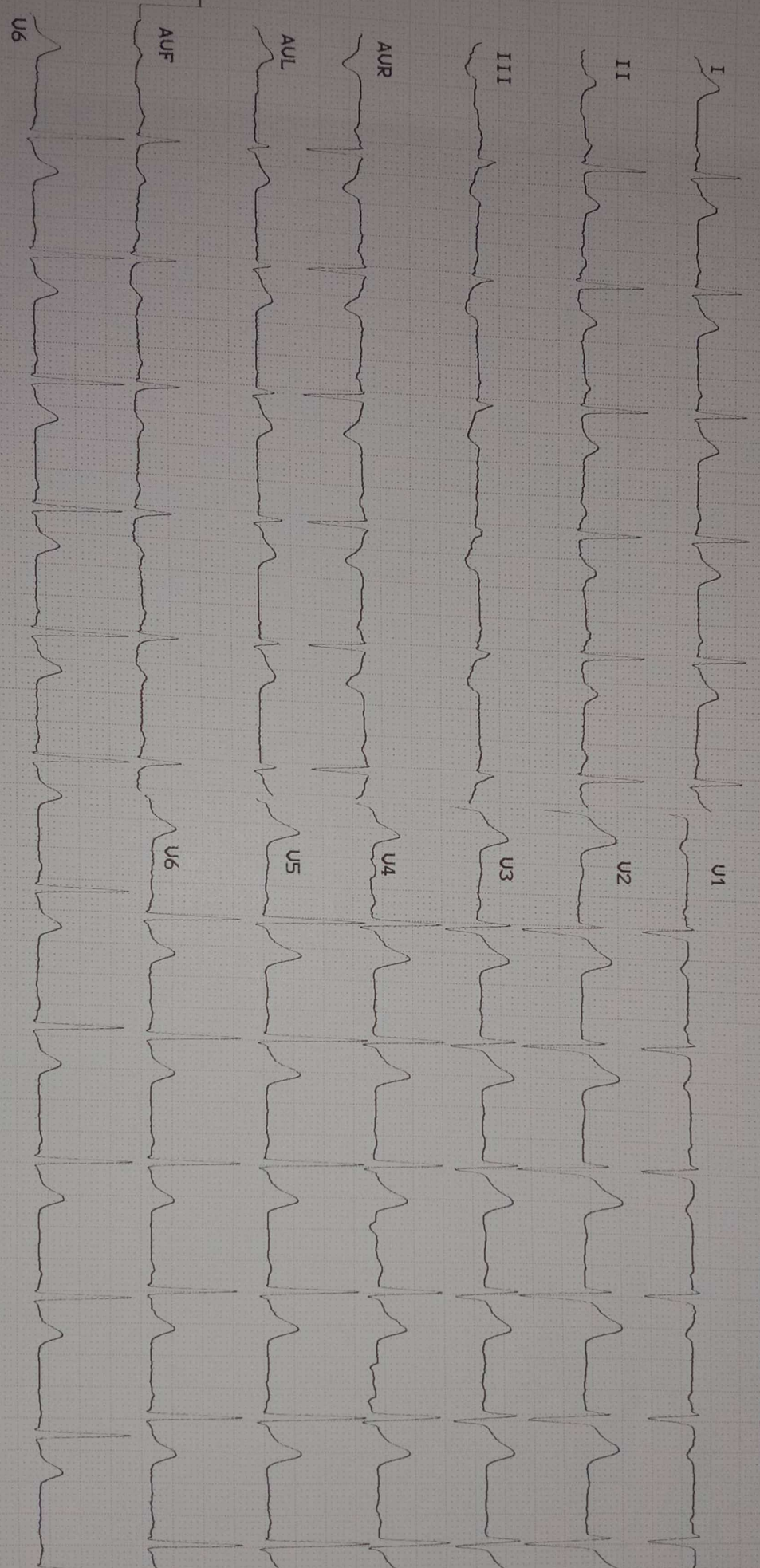
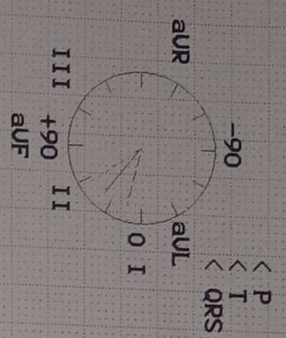
Mysore Branch : 0821-4293000 Mobile : 94490 03771

Mangalore Lasik Centre : 0824-2213801 Mobile : 97410 26389

Davangere Lasik Centre : 08192-226607/08 Mobile : 94820 01795

R / FD / 07 / 13

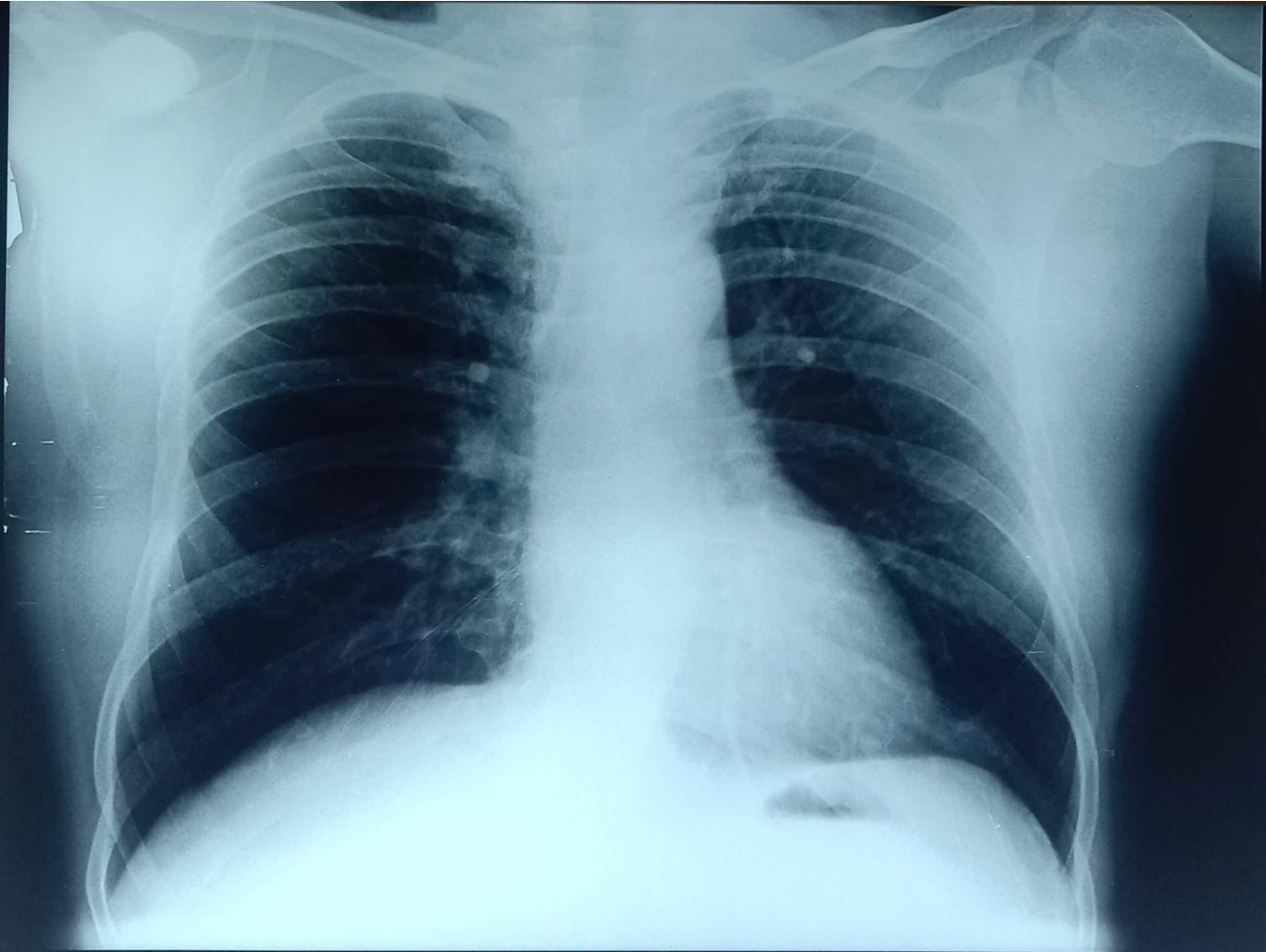
AGE: 41
Measurement Results:
QRS : 106 ms
QT/QTcB : 376 / 413 ms
PR : 166 ms
P : 128 ms
RR/PP : 830 / 830 ms
P/QRS/T : 55 / 40 / 15 degrees
QTd/QTcBD : 42 / 46 ms
Sokolow : 2.4 mV
NK : 10



Interpretation: *normal sinus rhythm*
slightly depressed ST segment (inferior) ? ischemia
probably normal ECG

Intraventricular Conduction Delay
So clinically correlate with

Unconfirmed report.



P GIRISH S 41 MED111148807 M CHEST PA 6/11/2022 10:43 AM
MEDALL CLUMAX DIAGNOSTIC