

Customer Name	MRS.SANDINTI YAMUNA	Customer ID	MED120491733
Age & Gender	28Y/FEMALE	Visit Date	22/11/2021
Ref Doctor	MediWheel		

## 2D ECHOCARDIOGRAPHIC STUDY

### M-mode measurement:

AORTA	:	2.01	cms.
LEFT ATRIUM	:	2.89	cms.
AVS	:	1.45	cms.
<b>LEFT VENTRICLE</b>			
(DIASTOLE)	:	3.55	cms.
(SYSTOLE)	:	2.08	cms.
<b>VENTRICULAR SEPTUM</b>	:		
(DIASTOLE)	:	1.04	cms.
(SYSTOLE)	:	1.08	cms.
<b>POSTERIOR WALL</b>	:		
(DIASTOLE)	:	1.08	cms.
(SYSTOLE)	:	1.43	cms.
EDV	:	52	ml.
ESV	:	14	ml.
FRACTIONAL SHORTENING	:	30	%
EJECTION FRACTION	:	60	%
EPSS	:	---	cms.
RVID	:	1.85	cms.

### DOPPLER MEASUREMENTS:

MITRAL VALVE:	E - 0.9m/s	A - 0.8m/s	TRACE MR.
AORTIC VALVE:	1.1 m/s		NO AR.
TRICUSPID VALVE:	E - 0.5 m/s	A -0.4 m/s	TRACE TR.
PULMONARY VALVE:	0.6 m/s		NO PR.





Customer Name	MRS.SANDINTI YAMUNA	Customer ID	MED120491733
Age & Gender	28Y/FEMALE	Visit Date	22/11/2021
Ref Doctor	MediWheel		

### 2D ECHOCARDIOGRAPHY FINDINGS:

Left Ventricle : Normal size, Normal systolic function.  
: No regional wall motion abnormalities.

Left Atrium : Normal.

Right Ventricle : Normal.

Right Atrium : Normal.

Mitral Valve : Normal. No mitral valve prolapsed.

Aortic Valve : Normal. Trileaflet.

Tricuspid Valve : Normal.

Pulmonary Valve : Normal.


IAS : Intact.

IVS : Intact.

Pericardium : No pericardial effusion.

### IMPRESSION:

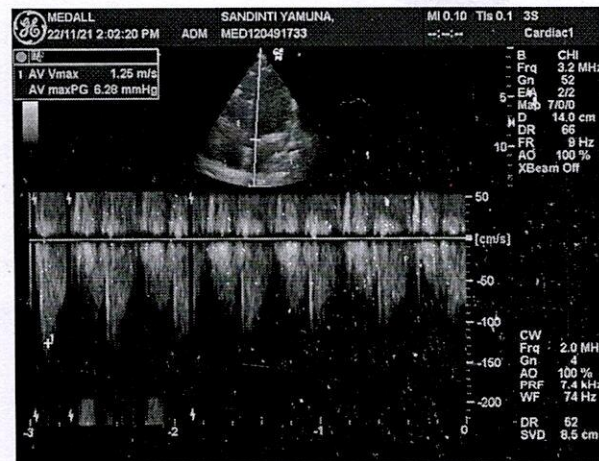
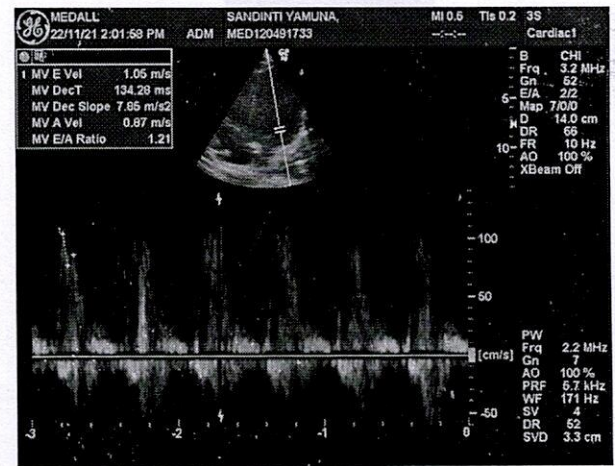
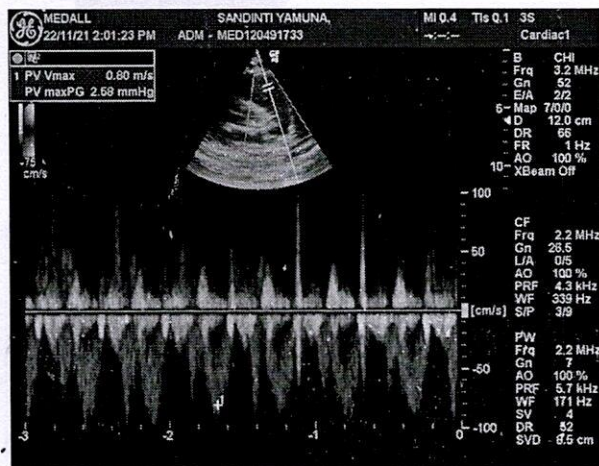
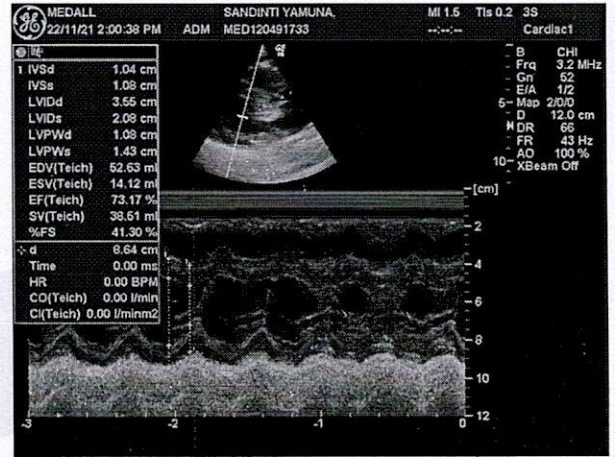
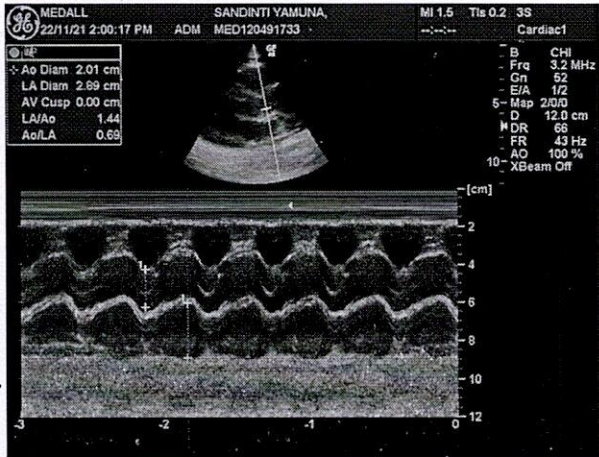
- SINUS TACHYCARDIA DURING THE STUDY.
- NORMAL SIZED CARDIAC CHAMBERS.
- NORMAL LV SYSTOLIC FUNCTION. EF: 60%.
- NO REGIONAL WALL MOTION ABNORMALITIES.
- TRACE MR.
- TRACE TR, PASP 10mmHg.
- NORMAL VALVES.
- NO CLOTS / PERICARDIAL EFFUSION / VEGETATION.

  
**DR. YASHODHA RAVI**  
**CONSULTANT CARDIOLOGIST**





Customer Name	MRS.SANDINTI YAMUNA	Customer ID	MEDI20491733
Age & Gender	28Y/FEMALE	Visit Date	22/11/2021
Ref Doctor	MediWheel		



You can also conveniently view the reports and trends through our App. Scan QR code to download the App.



Please produce bill copy at the time of collecting the reports. Request you to provide your mobile number or customer id during your subsequent visits.



MRS SANDINTI  
ID: MED12049733

28 Years

Female

22.11.2021 13:01:42  
CLUMAX DIAGNOSTICS  
VYALIKAVAL  
BANGALORE

QRS : 74 ms  
QT / QTcBaz : 312 / 437 ms  
PR : 148 ms  
P : 100 ms  
RR / PP : 506 / 508 ms  
P / QRS / T : 51 / 53 / 19 degrees

Sinus tachycardia  
Otherwise normal ECG

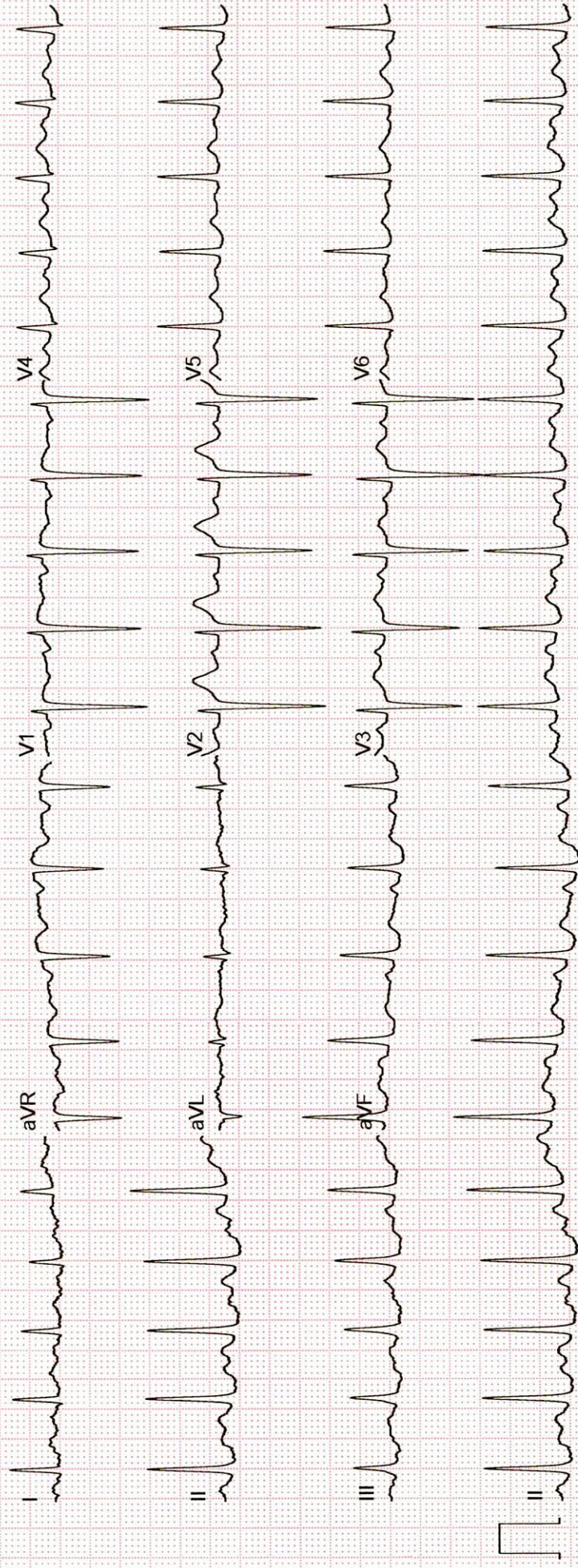
Technician:  
Ordering Ph:  
Referring Ph:  
Attending Ph:

*Srinivasachandran*

*[Signature]*

118 bpm

-- / -- mmHg





**Dr.SHYLESH REDDY**

M.B.B.S.,Dip. DIAB, (A.U)

KMC # 66843

Cons.Physician & Diabetologist

e-mail: drshyleshreddy@yahoo.com



Sandinti Yamma

B.P. 150/90mm of Hg.

28/F

Sup: Dyslipidemia, HTN?

- Regular exercise & diet.

- Check fasting lipid profile, FBS, Vit D3 after

2 months

- Monitor BP next 2 days.

*Shylesh Reddy*

22/11/21

