



PANACEA HOSPITAL



A shelter for many hearts A Home for many lives

(An ISO 9001:2008 Certified Organisation)
Lab Attached with CMC Under EQAS Scheme

Dept. of Radiodiagnosis - 32 Slice CT Scan, 3D/4D USG, 2D ECHO, Colour Doppler, Intervention Procedures, Digital X-Ray

PATIENT'S NAME : SHASHI KUMAR SINHA **AGE/SEX: 37 Y/M**
REF. BY : Dr. ASHUTOSH MISHRA (MD) **Saturday, November 25, 2023**

Echo - Cardiography

MITRAL VALVE Doppler	AML - normal morphology MV Flow - E - 0.9 A-0.5 E/A=1.33	PML - normal morphology MVA - 1.33 cm ² Mitral Regurgitation - No
TRICUSPID VALVE Doppler	Normal TV Flow -No	Tricuspid Regurgitation - No
PULMONARY VALVE Doppler	Normal PV Flow -No	Pulmonary Regurgitation - No
AORTIC VALVE Doppler	Trileaflet-No AV Flow - no	Aortic Regurgitation - No
MEASUREMENT	Aorta - 26.8 (20-38) mm IVS ed - 9.1 (6-12) mm LVID ed - 48.0 (35-55) mm LVPW ed - 9.1 (6-12) mm OA - 7 (> 5) mm	LA -32.0 (24-32) mm IVS es -17.1 (6-12) mm LVID es - 32.0 (24-40) mm LVPW es - 8.6 (6-12) mm EPSS - 4 (< 9) mm

CONCLUSION

All cardiac chamber dimensions are WNL
No valvular abnormalities
Good LV systolic function present Modified Simpson's method (4C, 2C) (LVEF-62%)
No diastolic dysfunction present (E/A = 1.33)
No RWMA
No pericardial effusion
Intact IAS / IV
No PAH
No intra cardiac mass /thrombus /vegetation

IMPRESSION **Normal Echocardiogram**

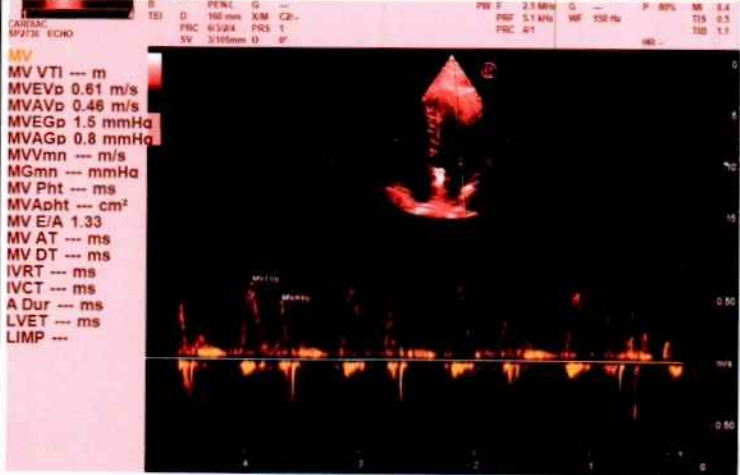

Nira Mishra
Physician Assistant
(PIRE)


Dr. Pallavi Mishra
MBBS, MD (MED) Lucknow
DR. Pallavi Misra
MBBS, MD (GENERAL MEDICINE)
MCI Reg. No. 52033
Women Cardiologist

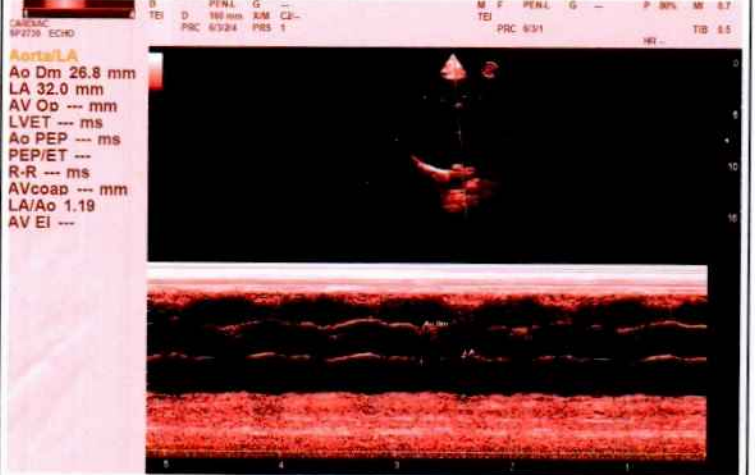
Disclaimer: This report is not valid for Madicolegal or Judicial Purpose. Radiological diagnosis is solely interpretation of images produced by tissue & may not be always conclusive.

Address : B36/44 B4 Kabir Nagar (Near Sanjay Shiksha Niketan), Durgakund, Varanasi
Mobile : 9554572190 / 9453837595 / Recpn, 9389994334
Email : dramishra@gmail.com, drpallaviojha@gmail.com, Website : www.pire.org

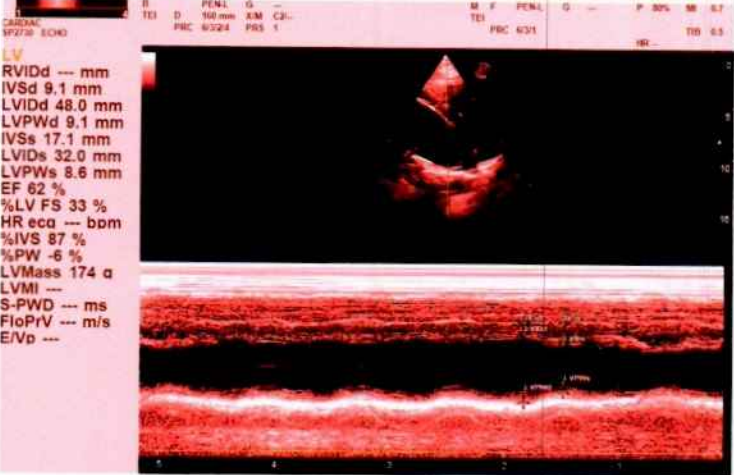
SHASHI KUMAR SINHA 37Y/M,F 25 11 2023 09:45:13 AM



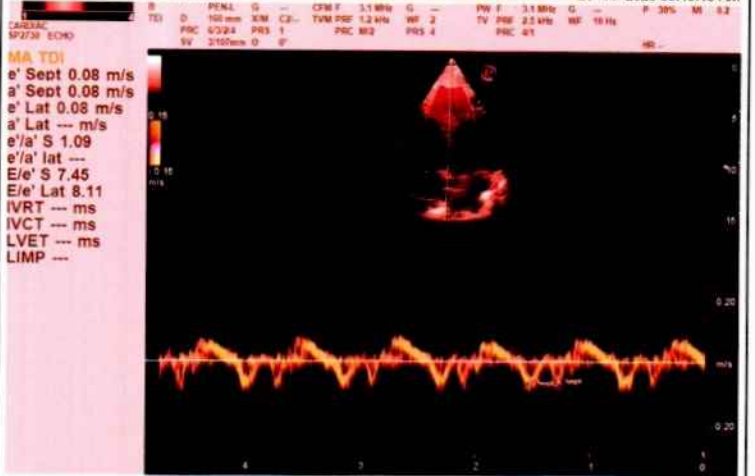
SHASHI KUMAR SINHA 37Y/M,F 25 11 2023 09:45:13 AM



SHASHI KUMAR SINHA 37Y/M,F 25 11 2023 09:45:13 AM



SHASHI KUMAR SINHA 37Y/M,F 25 11 2023 09:45:13 AM



Facilities:

All clinical Biomedical & Hematology Investigations including Bone Marrow Examination VPT, Podiascan & Complete Foot Care (First Time in Purvanchal) All Hormonal Investigation by Chemiluminescent Method Visceral Fat by (AB-140) Ambulatory BP Monitoring CGMS & Insulin Pump Available PFT, 2D-ECHO (Color Doppler), Holter, TMT, Cardiac-3 available VIA, VILI, Colposcopy available Special Endocrinological Investigation Protocols.

ISO 9001:2008 Certified
Mobile: 9389994334, 9554572190, 9453837595



Panacea Pathology

Clinical Reference Lab

Persistence, Preparedness and Precision
EQAS (CMC Vellore Attached) & IQAS System
पूर्वांचल की सर्वोत्तम गुणवत्ता वाली पैथोलॉजी

UHID No :- UD-23240004230
Booking No/Date :- 56 / 25-Nov-2023 12:51 PM
Patient Name :- Mr SHASHI KUMAR SINHA
Age/Sex :- 37 Y/M
Father :- SHIV LAKH PATI LAL
OP No :- OP-23240013551
Address :- JANIPUR ROAD NEAR WALMI
COMPLEX RAM NAGAR PHULWARI -
801505, Patna
Mobile No :- 8737042542
Consultant :- Dr ASHUTOSH MISHRA (MBBS MD IMS BHU)

HAEMATOLOGY

CBC

Investigations	Observations	Biological Ref. Interval	Unit
HAEMOGLOBIN <small>DefaultMethod / test Machine</small>	15.1	13.00 - 16.00	gm/dl
TLC <small>Methology / Carm</small>	6,900	4000.00 - 11000.00	Cells/cumm.
DLC DIFFERENTIAL LEUCOCYTE COUNT			
NEUTROPHILS	67	40.00 - 75.00	%
LYMPHOCYTES	27	20.00 - 45.00	%
EOSINOPHILS	02	1.00 - 6.00	%
MONOCYTES	04	2.00 - 10.00	%
BASOPHILS	00	<1-2	%
PLATELET COUNT	1.51	1.50 - 4.10	lacs /cumm
PCV	44.1	33.00 - 42.00	%
RBC <small>Methology / Carm</small>	4.61	4.50 - 5.50	million/cumm
MCV(MEAN CELL VOLUME)	95.7	83.00 - 101.00	fl
MCH(MEAN CELL HAEMOGLOBIN)	32.7	27.00 - 32.00	pg
MCHC	34.2	31.50 - 35.00	gm%

* END OF REPORT *

Consulting Pathologist

DR. UMESH KUMAR
MBBS, MD (PATHOLOGIST)
MCh Pathology
MCI Reg. No. 41413

Lab Technician

Timing : 24/7 hrs

This Report is not valid for medico legal purpose

Note: These tests have technical limitations. Clinico-pathological interpretation is necessary. In case of any disparity test may be repeated immediately.

Address : 36/44 FK Kabir Nagar, Durgakund, Varanasi – 221005

Email: dramishra@gmail.com, drpallaviojha@gmail.com Website: panaceahospital.org

Facilities:

All clinical Biomedical & Hematology Investigations including Bone Marrow Examination
 VPT, Podiascan & Complete Foot Care (First Time in Purvanchal)
 All Hormonal Investigation by Chemiluminescent Method
 Visceral Fat by (AB-140) Ambulatory BP Monitoring
 CGMS & Insulin Pump Available
 PFT, 2D-ECHO (Color Doppler), Holter, TMT, Cardiac-3 available
 VIA, VILI, Colposcopy available
 Special Endocrinological Investigation Protocols.

ISO 9001:2008 Certified

Mobile: 9389994334, 9554572190, 9453837595

**Panacea Pathology****Clinical Reference Lab**

Persistence, Preparedness and Precision
 EQAS (CMC Vellore Attached) & IQAS System
 पूर्वांचल की सर्वोत्तम गुणवत्ता वाली पैथोलॉजी

UHID No :- UD-23240004230 **Booking No/Date** :- 20 / 25-Nov-2023 12:07 PM
Patient Name :- Mr SHASHI KUMAR SINHA **Age/Sex** :- 37 Y/M
Father :- SHIV LAKH PATI LAL **OP No** :- OP-23240013551
Address :- JANIPUR ROAD NEAR WALMI COMPLEX RAM NAGAR PHULWARI - 801505 , Patna **Mobile No** :- 8737042542
Consultant :- Dr ASHUTOSH MISHRA (MBBS MD IMS BHU)

Investigations Observations Biological Ref. Interval Unit

URINE EXAMINATION**URINE ROUTINE EXAMINATION****PHYSICAL EXAMINATION**

QUANTITY 25 ml

COLOR STRAW CLEAR YELLOW
Methology

APPEARANCE CLEAR CLEAR
DefaultMethod

CHEMICAL EXAMINATION

SPECIFIC GRAVITY 1.015 1.01 - 1.03

PH 6.0 4.60 - 8.00

GLUCOSE NIL 60.00 - 100.00 mg/dl

PROTEIN- NIL

MICROSCOPIC EXAMINATION

PUS CELLS NIL 2.00 - 3.00 /HPF

RBCS (RED BLOOD CELLS) NIL 4.50 - 5.50 /HPF

EPITHELIAL CELLS 01-02 /HPF

CASTS ABSENT ABSENT

CRYSTALS ABSENT ABSENT

Consulting Pathologist

DR. UMESH KUMAR

MBBS, MD (PATHOLOGIST)

MCI Reg. No. 41483

Lab Technician

Timing : 24/7 hrs

This Report is not valid for medico legal purpose

Note: These tests have technical limitations. Clinico-pathological interpretation is necessary. In case of any disparity test may be repeated immediately.

Address : 36/44 FK Kabir Nagar, Durgakund, Varanasi - 221005

Email: dramishra@gmail.com, drpallaviojha@gmail.com Website: panaceahospital.org

Facilities:

All clinical Biomedical & Hematology Investigations including Bone Marrow Examination
 VPT, Podiascan & Complete Foot Care (First Time in Purvanchal)
 All Hormonal Investigation by Chemiluminescent Method
 Visceral Fat by (AB-140) Ambulatory BP Monitoring
 CGMS & Insulin Pump Available
 PFT, 2D-ECHO (Color Doppler), Holter, TMT, Cardiac-3 available
 VIA, VILI, Colposcopy available
 Special Endocrinological Investigation Protocols.

ISO 9001:2008 Certified

Mobile: 9389994334, 9554572190, 9453837595

**Panacea Pathology****Clinical Reference Lab**

Persistence, Preparedness and Precision
 EQAS (CMC Vellore Attached) & IQAS System
 पूर्वांचल की सर्वोत्तम गुणवत्ता वाली पैथोलॉजी

UHID No :- UD-23240004230 **Booking No/Date** :- 20 / 25-Nov-2023 12:07 PM
Patient Name :- Mr SHASHI KUMAR SINHA **Age/Sex** :- 37 Y/M
Father :- SHIV LAKH PATI LAL **OP No** :- OP-23240013551
Address :- JANIPUR ROAD NEAR WALMI COMPLEX RAM NAGAR PHULWARI - 801505, Patna **Mobile No** :- 8737042542
Consultant :- Dr ASHUTOSH MISHRA (MBBS MD IMS BHU)

Investigations	Observations	Biological Ref. Interval	Unit
HAEMATOLOGY			
BLOOD GROUP ABO & RH FACTOR			
BLOOD GROUP	"O"		
RH FACTOR	POSITIVE		
HBA1C -(BY GOLD STANDARD METHOD :HPLC)	5.0	Normal: 4.0 - 5.4 Prediabetic : 5.5 -6.3 Diabetes mellitus := 6.4	%
ESR	10.0	0.00 - 15.00	mm at 1 hr
BIOCHEMISTRY			
LIPID PROFILE			
TOTAL CHOLESTROL	176.0	Desirable : - < 200 mg/dL Borderline: - 200 - 239 mg/dL High : - > 240mg/dL	mg/dl
TRIGLYCERIDES	159.0	35.00 - 160.00	mg/dl
HDL CHOLESTROL	42.0	35.30 - 79.50	mg/dl
LDL CHOLESTROL	102.2	<130	mg/dl
VLDL	31.80	<40	mg/dl
CHOLESTROL/ HDL RATIO	4.19	<3.0 LOW RISK, 3.0-5.0 AVG RISK, >5.0 HIGH RISK	ratio
LDL/HDL RATIO	2.43	<3	ratio
YGGT	19.0	10.00 - 50.00	U/L

Lab Technician

Consulting Pathologist

DR. UMESH KUMAR
 MBBS, MD (PATHOLOGIST)
 MCI Reg. No. 41413

Timing : 24/7 hrs

This Report is not valid for medico legal purpose

Note: These tests have technical limitations. Clinico-pathological interpretation is necessary. In case of any disparity test may be repeated immediately.

Address : 36/44 FK Kabir Nagar, Durgakund, Varanasi - 221005

Email: dramishra@gmail.com, drpallaviojha@gmail.com Website: panaceahospital.org

Facilities:

All clinical Biomedical & Hematology Investigations including Bone Marrow Examination
 VPT, Podiascan & Complete Foot Care (First Time in Purvanchal)
 All Hormonal Investigation by Chemiluminescent Method
 Visceral Fat by (AB-140) Ambulatory BP Monitoring
 CGMS & Insulin Pump Available
 PFT, 2D-ECHO (Color Doppler), Holter, TMT, Cardiac-3 available
 VIA, VILI, Colposcopy available
 Special Endocrinological Investigation Protocols

ISO 9001:2008 Certified

Mobile: 9389994334, 9554572190, 9453837595



Panacea Pathology

Clinical Reference Lab

Persistence, Preparedness and Precision
 EQAS (CMC Vellore Attached) & IQAS System
 पूर्वांचल की सर्वोत्तम गुणवत्ता वाली पैथोलॉजी

UHID No :- UD-23240004230 **Booking No/Date** :- 20 / 25-Nov-2023 12:07 PM
Patient Name :- Mr SHASHI KUMAR SINHA **Age/Sex** :- 37 Y/M
Father :- SHIV LAKH PATI LAL **OP No** :- OP-23240013551
Address :- JANIPUR ROAD NEAR WALMI COMPLEX RAM NAGAR PHULWARI - 801505, Patna **Mobile No** :- 8737042542
Consultant :- Dr ASHUTOSH MISHRA (MBBS MD IMS BHU)

Investigations	Observations	Biological Ref. Interval	Unit
LFT (LIVER FUNCTION TESTS)			
TOTAL BILIRUBIN	0.67	0.00 - 1.20	mg/dl
DIRECT BILIRUBIN	0.21	0.00 - 0.30	
INDIRECT BILIRUBIN	0.46	0.20 - 0.70	mg/dl
SGOT	25.0	2.00 - 31.00	U/L
SGPT	29.0	10.00 - 45.00	U/L
ALKALINE PHOSPHATASE	69.0	25.00 - 140.00	U/L
TOTAL PROTIENS	7.34	6.60 - 8.70	g/dl
ALBUMIN	4.21	3.50 - 5.20	gm%
GLOBULIN	3.13	1.50 - 3.60	gms/dl
A/G RATIO	1.34	2:1	RATIO
S.CREATININE	1.0	0.60 - 1.40	mg/dl
BLOOD UREA NITROGEN	12.0	6.00 - 21.00	mg/dl
URIC ACID			
URIC ACID	4.10	3.60 - 7.70	mg/dl

BIOCHEMISTRY

BLOOD SUGAR FASTING			
GLUCOSE	99.0	60.00 - 100.00	mg/dl

Lab Technician

Consulting Pathologist

DR. UMESH KUMAR
 MBBS MD (PATHOLOGIST)
 MCI Reg. No. 41413

Timing : 24/7 hrs

This Report is not valid for medico legal purpose

Note: These tests have technical limitations. Clinico-pathological interpretation is necessary. In case of any disparity test may be repeated immediately.

Address : 36/44 FK Kabir Nagar, Durgakund, Varanasi - 221005

Email: dramishra@gmail.com, drpallaviojha@gmail.com Website: panaceahospital.org

Facilities:

All clinical Biomedical & Hematology Investigations including Bone Marrow Examination
 VPT, Podiascan & Complete Foot Care (First Time in Purvanchal)
 All Hormonal Investigation by Chemiluminescent Method
 Visceral Fat by (AB-140) Ambulatory BP Monitoring
 CGMS & Insulin Pump Available
 PFT, 2D-ECHO (Color Doppler), Holter, TMT, Cardiac-3 available
 VIA, VILI, Colposcopy available
 Special Endocrinological Investigation Protocols.

ISO 9001:2008 Certified

Mobile: 9389994334, 9554572190, 9453837595

**Panacea Pathology****Clinical Reference Lab**

Persistence, Preparedness and Precision
 EQAS (CMC Vellore Attached) & IQAS System
 पूर्वांचल की सर्वोत्तम गुणवत्ता वाली पैथोलॉजी

UHID No :- UD-23240004230 **Booking No/Date** :- 20 / 25-Nov-2023 12:07 PM
Patient Name :- Mr SHASHI KUMAR SINHA **Age/Sex** :- 37 Y/M
Father :- SHIV LAKH PATI LAL **OP No** :- OP-23240013551
Address :- JANIPUR ROAD NEAR WALMI COMPLEX RAM NAGAR PHULWARI - 801505, Patna **Mobile No** :- 8737042542
Consultant :- Dr ASHUTOSH MISHRA (MBBS MD IMS BHU)

Investigations	Observations	Biological Ref. Interval	Unit
PRE-DIABETICS(IMPAIRED FASTING TOLER)	-	100.00 - 125.00	mg/dl
DIABETICS	-	upto 126	mg/dl
TARGET IN DM	-	80.00 - 130.00	mg/dl

BIOCHEMISTRY**PPBS(POST PRANDIAL BLOOD SUGAR)**

POST PRANDIAL BLOOD GLUCOSE(2 HR AFTER MEAL)	119.0	110.00 - 150.00	mg/dl
IGT(2 HR 75GM GLUCOSE)	-	140.00 - 199.00	mg/dl
DIABETES	-	upto200	mg/dl
TARGET IN DM	-	80.00 - 130.00	mg/dl

* END OF REPORT *

Lab Technician

Consulting Pathologist

DR. UMESH KUMAR
 MBBS, MD (PATHOLOGIST)
 MCI Reg. No. 41413

Timing : 24/7 hrs

This Report is not valid for medico legal purpose

Note: These tests have technical limitations. Clinico-pathological interpretation is necessary. In case of any disparity test may be repeated immediately.

Address : 36/44 FK Kabir Nagar, Durgakund, Varanasi - 221005

Email: dramishra@gmail.com, drpallaviojha@gmail.com Website: panaceahospital.org

10mm/mV
10mm/mV
5mm/mV

2023-11-25 09:18

<< Conclusions >>

ID :
Name : Shashi Kumar Sinhu

Sex : M

Height : 160

SYS :
DIA :

Age : 37

Weight : 79.5kg

HR : 74

PR Interval : 182

P Duration : 120

QRS Duration : 68

T Duration : 213

QT/QTc : 367/408

P/QRS/T Axis : 56.9/38.8/24.8

R(V5)/S(V1) : 1.54/0.23

R(V5)+S(V1) : 1.77

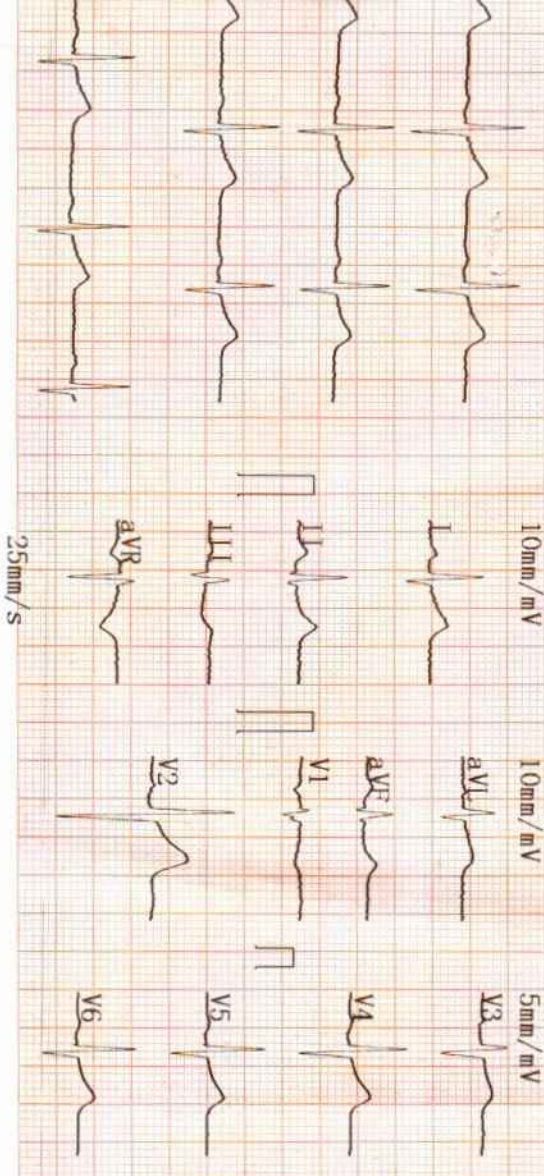
Normal Sinus Rhythm;
Cardiac electric axis normal;
possible old inferior MI.

Report need physician confirm

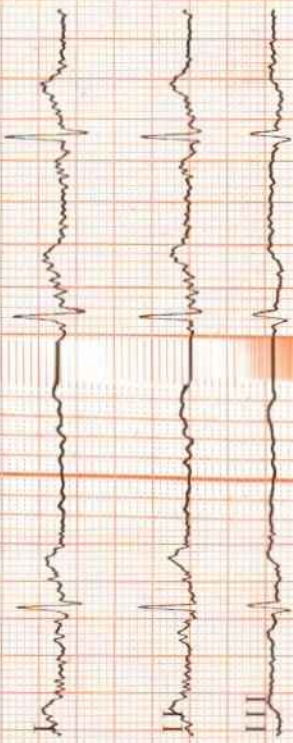
Pallavi
DR. Pallavi Misra
MBBS, MD(GENERAL MEDICINE)
MCI Reg. No.52033

Physician _____

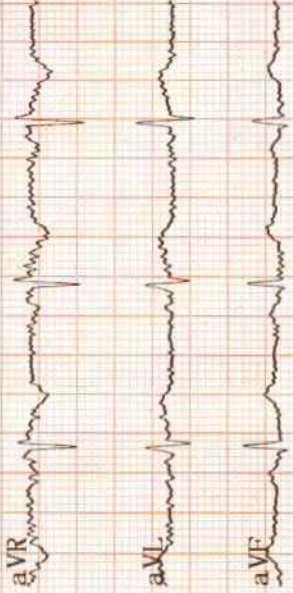
25mm/s



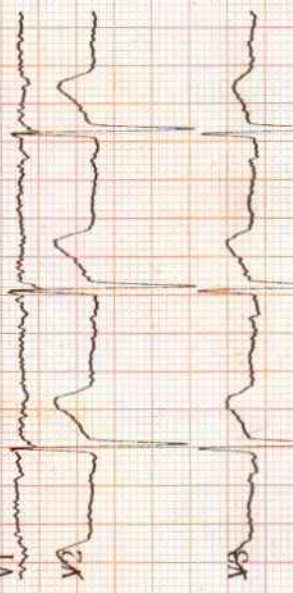
AUTO 10mm/mV



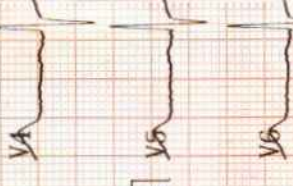10mm/mV



10mm/mV



5mm/mV



V5 5mm/mV



25mm/s AC50Hz+EMCG3 5Hz+DFT



PANACEA HOSPITAL

B 36/44 F.K KABIR NAGAR, DURGAKUND
TOLLFREE NO-18001233070. Whatsapp No - 8795832852
www.piire.org
panaceaquery@gmail.com|panaceahospitalit@gmail.com



OP Slip

Print Date : 25-Nov-2023 09:16AM



UHID No :- UD-23240004230	OP No :- OP-23240013551	OP Date :- 25 Nov 2023 9:15AM
Patient Name :- Mr SHASHI KUMAR SINHA	Age/Sex :- 37 Y/Male	Mobile No :- 8737042542
Father :- SHIV LAKH PATI LAL	Department :- GENERAL MEDICINE	
Pay Type :- Cash	Consultant :- Dr ASHUTOSH MISHRA (MBBS MD IMS BHU,MD)	
Token No :- NOR. - 1	Paid/Bal :- 0.00 /630.00	
Patient Type :- Normal		
Address :- JANIPUR ROAD NEAR WALMI COMPLEX RAM NAGAR PHULWARI -801505,Patna		

BP :- 130/90 ✓
 height :- 160
 Weight (kg) :- 77.5
 BMI :- 30.2

Rx

△ COPD
 HASTY
 Obesity

SpO2 - 98
 PR - 80
 NC - 39
 WC - 113
 PEF - 300

Post ventric - sync

CRF
 Par

Rx
 Wt loss - Diets
 Tab. Dapa 10mg OD
 Tab. Benpryam 10mg OD
 Au CRK (SRA) (M)

Imz. Ash

✓ Tab. Doxolin. (400) OD
 ✓ Rev. Artic FF (200)
 & Rybalsin. (3mg) SUNDAY.

Printed By : Ms. RENUKA
 Created By : Ms. RENUKA

AAA 1 month

DR. ASHUTOSH MISHRA
 MBBS, MD (GENERAL MEDICINE)
 MCI, Reg. No. 45695



PANACEA HOSPITAL

B 36/44 F.K KABIR NAGAR, DURGAKUND
TOLLFREE NO-18001233070. Whatsapp No - 8795832852
www.piire.org
panaceaquery@gmail.com|panaceahospitalit@gmail.com



OP Slip

Print Date : 25-Nov-2023 03:07PM



UHID No :- UD-23240004230	OP No :- OP-23240013611	OP Date :- 25 Nov 2023 3:06PM
Patient Name :- Mr SHASHI KUMAR SINHA	Age/Sex :- 37 Y/Male	Mobile No :- 8737042542
Father :- SHIV LAKH PATI LAL	Department :- OPHTHALMOLOGY	
Pay Type :- Cash	Consultant :- Dr Santosh Verma (MBBS,MS)	
Token No :- NOR. - 5	Paid :- 0.00	
Patient Type :- Normal		
Address :- JANIPUR ROAD NEAR WALMI COMPLEX RAM NAGAR PHULWARI -801505,Patna		

BP :- 130/90
height :- 160
Weight (kg) :- 77.5
BMI :- 30.2

SPO2 98
PR 80
NC 39
WC 113
PEFR 300

Rx

VA $\left\{ \begin{array}{l} 6/24' \text{ --- } 6/6' \\ 6/36 \text{ --- } 6/9' \end{array} \right.$

Nv $\left\{ \begin{array}{l} N16 \text{ 'x'} \\ N16 \text{ 'x'} \end{array} \right.$

Omega Paper :- ~~conventional~~ / ~~beginner~~ RFL.

Adv

- Refraction
- Dilated fundus evaluation
- OCT (m) BE

Cap 2-FORTE PLUS 100
B/E
- a. substance ultra
0000

~~Fasto plus~~
~~cto drug~~

Adv. - Convergence exercise
- Rf investigations of management

Printed By : Mr NITIN YADAV
Created By : Mr NITIN YADAV





PANACEA HOSPITAL



A shelter for many hearts A Home for many lives

(An ISO 9001:2008 Certified Organisation)
Lab Attached with CMC Under EQAS Scheme

Dept. of Radiodiagnosis - 32 Slice CT Scan, 3D/4D USG, 2D ECHO, Colour Doppler, Intervention Procedures, Digital X-Ray

PATIENT'S NAME : SHASHI KUMAR SINHA AGE/SEX: 37Y/M
REF. BY : DR.ASHUTOSH MISHRA (MD) Saturday, November 25, 2023

U/S. WHOLE ABDOMEN

- LIVER** : Liver is enlarge in size 166mm, diffuse increased echogenicity of liver parenchyma - Grade II fatty liver. Intra hepatic biliary radicals are normal. Portal venous channels are normal
- G. B.** : Gall bladder is normal in size, lumen is clear. Wall thickness normal.
- C.B.D.** : C.B.D. is normal in caliber.
- PANCREAS** : Pancreas is normal in size, shape and echotexture. No evidence of any inflammatory disease or mass.
- SPLEEN** : Spleen is normal in size (11.0cm), shape and echotexture.
- Rt. KIDNEY** : Normal in size, shape and echotexture. Renal sinus is normal Cortico medullary differentiation is normal. P. C. system is normal.
- Lt. KIDNEY** : Normal in size, shape and echotexture. Renal sinus is normal Cortico medullary differentiation is normal. P. C. system is normal.
- URI. BLADDER** : Urinary bladder is normal in size, position. Wall thickness normal. No evidence of calculus or mass.
- URI. BLADDER** : Urinary bladder is normal in size, position. Wall thickness normal.
- PROSTATE** : Prostate is normal in size 25x40x38mm Vol 20.4ml. No ascites & retro peritoneal lymphadenopathy seen.

IMPRESSION :

- **GRADE II FATTY LIVER WITH HEPATOMEGALY**

Sonologist

Dr. Rahul Kumar Tiwan
MBBS, MD (Radio Diagonosis),
Reg. No. 57557

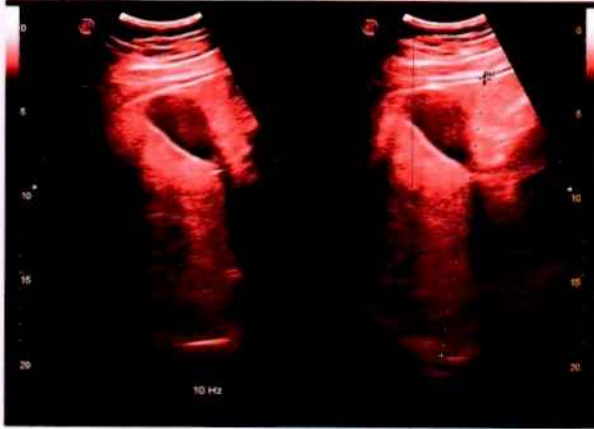
Thanks for reference.

SHASHI KUMAR SINHA 37Y/M,F

25 11 2023 09:41:51 AM

TEI D 211 mm XM C2-
PRC 19/2/35 PRS 4

D1
166.1 mm

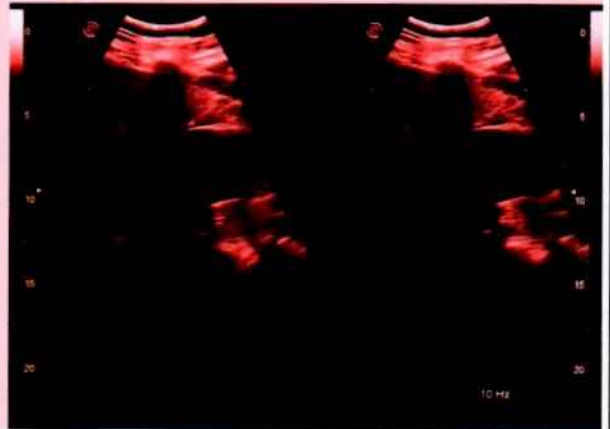


SHASHI KUMAR SINHA 37Y/M,F

25 11 2023 09:41:51 AM

TEI D 211 mm XM C2-
PRC 19/2/35 PRS 4

D1
110.8 mm

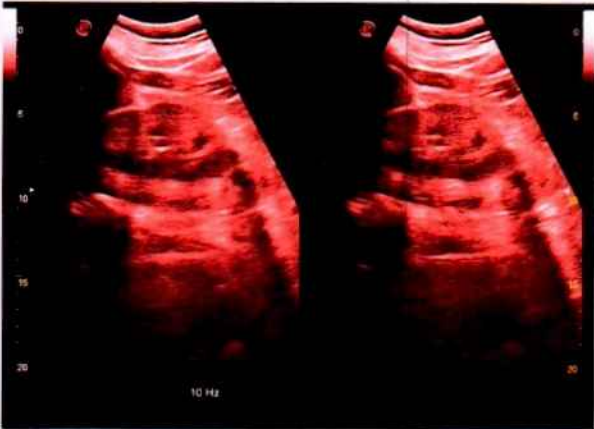


SHASHI KUMAR SINHA 37Y/M,F

25 11 2023 09:41:51 AM

TEI D 211 mm XM C2-
PRC 19/2/35 PRS 4

D1
110.8 mm

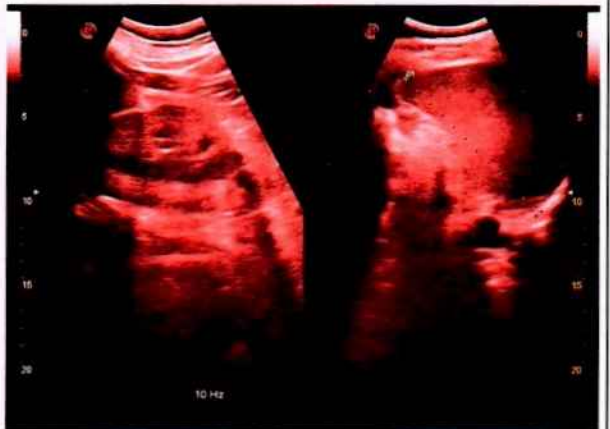

SHASHI KUMAR SINHA 37Y/M,F

25 11 2023 09:41:51 AM

TEI D 211 mm XM C2-
PRC 19/2/35 PRS 4

D1
110.8 mm



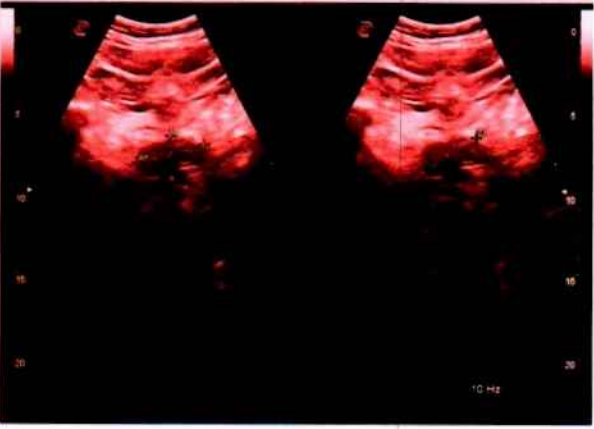
SHASHI KUMAR SINHA 37Y/M,F

25 11 2023 09:41:51 AM

TEI D 211 mm XM C2-
PRC 19/2/35 PRS 4

Bi-Volume

D1
25.2 mm
D2
40.6 mm
D3
38.0 mm
V
20.4 ml





PANACEA HOSPITAL



A shelter for many hearts A Home for many lives

(An ISO 9001:2008 Certified Organisation)
Lab Attached with CMC Under EQAS Scheme

Dept. of Radiodiagnosis - 32 Slice CT Scan, 3D/4D USG, 2D ECHO, Colour Doppler, Intervention Procedures, Digital X-Ray

PATIENT'S NAME : SINHA SHASHI KUMAR
REF. BY : Dr. ASHUTOSH MISHRA

AGE/SEX: 35 Y/M
DATE: 25/11/2023

X-RAY CHEST PA

BOTH LUNG FIELDS AND PLEURAE:

Lung fields show hazy opacities in both parahilar basal zone with mild prominent bronchopulmonary marking finding suggestive of MILD BRONCHITIS.

Right & left hila are normal

There is no evidence of any fluid in the both the pleural cavities.

Both domes of diaphragms are normal in position.

MEDIASTINUM:

Trachea is central in position.

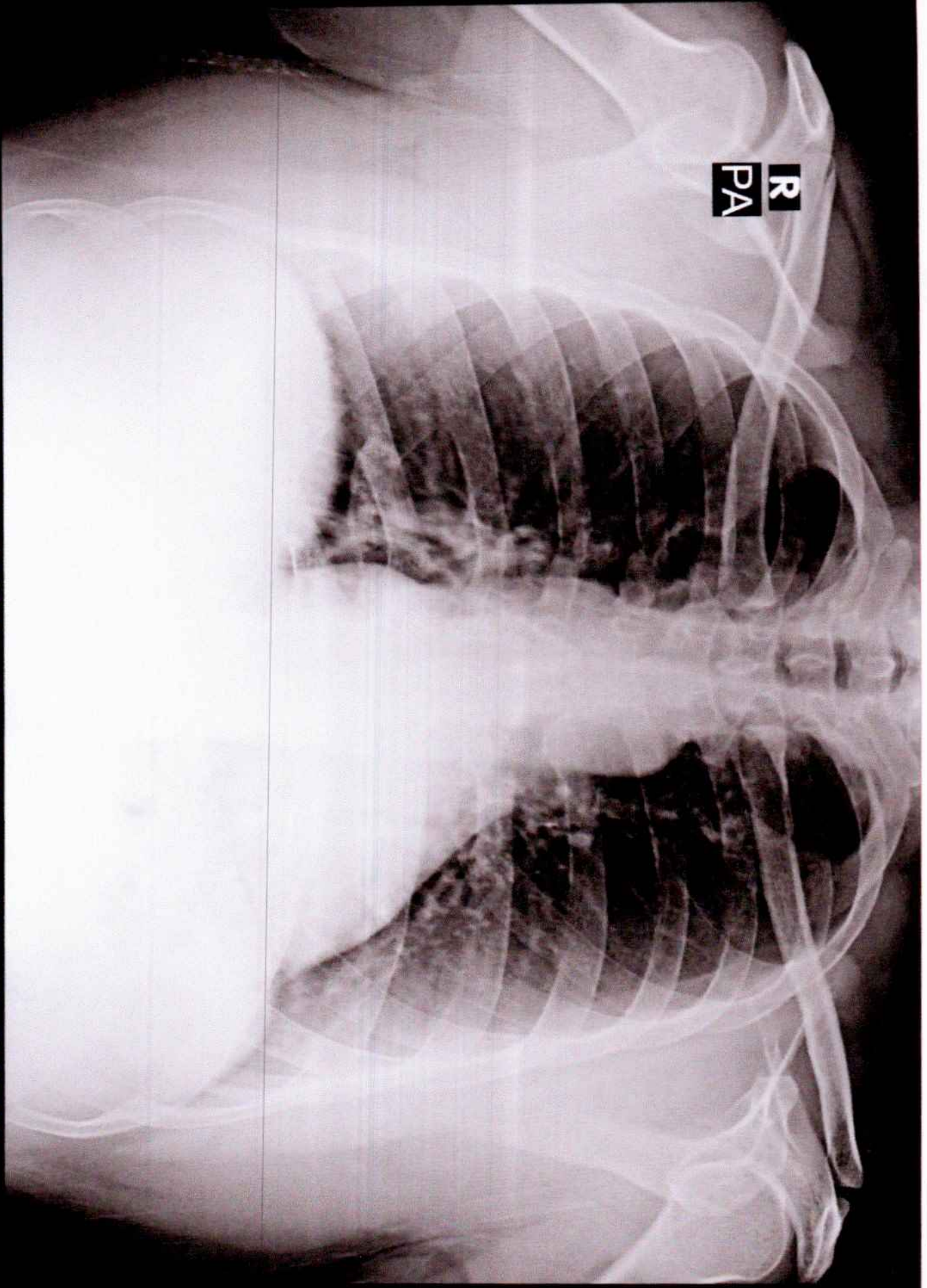
No evidence of pericardial effusion.

No significant lymphadenopathy is seen.

Visualized skeleton is normal.


Radiologist

Dr. Rahul Kumar Tiwari
MBBS, MD (Radio Diagono)
Reg. No. 57557



R
PA

SINHA SHASHI KUMAR 35Y/M 4230 M CHEST P.A. 25-NOV-23 09:58 AM

PANACEA HOSPITAL, KABIR NAGAR, DURGAKUND, VARANASI