



Aakriti Labs

3, Mahatma Gandhi Marg, Gandhi Nagar Mod,
Tonk Road, Jaipur (Raj.) Ph.: 0141-2710661
www.aakritilabs.com
CIN No. U85195RJ2004PTC019563

NAME	MR NISHANT VIJAY	AGE	38Y	SEX	MALE
REF BY	MEDIWHEEL	DATE	10/12/2022	REG NO	

ECHOCARDIOGRAM REPORT

WINDOW- POOR/ADEQUATE/GOODVALVE

MITRAL	NORMAL	TRICUSPID	NORMAL
AORTIC	NORMAL	PULMONARY	NORMAL

2D/M-MOD

IVSD mm	9.5	IVSS mm	14.9	AORTA mm	23.3
LVID mm	40.6	LVIS mm	24.7	LA mm	22.7
LVPWD mm	8.8	LVPWS mm	12.5	EF%	60%

CHAMBERS

LA	NORMAL	RA	NORMAL
LV	NORMAL	RV	NORMAL
PERICARDIUM	NORMAL		

DOPPLER STUDY MITRAL

PEAK VELOCITY m/s E/A	1.04/0.92	PEAK GRADIANT MmHg	
MEAN VELOCITY m/s		MEAN GRADIANT MmHg	
MVA cm2 (PLANIMETERY)		MVA cm2 (PHT)	
MR			

AORTIC

PEAK VELOCITY m/s	1.74	PEAK GRADIANT MmHg	
MEAN VELOCITY m/s		MEAN GRADIANT MmHg	
AR			

TRICUSPID

PEAK VELOCITY m/s	00.79	PEAK GRADIANT MmHg	
MEAN VELOCITY m/s		MEAN GRADIANT MmHg	
TR		PASP mmHg	

PULMONARY

PEAK VELOCITY m/s	1.42	PEAK GRADIANT MmHg	
MEAN VELOCITY m/s		MEAN GRADIANT MmHg	
PR		RVEDP mmHg	

IMPRESSION

- NORMAL LV SYSTOLIC & DIASTOLIC FUNCTION
- NO RWMA LVEF 60%
- NORMAL RV FUNCTION
- NORMAL CHAMBER DIMENSIONS
- NORMAL VALVULAR ECHO
- INTACT IAS / IVS
- NO THROMBUS, NO VEGETATION, NORMAL PERICARDIUM.
- IVC NORMAL

CONCLUSION : FAIR LV FUNCTION.

Cardiologist



Aakriti Labs

3, Mahatma Gandhi Marg, Gandhi Nagar Mod,
Tonk Road, Jaipur (Raj.) Ph.: 0141-2710661
www.aakritilabs.com
CIN No. U85195RJ2004PTC019563

PATIENT NAME: MR NISHANT VIJAY	AGE & SEX: 38Y/MALE
REF. By: MEDIWHEEL	DATE: 10/12/2022

REPORT: DIGITAL X-RAY CHEST PA VIEW

Soft tissue shadow and bony cages are normal.

Trachea is central.

Bilateral lung field and both CP angle is clear.

Domes of diaphragm are normally placed.

Transverse diameter of heart appear with normal limits.

IMPRESSION:- NO OBVIOUS ABNORMALITY DETECTED.

wellness
partner

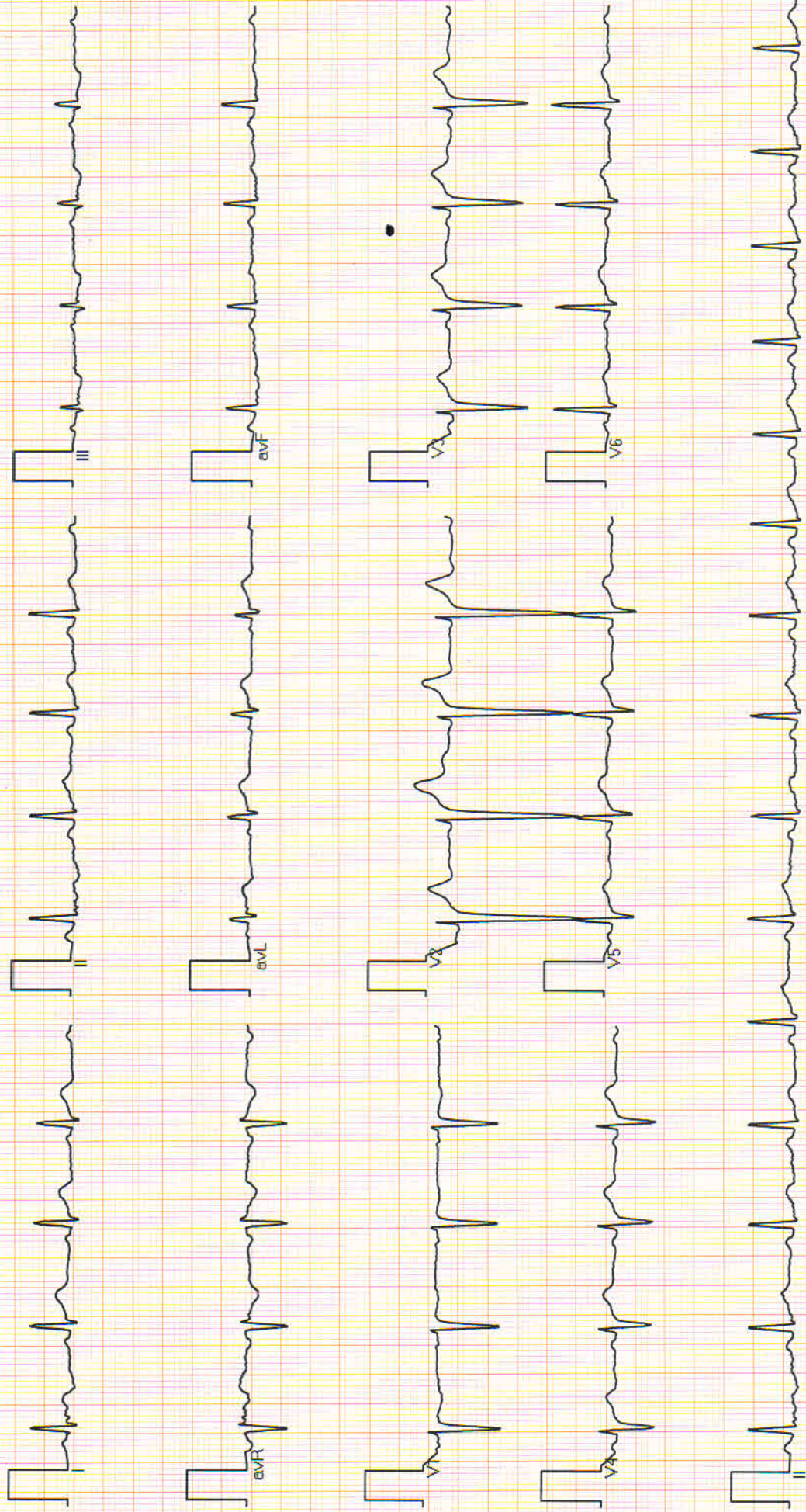
DR. NEERA MEHTA
MBBS, DMRD

AAKRITI LABS PVT.LTD JAIPUR

47828 / MR NISHANT VIJAY / 38 Yrs / M / Non Smoker

Heart Rate : 89 bpm / Tested On : 10-Dec-22 11:19:50 / HF 0.05 Hz - LF 100 Hz / Notch 50 Hz / Sn 1.00 Cm/mV / Sw 25 mm/s
/ Refd By : MEDI WHEEL

ECG



Vent Rate : 89 bpm
 PR Interval : 122 ms
 QRS Duration: 90 ms
 QT/QTc Int : 348/399 ms
 P-QRS-T axis: 61.00 • 40.00 • 5.00 •

Allengers ECG (Pisces)(PIS215190517)

DR. NISHANT VIJAY
 B.S. MD
 PISCES
 Reported By: - 02233319



Name : Mr. NISHANT VIJAY

Age/Gender: 38 Y/Male

Patient ID : 012212100019

BarcodeNo : 10070086

Referred By : Self

Registration No: 48015

Registered : 10/Dec/2022 09:02AM

Analysed : 11/Dec/2022 11:24AM

Reported : 11/Dec/2022 11:24AM

Panel : MEDI WHEEL (ARCOFEMI HEALTHCARE LTD)

USG: WHOLE ABDOMEN (Male)

LIVER : Is normal in size, shape and echogenicity.

The IHBR and hepatic radicals are not dilated.

No evidence of focal echopoor/echorich lesion seen.

Portal vein diameter and common bile duct appear normal.

GALL : Is normal in size, shape and echotexture. Walls are smooth and

BLADDER regular with normal thickness. There is no evidence of cholelithiasis.

PANCREAS : Is normal in size, shape and echotexture. Pancreatic duct is not dilated.

SPLEEN : Is normal in size, shape and echogenicity. Splenic hilum is not dilated.

KIDNEYS : Right Kidney:-Size: 91 x 39 mm, Left Kidney:-Size: 87 x 41 mm.

Bilateral Kidneys are normal in size, shape and echotexture,

corticomedullary differentiation is fair and ratio appears normal.

Pelvi calyceal system is normal. No evidence of hydronephrosis/ nephrolithiasis.

URINARY : Bladder walls are smooth, regular and normal thickness.

BLADDER : No evidence of mass or stone in bladder lumen.

PROSTATE : Is normal in size, shape and echotexture,

measures: 33 x 28 x 26 mm, wt: 13 gms.

Its capsule is intact and no evidence of focal lesion.

SPECIFIC : No evidence of retroperitoneal mass or free fluid seen in peritoneal cavity.

No evidence of lymphadenopathy or mass lesion in retroperitoneum.

Visualized bowel loop appear normal. Great vessels appear normal.

IMPRESSION :- NORMAL STUDY.



Dr. Neera Mehta
M.B.B.S., D.M.R.D.
RMCNO.005807/14853