

CID# : 2208525474
Name : MRS.KAVITA THITE
Age / Gender : 38 Years/Female
Consulting Dr. :-
Reg.Location : Lulla Nagar, Pune (Main Centre)

SID# : 177805060796
Registered : 26-Mar-2022 / 09:42
Collected : 26-Mar-2022 / 09:42
Reported : 26-Mar-2022 / 14:48
Printed : 28-Mar-2022 / 11:41

PHYSICAL EXAMINATION REPORT

a) Diet : Veg

b)Addiction : No

GENERAL EXAMINATION :

a)Height (cms) : 162

b)Weight (kgs) : 86

c)Lymph Nodes : Not Palpable

3) SYSTEMIC EXAMINATION

A) RESPIRATORY SYSTEM

a) Lungs : Clear

b) Trachea : Central

c) Air Entry : Equal

d) Rales : No

d) Others : NAD

B) CARDIOVASCULAR SYSTEM (CVS)

a) Heart Sounds : S1 S2 Normal

b) Murmurs : No

c) Pulse/min : 82

d) B/P (mm of Hg) : 130/80

e) Miscellenous : NAD

PUNE LAB ADDRESS: Seraph Centre, Opp. BSNL Exchange, Shahu College Road, Off Pune-Satara Road, Behind Panchami Hotel, Pune - 411009

CENTRAL PROCESSING LAB: 2nd Floor, Aston, Sundervan Complex, Above Mercedes Showroom, Andheri West, Mumbai - 400053

HEALTHLINE - MUMBAI: 022-6170-0000 | **OTHER CITIES:** 1800-266-4343 | **For Feedback** - customerservice@suburbandiagnosics.com | www.suburbandiagnosics.com

Brief Disclaimer: (1)Suburban Diagnostics ensures that the tests are conducted with utmost care and safety and are performed on samples received as per the sample collection guide of Suburban Diagnostics.(2)Sample may be rejected if unacceptable for the requested tests.(3)Test results may vary from laboratory to laboratory and also in some parameters from time to time for the same patient.(4)Report must not be copied in part, only in full.(5)This report is not valid for medico-legal purposes.(6)Patient information or data will not be communicated to a third party except in the case of a notifiable disease to a Public Care Unit.(7)Suburban Diagnostics reserves the right to subcontract samples to other laboratories as required.(8)Suburban Diagnostics is not liable for any penalties or liabilities arising out of or relating in any way to these services and/or content or information provided herein.(9) For the elaborated disclaimer, please turn

CID# : 2208525474
Name : MRS.KAVITA THITE
Age / Gender : 38 Years/Female
Consulting Dr. :-
Reg.Location : Lulla Nagar, Pune (Main Centre)

SID# : 177805060796
Registered : 26-Mar-2022 / 09:42
Collected : 26-Mar-2022 / 09:42
Reported : 26-Mar-2022 / 14:48
Printed : 28-Mar-2022 / 11:41

C) ABDOMEN

- a) Liver : Not Palpable
- b) Spleen : Not Palpable
- c) Any other Swelling : No


D) NERVOUS SYSTEM

- a) Ankle Reflex : Normal
- b) Plantars : Flexor

DOCTOR REMARKS :

Overweight
Hb: 38.7
fatty liver
-) Daily 30min walking

*** End Of Report ***



Dr. Milind Shinde
MBBS, DNB, Consuling Physician,
Diabetologist & Echocardiologist

PUNE LAB ADDRESS: Seraph Centre, Opp. BSNL Exchange, Shahu College Road, Off Pune-Satara Road, Behind Panchami Hotel, Pune - 411009

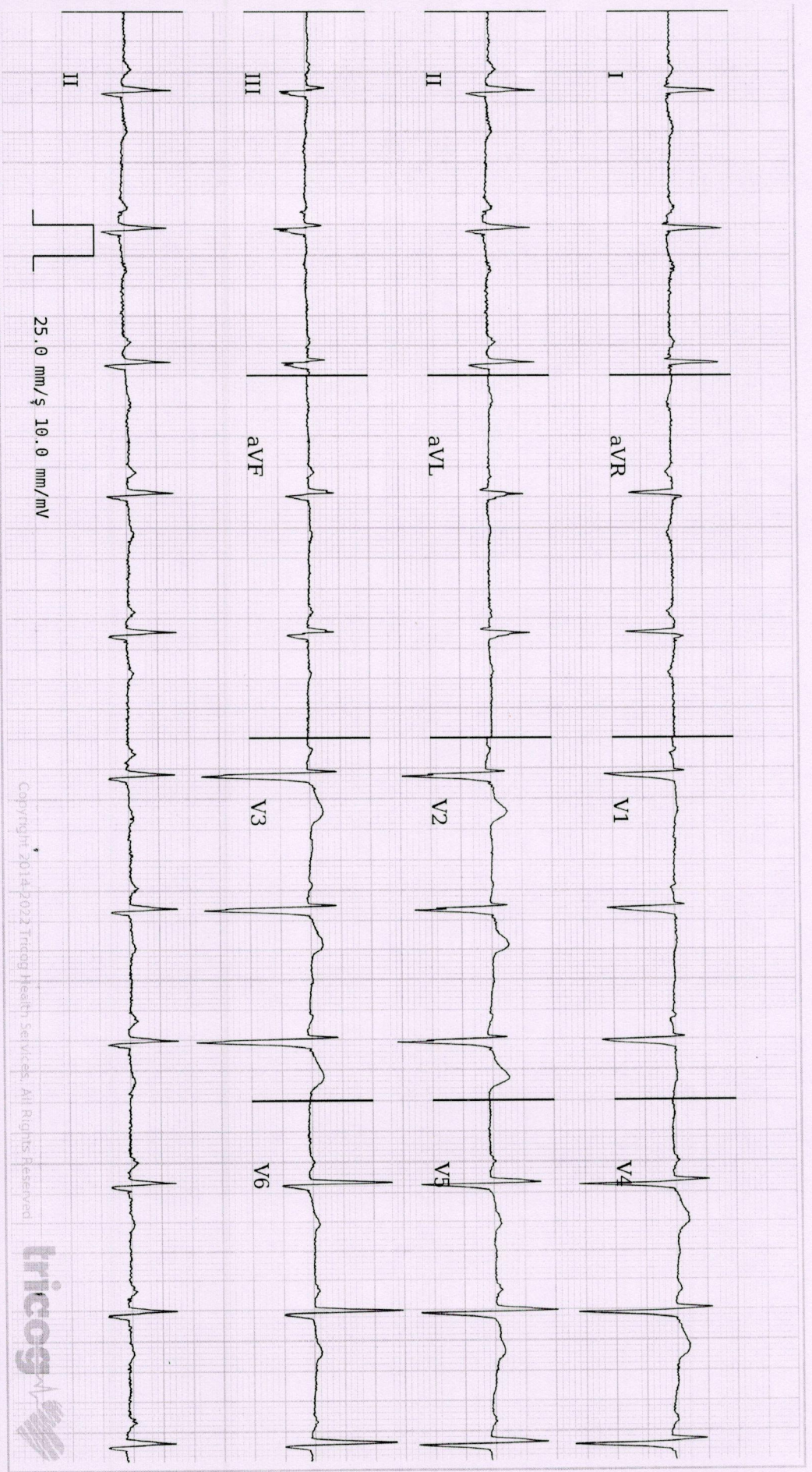
CENTRAL PROCESSING LAB: 2nd Floor, Aston, Sundervan Complex, Above Mercedes Showroom, Andheri West, Mumbai - 400053

HEALTHLINE - MUMBAI: 022-6170-0000 | **OTHER CITIES:** 1800-266-4343 | **For Feedback -** customerservice@suburbandiagnosics.com | www.suburbandiagnosics.com

Brief Disclaimer: (1)Suburban Diagnostics ensures that the tests are conducted with utmost care and safety and are performed on samples received as per the sample collection guide of Suburban Diagnostics.(2)Sample may be rejected if unacceptable for the requested tests. (3)Test results may vary from laboratory to laboratory and also in some parameters from time to time for the same patient.(4)Report must not be copied in part, only in full.(5)This report is not valid for medico-legal purposes.(6)Patient information or data will not be communicated to a third party except in the case of a notifiable disease to a Public Care Unit.(7)Suburban Diagnostics reserves the right to subcontract samples to other laboratories as required.(8)Suburban Diagnostics is not liable for any penalties or liabilities arising out of or relating in any way to these services and/or content or information provided herein.(9) For the elaborated disclaimer, please turn

Patient Name: **KAVITA THITE**
Patient ID: **2208525474**

Date and Time: **26th Mar 22 11:05 AM**



Copyright © 2014-2023 Tridrog Health Services. All Rights Reserved



Age **38** **7** **17**
years months days

Gender **Female**

Heart Rate **67bpm**

Patient Vitals

BP: **130/80 mmHg**

Weight: **86 kg**

Height: **162 cm**

Pulse: **NA**

Spo2: **NA**

Resp: **NA**

Others:

Measurements

QSRD: **88ms**

QT: **384ms**

QTc: **405ms**


PR: **148ms**

P-R-T: **46° 12° 18°**

REPORTED BY

[Signature]

Dr. Milind Shinde
MBBS, DNB Medicine
2011/05/1544



ECG Within Normal Limits: Sinus Rhythm, Normal Axis. Please correlate clinically.

Disclaimer: 1) Analysis in this report is based on ECG alone and should be used as an adjunct to clinical history, symptoms, and results of other invasive and non-invasive tests and must be interpreted by a qualified physician. 2) Patient vitals are as entered by the clinician and not derived from the ECG.

CID#	: 2208525474	SID#	: 177805060796
Name	: MRS.KAVITA THITE	Registered	: 26-Mar-2022 / 09:42
Age / Gender	: 38 Years/Female	Collected	: 26-Mar-2022 / 09:42
Consulting Dr.	: -	Reported	: 26-Mar-2022 / 12:36
Reg.Location	: Lulla Nagar, Pune (Main Centre)	Printed	: 26-Mar-2022 / 12:39

USG WHOLE ABDOMEN

LIVER : The liver is normal in size, shape and smooth margins. **It shows raised parenchymal echo pattern.**The intra hepatic biliary and portal radical appear normal. No evidence of any intra hepatic cystic or solid lesion seen.The main portal vein and CBD appears normal.

GALL BLADDER : The gall bladder is physiologically distended. The visualized gall bladder appears normal. No evidence of pericholecystic fluid is seen.

PANCREAS : The pancreas is well visualised and appears normal. No evidence of solid or cystic mass lesion is noted.

KIDNEYS :Both the kidneys are normal in size, shape and echotexture. No evidence of any calculus, hydronephrosis or mass lesion seen.

SPLEEN : The spleen is normal in size, shape and echotexture. No evidence of focal lesion is noted.

URINARY BLADDER : The urinary bladder is well distended. It shows thin walls and sharp mucosa. No evidence of calculus is noted. No mass or diverticulum is seen.

UTERUS : The uterus is anteverted and appears normal. No obvious focal lesion. The endometrial thickness is normal.

OVARIES : Both the ovaries are well visualised and appears normal. There is no evidence of any ovarian or adnexal mass seen.

PUNE LAB ADDRESS: Seraph Centre, Opp. BSNL Exchange, Shahu College Road, Off Pune-Satara Road, Behind Panchami Hotel, Pune - 411009

CENTRAL PROCESSING LAB: 2nd Floor, Aston, Sundervan Complex, Above Mercedes Showroom, Andheri West, Mumbai - 400053

HEALTHLINE - MUMBAI: 022-6170-0000 | **OTHER CITIES:** 1800-266-4343 | **For Feedback -** customerservice@suburbandiagnosics.com | www.suburbandiagnosics.com

CID#	: 2208525474	SID#	: 177805060796
Name	: MRS.KAVITA THITE	Registered	: 26-Mar-2022 / 09:42
Age / Gender	: 38 Years/Female	Collected	: 26-Mar-2022 / 09:42
Consulting Dr.	: -	Reported	: 26-Mar-2022 / 12:36
Reg.Location	: Lulla Nagar, Pune (Main Centre)	Printed	: 26-Mar-2022 / 12:39


Visualized small bowel loops appear non-dilated. Gaseous distension of large bowel loops. There is no evidence of any lymphadenopathy or ascitis.

IMPRESSION :

Ø Fatty liver.

Advice - Clinical and lab correlation.

*** End Of Report ***



Dr. Navid Shattari
MD, DNB, Radio-Diagnosis Reg No.
2015/05/2742

CID#	: 2208525474	SID#	: 177805060796
Name	: MRS.KAVITA THITE	Registered	: 26-Mar-2022 / 09:42
Age / Gender	: 38 Years/Female	Collected	: 26-Mar-2022 / 09:42
Consulting Dr.	: -	Reported	: 26-Mar-2022 / 12:43
Reg.Location	: Lulla Nagar, Pune (Main Centre)	Printed	: 26-Mar-2022 / 12:46

X-RAY CHEST PA VIEW

Prominent bronchovascular markings are noted.

No obvious consolidation/cavitation.

The cardiothoracic ratio is maintained.


The domes of the diaphragm are normal.

The cardio and costophrenic angles are clear.

Bony thorax is normal.

Advice - Clinical and lab correlation.

*** End Of Report ***



Dr. Navid Shattari
MD, DNB, Radio-Diagnosis Reg No.
2015/05/2742