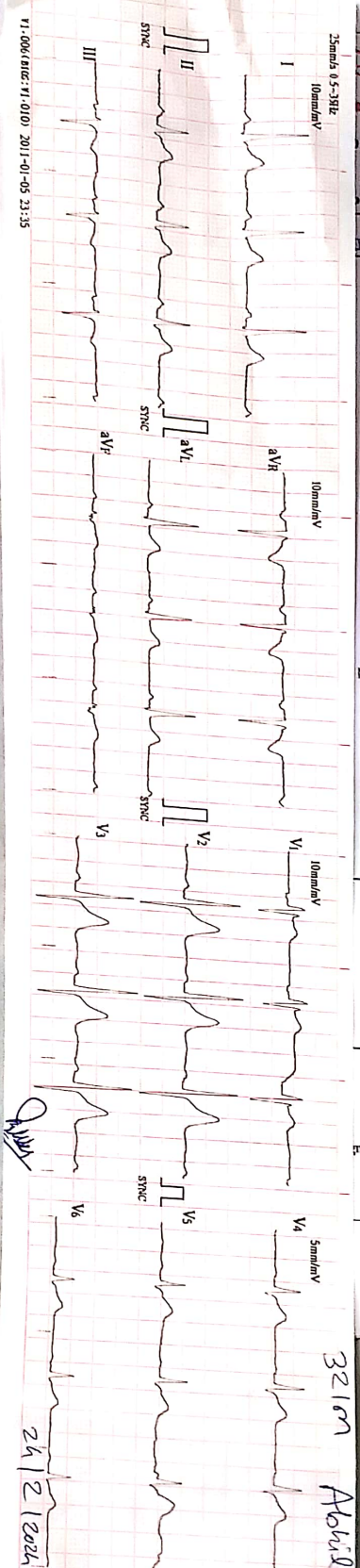

32101  
 Abhishek  
 Iyer  
 HR : 69  
 R-R : 861  
 P-R : 175  
 QRS : 112  
 QT/QTc : 453/488  
 P/QRS/T : 23/-2/8  
 HV5/SVI : 1.190/0.690 mV  
 HV5/STI : 1.880 mV

Strains: None  
 Dr. Krish P Vaidya  
 MBBS  
 MD  
 DGPCC  
 Associate Consultant: Cardiology  
 Reg. No. G-50510

24 | 2 | 2024  
 Incontinent report verified by:



# Heart & General Clinic

Icure Heart & Diet Clinic, 402, Epsilon tower, opp Pasha bhal park, Race course, Vadodar

## :: PERSONAL HEALTH REPORT ::

Abhilash Jyee		11/26/2024
		SR. NO.
		SEX. Male
		AGE 32 Year
		HEIGHT 176 CM
		WEIGHT 95KG.

### HISTORY

Present History : NO  
 Past Illness History : NO Diabetes/Hypertension/Tuberculosis/Asthma/Epilepsy  
 Past Occupational History : NO  
 Family History : Father HT  
 Personal History : NO  
 Addiction : Tobacco/Gutkha/Smoking/Alcohol 1 pouch/day since 2018

### GENERAL EXAMINATION

T.P.R. : 70/min B.P. : 124/80 mm Hg :

Pallor/Icterus/Cyanosis/Varicosity/Lymph Nodes/Thyroid/Oedema/NVE/Other :

### SYSTEMIC EXAMINATION

R.S. : MAD  
 C.V.S : MAD  
 C.N.S : MAD  
 A.S. : MAD  
 Musculo-skelet System : MAD

E.N.T. Ex. MAD	ACUITY OF VISION		RT EYE -S	LT EYE -S
	Without Glass	DISTANT	6/	6/
With Glass		DISTANT	6/ 6	6/ 6
	Dental Ex. MAD	Near	6/	6/
Skin Ex. MAD		Near	6/ 6	6/ 6
	Psychic Ex. MAD	COLOUR BLINDNESS MAD		

### REMARK

### ADVICE


The Worker is FIT/UNFIT for the assigned job.




Dr. Krish P. Vaidya  
 MD, PG, CCC  
 Associate Consultant-Cardiology  
 Reg. No. G-50510

DR. KRISH VAIDYA


MD G-50510, CIH

 भारत सरकार  
GOVERNMENT OF INDIA

 आशीष अभिलश सुब्रमानी  
Iyer Abhilash Subramaniam  
जन्म तिथि / DOB : 30/06/1991  
पुरुष / MALE


9196 9070 4510

भेदा आधार, भेदी पहचान

 बैंक ऑफ बरोडा  
Bank of Baroda  
India's International Bank

नाम  
Name आशीष अभिलश सुब्र. IYER ABHILASH S.

कार्यकारी अङ्क सं.  
E.C. No. 160370

 आशीष अभिलश सुब्रमानी  
Signature Holder's



  
**Heart & General Clinic**

**301 Trivia complex, near Natubhai circle, Racecourse Road**

**Name** : ABHILASH IYER  
**Ref By** : ICURE HEART & DIET CLINIC

**Age/Sex** : 32 Yrs./M  
**Date** : 24/02/2024  
**Report ID.** : 8

**HAEMOGRAM PROFILE**

<u>TEST</u>	<u>RESULT</u>	<u>UNIT</u>	<u>METHOD</u>	<u>REFERENCE INTERVAL</u>
<b><u>BLOOD COUNTS &amp; INDICES</u></b>				
Haemoglobin	: 14.40	gm%		13.5 - 17.0 gm%
Total RBC	: 5.00	mill/cmm		4.6 - 6.2 mill/cmm
PCV	: <b>37.00</b>	%		40 - 54 %
MCV	: <b>74.00</b>	fL		80 - 96 fL
MCH	: 28.80	pg		27 - 31 pg
MCHC	: <b>38.91</b>	%		32 - 36 %
RDW	: 14.00	%		10 - 15 %
Total WBC	: 8,300	/cmm		4,000 - 11,000/cmm
Platelet Count	: 3,12,000	/cmm		1.5 - 4.0 Lac/cmm.
<b><u>DIFFERENTIAL LEUCOCYTES COUNT</u></b>				
Band Cells	: 00	%		00 - 06 %
Neutrophils	: 60	%		55 - 70 %
Lymphocytes	: 39	%		20 - 40 %
Eosinophils	: <b>00</b>	%		01 - 06 %
Monocytes	: <b>01</b>	%		02 - 08 %
Basophils	: 00	%		00 - 01 %
Platelet In Smear	: ADEQUATE			
<b><u>ERYTHROCYTES SEDIMENTATION RATE</u></b>				
ESR After 1st Hour	: <b>10</b>	mm	Westergren	01 - 07 mm
Blood Group	: " A "			
Rh Factor (Anti D.)	: " POSITIVE "			

*(By Fully Automated Cell Counter Sysmex KK - 21, Japan)*

END OF REPORT

  
**Heart & General Clinic**

**301 Trivia complex, near Natubhai circle, Racecourse Road**

**Name** : ABHILASH IYER  
**Ref By** : ICURE HEART & DIET CLINIC

**Age/Sex** : 32 Yrs./M  
**Date** : 24/02/2024  
**Report ID.** : 8

**BIOCHEMISTRY**

<u>TEST</u>	<u>RESULT</u>	<u>UNIT</u>	<u>REFERENCE INTERVAL</u>
Blood Urea	: 31.00	mg/dL	10 - 50 mg/dL
Blood Urea Nitrogen - BUN	: 14.50	mg/dL	4.5 - 19.0 mg/dL
Serum Creatinine	: 0.77	mg/dL	0.6 - 1.4 mg/dL
Serum Uric Acid	: 4.99	mg/dL	3.4 - 7.0 mg/dL
<b><u>SERUM PROTEIN</u></b>			
Serum Protein Total	: 7.50	g/dL	6.6 - 8.3 g/dL
Albumin	: 4.50	g/dL	3.5 - 5.0 g/dL
Globulin	: 3.00	g/dL	2.3 - 3.5 g/dL
A/G Ratio	: 1.5	: 1	1.5 - 2.5 : 1
Bilirubin - Total	: 0.4	mg/dL	0.00 - 1.00 mg/dL
Bilirubin - Direct	: 0.2	mg/dL	Upto 0.30 mg/dL
Bilirubin - Indirect	: 0.2	mg/dL	0.1 - 1.0 mg/dL
SGPT	: 19.0	IU/L	10 - 40 IU/L
SGOT	: 27.0	IU/L	Upto 40 IU/L
Serum Alkaline Phosphatase	: 81.0	U/L	37 - 147 U/L
<b><u>FASTING (FBS)</u></b>			
Blood Glucose	: 102.0	mg/dL	70 - 110 mg/dL
<b><u>POST-PRANDIAL</u></b>			
Blood Glucose	: 108.0	mg/dL	80 - 140 mg/dL
<b><u>SPECIAL TESTS</u></b>			
GGTP	: 18	U/L	05 - 85 U/L
Gamma Glutamyltransferase			

*Done By Fully Auto Analyzer MIURA, A-1004*

END OF REPORT

**301 Trivia complex, near Natubhai circle, Racecourse Road**

**Name** : ABHILASH IYER  
**Ref By** : ICURE HEART & DIET CLINIC

**Age/Sex** : 32 Yrs./M  
**Date** : 24/02/2024  
**Report ID.** : 8

**LIPID PROFILE**

<u>TEST</u>	<u>RESULT</u>	<u>UNIT</u>	<u>REFERENCE INTERVAL</u>
Total Lipid (Calculated)	: 503	mg/dL	350 - 750 mg/dL
Serum Cholesterol	: 142.0	mg/dL	130 - 200 mg/dL
Serum Triglyceride	: 123.0	mg/dL	60 - 165 mg/dL
HDL Cholesterol	: 46.0	mg/dL	30 - 70 mg/dL
LDL Cholesterol	: 71.4	mg/dL	Upto 150 mg/dL
LDL Cholesterol - Direct	: 118.9	mg/dL	Upto 150 mg/dL
CHOL./HDL Chol. Ratio	: 3.08	: 1	Less than 5
LDL Chol/HDL Chol Ratio	: 1.55	: 1	Less than 3.5
VLDL (Calculated)	: 24.60	mg/dL	Upto 30 mg/dL

**Hb A1C REPORT**

Hb A1C - Glycated Hb Glycated Haemoglobin	: 5.0	%	Non Diabetic : 4.3 - 6.3 % Good Control : 6.4 - 7.5 % Moderate Control : 7.5 - 9.0 % Poor Control : 9.0 % & Above
Avg. Blood Glucose Level	: 101	mg/dL	
Estimated Average Glucose eAG	: 97	mg%	

END OF REPORT



**301 Trivia complex, near Natubhai circle, Racecourse Road**

**Name** : ABHILASH IYER  
**Ref By** : ICURE HEART & DIET CLINIC

**Age/Sex** : 32 Yrs./M  
**Date** : 24/02/2024  
**Report ID.** : 8

**EXAMINATION OF URINE**

<u>TEST</u>	<u>RESULT</u>	<u>UNIT</u>
Sample	: FASTING	
<b><u>PHYSICAL EXAMINATION</u></b>		
Quantity	: 10	mL
Colour	: COLOURLESS	
Transperancy	: CLEAR	
Specific Gravity	: 1.003	
Reaction	: ACIDIC	
Deposits	: ABSENT	
<b><u>CHEMICAL EXAMINATION</u></b>		
Albumin	: NIL	
Sugar	: NIL	
Acetone	: ABSENT	
Bile Salts	: ABSENT	
Bile Pigments	: ABSENT	
Urobilinogen	: NORMAL : ~ < 1.0 mg/dL	
Occult Blood	: ABSENT	
Nitrate	: ABSENT	
<b><u>MICROSCOPIC EXAMINATION</u></b>		
Pus Cells	: 0-1 / hpf	
RBC	: NIL	
Epithelial Cells	: NIL	
Crystals	: NIL	
Amorphous Phosphate	: NIL	
Cast	: NIL	

**THYROID FUNCTIONS**

Total Triiodothyronine - T3	: 1.00	ng/mL	0.58 - 1.59 ng/mL
Total Thyroxine - T4	: 8.90	ng/mL	4.87 - 11.72 microgram%
Thyroid Stl. Hormone -TSH	: 3.50	ng/mL	0.35 - 4.94 IU/mL

END OF REPORT



# Echocardiography & Color Doppler Report

Patient Name: Abhilash Iyaer

Date: 24/02/2024

Age/ Gender: 32/Male

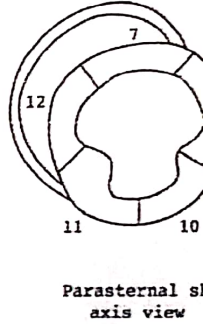
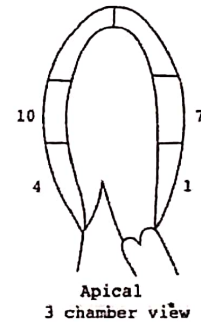
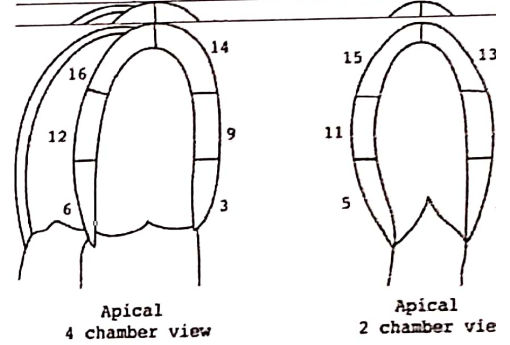
LA	30	IVS	10	PWD	11
AO	25	LVDs	27	LVDd	45

**M.**

**Mode**

**Study:**


Mitral Valve	E: 0.75 A:0.58
Aortic Valve	Normal
Tricuspid Valve	Normal
Pulmonary Valve	Normal



**Doppler Study:**

**Conclusion:**

- LV Function: Normal LV Systolic Function
- LVEF: 60%
- RWMA: No RWMA at Rest
- Cardiac Chambers: Normal
- Diastolic function: Grade I LVDD
- TR: No PAH: No      RVSP: 20mmhg
- MR/ MS: No
- AR/ AS: No
- ASD/VSD/PDA/Co-A: No
- No clot or vegetation seen
- IVC: 14mm &>50% collapsing with Respiration





# PARAMOUNT DIAGNOSTIC & RESEARCH CENTRE

(A Unit of Paramount Charly Trust)

Radiology ■ Pathology ■ Histopathology ■ Molecular Biology

NAME : ABHILASH IYER

AGE : 32 Y/M

DATE : 24/02/2024

## ULTRASOUND WHOLE ABDOMEN

**Liver** is normal in size and shows raised parenchymal reflectivity. No focal lesion is seen. Hepatic veins appear normal. There is no evidence of any dilated intra hepatic billiary radicals.

**Portal Vein** appears normal in diameter. **Common Bile Duct** is of normal diameter.

**Gallbladder** is distended with normal wall thickness. There is no evidence of gallstones. No evidence of peri-cholecystic fluid or probe tenderness.

**Pancreas** is normal in size and shows homogenous reflectivity. There is no evidence of any calcification or ductal dilatation.

**Spleen** is normal size and shows a homogenous echotexture. There is no evidence of any focal lesion.

**Both Kidneys** are normal in position and size. They show normal cortical reflectivity and cortico-medullary distinction. Right kidney measures 104 x 42 mm. Left kidney measures 103 x 46 mm. There is no evidence of renal calculi, hydronephrosis or mass seen.

**Bladder** is distended and shows normal wall thickness. No evidence of intra-luminal mass or calculi.

**Prostate gland** is normal in size. It has smooth outlines and normal reflectivity. Estimated volume is around 14.5 cc.

There is no evidence of ascites.

No evidence of any gross bowel dilatation seen.

No evidence of any aorto-caval or mesenteric root lymphadenopathy.

No mass or collection in right iliac fossa.

### CONCLUSION:

- Grade I fatty liver.



**DR. HENY GANDHI**  
**CONSULTANT RADIOLOGIST**

24 hours Emergency Service Available for CT Scan / MRI / Pathology **AMBULANCE SERVICE AVAILABLE**

**Main Branch:** Paramount Complex, Gotri Road, Race Course, Vadodara, Ph. : 0265-2395772, 2397438, 6647222, +91 - 6352731483,  
Path. Lab : 0265 - 8803900/901/902/903, +91 - 8160226911, +91 - 9099066029

**City Branch:** Opp. Brahman Sabha Hall, Pratap Road, Dandlabazar, Vadodara. Ph.: 0265 - 2423233, +91 - 6352734810



# PARAMOUNT DIAGNOSTIC & RESEARCH CENTRE

(A Unit of Paramount Charity Trust)

Radiology ■ Pathology ■ Histopathology ■ Molecular Biology

NAME : ABHILASH IYER

AGE : 32 Y/M

DATE : 24/02/2024

## X RAY CHEST (PA)

### OBSERVATIONS:

Both the lung fields and apices appear clear.

Both the hilar shadow appears normal.

Cardiac silhouette appears normal.

Both the costophrenic sinuses are clear.

Mediastinal and tracheal shadows are normal.

Both the domes of diaphragm are normal.

Visualized rib cage and clavicle are normal.

### COMMENTS:

No significant abnormality is seen.



DR. HENY GANDHI  
CONSULTANT RADIOLOGIST



24 hours Emergency Service Available for CT Scan / MRI / Pathology **AMBULANCE SERVICE AVAILABLE**

Main Branch: Paramount Complex, Gotri Road, Race Course, Vadodara, Ph. : 0265-2395772, 2397438, 6647222, +91 - 6352731483,  
Path. Lab : 0265 - 6603900/901/902/903, +91 - 8160225911, +91 - 9099066029

City Branch: Opp. Brahman Sabha Hall, Pratap Road, Dandlabazar, Vadodara. Ph.: 0265 - 2423233, +91 - 8352734810

