

MYSORE-BALLAL CIRCLE



--- A MEDALL COMPANY ---

CUSTOMER CHECKLIST

Date 25-Mar-2023 9:18 AM


Customer Name : MRS.POOJA O N

DOB : 28 Oct 1990

Ref Dr Name : MediWheel

Age : 32Y/FEMALE

Customer Id : MED111551700



Visit ID : 712309945

MED111551700

Email Id :

Phone

: 8310265194

No

Corp Name : MediWheel

Address :

Package Name : Mediwheel Full Body Health Checkup Female Below 40

H --- 154cm
 W --- 66 kg
 BP --- 110/78
 Pulse --- 85
 Ht --- 37 in
 Wgt --- 30 in

S.No	Modality	Study	Accession No	Time	Seq	Signature
1	LAB	BLOOD UREA NITROGEN (BUN)				
2	LAB	GLUCOSE - FASTING				
3	LAB	GLUCOSE - POSTPRANDIAL (2 HRS)				
4	LAB	GLYCOSYLATED HAEMOGLOBIN (HbA1c)				
5	LAB	LIPID PROFILE				
6	LAB	LIVER FUNCTION TEST (LFT)				
7	LAB	URIC ACID				
8	LAB	URINE GLUCOSE - FASTING				
9	LAB	URINE GLUCOSE - POSTPRANDIAL (2 Hrs)				
10	LAB	COMPLETE BLOOD COUNT WITH ESR				
11	LAB	THYROID PROFILE/ TFT(T3, T4, TSH)				
12	LAB	STOOL ANALYSIS - ROUTINE				

BPM

Patient Details Print Page

3		URINE ROUTINE			
LAB		CREATININE ✓			
LAB		BLOOD GROUP & RH TYPE (Forward Reverse) ✓			
6	LAB	BUN/CREATININE RATIO ✓			
17	OTHERS	physical examination	MYS2777115102651		
18	US	ULTRASOUND ABDOMEN ✓	MYS2777115103462		
19	OTHERS	Treadmill / 2D Echo	MYS2777115127528		Monday Peddy
20	OTHERS	EYE CHECKUP ✓	MYS2777115135592		
21	X-RAY	X RAY CHEST ✓	MYS2777115145199		
22	OTHERS	Consultation Physician	MYS2777115148004		
23	ECHO	ELECTROCARDIOGRAM ECG ✓	MYS2777115149333		

Registered By

(SOWMYA.RAJU)

Customer Name	MRS.POOJA O N	Customer ID	MED111551700
Age & Gender	32Y/FEMALE	Visit Date	25/03/2023
Ref Doctor	MediWheel		

ABDOMINO-PELVIC ULTRASONOGRAPHY

LIVER is normal in shape, size and has uniform echopattern.
No evidence of focal lesion or intrahepatic biliary ductal dilatation.
Hepatic and portal vein radicals are normal.

GALL BLADDER show normal shape and has clear contents.
Gall bladder wall is of normal thickness. CBD is of normal calibre.

PANCREAS has normal shape, size and uniform echopattern.
No evidence of ductal dilatation or calcification.

SPLEEN show normal shape, size and echopattern.

KIDNEYS move well with respiration and have normal shape, size and echopattern.
Cortico- medullary differentiations are well madeout.
No evidence of calculus or hydronephrosis.

	Bipolar length (cms)	Parenchymal thickness (cms)
Right Kidney	10.1	1.8
Left Kidney	10.3	2.0

URINARY BLADDER show normal shape and wall thickness.
It has clear contents.

UTERUS is anteverted and has normal shape and size. It has uniform myometrial echopattern.
Endometrial echo is of normal thickness 4.5 mms.
Uterus measures as follows: LS: 6.2cms AP: 4.1cms TS: 4.3cms.

OVARIES:

Simple cyst measuring 3.4 x 2.8cm is noted in the right adnexa. No evidence of septations / solid component.

Right ovary is not separately seen.

Left ovary is normal size, shape and echotexture measures: 2.8 x 2.2cms
POD & adnexa are free.

No evidence of ascites.

IMPRESSION:

➤ **RIGHT OVARIAN SIMPLE CYST.**

CONSULTANT RADIOLOGISTS

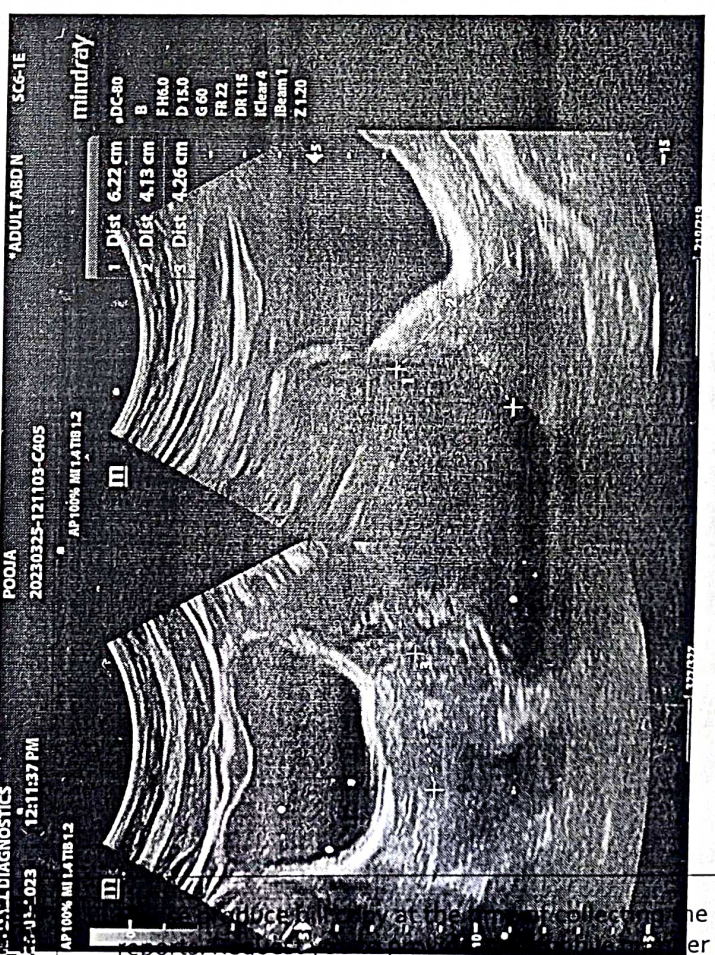
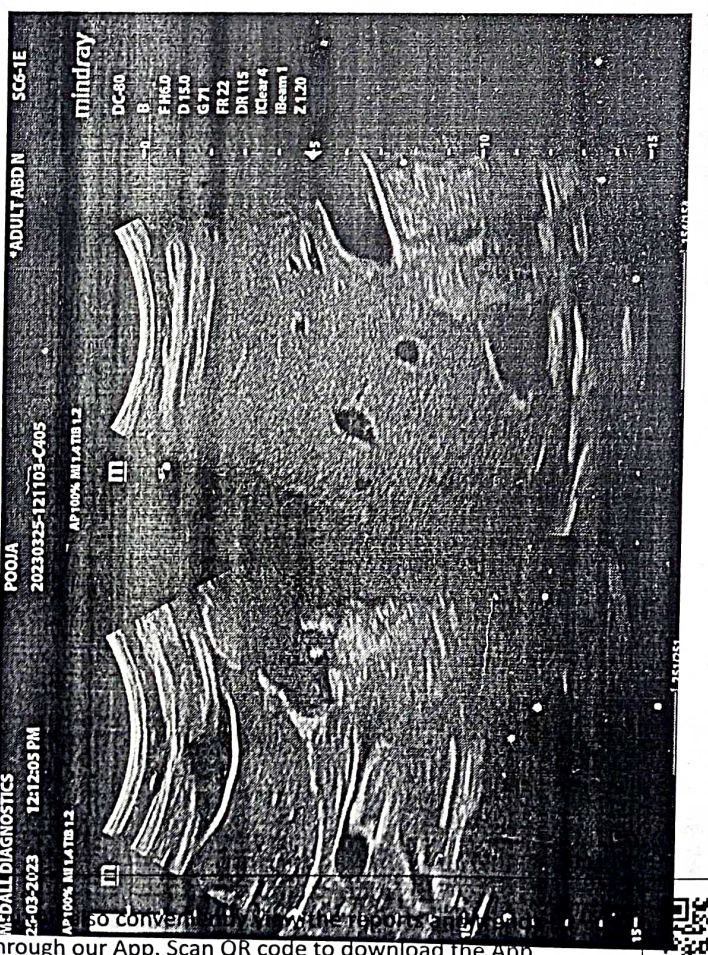
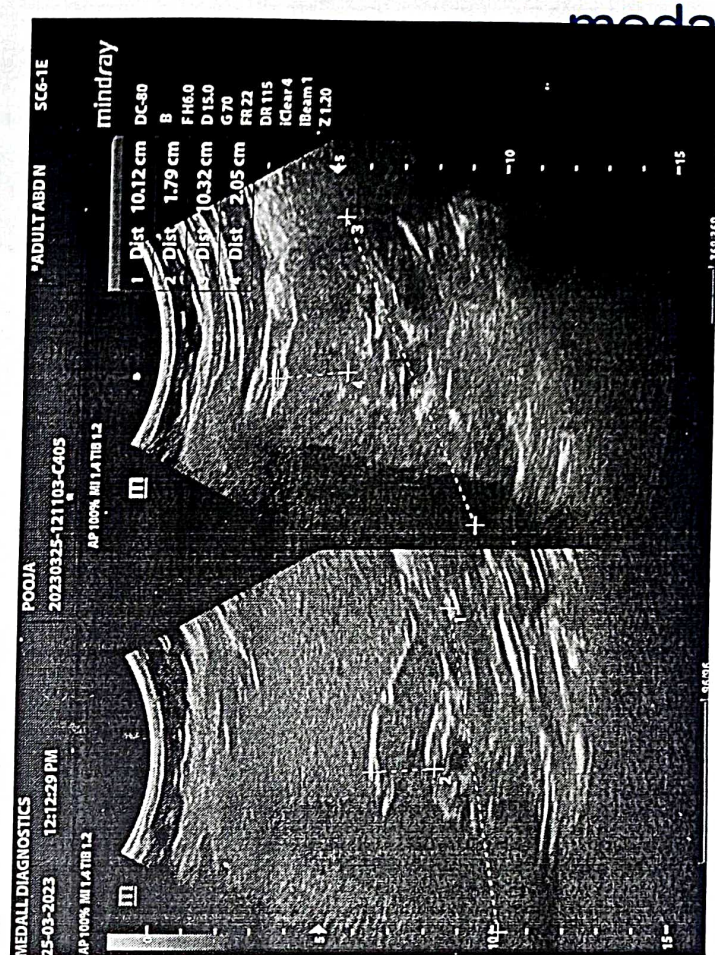
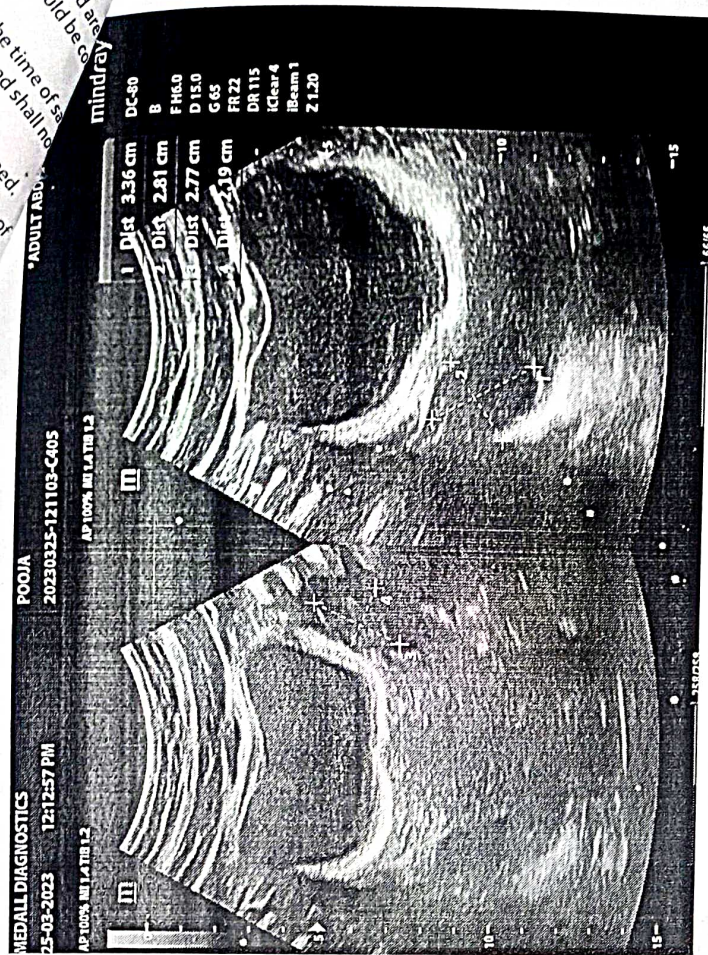
DR. ANITHA ADARSH
MB/MS



DR. MOHAN B



ions indicated are
 at the time of sa
 ntative and shall no
 ed or named,
 procedure of



through our App. Scan QR code to download the App.



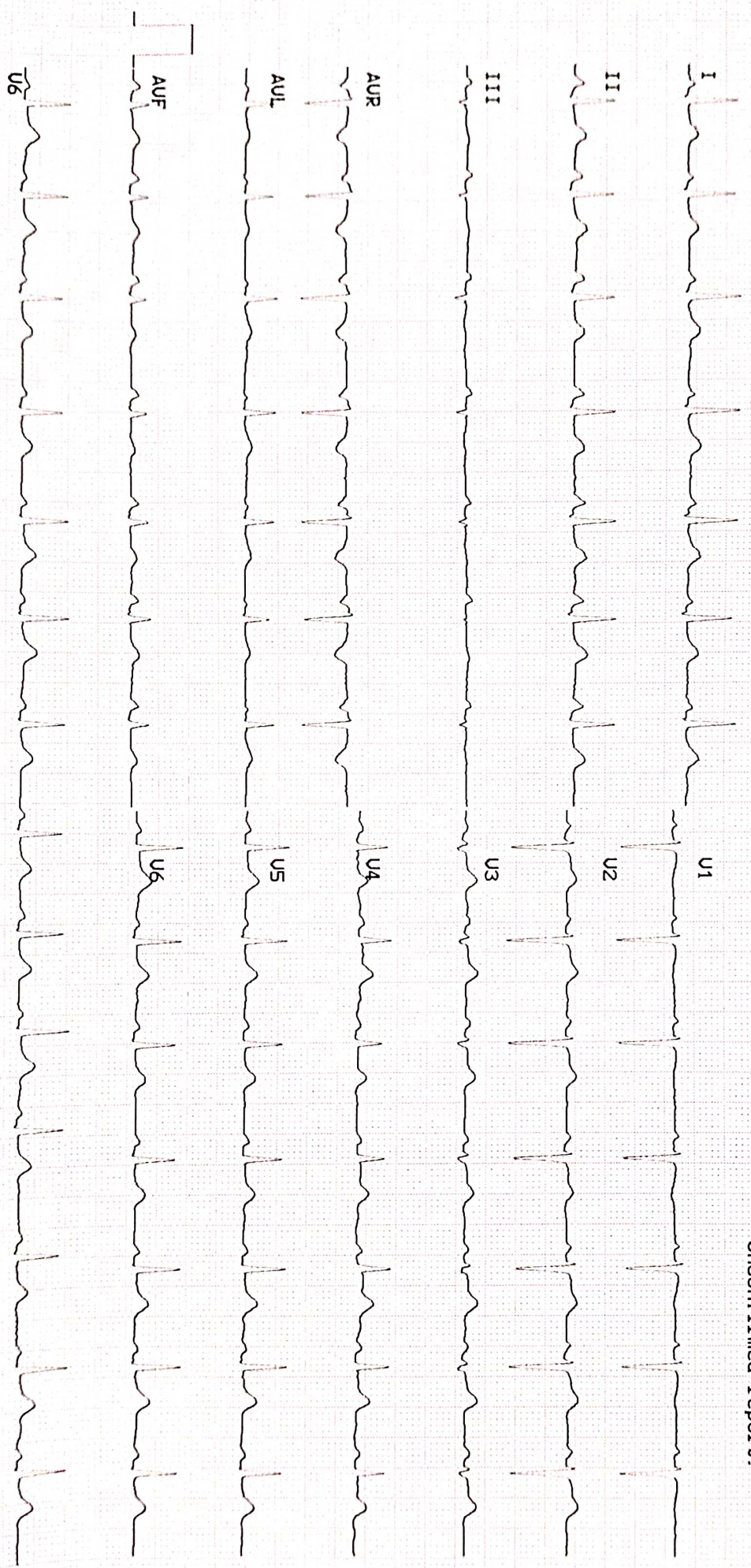

customer id during your subsequent visits.

Male

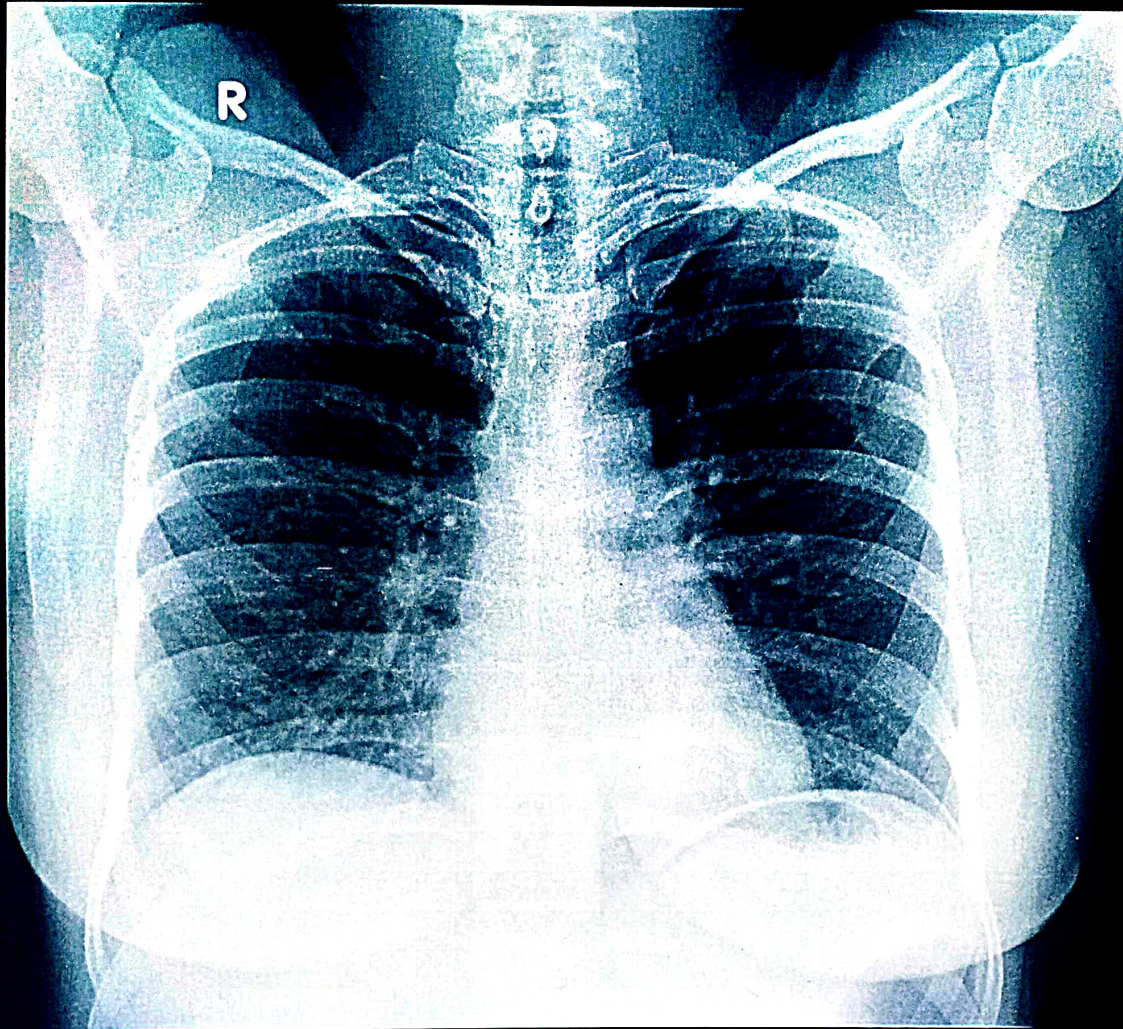
AGE: 32

Measurement Results:

QRS	:	84 ms
QT/QTcB	:	366 / 436 ms
PR	:	128 ms
P	:	100 ms
RR/PP	:	704 / 690 ms
P/QRS/T	:	55 / 25 / 35 degrees
QTd/QTcBD	:	18 / 21 ms
Sokolow	:	1.6 mV
NK	:	12



Unconfirmed report.



POOJA O N 32 MED111551700 F CHEST PA 3/25/2023 12:16 PM
MEDALL CLUMAX DIAGNOSTIC



W

MEDALL

NETHRADHAMA SUPER SPECIALITY EYE HOSPITAL

(A Unit of Nethradhama Hospitals Pvt. Ltd.)

OPD SHEET

Date: 25/03/2023

Patient's Name: Mrs. Pooja D.N.

OP No. 1238949

32/F

3:50 PM

Dr. Varsha Uday K

Came for medical certificate.

A/S: BE k clear. Ac Vh₂ pupil RRR,
lens clear.IOP < 15
15 mm HgBCVA < 6/6, N₆
6/6, N₆Fundus: BE CDR 0.2, HNRR, Macula R₀Colour V_n - BE WNL.

Adv: R/A 1 year / SOS