



A.L.C. Advance Imaging Dignostics

ISO 9001:2015 Certified center

(A Unit of P.K.Arogyam Health & Wellness Center)

E-95, P.C. Colony, Near Sai Netryalaya Transformer, Kankarbagh, Patna - 20

✉ alcdiagnostics@gmail.com

🌐 www.alhealthcheckup.in

☎ 7050037694, 8271206196

OPINION MUST BE CORRELATES WITH CLINICALLY & OTHER INVESTIGATION FOR FINAL DIAGNOSIS. NOT FOR MEDICO LEGAL PURPOSE

Pt. Name :- EKTA RANJAN
Ref. By :- DR. / MEDIWHEEL

Date:- 13-Jun-21
Age / Sex -30 Yrs. F.

Report of x- ray Chest (PA)

Thanks for your referral

Evidence of fibrous opacities seen in Rt. And Lt. mid zone and hilar zone
Both Cp angle are clear
Cardiac size is seen normal
Bony cage are seen normal

Consultant Radiologist

ESTB BY:-

Dr. P. K. Tiwari

MD, BRIT (Radio Imaging)
Consultant Imagionologist

Dr. S. Kumar

MD (Pat)
Consultant Pathologist

Dr. Abhishek Kumar

MBBS, MD
Consultant Neuropatho Physiologist

Dr. Anjali

MBBS, MD
Consultant(TMT,EEG Specialist)

Dr. Kumari Suman

MBBS, DGO, MD
Consultant (TVS & HSG Specialist)

12/06/2021 12:45:48
ALC ADVANCE IMAGING DIAGNOSTICS
E95 PC COLONY KANKARBAGH PATNA

EKTA RANJAN
FEMALE


CASE: 1
AGE: 30Y 05M 23D
64Cms 62Kg

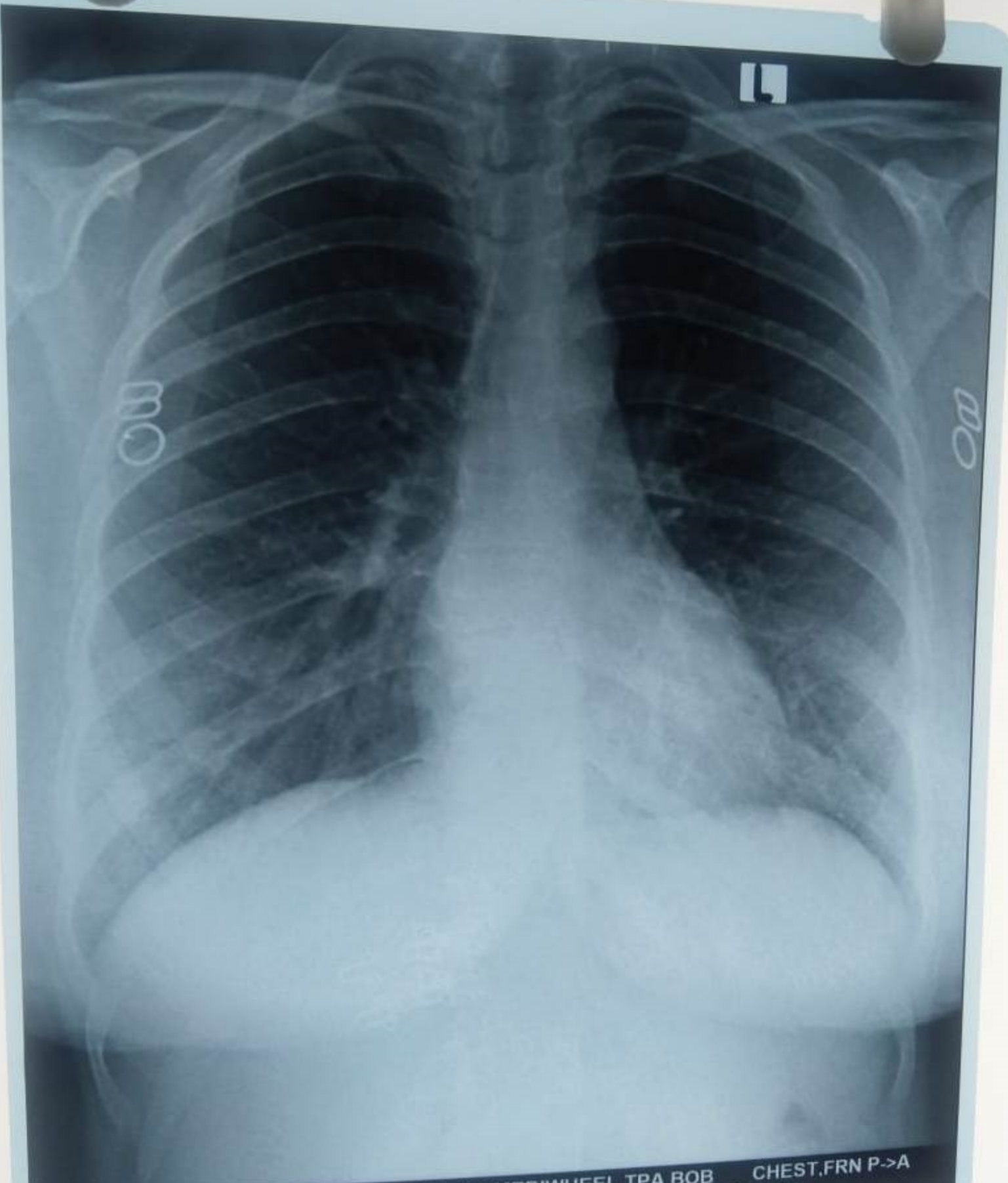
HR : 65 bpm SINUS RHYTHM
PR : 922 ms SHORT PR INTERVAL
QT : 102 ms INFERIOR T WAVE ABNORMALITY IS NONSPECIFIC
QTc : 78 ms
QTc : 402 ms
QTc : 411 ms

-AXIS : -29°
AS : 45°
c : -04°

REF: DR. MEDI WHEEL TPA BOB REF: DR. ABHISHEK KUMAR MBBS MD

SL: REPORT FORMAT: 3x4+1L SQ





EKTA RANJAN AGE 30 YEARS 719 BY MEDIWHEEL TPA BOB CHEST,FRN P->A
A.L.C. Advance Imaging Dignostics Centre PATNA-20

 **ਬੈਂਕ ਭਾਰਤੀ**
Bank of Baroda



ਨਾਮ **EKTA RANJAN**
Name

ਕਾਰਜਕਾਰੀ ਕੋਡ ਨੰ. **74851**
E.C. NO.


Ekta Ranjan

ਘੋਸ਼ਣਕ ਦੇ ਹਸਤਾਖਰ
Signature of Holder


ਘੋਸ਼ਣਕਾਰੀ ਅਧਿਕਾਰੀ
Issuing Authority

 **ਭਾਰਤ ਸਰਕਾਰ**
GOVERNMENT OF INDIA



ਏਕਤਾ
Ekta

ਜਨਮ ਦਾ ਸਾਲ / Year of Birth : 1990
ਇਸਤਰੀ / Female



6825 2366 4367

ਆਧਾਰ - ਆਮ ਆਦਮੀ ਦਾ ਅਧਿਕਾਰ

- ਆਧਾਰ ਦੇਸ਼ ਭਰ ਵਿੱਚ ਪ੍ਰਵਾਨਤ ਹੈ।
- ਆਧਾਰ ਭਵਿੱਖ ਵਿੱਚ ਸਰਕਾਰੀ ਅਤੇ ਗੈਰ-ਸਰਕਾਰੀ ਸੇਵਾਵਾਂ ਦਾ ਲਾਭ ਚੁੱਕਣ ਲਈ ਸਹਾਈ ਹੋਵੇਗਾ।
- Aadhaar is valid throughout the country
- Aadhaar will be helpful in availing Government and Non-Government services in future.

5199643



ਭਾਰਤੀ ਵਿਲੱਖਣ ਪਛਾਣ ਅਥਾਰਿਟੀ
UNIQUE IDENTIFICATION AUTHORITY OF INDIA

ਪਤਾ:

D/O ਅਨਿਲ ਕੁਮਾਰ, ਮਕਾਨ ਨੰ . 73,
ਵਾਰਡ ਨੰ 14, ਨੇੜੇ ਬਸ਼ੀਰਪੁਰਾ, ਕਮਲ
ਵਿਹਾਰ, ਜਲੰਧਰ - 1, ਜਲੰਧਰ, ਪੰਜਾਬ,
144001

Address:

D/O Anil Kumar, H.NO. 73,
Ward NO 15, Near Bashirpura,
Kamal Vihar, Jalandhar - 1,
Jalandhar, Punjab, 144001



1947
1800 180 1947



help@uidai.gov.in



www.uidai.gov.in



P.O. Box No.1947,
Bengaluru-560 001



A.L.C. Advance Imaging Dignostics

ISO 9001:2015 Certified center

(A Unit of P.K.Arogyam Health & Wellness Center)

E-95, P.C. Colony, Near Sai Netryalaya Transformer, Kankarbagh, Patna - 20

alcdiagnostics@gmail.com

www.alhealthcheckup.in

7050037694, 8271206196

OPINION MUST BE CORRELATES WITH CLINICALLY & OTHER INVESTIGATION FOR FINAL DIAGNOSIS. NOT FOR MEDICO LEGAL PURPOSE

PATIENT NAME : Mrs. EKTA RANJAN PATIENT ID: 719
COL DATE : 12/06/2021 REPORTING DATE: 12/06/2021 AGE SEX : 30 YRS/F
REF.BY : DR. /MEDIWHEEL TPA B.O.B. BOOKING NO. bobE1219

TEST NAME	RESULT	Unit	REF.RANGE
BLOOD SUGAR (F)	99.0 mg/dl		70-110 mg/dl
BLOOD SUGAR (PP)	122.0 mg/dl		70-140 mg/dl

LIPID PROFILE:-

TOTAL CHOLESTROL	242.2 mg/dl		130-250 mg/dl
TRIGLYCERIDE	143.7 mg/dl		50-160 mg/dl
HDL CHOLESTROL	49.0 mg/dl		30- 60 mg/dl
LDL CHOLESTROL	164.5 mg/dl		80-130 mg/dl
VLDL CHOLESTROL	28.7 mg/dl		15-40 mg/dl
T.CH./HDL RATIO	4.9:1		
LDL./HDL RATIO	3.3:1		

ESTB BY:-

Dr. P. K. Tiwari
MD, BRIT (Radio Imaging)
Consultant Imagonologist

Dr. S. Kumar
MD (Pat)
Consultant Pathologist

Dr. Abhishek Kumar
MBBS, MD
Consultant Neuropatho Physiologist

Dr. Anjali
MBBS, MD
Consultant(TMT,EEG Specialist)

Dr. Kumari Suman
MBBS, DGO, MD
Consultant (TVS & HSG Specialist)


Consultant Radiologist



A.L.C. Advance Imaging Diagnostics

ISO 9001:2015 Certified center

(A Unit of P.K.Arogyam Health & Wellness Center)

E-95, P.C. Colony, Near Sai Netryalaya Transformer, Kankarbagh, Patna - 20

alcdiagnostics@gmail.com

www.alchealthcheckup.in

7050037694, 8271206196

OPINION MUST BE CORRELATES WITH CLINICALLY & OTHER INVESTIGATION FOR FINAL DIAGNOSIS. NOT FOR MEDICO LEGAL PURPOSE

PATIENT NAME : Mrs. EKTA RANJAN PATIENT ID: 719
COL DATE : 12/06/2021 REPORTING DATE: 12/06/2021 AGE SEX:- 30 YRS/F
REF.BY : DR./ MEDIWHEEL TPA B.O.B. BOOKING NO. bobE1219

TEST NAME	RESULT	Unit	REF.RANGE
ESR	8 mm/hr		<20 mm/hr
CBC			
Total W.B.C. Count	6400 /cumm		4000-11,000 /cumm
R B C COUNT	3.95 Million/ CUmm		4.-7 Million/ CUmm
Platelets count	1.67 Lakh/ cumm		1.5-5.0 Lakh/ cumm
Differential Count of W.B.C.			
Neutrophils	65 %		40-70%
Lymphocytes	30 %		25-40%
Eosinophils	04 %		01-05%
Mnonocytes	01 %		00-02%
Basophiles	00 %		00-0%
HAEMOGLOBIN	12.2 gm/dl (83.5 %)		14.6 gm/dl = 100%
PCV	37.4 %		35-47 %
MCV	94.8 fl		76-96 fl
MCH	31.0 pg		29-35 pg
MCHC	32.7 %		30-38 %

ESTB BY:-

Consultant Radiologist

Dr. P. K. Tiwari
MD, BRIT (Radio Imaging)
Consultant Imaginationologist

Dr. S. Kumar
MD (Pat)
Consultant Pathologist

Dr. Abhishek Kumar
MBBS, MD
Consultant Neuropatho Physiologist

Dr. Anjali
MBBS, MD
Consultant(TMT,EEG Specialist)

Dr. Kumari Suman
MBBS, DGO, MD
Consultant (TVS & HSG Specialist)

PRINTING MISTAKE SHOULD BE REPORTED BACK IMMEDIATELY/ यहाँ जन्म से पहले भुण का लिंग जाँच नहीं होता है ।



A.L.C. Advance Imaging Dignostics

ISO 9001:2015 Certified center

(A Unit of P.K.Arogyam Health & Wellness Center)

E-95, P.C. Colony, Near Sai Netryalaya Transformer, Kankarbagh, Patna - 20

alcdiagnostics@gmail.com

www.alchealthcheckup.in

7050037694, 8271206196

OPINION MUST BE CORRELATES WITH CLINICALLY & OTHER INVESTIGATION FOR FINAL DIAGNOSIS. NOT FOR MEDICO LEGAL PURPOSE

PATIENT NAME : Mrs. EKTA RANJAN

PATIENT ID: 719

COL DATE : 12/06/2021 REPORTING DATE: 12/06/2021 AGE SEX:- 30 YRS/F

REF.BY : DR. / MEDIWHEEL TPA B.O.B. BOOKING NO. bob E1219

TEST NAME	RESULT	Unit	REF.RANGE
-----------	--------	------	-----------

LFT:-

GGT	13.3 IU/l		8 - 38 IU/L
SGPT	14.0 IU/L		5 - 40 IU/L
SGOT	17.7 IU/L		5 - 40 IU/L
ALKALINE PHOSPHATASE	83.7 IU/L		25-147 IU/L
SERUM ALBUMIN	5.0 g/dl		3.5 --5.4 g/dl
SERIUM GLUBLINE	2.9 g/dl		2.3 -- 3.6 g/dl
AG RATIO	1.7 : 1		1.0—2.3 g/dl
BILIRUBIN			
TOTAL	0.6 mg/dl		0.1- 1.0mg/dl
DIRECT	0.2 mg/dl		0.0- 0.3mg/dl
INDIRECT	0.4 mg/dl		0.0- 0.7 mg/dl

KFT/RFT

URIC ACID	3.5 mg/dl		3.2—7.0 mg/dl
TOTAL PROTIN	7.9 g/dl		6.0--8.7 g/dl
SERUM CREATNINE	0.7 mg/dl		0.6-1.5 mg/dl
BLOOD UREA	28.6 mg/dl		5 - 45 mg/dl
BLOOD URIA NITROZEN(BUN).	13.3 mg/dl		13- 39 mg/dl
BUN/CREATININE RATIO	19.0:1		

ESTB BY:-

Dr. P. K. Tiwari
MD, BRIT (Radio Imaging)
Consultant Imagonologist

Dr. S. Kumar
MD (Pat)
Consultant Pathologist

Dr. Abhishek Kumar
MBBS, MD
Consultant Neuropatho Physiologist

Dr. Anjali
MBBS, MD
Consultant(TMT,EEG Specialist)

Dr. Kumari Suman
MBBS, DGO, MD
Consultant (TVS & HSG Specialist)


12/6/21
Consultant Radiologist



A.L.C. Advance Imaging Dignostics

ISO 9001:2015 Certified center

(A Unit of P.K.Arogyam Health & Wellness Center)

E-95, P.C. Colony, Near Sai Netryalaya Transformer, Kankarbagh, Patna - 20

alcdiagnostics@gmail.com

www.alchealthcheckup.in

7050037694, 8271206196

OPINION MUST BE CORRELATES WITH CLINICALLY & OTHER INVESTIGATION FOR FINAL DIAGNOSIS. NOT FOR MEDICO LEGAL PURPOSE

PATIENT NAME : Mrs. EKTA RANJAN

PATIENT ID: 719

COL DATE : 12/06/2021 REPORTING DATE: 12/06/2021 AGE SEX : 30 YRS/F

REF.BY : DR./ MEDIWHEEL TPA B.O.B

BOKING NO bobE1219.

GLYCOSYLATED HEMOGLOBIN

TEST NAME	RESULT	Unit	REF.RANGE
HbA1c	3.4 %		Below 5.7 % : Normal 5.7 – 6.4 % : Prediabetic > = 6.5 % : Diabetic
AVERAGE PLASMA GLUCOSE	91.6 mg/dl		90 – 120 mg/dl : Good Control 121 – 150 mg/dl : Fair Control 151- 180 mg/dl: Unsatisfactory Control >180 mg/dl : Poor Control

ESTB BY:-

Dr. P. K. Tiwari
MD, BRIT (Radio Imaging)
Consultant Imagonologist

Dr. S. Kumar
MD (Pat)
Consultant Pathologist

Dr. Abhishek Kumar
MBBS, MD
Consultant Neuropatho Physiologist

Dr. Anjali
MBBS, MD
Consultant(TMT,EEG Specialist)

Dr. Kumari Suman
MBBS, DGO, MD
Consultant (TVS & HSG Specialist)


Consultant Radiologist



A.L.C. Advance Imaging Dignostics

ISO 9001:2015 Certified center

(A Unit of P.K.Arogyam Health & Wellness Center)

E-95, P.C. Colony, Near Sai Netryalaya Transformer, Kankarbagh, Patna - 20

alcdiagnostics@gmail.com

www.alhealthcheckup.in

7050037694, 8271206196

OPINION MUST BE CORRELATES WITH CLINICALLY & OTHER INVESTIGATION FOR FINAL DIAGNOSIS. NOT FOR MEDICO LEGAL PURPOSE

PATIENT NAME : Mrs. EKTA RANJAN PATIENT ID: 719

COL DATE : 12/06/2021 REPORTING DATE: 12/06/2021 AGE SEX:- 30 YRS/F

REF.BY : DR. / MEDIWHEEL TPA B.O.B. BOOKING NO. bobE1219

TEST NAME	RESULT	Unit	REF.RANGE
-----------	--------	------	-----------

BLOOD GROUP	: 'A'		
-------------	-------	--	--

Rh Typing	: POSITIVE		
-----------	------------	--	--

Note: Do always cross – matching before blood transfusion

ESTB BY:-

Dr. P. K. Tiwari
MD, BRIT (Radio Imaging)
Consultant Imagonologist

Dr. S. Kumar
MD (Pat)
Consultant Pathologist

Dr. Abhishek Kumar
MBBS, MD
Consultant Neuropatho Physiologist

Dr. Anjali
MBBS, MD
Consultant(TMT,EEG Specialist)

Dr. Kumari Suman
MBBS, DGO, MD
Consultant (TVS & HSG Specialist)


Consultant Radiologist

PRINTING MISTAKE SHOULD BE REPORTED BACK IMMEDIATELY/ यहाँ जन्म से पहले भुण का लिंग जाँच नहीं होता है ।



A.L.C. Advance Imaging Diagnostics

ISO 9001:2015 Certified center

(A Unit of P.K.Arogyam Health & Wellness Center)

E-95, P.C. Colony, Near Sai Netryalaya Transformer, Kankarbagh, Patna - 20

alcdiagnostics@gmail.com

www.alhealthcheckup.in

7050037694, 8271206196

OPINION MUST BE CORRELATES WITH CLINICALLY & OTHER INVESTIGATION FOR FINAL DIAGNOSIS. NOT FOR MEDICO LEGAL PURPOSE

PATIENT NAME : Mrs. EKTA RANJAN

PATIENT ID: 719

COL DATE : 12/06/2021 REPORTING DATE: 12/06/2021 AGE SEX : 30 YRS/F

REF.BY : DR./ MEDIWHEEL TPA B.O.B. BOOKING NO. bobE1219

Investigation	Result	Normal Range
Total Triiodothyronin T3	141.97 μ ng/dl	70 -200 μ ng/dl
Total Thyroxin T4	10.22 μ ug/dl	4.8 -13.5 μ ug/dl
Serum TSH	1.86 μ U/ml	0.39 -6.16 μ U/ml

THYROID DISORDER (>: Increase: < Decrease: n Normal

1. T3(n) T4(n) TSH(n) :EUTHYROID STATE:
2. T3(>) T4(>) TSH(<): HYPERTHYROIDISM:
3. T3(<)T4(<) TSH(>): HYPOTHYROIDISM:
4. T3(n)T4(n) TSH(>) : SUB-CLINICAL HYPO-THYROIDISM:
5. T3(n)T4(n) TSH(<): SUB-CLINICAL HYPER-THYROIDISM:
6. T3(>) T4(n) TSH(<): T3 THYROTOXICOSIS:

Total T3/T4 level is dependent on Level:

So determination of free T3/T4is a better MARKER of Thyroid Function.

*FREE T3/T4 ESTIMATION FACILITY IS AVAILABALE ON REQUEST.:

12/6/21

Consultant Radiologist

ESTB BY:-

Dr. P. K. Tiwari
MD, BRIT (Radio Imaging)
Consultant Imagiologist

Dr. S. Kumar
MD (Pat)
Consultant Pathologist

Dr. Abhishek Kumar
MBBS, MD
Consultant Neuropatho Physiologist

Dr. Anjali
MBBS, MD
Consultant(TMT,EEG Specialist)

Dr. Kumari Suman
MBBS, DGO, MD
Consultant (TVS & HSG Specialist)



A.L.C. Advance Imaging Dignostics

ISO 9001:2015 Certified center

(A Unit of P.K.Arogyam Health & Wellness Center)

E-95, P.C. Colony, Near Sai Netryalaya Transformer, Kankarbagh, Patna - 20

alcdiagnostics@gmail.com

www.alchealthcheckup.in

7050037694, 8271206196

OPINION MUST BE CORRELATES WITH CLINICALLY & OTHER INVESTIGATION FOR FINAL DIAGNOSIS. NOT FOR MEDICO LEGAL PURPOSE

PATIENT NAME : Mrs . EKTA RANJAN PATIENT ID: 719
COL DATE : 12/06/2021 REPORTING DATE: 12/06/2021 AGE SEX:- 30 YRS/F
REF.BY : DR./MEDIWHEEL TPA B.O.B. BOOKING NO. bobE1219

ROUTINE EXAMINATION OF URINE

PHYSICAL EXAMINATION

Volume	10 ml
Colour	Straw
Appearance	Clear
Sediments	Nil
Specific Gravity	1.020

CHEMICAL EXAMINATION

PH	6.0
Reaction	ACIDIC
Sugar	NIL
Albumin	NIL
Phosphate....	Nil
Nitrite	Not done

MICROSCOPIC EXAMINATION

Erythrocytes....	Nil
Pus cells	1-4 / HPE
Epithelial Cells	A, Few
Other	Nil

ESTB BY:-

Dr. P. K. Tiwari

MD, BRIT (Radio Imaging)
Consultant Imaginationologist

Dr. S. Kumar

MD (Pat)
Consultant Pathologist

Dr. Abhishek Kumar

MBBS, MD
Consultant Neuropathology Physiologist

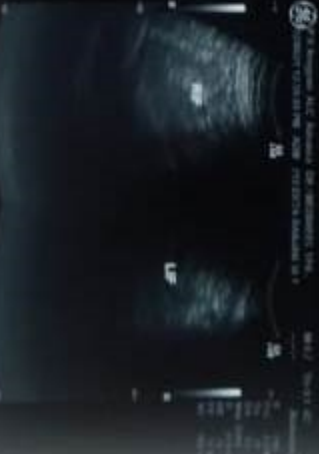
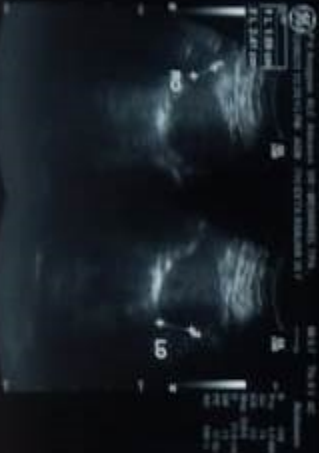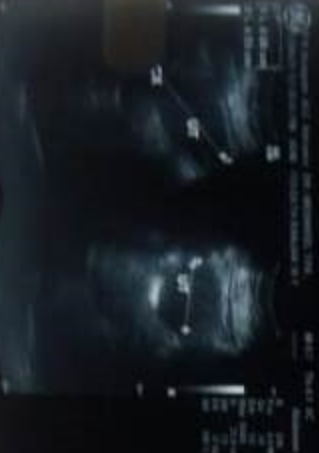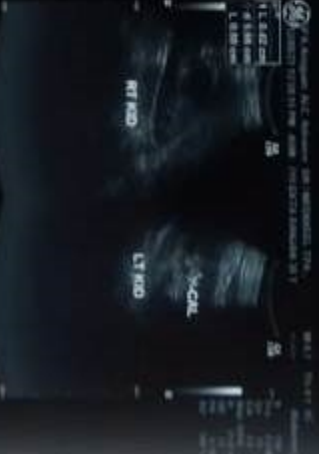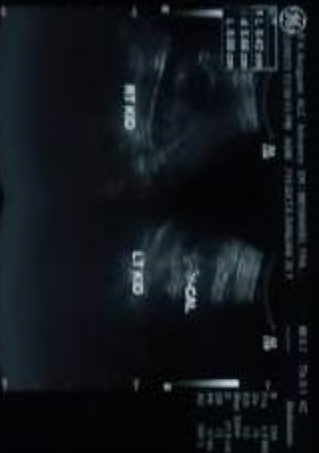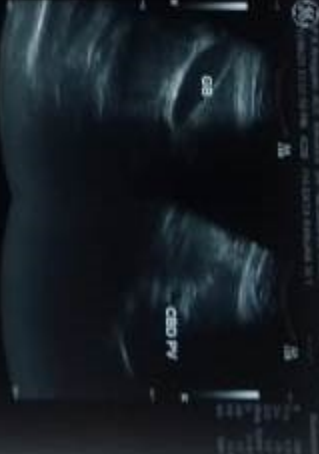Dr. Anjali

MBBS, MD
Consultant(TMT,EEG Specialist)

Dr. Kumari Suman

MBBS, DGO, MD
Consultant (TVS & HSG Specialist)

(Signature)
Consultant Radiologist





A.L.C. Advance Imaging Dignostics

ISO 9001:2015 Certified center

(A Unit of P.K.Arogyam Health & Wellness Center)

E-95, P.C. Colony, Near Sai Netryalaya Transformer, Kankarbagh, Patna - 20

alcdiagnostics@gmail.com

www.alhealthcheckup.in

7050037694, 8271206196

OPINION MUST BE CORRELATES WITH CLINICALLY & OTHER INVESTIGATION FOR FINAL DIAGNOSIS. NOT FOR MEDICO LEGAL PURPOSE

Pt. Name :- **EKTA RANJAN**
Ref. By :- **DR. / MEDIWHEEL**

Date:- **13-Jun-21**
Age / Sex – **30 Yrs. F.**

REAL TIME U.S.G. OF WHOLE ABDOMEN

Thanks for your kind referral

(Report.)

- LIVER** :- Measures 13.55 cm. Normal in shape , size and echo texture .I.H.B.R. are not dilated. Hepatic veins are normal. No SOL seen.
- G.BL.** :- Lumen is echo free. Wall thickness appears normal.
- C.B.D.** :- Measures 3.5 mm in diameter with echo free lumen. No calculi or mass seen.
- P.V.** :- Measures 7.1 mm in diameter. Appears normal. No thrombus seen.
- PANCREAS** :- Normal in shape, size and echo texture. No calcification mass seen.
- SPLEEN** :- Measures 9.07 cm. Normal in shape, size and echo texture. No SOL seen.
- KIDNEY** :- **Both kidney shows normal shape, size & echo texture. C.M.D.intact. P.C.S.is not dilated. A small calculi measures 4 mm approx seen at mid pole Lt Kidney No cyst or hydronephrosis seen on either side.**
Right Kidney :- Measures 9.27 x 4.2 cm.
Left Kidney :- Measures 10.25 x 4.5 cm.
- URETER** :- Not dilated .No apparent calculi seen.
- U.BLADDER**:- Shows normal in outline with echo free lumen. No calculi or mass seen.
Pre void 24ml. Post void – is in significant
- UTERUS** :- Is normal in size, shape & position measuring 8.88 x 8.8 cm. Endometrial And Myometeriam appears normal in limits No focal mass lesion seen
- ADNEXA** :- Both ovary appears normal in size and shape.
Rt Ovary Measures – 3.10 cm Lt Ovary Measures 2.30 cm
- P.O.D** :- No collection seen in P.O.D.
- R.I.F.** :- Son graphically no appendicular mass or collection seen.
- R.I.F.** :- Son graphically no appendicular mass or collection seen.
- OTHERS** :- **Excess Gasses bowel distention seen in Abdomen .No Ascites No Lymph Adenopathy. No pleural Effusion seen on either side .**

IMPRESSION

- **Small Lt Renal Calculi**
- **Excess Gasses Bowel Distention Seen In Abdomen .**
Otherwise son graphically normal scan. of rest organs

Consultant Radiologist

ESTB BY:-

Dr. P. K. Tiwari
MD, BRIT (Radio Imaging)
Consultant Imagonologist

Dr. S. Kumar
MD (Pat)
Consultant Pathologist

Dr. Abhishek Kumar
MBBS, MD
Consultant Neuropatho Physiologist

Dr. Anjali
MBBS, MD
Consultant(TMT,EEG Specialist)

Dr. Kumari Suman
MBBS, DGO, MD
Consultant (TVS & HSG Specialist)