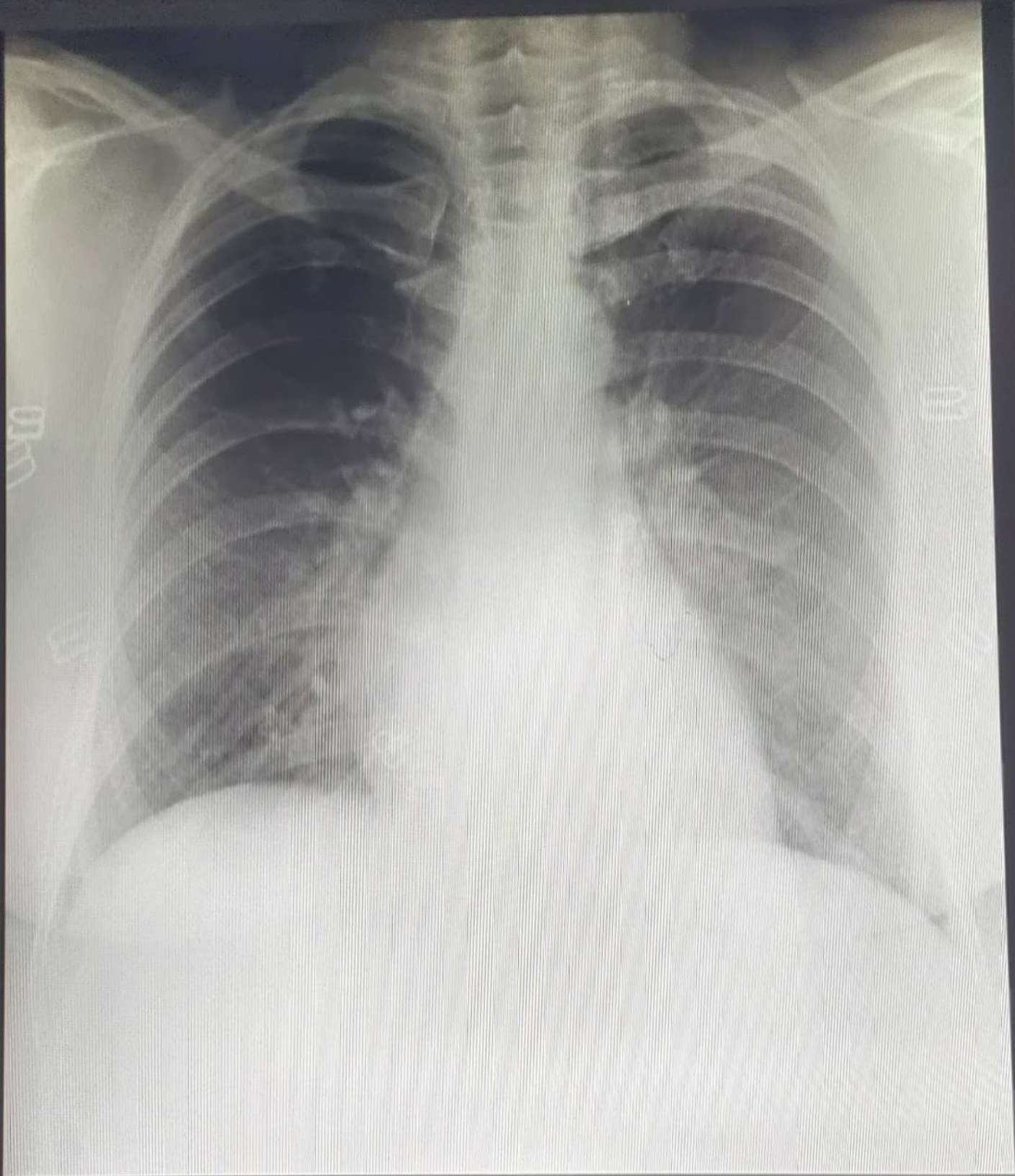

**MRS POONAM PATHAK 34Y 1074 CHEST,FRN P->A 12-Mar-22  
DIWAKAR DIAGNOSTIC CENTRE , ARERA COLONY ,BHOPAL**

आ वाय  
पूरा पठक  
Poonam Pathak  
जन्म तिथि/DOB: 13/12/1987  
महिला/ FEMALE  
7857 1109 8496  
VID : 9138 9937 3256 8074  
मेरा आधार, मेरी पहचान

भारत



*Poonam Pathak*



Dr. B. M. Agarwal  
MBBS, DCP  
Consultant Pathologist





# डिवांजी डायग्नोस्टिक सेंटर

E-7/636, पंजाब पुराना बँक के पास, मंग रोड, अरुण कॉलोनी श्यामल (म.प्र.)

फोन: 0755-2465288, 0755-3520545 फा: 9826340190

Pt.Name :-	Mrs. Poonam Pathak
Age :-	34y/F
Refd. By :-	Medi-wheel Full Body Health Checkup
Lab.No.:-	92
Date :-	12/03/2022

## EXAMINATION OF BLOOD

TEST	RESULT	NORMAL VALUE
Haemoglobin	12.2mg%	Female 12-16gms%, Male 14-18gms%
Red Cell count	4.8	4.5-5.6 million /cumm
Platelet Count	1.96	1.5-5.6 Lac/cumm
Leucocytes per.cumm	6400/cumm	5000-11000/cumm
Neutrophils	56%	50-70%
Lymphocytes	34%	20-40%
Eosinophils	06%	0-7%
Monocytes	04%	2-8%
PCV	37.1	37-47
MCV	77.5	76-96
MCH	29.2	27-32
MCHC	30.6	31-35
ESR	12	Male 0-9, Female 0-20mm/FHR
Blood Group	"AB" Positive	By Slide Method
S.Bilirubin(Total)	0.70	0.2-1.0mg/dl
Direct	0.28	0.0-0.25mg/dl
Indirect	0.42	
SGOT	18.5	5-35U/L
SGPT	22.2	8-40U/L
Alk Phosphatase	8.6	3-13 KA units
S. Protein(Total)	6.8	6.0-8.0mg%
Albumin	3.9	3.7-5.3mg%
Globulin	3.0	1.5 to 3.5 mg%
AG Ratio	1.26	1-2.0
Blood Urea Nitrogen (BUN)	12.1	7-20 mg/dl
S.Creatine	0.69	0.5-1.4mg/dl
S. Uric Acid	4.9	3.5-7.5mg%
Calcium	8.8	8.5-10.5 gm/dl
GGTP	28.5	5-35 U/L/dl
Fasting Blood Sugar	73.5	70 to 110mg/dl
Post Prandial Blood Sugar	119.3	Up to 140Mg/dl
Total Serum Cholesterol	156.3	100-250 mg%
Serum Triglyceride	108.2	Up to 160 mg%
Serum Cholesterol HDL	43.6	Up to 65 mg%
Serum Cholesterol/LDL	91.0	Up to 125 mg%
LDL	21.6	Up to 30 mg%
TC/HDL Ratio	3.20	
Glycosylated Hemoglobin	5.2	Below - 6.0 % - Non Diabetic control 6-7 % - Excellent control Above - 8 % - Poor control



Dr. B. P. Agarwal  
MBBS, DNB  
Pathologist  
All test have technical limitation. Collaborative clinic pathological interpretation is mandatory. In case of discrepancy test may be repeated immediately.





# द्विवाकर डायग्नोस्टिक सेंटर

E-7/636, पंजाब नेशनल बैंक के पास, मैन रोड, अरेरा कॉलोनी भोपाल ( म.प्र. )


फोन: 0755-2465288, 0755-3520545 मो: 9826340190

Pt.Name :-	Mrs. Poonam Pathak
Age :-	34y/F
Refd. By :-	Medi-wheel Full Body Health Checkup
Lab.pNo.:-	92
Date :-	12/03/2022

## URINE ANALYSIS

<u>A. PHYSICALEXAMINATION</u>		<u>C. MICROSCOPIEXAMINATION</u>	
1. Colour	Yellow	Pus Cells	3-4/HPF
2. Appearance	Clear	R.B.C.	Nil
3. Specific Gravity	Q.N.S.	Epithelial Cell	occ/HPF
<u>B. CHEMICAL EXAMINATION</u>		Cast	Nil
1.Reaction	Acidic	Crystals(Cal.Oxa)	Nil
2.Albumin	Absent	Bacteria	Nil
3.Sugar	Nil	Amorphous	Nil
4.Bile Salts	Absent	T. Vaginitis	Nil

URINE COTININE	Negative	By Card method
----------------	----------	----------------



Dr. B. M. Agarwal  
MBBS, DCP  
Pathologist

All test have technical limitation. Collaborative clinic pathological interpretation is mandatory. In case of discrepancy test may be repeated immediately. Typographical mistakes should be get correct instantly. This report is not valid for medico legal purpose





# द्विवाकर डायग्नोस्टिक सेंटर

E-7/636, पंजाब नेशनल बैंक के पास, मैन रोड, अरेरा कॉलोनी भोपाल ( म.प्र. )

फोन: 0755-2465288, 0755-3520545 मो: 9826340190

Pt.Name :-	Mrs. Poonam Pathak
Age :-	34y/F
Refd. By :-	Medi-wheel Full Body Health Checkup
Lab.pNo.:-	92
Date :-	12/03/2022

## REPORT

Tricia Central

Thoracic cage normal

Both Lungs Field Clear.

Both hilers normal

Cardiac border normal

Both cp angles clear

Both domes and diaphragm normal

## IMPRESSION

\*\*\*\*\*

-NO CARDIO PULMONARY PATHOLOGY

-COORELATE WITH CLINICAL FINDINGS.



**Dr. B. M. Agarwal**  
MD, Radiology  
Consultant Radiologist  
Radiologist





# द्विवाकर डायग्नोस्टिक सेंटर

E-7/636, पंजाब नेशनल बैंक के पास, मैन रोड, असेरा कॉलोनी भोपाल ( म.प्र. )

फोन: 0755-2465288, 0755-3520545 मो: 9826340190

Pt.Name :-	Mrs. Poonam Pathak
Age :-	34y/F
Refd. By :-	Medi-wheel Full Body Health Checkup
Lab.pNo.:-	92
Date :-	12/03/2022

## EXAMINATION OF BLOOD

### Thyroid profile

<u>TEST</u>	<u>RESULT</u>	<u>NORMAL VALUE</u>
T3 - TOTAL	106.5	82-213 ng/dL
T4 - TOTAL	8.25	6.09-12.23 ug/dL
THYROID STIMULATING HORMONE (TSH)	3.06	0.45-4.25 ul/mL

#### Interpretation:

TSH Levels will be elevated in primary hypothyroidism, TSH levels will be low in Hyperthyroidism there is decreased production of thyroid hormones by the thyroid hence the person may experience symptoms such as weight gain, constipation, cold intolerance and fatigue. Iodine deficiency and Hashimoto thyroiditis is the most common cause of hypothyroidism It makes Thyroid stimulating hormone. If TSH levels are abnormally high it could mean you have an underactive thyroid or hypothyroidism.



Dr. B. M. Agarwal  
MBBS, DCP  
Pathologist  
Consultant Pathologist

All test have technical limitation. Collaborative clinic pathological interpretation is mandatory. In case of disparity test may be repeated immediately. Typographic mistakes should be get correct instantly. This report is not valid for medico legal purpose





# डॉ. सविता क्लिनिक

34, भूतल, मोहिनी अदिति आर्केड, शाहपुरा मस्जिद के पास  
भरत नगर रोड, ई-7/194, अरेरा कॉलोनी, भोपाल - 462038

Mob. : 8989649694, 9516333619

Clinic Registration : CL/5392/Jun/2017

PNDT Registration : MPPCPNDT/BPL/2017/206



Name : Mrs. Poonam Pattak. 34/R. Age.....YRS./F

R/B Health check up. No. .... Date 12/3/2022.

## WHOLE ABDOMES ULTRASOUND REPORT

### Indication:

Liver appears normal in size and shape with normal outline. Normal/  
increased parenchymal echogenicity is noted. No E/O focal lesion/ IHBR  
dilatation is seen. Hepatic veins and portal veins appear normal. grade II  
fatty liver.

No E/O subdiaphragmatic Collection.

Gall Bladder is physiologically well distended. No. E/O echogenic foci in GB  
lumen. GB wall is normal / thickened. No E/O pericholecystic collection.  
Common duct reveals normal course and caliber.

Pancreas appear normal in size, shape and echo texture with smooth  
contour. No peripancreatic pathology seen. (~~Not seen due to gases~~)

Spleen is normal in size and echo texture.

IVC and aorta appear to be normal.

No evidence of lymphadenopathy is noted.

No evidence of free fluid is noted.

Right Kidney is normal in size. size, shape and position. Corticomedullary  
differentiation (CMD) is well maintained. Normal cortical thickness is  
noted. No E/O hydronephrosis or calculus is noted.

PTO

Dr. P. Savita, MD

MBBS, MD (O&G) Reg. No. 9971

स्त्री रोग विशेषज्ञ

Dr. Jayant Yadav, MD

MBBS, MD (Radiologist) Reg. No. 4166

रेडियोलॉजिस्ट



**Left Kidney** is normal in size, shape and position. CMD is well maintained. Normal cortical thickness is noted. No E/O hydronephrosis or calculus is noted. *Small cortical cyst - 2.35 cm size*

**Urinary Bladder** is well distended (physiological). its contents are echo free. No E/O bladder wall thickening is noted. Post-void residue is insignificant.

**Prostate** is normal in size. Shape and echo texture with smooth outline. No E/O focal lesion is noted.

**Uterus** is ante/~~retro~~verted and normal in size, shape and echotexture with smooth outline. No E/O focal lesion is noted. Endometrial echo appear normal. Cervical and vaginal shadows appear normal.

**Right Ovary** appears ~~enlarged~~ / Normal in size, shape and echo texture.

**Left Ovary** appears ~~enlarged~~ / Normal in size, shape and echo texture.

**Impression :** ~~Normal study.~~ *Grade II fatty liver.*

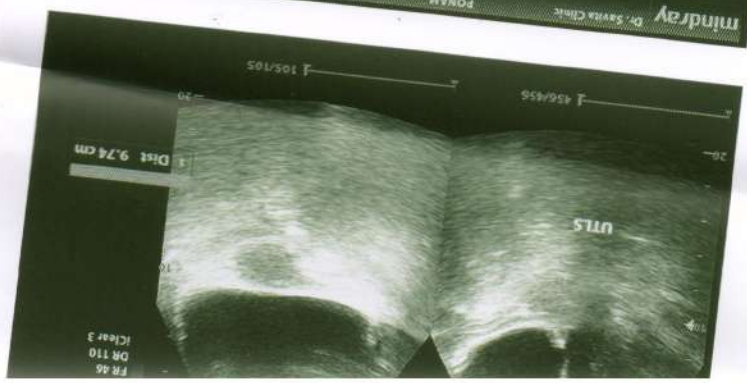
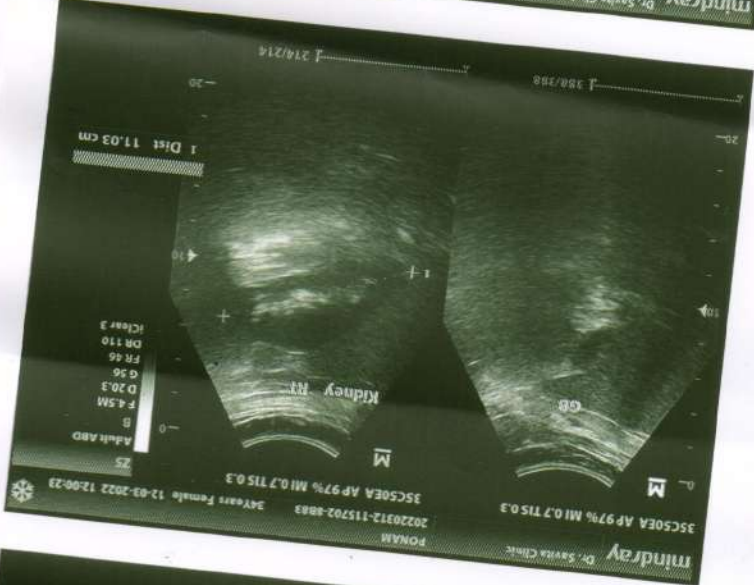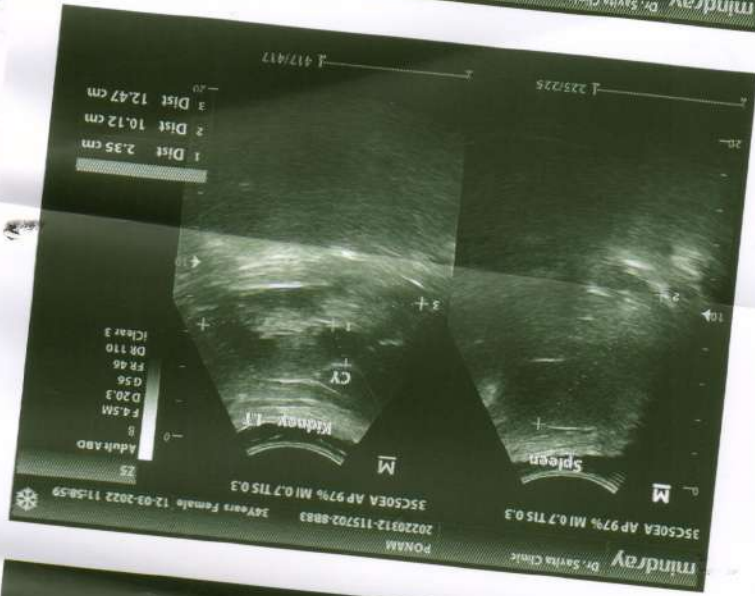
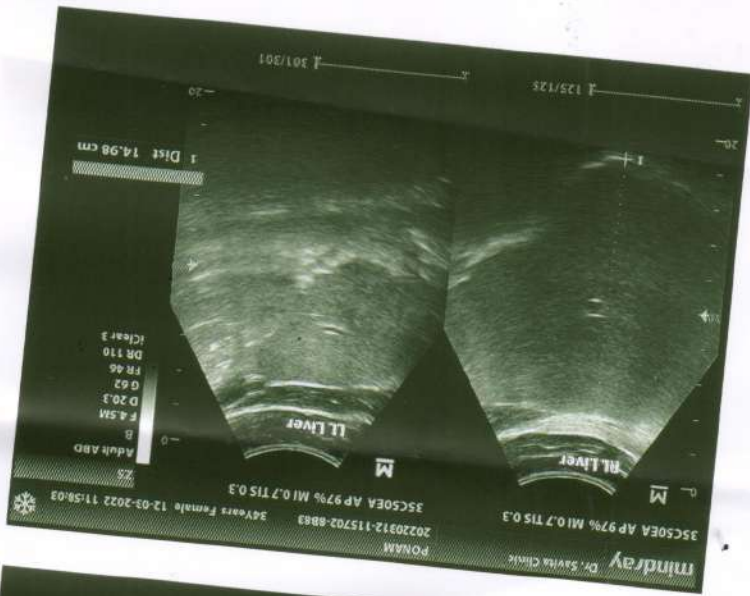
**Advised clinical Correlation.**

*Review*

Dr. P. Savita, MD  
MBBS, MD (O&G) Reg. No. 9971  
स्त्री रोग विशेषज्ञ

Dr. Jayant Yadav, MD  
MBBS, MD (Radiologist) Reg. No. 4166  
रेडियोलॉजिस्ट







**Diwakar Diagnostic Centre  
E-7/636, Near Punjab National Bank Bhopal(M.P.)**

256 / MS.POONAM PATHAK / 34 Yrs / M / 167 Cms / 95 Kg Date: 12-Mar-2022 Technician : BOB

**Report :**

TEST OBJECTIVE : ROUTINE CHECK UP  
RISK FACTOR : AGE  
ACTIVITY : MODERATE ACTIVE  
REASON FOR TERMINATION : FATIGUE, HEART RATE ACHIEVED  
EXERCISE TOLERANCE : AVERAGE  
EXERCISE INDUCED ARRHYTHMIAS : NO  
HAEMODYNAMIC RESPONSE : NORMAL  
CHRONOTROPIC RESPONSE : NORMAL  
FINAL IMPRESSION : STRESS TEST IS NEGATIVE FOR EXERCISE INDUCED ISCHAEMIC HEART DISEASE

*Dr. Pooja Pathak*



**Doctor : CARDIOLOGIST**





256 / MS.POONAM PATHAK / 34 Yrs / M / 167 Cms / 95 Kg Date: 12-Mar-2022 Technician : BOB

Stage	Time	Duration	Belt Speed (mph)	Elevation	METs	Rate	% THR Achieved	BP	RPP	PVC	Comments
Supine	00:30	0:01	00.0	00.0	01.0	92	49 %	120/80	110	00	
Standing	01:21	0:01	00.0	00.0	01.0	90	48 %	120/80	108	00	
HV	01:54	0:01	00.0	00.0	01.0	115	62 %	120/80	138	00	
Warm Up	04:51	0:02	01.7	10.0	01.0	104	56 %	120/80	124	00	
ExStart	04:56	0:07	01.7	10.0	01.1	104	56 %	120/80	124	00	
BRUCE Stage 1	07:56	3:00	01.7	10.0	04.7	142	76 %	130/80	184	00	
BRUCE Stage 2	10:56	3:00	02.5	12.0	07.1	166	89 %	136/80	225	00	
PeakEX	11:06	0:10	03.4	14.0	07.3	167	90 %	136/80	227	00	
Recovery	12:05	1:00	01.1	00.0	01.2	152	82 %	140/80	212	00	
Recovery	13:05	2:00	00.0	00.0	01.0	115	62 %	140/80	161	00	
Recovery	14:05	3:00	00.0	00.0	01.0	109	59 %	140/80	152	00	
Recovery	15:05	4:00	00.0	00.0	01.0	103	55 %	140/80	144	00	
Recovery	16:05	5:00	00.0	00.0	01.0	109	59 %	120/80	130	00	
Recovery	16:19	5:13	00.0	00.0	01.0	104	56 %	120/80	124	00	

**Findings :**

Exercise Time : 06:11  
 Max HR Attained : 167 bpm 90% of Target 186  
 Max BP Attained : (Sys) 140/80  
 Max WorkLoad Attained : 7.3 Fair response to induced stress  
 Max ST Dep Lead & Value : Max ST Dep Lead & Value  
 Test End Reasons : Fatigue, Heart Rate Acheived





SUPINE

Agar Diagnostic Centre

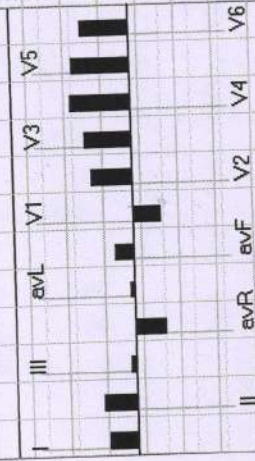
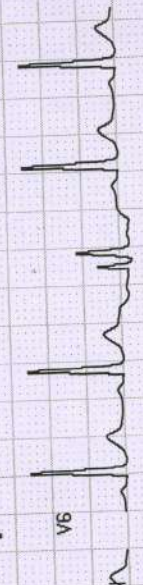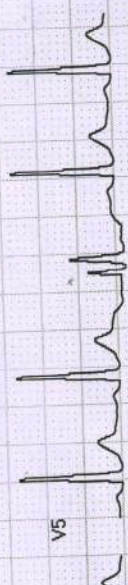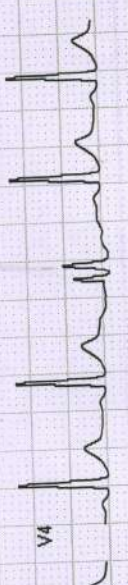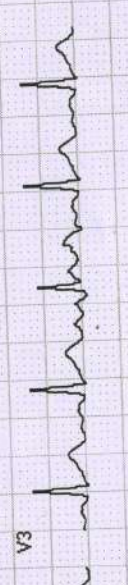
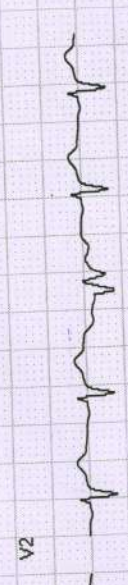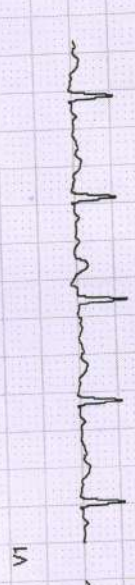
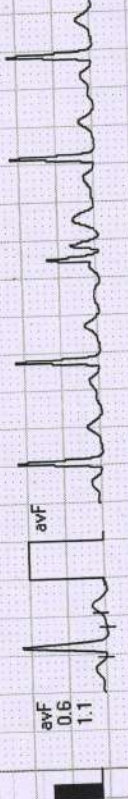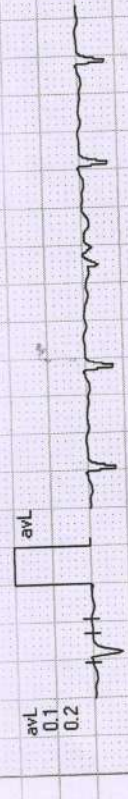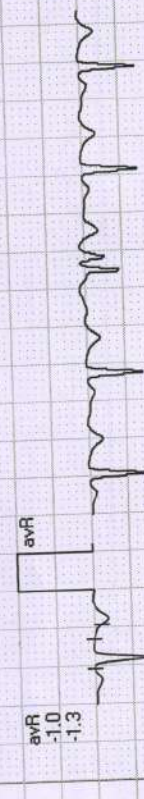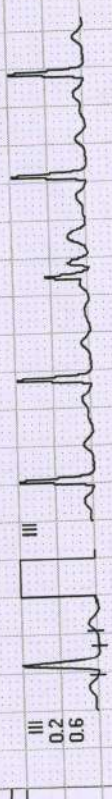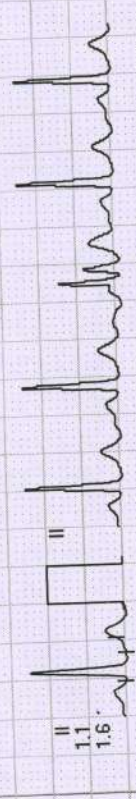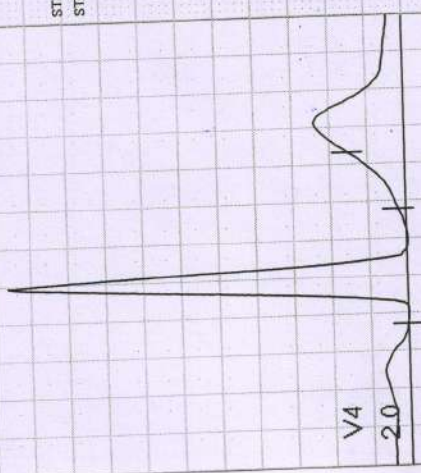
256 / MS. POONAM PATHAK / 34 Yrs / M / 167 Cms / 95 Kg / HR : 92

ExTime: 00:29 0.0 mph. 0.0%

25 mm/Sec. 1.0 Cm/mV

Date: 12-Mar-2022 12:46:23 PM METS: 1.0/ 92 bpm 49% of THR BP: 120/80 mmHg Raw ECG/ BLC On/ Natch On/ HF 0.05 Hz/LF 20 Hz

4X 80 mS Post J



REMARKS:

(GEM213180307)(A)Allengers





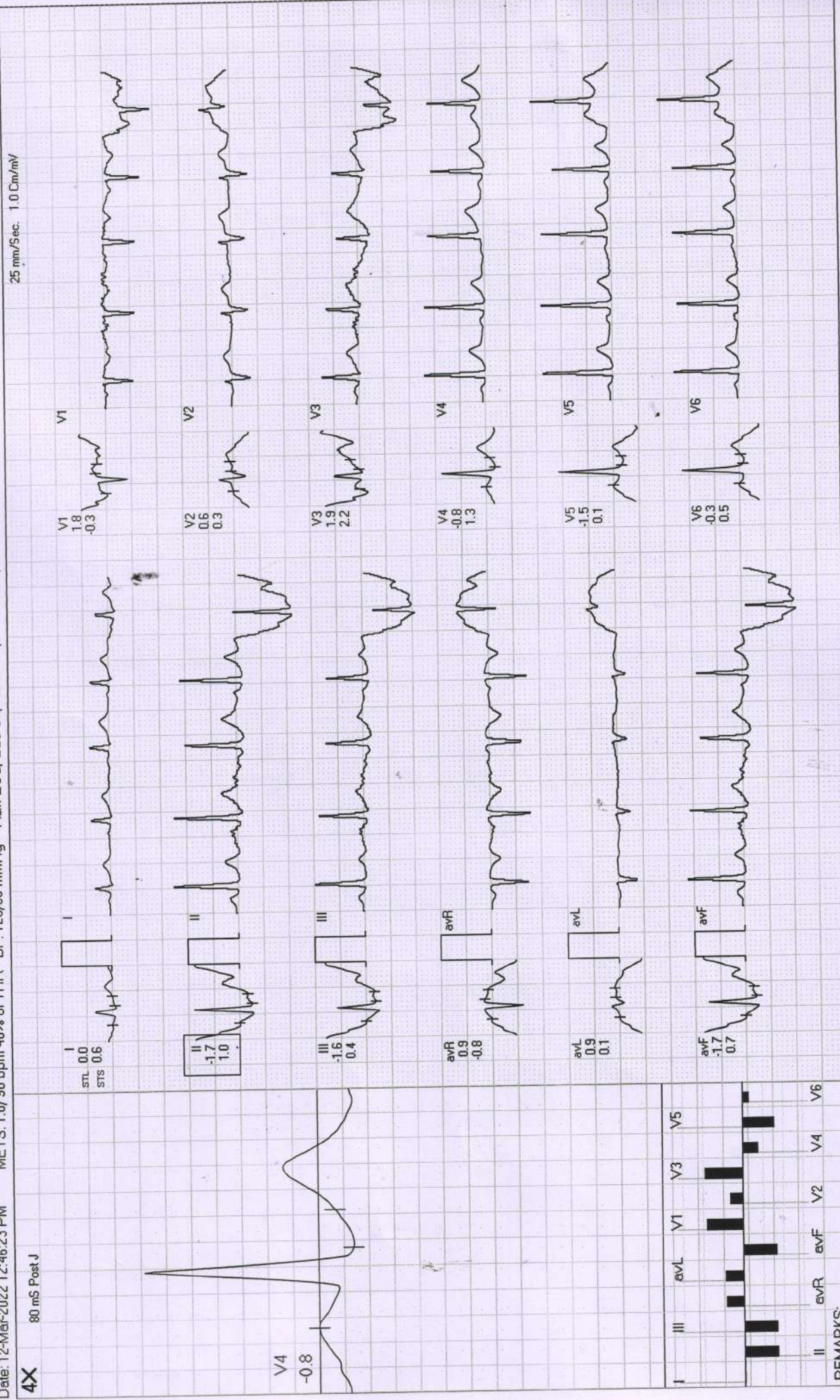
STANDING

Diagnostic Centre

256 / MS. POONAM PATHAK / 34 Yrs / M / 167 Cms / 95 Kg / HR : 90

ExTime: 01:20 0.0 mph, 0.0%

Date: 12-Mar-2022 12:46:23 PM METS: 1.0/90 bpm 48% of THR BP: 120/80 mmHg Raw ECG/ BLC On/ Notch On/ HF 0.05 Hz/LF 20 Hz



REMARKS:

(GEM213180307)(A)Allengers





HV

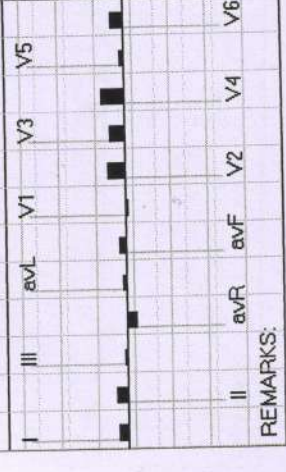
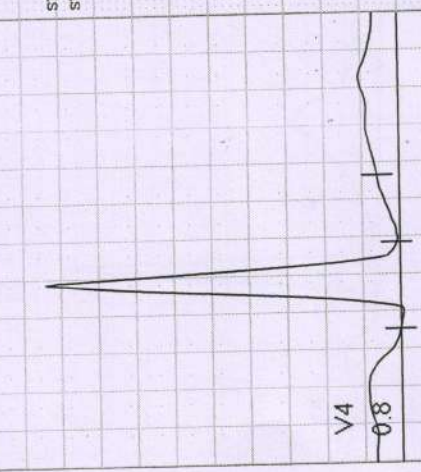
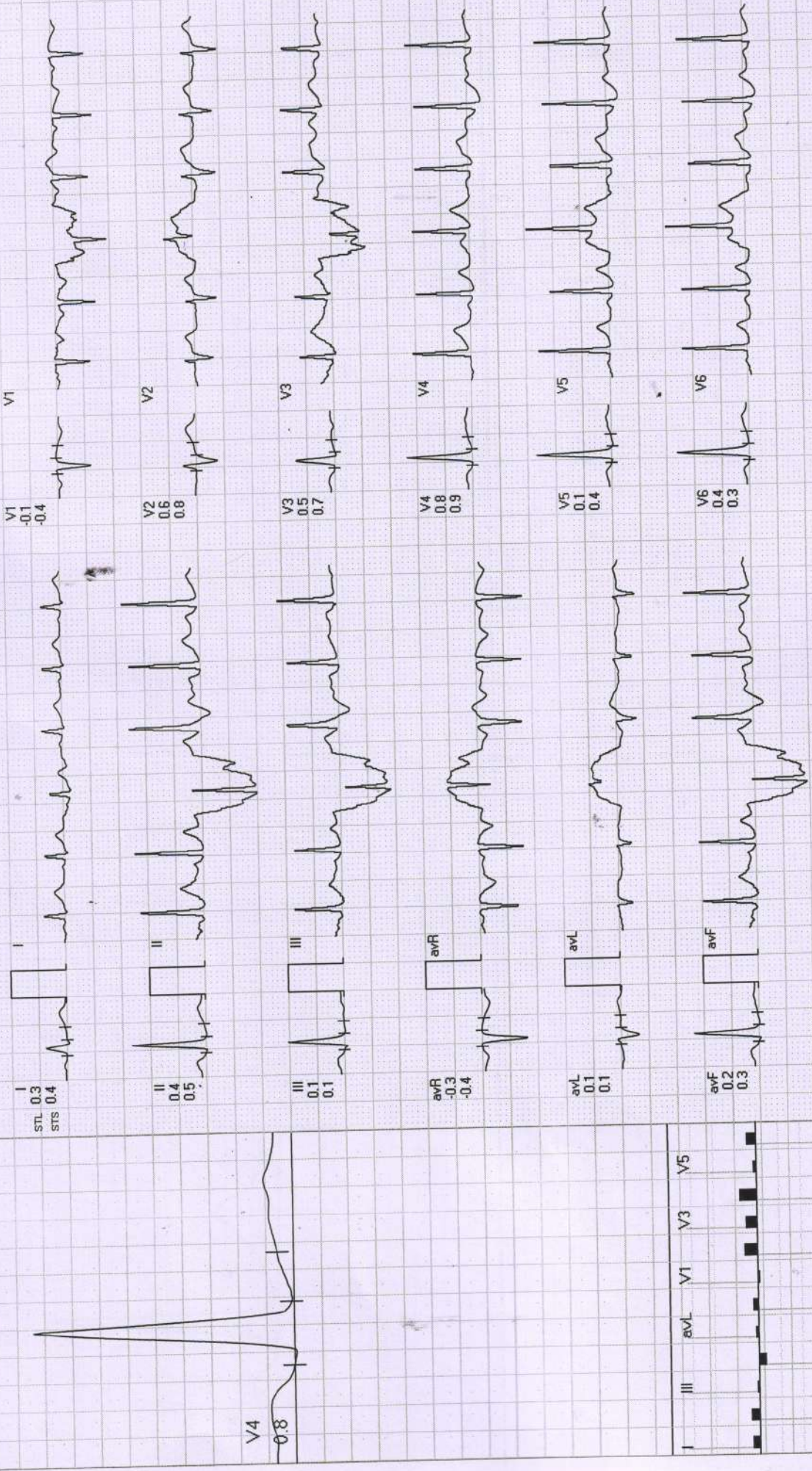
Diagnostic Centre

256 / MS. POONAM PATHAK / 34 Yrs / M / 167 Cms / 95 Kg / HR : 115

ExTime: 01:53 0.0 mph. 0.0%  
25 mm/Sec. 1.0 Cm/mV

Date: 12-Mar-2022 12:46:23 PM METS: 1.0/115 bpm 61% of THR BP: 120/80 mmHg Raw ECG/ BLC On/ Notch On/ HF 0.05 Hz/ LF 20 Hz

4X 80 mS Post J



REMARKS:






MS. POONAM PATHAK / 34 Yrs / M / 167 Cms / 95 Kg / HR : 93

Date: 12-Mar-2022 12:46:23 PM METS: 1.0/ 93 bpm 50% of THR BP: 120/80 mmHg Raw ECG/BLC On/ Notch On/ HF 0.05 Hz/LF 20 Hz

ExTime: 04:50 1.0 mph, 0.0%

4X 80 mS Post J






MS. POONAM PATHAK / 34 Yrs / M / 167 Cms / 95 Kg / HR : 93

Date: 12-Mar-2022 12:46:23 PM METS: 1.0 / 93 bpm 50% of THR BP: 120/80 mmHg Raw ECG/BLC On/Notch On/HF 0.05 Hz/LF 20 Hz

ExTime: 00:00 0.0 mph, 0.0%  
25 mm/Sec. 1.0 Cm/mV







BRUCE : Stage 1 ( 03:00 )

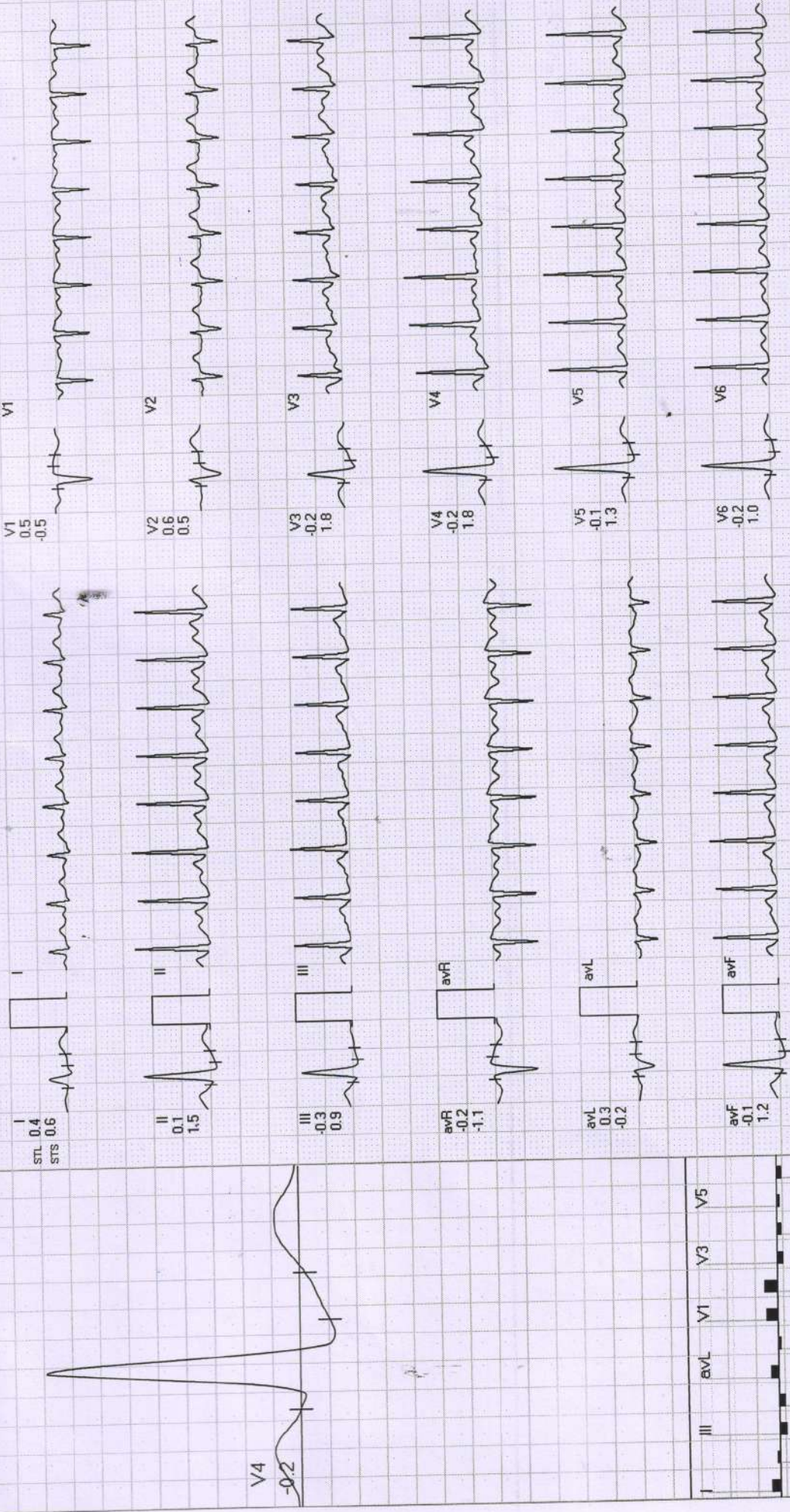
Cardiac Diagnostic Centre

266 / MS. POONAM PATHAK / 34 Yrs / M / 167 Cms / 95 Kg / HR : 142

EXTIME: 03:00 1.7 mph, 10.0%  
25 mm/Sec. 1.0 Cm/mV

Date: 12-Mar-2022 12:46:23 PM METS: 4.7/142 bpm 76% of THR BP: 130/80 mmHg Raw ECG/BLC On/Notch On/HF 0.05 Hz/LF 20 Hz

4X 60 mS Post J



I	II	III	aVL	aVR	aVF	V1	V2	V3	V4	V5	V6
■	■	■	■	■	■	■	■	■	■	■	■

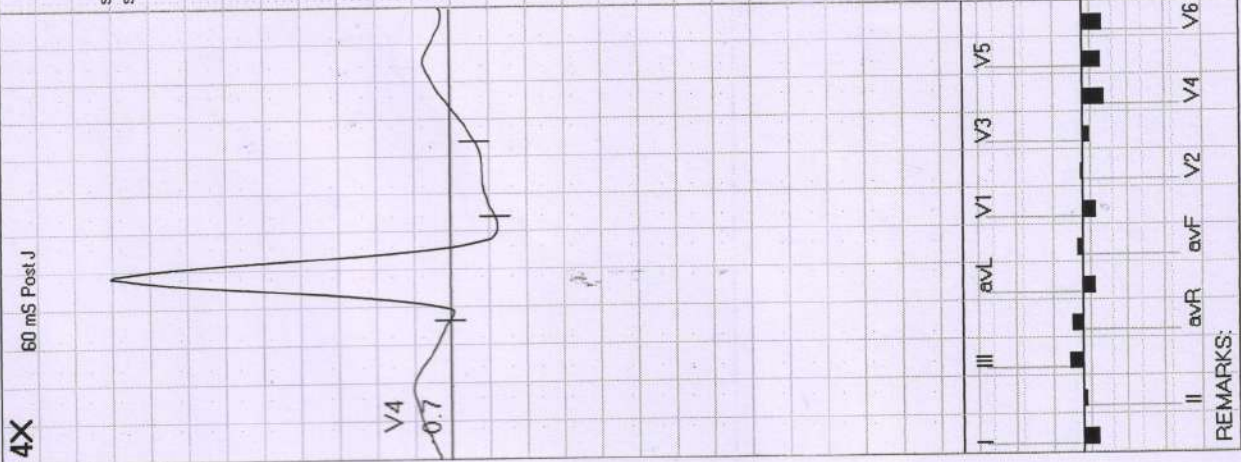
REMARKS:





Date: 12-Mar-2022 12:46:23 PM METS: 7.1 / 166 bpm 89% of THR BP: 136/80 mmHg Raw ECG/BLC On/ Notch On/ HF 0.05 Hz/LF 20 Hz

Ex Time: 06:00 2.5 mph, 12.0%  
25 mm/Sec. 1.0 Cm/mV







PeakEx

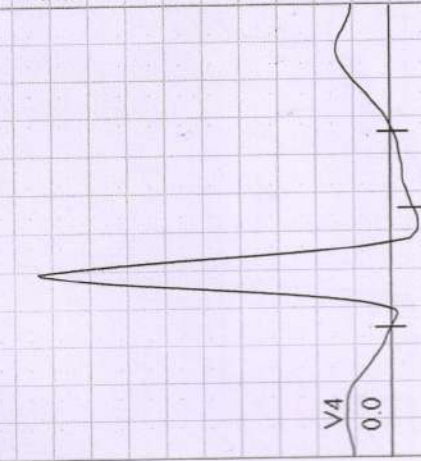
Peak Diagnostic Centre

256 / MS. POONAM PATHAK / 34 Yrs / M / 167 Cms / 95 Kg / HR : 167

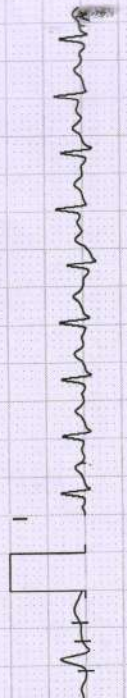Date: 12-Mar-2022 12:46:23 PM METS: 7.3/167 bpm 89% of THR BP: 136/80 mmHg Raw ECG/BLC On/ Notch On/ HF 0.05 Hz/LF 20 Hz

EXTime: 06:10 3.4 mph, 14.0%  
25 mm/Sec. 1.0 Cm/mV

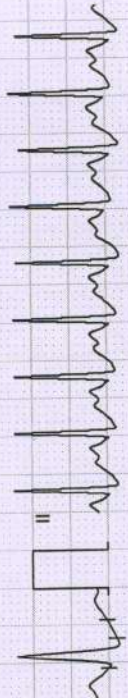
4X 60 mS Post J



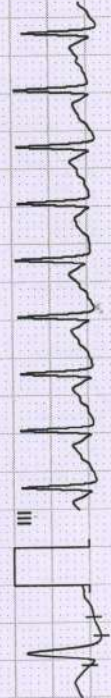I  
STL 0.8  
STS 0.5



II  
0.2  
2.2



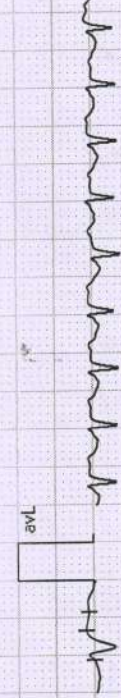III  
-0.5  
1.7



avR  
-0.5  
-1.4



avL  
0.7  
-0.6



avF  
-0.2  
1.9



V1  
0.6  
-1.8



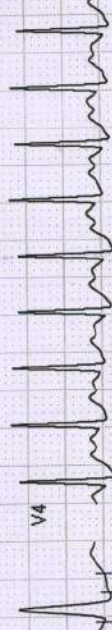V2  
0.5  
0.7



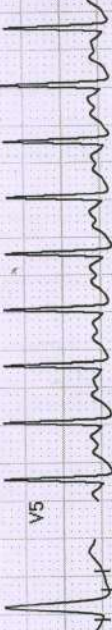
V3  
0.0  
1.2



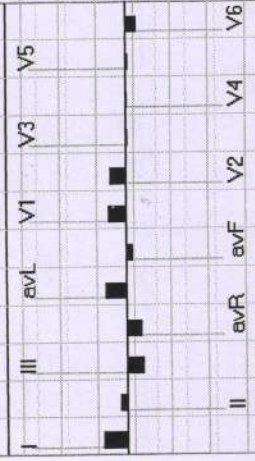
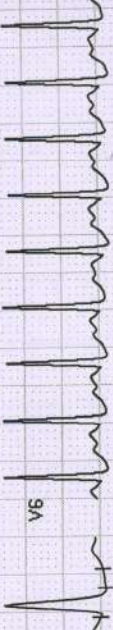
V4  
0.0  
1.1



V5  
-0.1  
1.4



V6  
-0.4  
0.6



REMARKS:





Recovery : ( 01:00 )


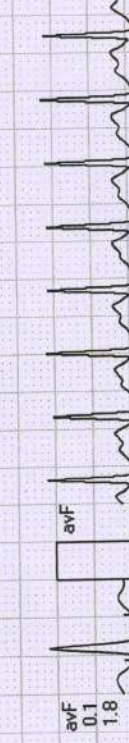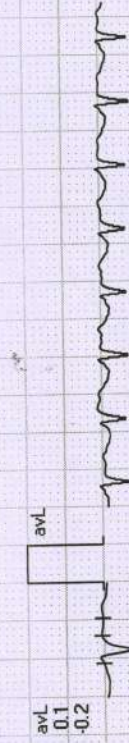
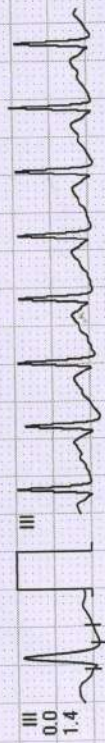


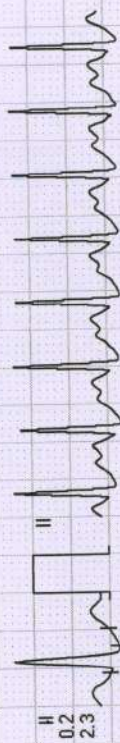

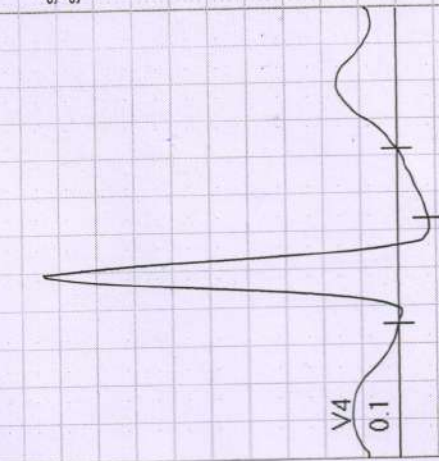
# Wakar Diagnostic Centre

256 / MS. POONAM PATHAK / 34 Yrs / M / 167 Cms / 95 Kg / HR : 152

Date: 12-Mar-2022 12:46:23 PM METS: 1.1 / 152 bpm 81% of THR BP: 140/80 mmHg Raw ECG/BLC On/ Notch On/ HF 0.05 Hz/LF 20 Hz

ExTime: 06:10 0.0 mph, 0.0%  
25 mm/Sec. 1.0 Cm/mV

4X 60 mS Post J



REMARKS: