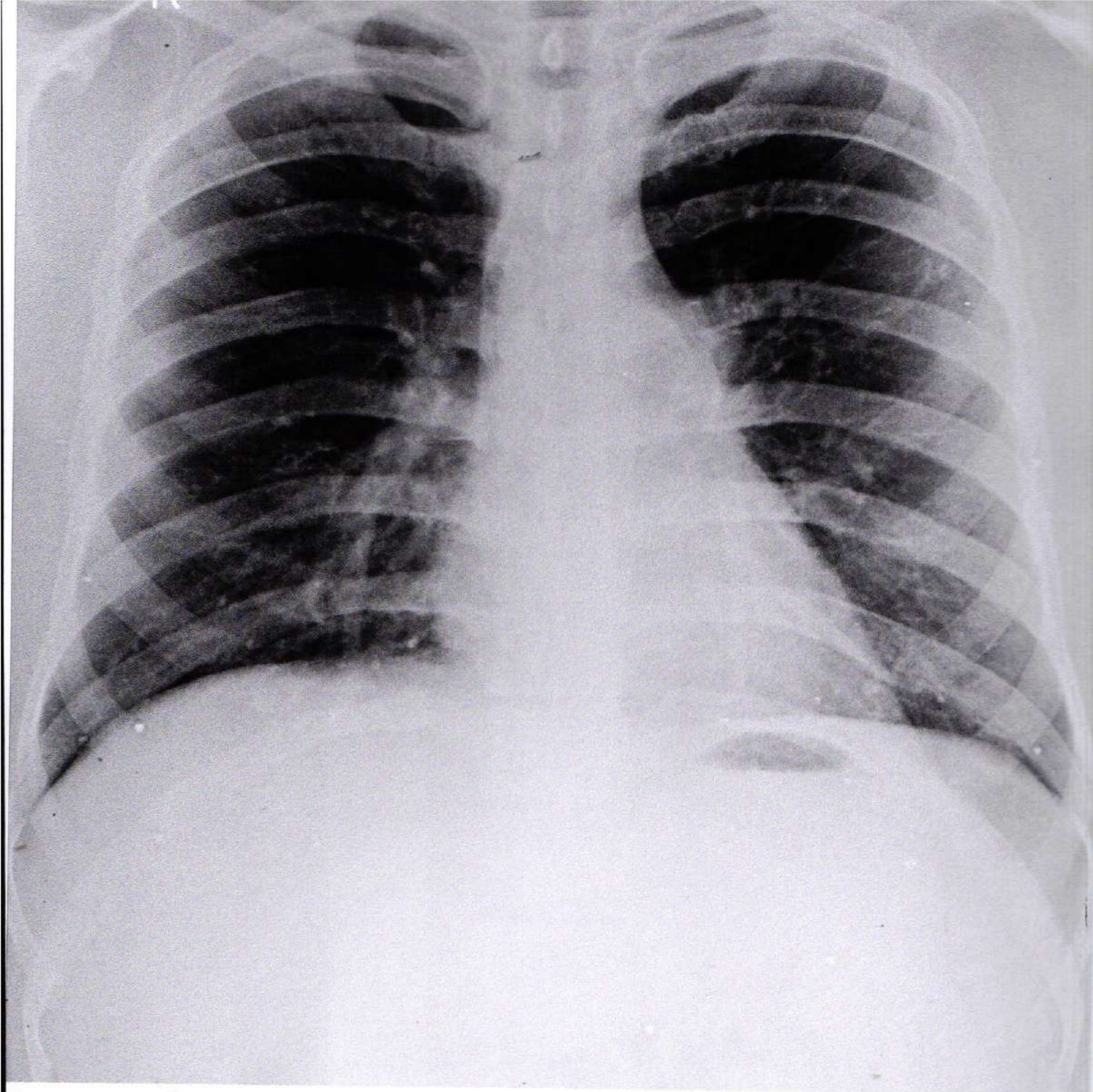

**PRAFULLA MULE 34Y 2205210049 OPD Chest PA/AP-REALISM  
21/05/2022**

**Acharya Vinoba Bhave Rural hospital, Sawangi (Meghe)**



Datta Meghe Institute of Medical Sciences (Deemed to be University) NAAC Grade A+

# ACHARYA VINOBA BHAVE RURAL HOSPITAL

*Transforming Lives Through Well Being*

A Teaching Hospital of Jawaharlal Nehru Medical College, Sawangi (Meghe), WARDHA-442 004

Ph. : 07152-287701 - 06, 304000 Ext. 342 Visit us at : www.avbrhsawangimeghe.com Email : info@avbrhsawangimeghe.com



## DEPARTMENT OF RADIODIAGNOSIS

NAME:	PRAFULLA MULE 34Y	AGE & SEX:	& M
REG. NO.:	2205210049	DATE:	21-May-2022
REFERRED BY:			

### Radiogram of chest

- Lung fields do not show any parenchymal abnormality.
- Hila appear normal. No adenopathy noted.
- Cardiac silhouette appears normal.
- Diaphragmatic outline and bilateral costophrenic angles are clear.
- The visualised soft tissues are normal.
- Bony cage is normal.

**Impression: No obvious pleuroparenchymal abnormality.**

DR R P DHANDE  
PROF AND HOD  
RADIODIAGNOSIS

Date: 21-May-2022 11:18:34





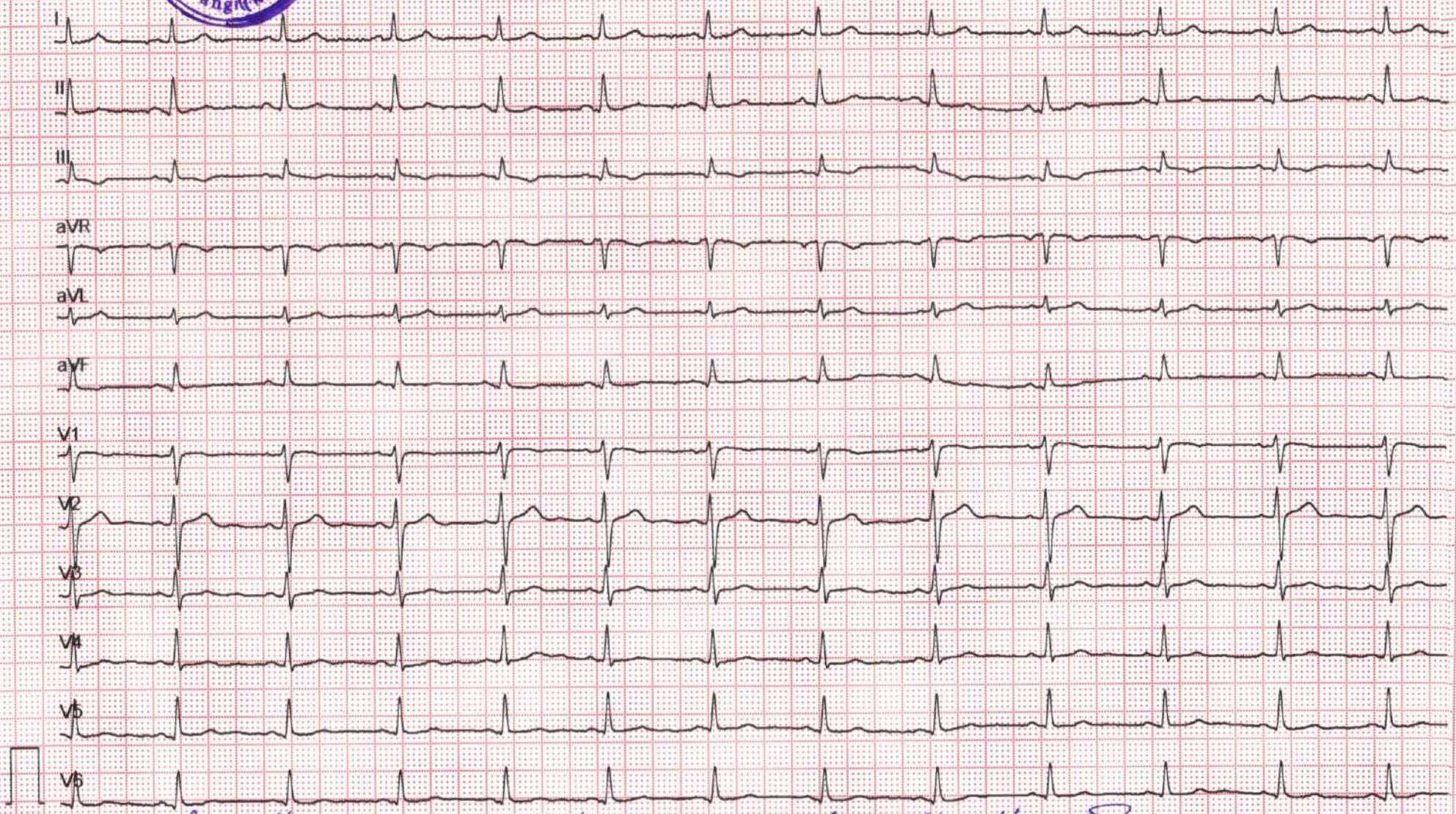
Male



*Dr. Anuj Verma*  
MBBS, MD (Medicine)  
Reg. No. MCI 09/34884  
Acharya Vinoba Bhave Rural Hospital  
Sawangi (Meghe), WARDHA

2205210049  
21/05/2022

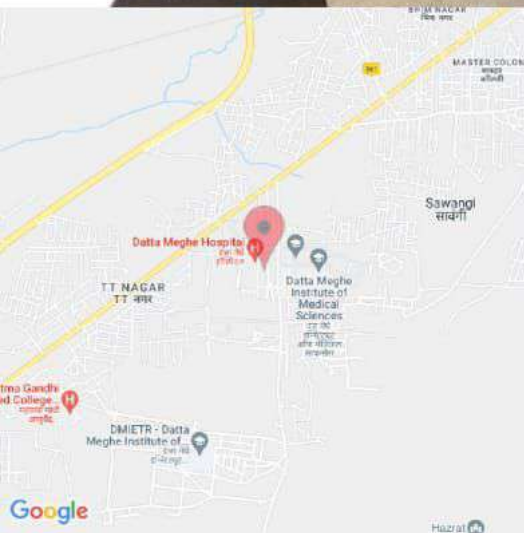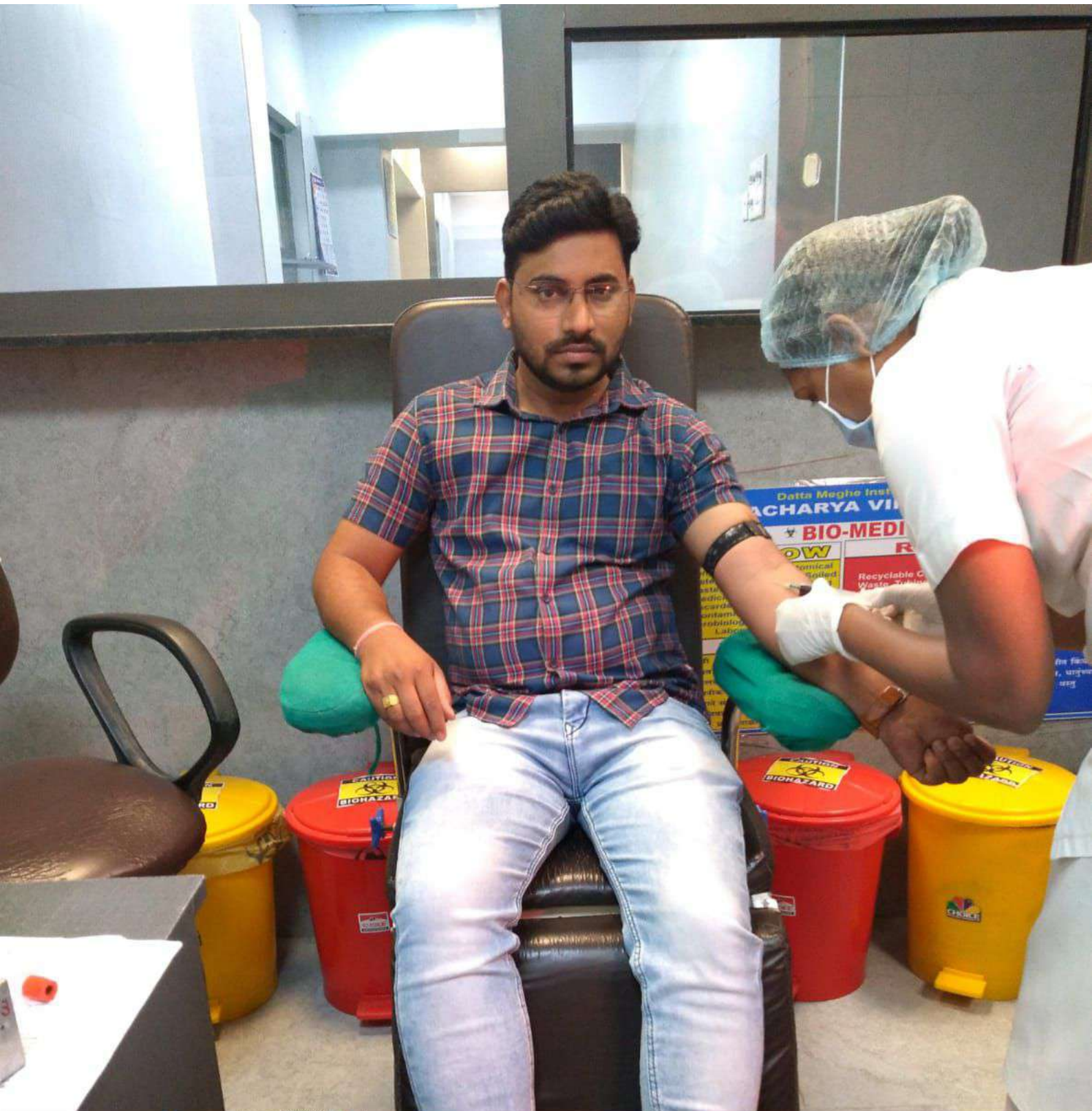*Dr. Mule*



*Repeating ECG within normal limit*

Unconfirmed



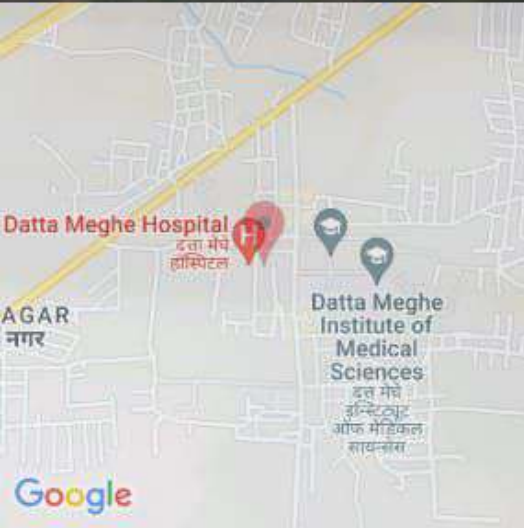

PH7F+W85, Sawangi, Maharashtra 442001, India

Sawangi  
Maharashtra  
India

2022-05-21(Sat) 10:24





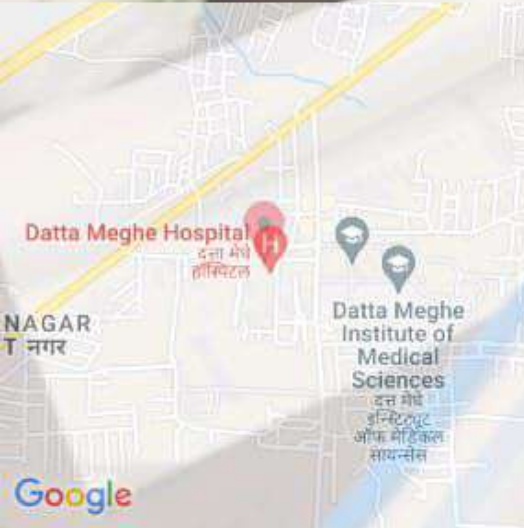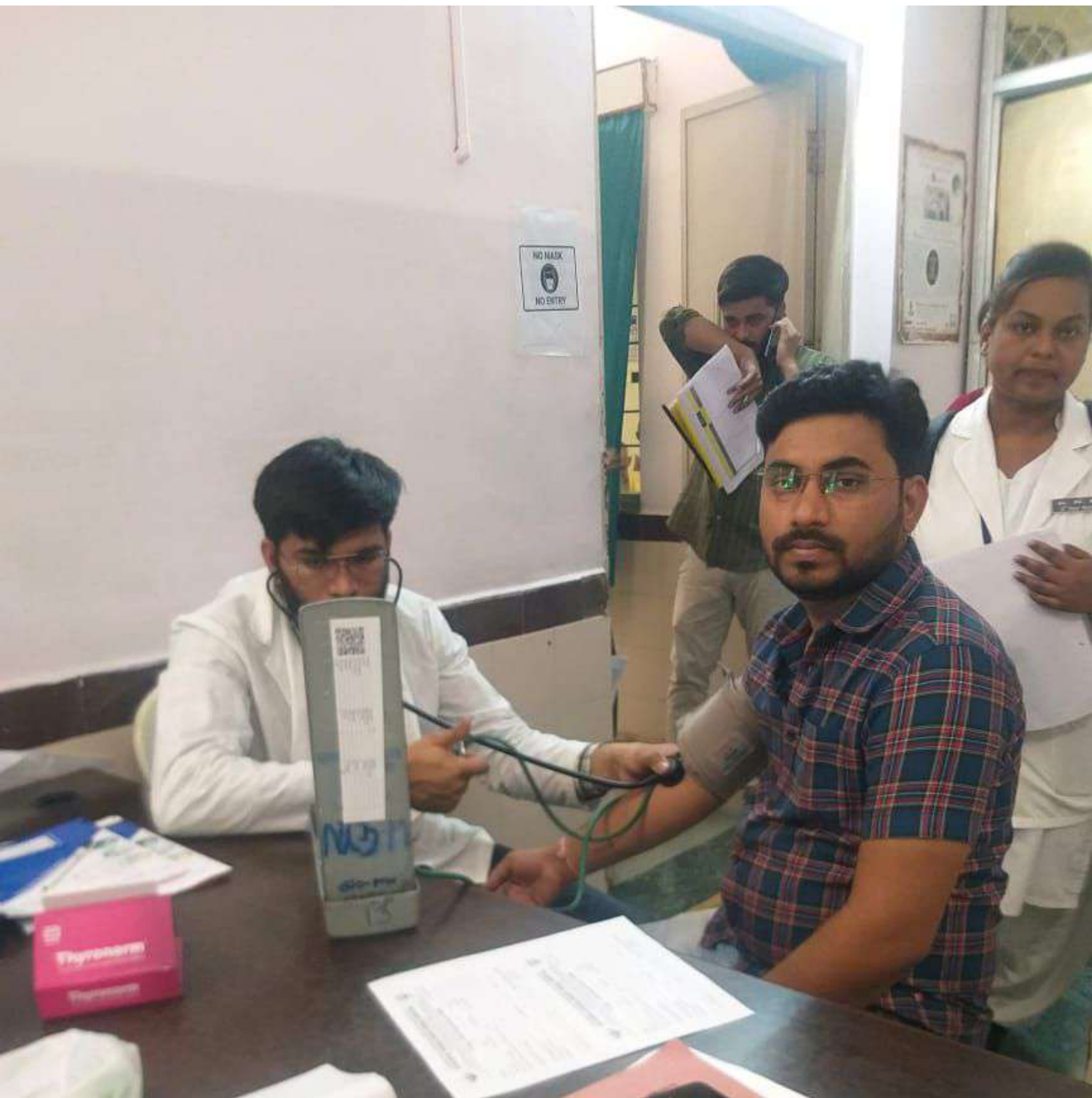AVBRH Complex, Sawangi Meghe, Wardha, Maharashtra 442001, India

Wardha  
Maharashtra  
India



41°C  
106°F

2022-05-21(Sat) 12:27(pm)



Near Sawangi Meghe Hospital, beside A.G. House, Sawangi, Maharashtra 442001, India

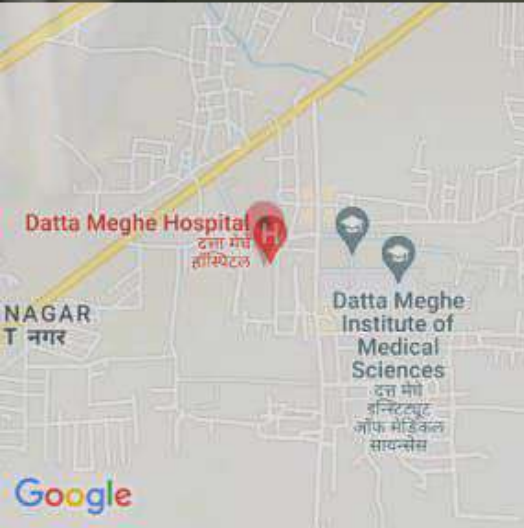Sawangi  
Maharashtra  
India



41°C  
106°F

2022-05-21(Sat) 12:11(pm)





PH7F+W4R, Sawangi, Maharashtra 442001, India

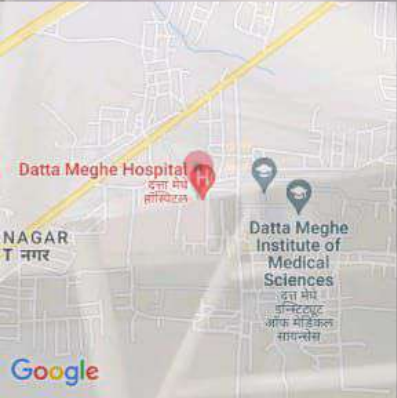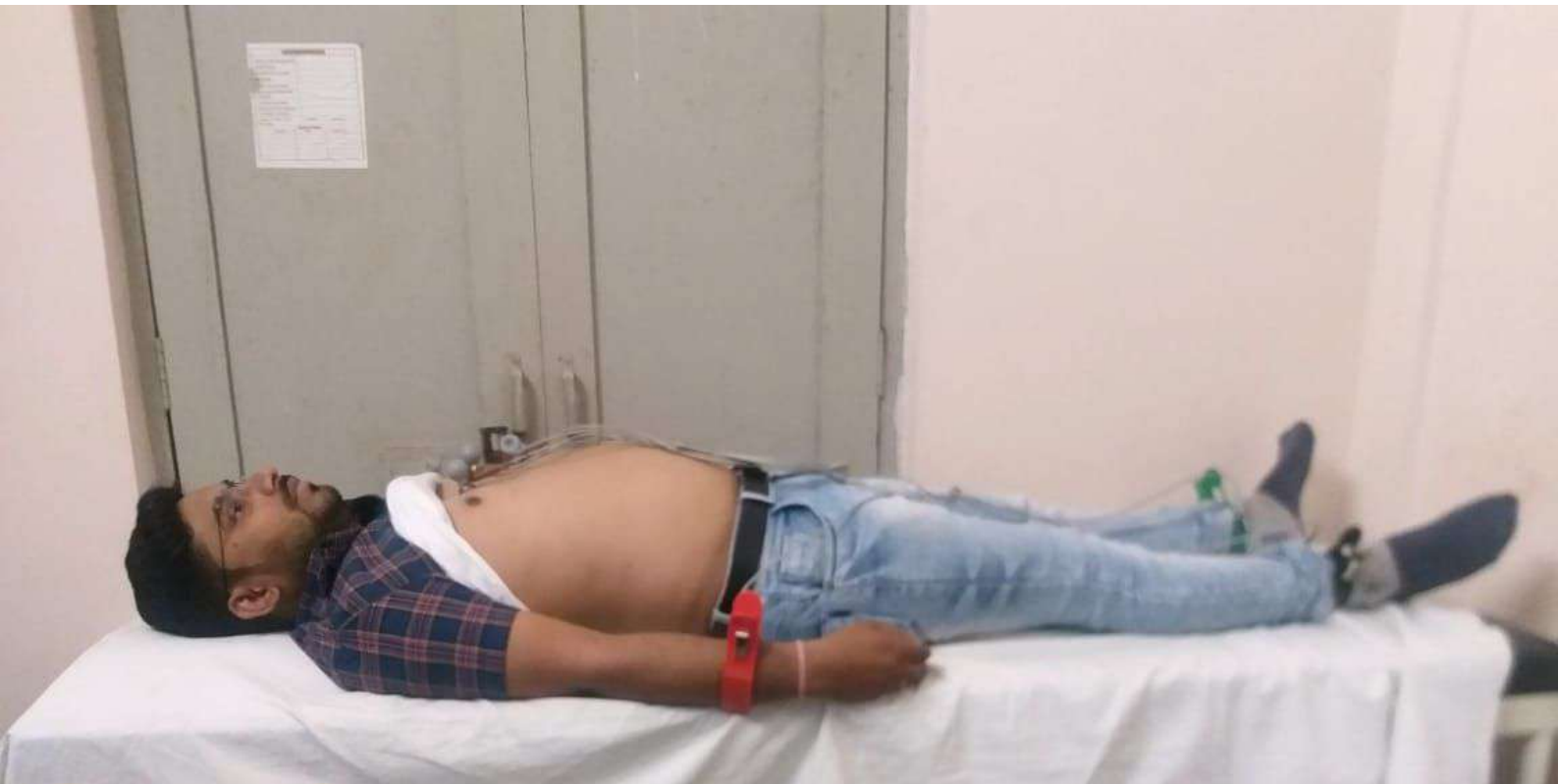Sawangi  
Maharashtra  
India



40°C

104°F

2022-05-21(Sat) 11:57(am)



Near Sawangi Meghe Hospital, beside A.G.House, Sawangi, Maharashtra 442001, India

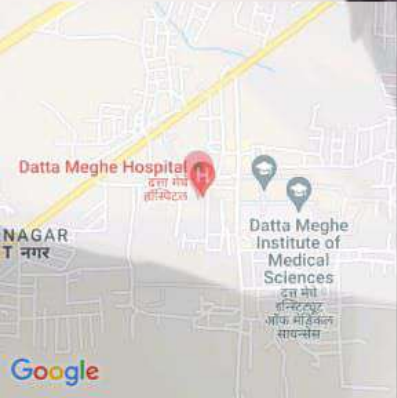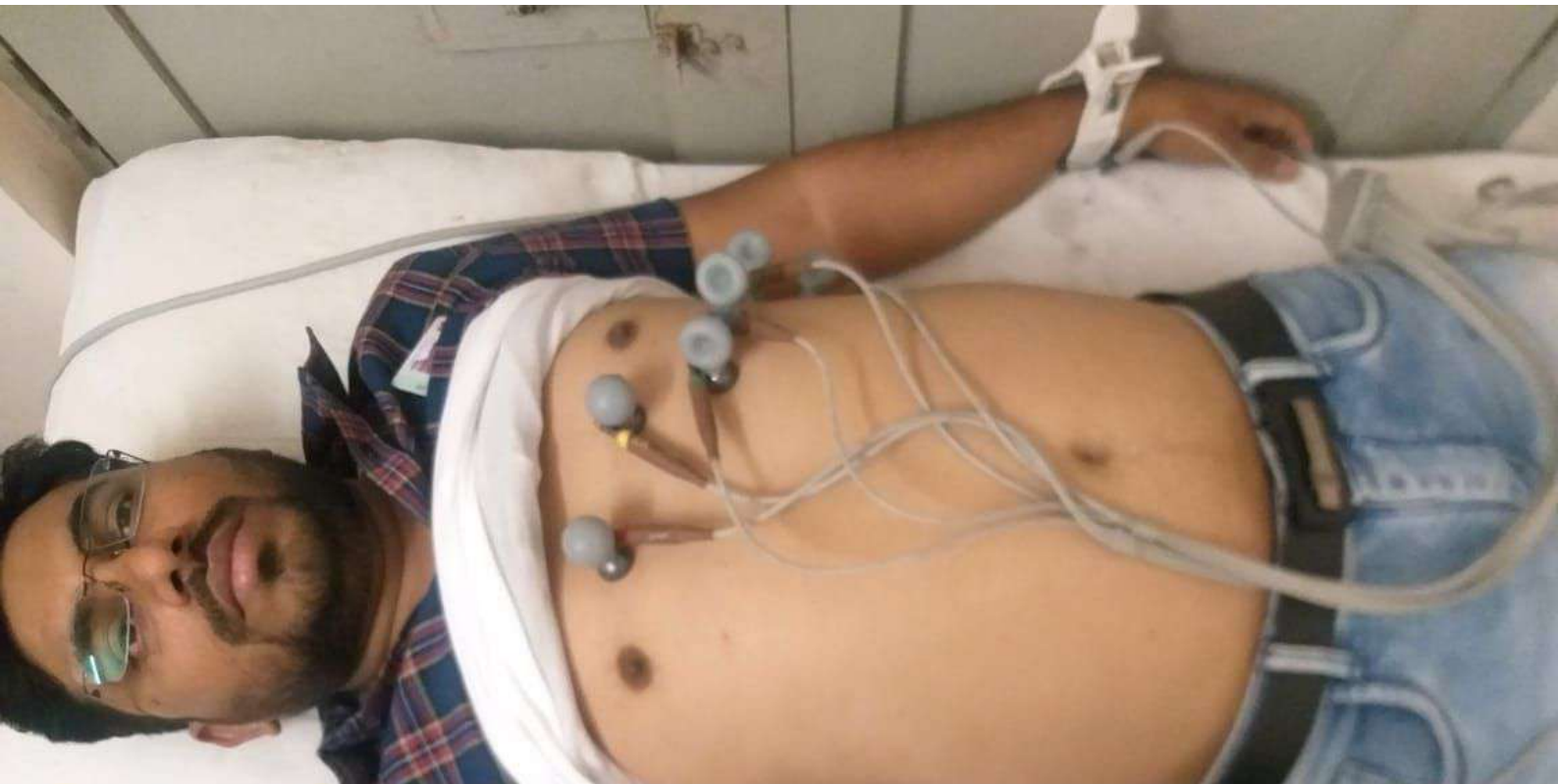Sawangi  
Maharashtra  
India



40°C  
104°F

2022-05-21(Sat) 11:45(am)





PH7F+W4R, Sawangi, Maharashtra 442001, India

Sawangi  
Maharashtra  
India

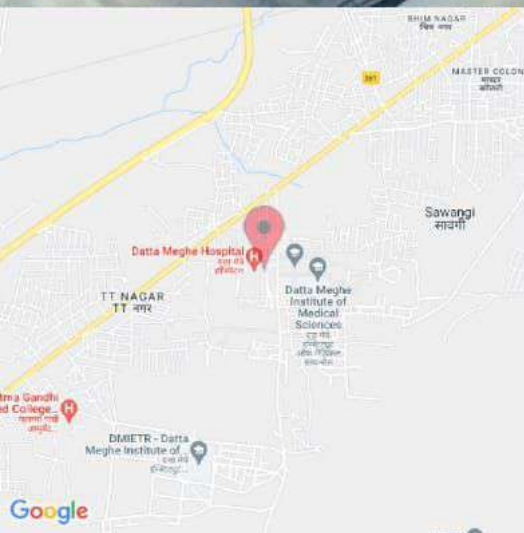
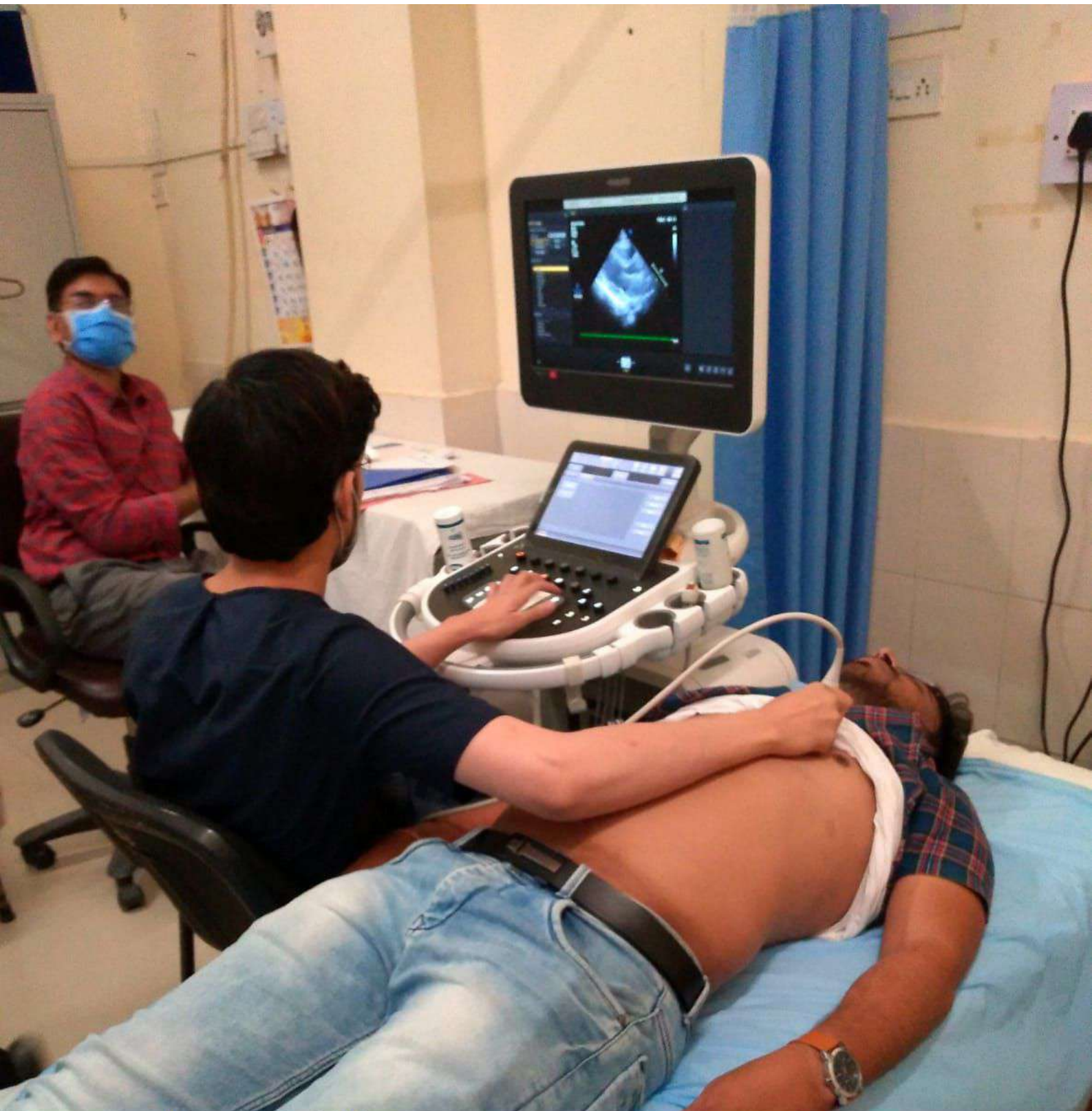
40°C

104°F

2022-05-21(Sat) 11:45(am)



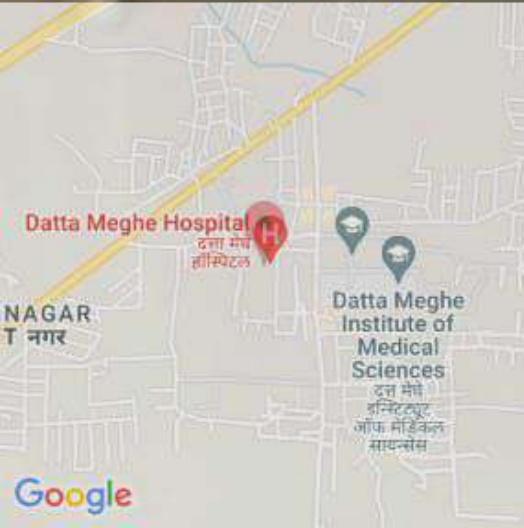

AVBRH Complex, Sawangi Meghe, Wardha, Maharashtra 442001, India

Wardha  
Maharashtra  
India

2022-05-21(Sat) 13:34





PH7F+W4R, Sawangi, Maharashtra 442001, India

Sawangi  
Maharashtra  
India

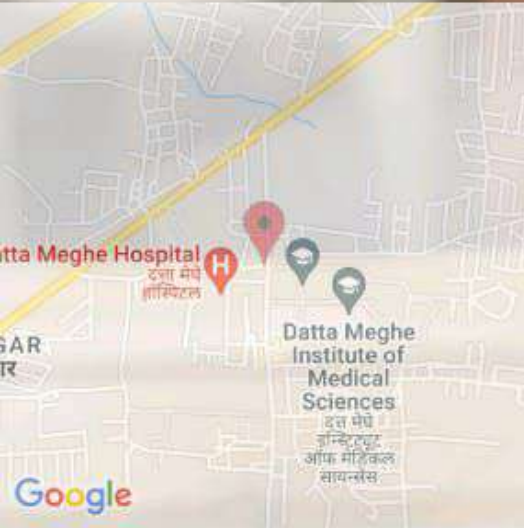


40°C

104°F

2022-05-21(Sat) 11:58(am)





PH8F+FJP, Sawangi, Maharashtra 442001, India

Sawangi  
Maharashtra  
India

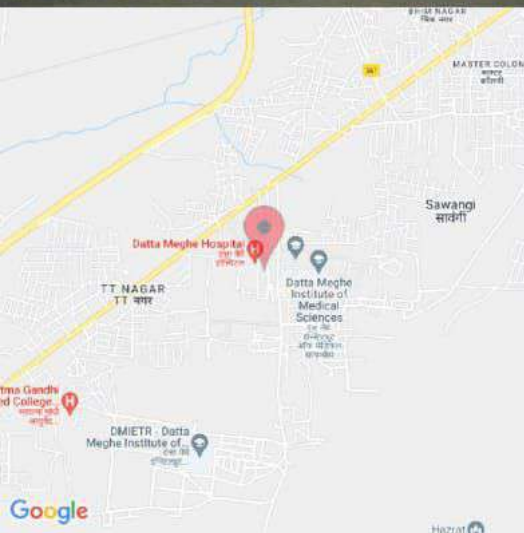

41°C

106°F

2022-05-21(Sat) 01:17(pm)



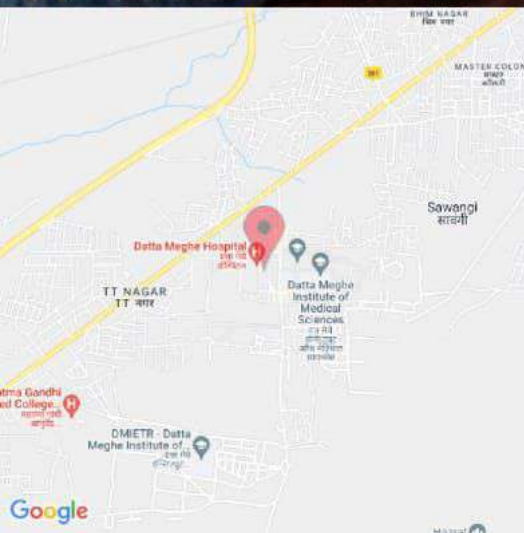
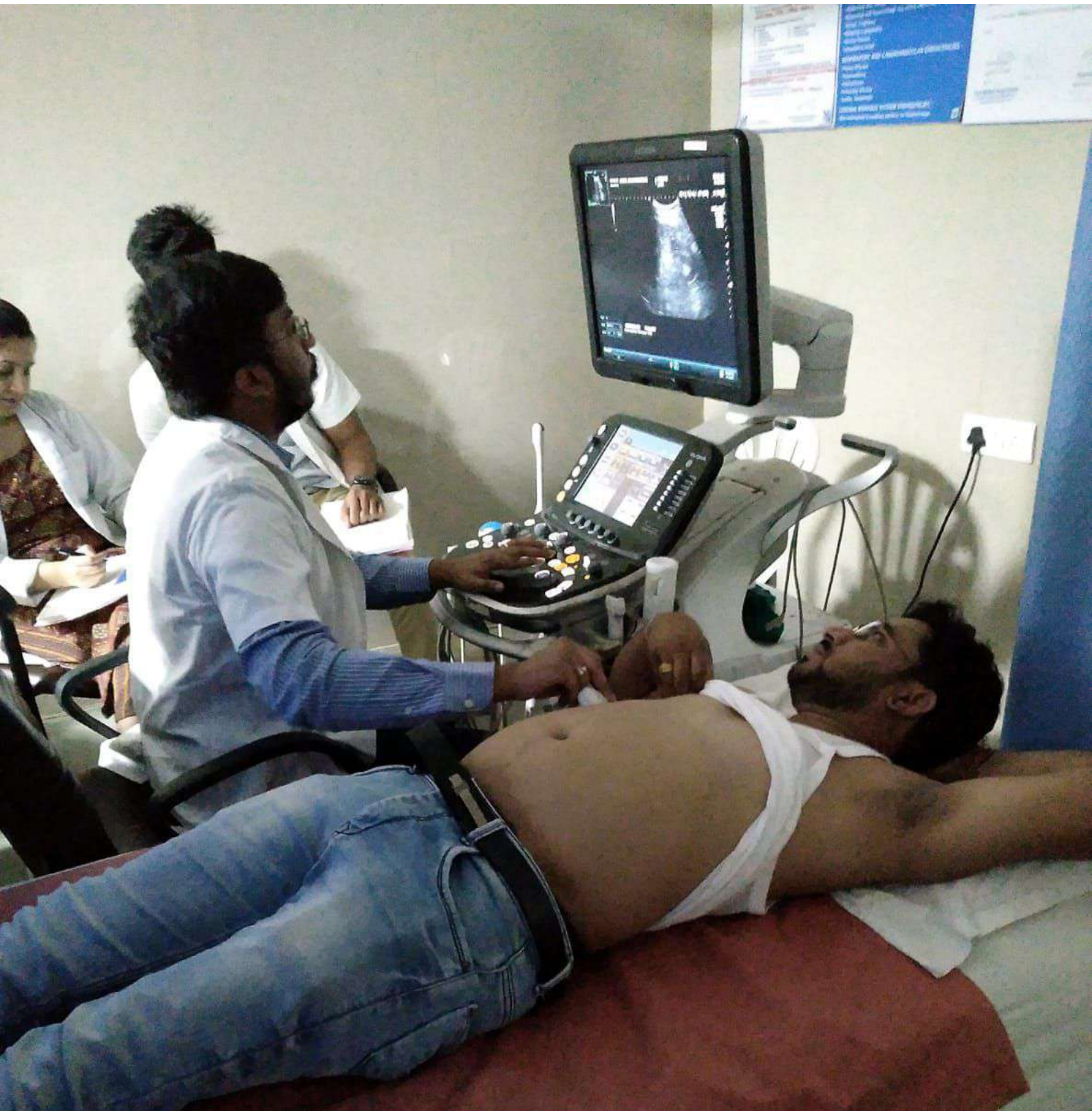

Ward no 4, medical college road Swangi Meghe, Wardha, Maharashtra 442001, India

Wardha  
Maharashtra  
India

2022-05-21(Sat) 11:09





PH7F+W85, Sawangi, Maharashtra 442001, India

Sawangi  
Maharashtra  
India

2022-05-21(Sat) 11:20



## NATIONAL AIDS CONTROL ORGANIZATION

## Laboratory Test Report form for HCTS Confirmatory facility

Name & Address of the SA-ICTC: J N M C Sawangi M) WardhaName: Surname Mule Middle Name Namdeo First Name PragullaGender:  Male  Female  TransgenderAge: 34 (years)PID No.: GC/PW/SAICTCMHWDH0032201649

Lab ID No.: \_\_\_\_\_

Date & Time of Blood Drawn: 21.5.22 (DD/MM/YY) \_\_\_\_\_ (HH:MM)

## Test Details:

- Specimen type used for testing (tick one): Serum / Plasma / Whole Blood
- Date & Time of specimen tested: 21.5.22 (DD/MM/YY) 2pm (HH:MM)

## Note:

- Column 2 and 3 to be filled only when HIV 1 & 2 antibody discriminatory test(s) used
- No cell has to be left blank; indicate as NA wherever not applicable

Column 1	Column 2	Column 3	Column 4
Name of the HIV kit	Reactive/Nonreactive (R/NR) for HIV-1 antibodies	Reactive/Nonreactive (R/NR) for HIV-2 antibodies	Reactive/Nonreactive (R/NR) for HIV-antibodies
Test I: <u>Comb AIDS Rs</u>	<u>N.A.</u>	<u>N.A.</u>	<u>NON REACTIVE</u>
Test II: <u>N.A.</u>	<u>N.A.</u>	<u>N.A.</u>	<u>N.A.</u>
Test III: <u>N.A.</u>	<u>N.A.</u>	<u>N.A.</u>	<u>N.A.</u>

Interpretation of the result: Tick (✓) relevant

- Specimen is Negative for HIV antibodies
- Specimen is Positive for HIV-1 antibodies
- \*Specimen is positive for HIV antibodies (HIV-1 and HIV-2; or HIV-2 alone)
- Specimen is indeterminate for HIV antibodies. Collect fresh sample in 2 weeks

\*Confirmation of HIV 2 sero-status at identified referral laboratory through ART centers

Name & Signature  
Laboratory technicianDEPT OF MICROBIOLOGY  
Name & Signature  
Laboratory in-charge





Datta Meghe Institute of Medical Sciences (Deemed to be University) NAAC Grade A+

# ACHARYA VINOBA BHAVE RURAL HOSPITAL

Transforming Lives Through Well Being

A Teaching Hospital of Jawaharlal Nehru Medical College, Sawangi (Meghe), WARDHA-442 004

Ph. : 07152-287701 - 06, 304000 Ext. 342 Visit us at : www.avbrhsawangimeghe.com Email : info@avbrhsawangimeghe.com



## DEPARTMENT OF RADIODIAGNOSIS

Patient Name Pratulla Mule Age 74 Sex m

RAF By \_\_\_\_\_ Date: 21/5/22

OPED /I.D. Rig No. 2205210049 Indication/Clinical OPD

LIVER: Normal in size 10.4 cm. shape and Echotexture. No focal Lesion noted.

IHBR : not dilated, portal vein CBD not dilated. Normal in course and caliber.

GB : Appears normal descendent/~~collapse~~, no calculus noted. Wall thickness appears normal.

PANCREAS : Normal in size, Shape and Echotexture.

SPLEEN : Normal in size 7.9 cm. Shape and Echotexture.

### RENALS:

Right Kidney : 8.8 x 4.4 cm

Left Kidney: 9 x 3.9 cm | (N)

Both Kidneys: Normal in size, Shape and Echotexture with CMD maintained. No focal lesion noted.

No hydromephrosis or calculus seen.

URINARY BLADDER: APPEARS normal, wall thickness is also normal. No local lesion noted.

No obvious mass lesion noted in the pelvis.

No ascitis seen.

### Uterus:

Endometrial thickness;

Right ovary:

Left ovary :

Left ovary:

Peritoneal Cavity: No free fluid noted

**IMPRESSION, NO OBVIOUS ABNORMALITY NOTED IN PRESENT SCAN**



Dr. Harshith Gowda

M. B. B. S.

Reg. No. 179362

Resident, Dept. of Radiodiagnosis

Date :- .....

Time :- ..... Signature

Dr. Harshith Gowda

No. Dr. J. R. J.

**Sign : Consultant Radiologist**



(Receiving of Specimen)

(Despatch of Report)

# MICROBIOLOGY REPORT

JNMC : \_\_\_\_\_

Lab. No. : 21/05/2022

Name : Pratfulko Mule

Age/Sex : 34/M

Reg. No. 2205210029


Ward/Bed \_\_\_\_\_ O.P.D.     

Consultant : \_\_\_\_\_

Specimen : Stool

Microscopy : \_\_\_\_\_

No pus cell, NO RBC, NO Ova &  
Cyst seen, NO OVA.



Signature Pratfulko Mule