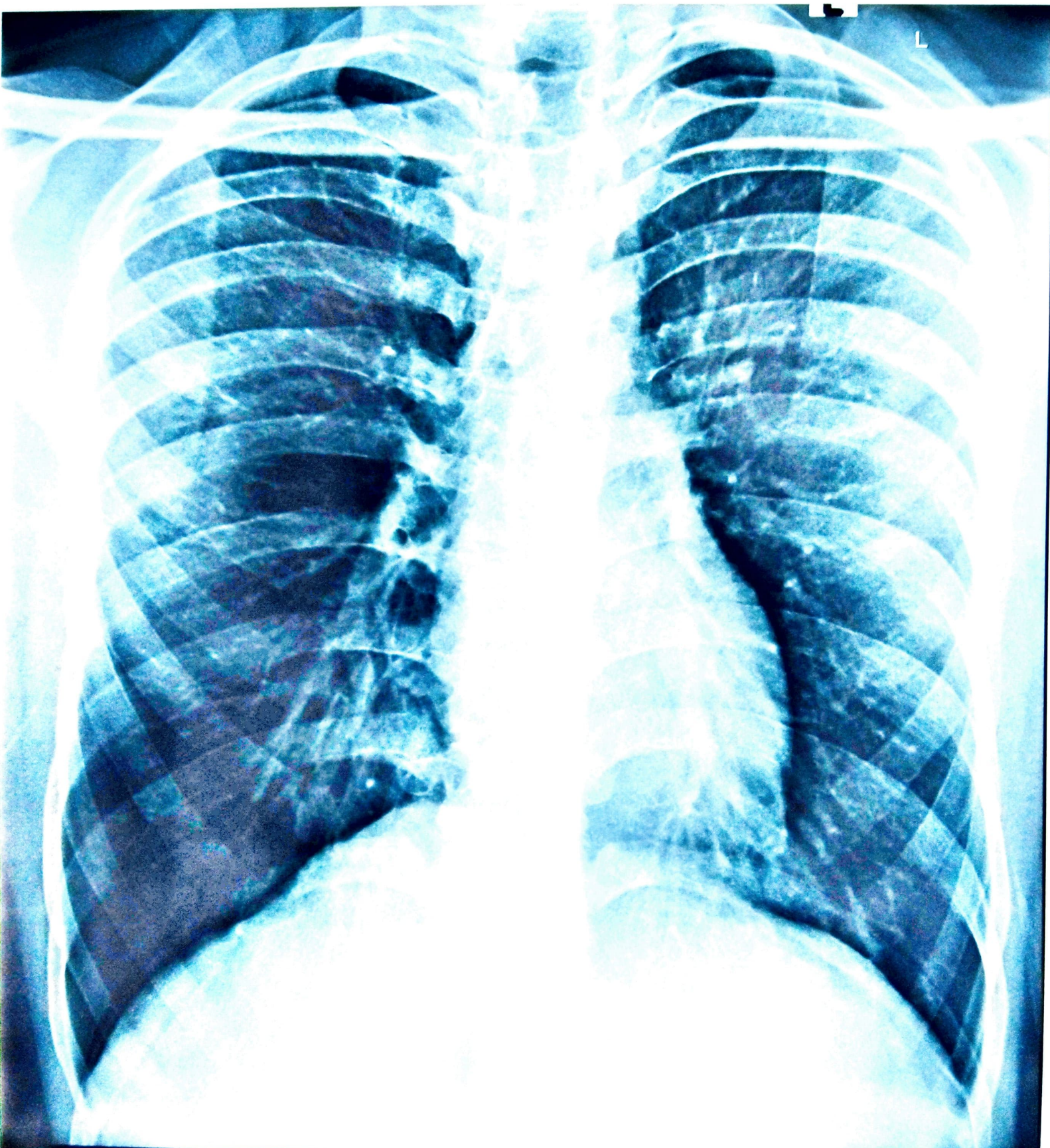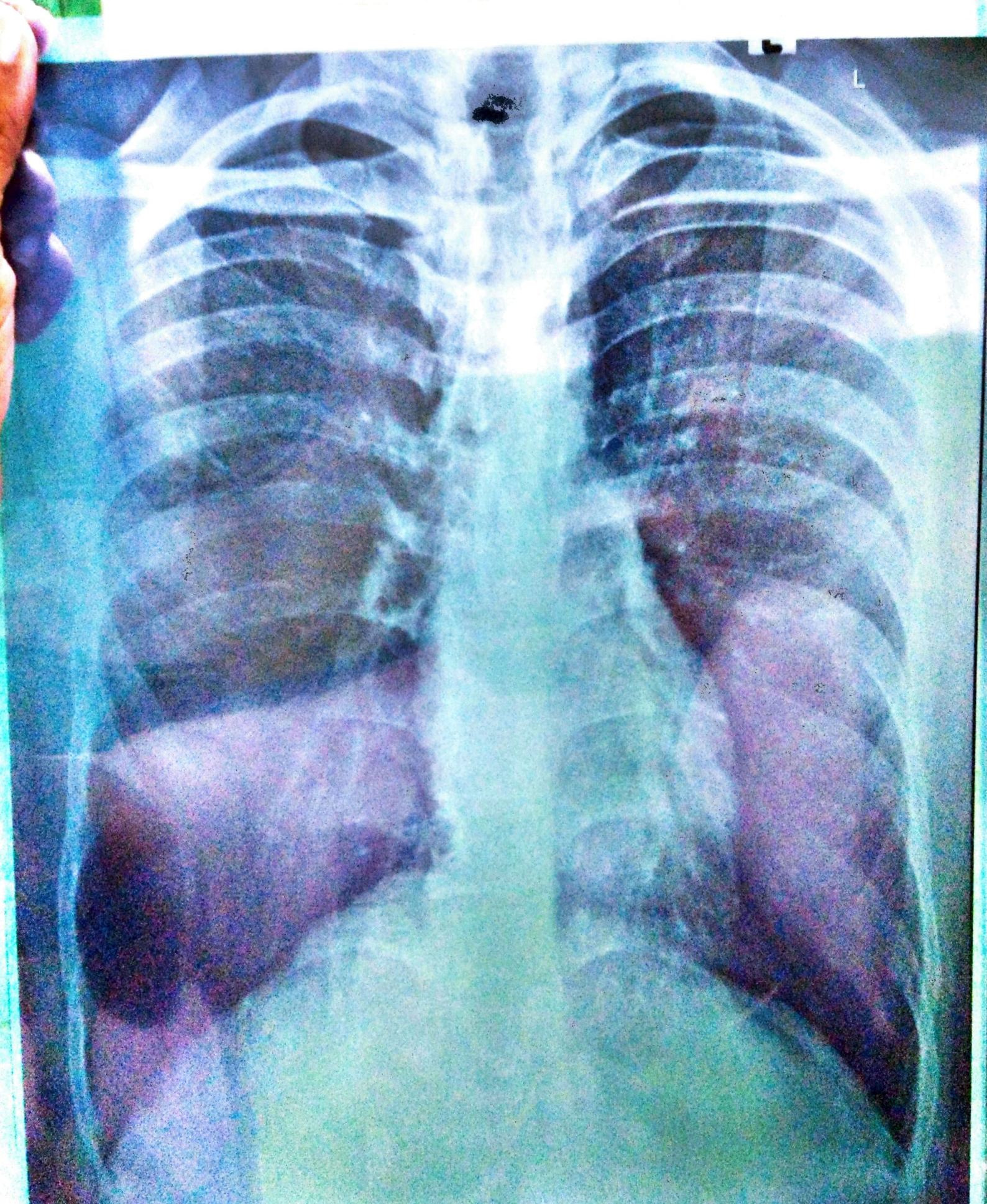





ANTULE ANMOLE AGE 25 YEARS 520 BY MEDIWHEEL TPA BOB CHEST,FRN P->A 5/22/2021
A.L.C. Advance Imaging Dignostics Centre PATNA-20



AMTULE ANMOLE AGE 25 YEARS 520 BY MEDIWHEEL TPA BOB CHEST,FRN P->A 5/22/2021
A.L.C. Advance Imaging Dignostics Centre PATNA-20


बैंक ऑफ बड़ोदा
Bank of Baroda



नाम **अंतुले अनमोल**
Name **ANTULE ANMOL**


कर्मचारी कूट क्र. **182866**
E.C. No.

आरीकर्ता प्राधिकारी, क्षेत्रीय प्रबंधक (पा.शे.)
Issuing Authority, Regional Manager (V.R.)



Antule Anmol
धारक के हस्ताक्षर
Signature of Holder

भारत सरकार
Government of India



अंतुले अनमोल
Antule Anmol
जन्म तिथि/DOB: 18/08/1995
पुरुष/ MALE

Download Date: 24/05/2020

Issue Date: 18/08/2018

2859 1465 5529
VID : 8168 7021 1303 8171

मेरा आधार, मेरी पहचान

ANTIGEN TEST REPORT

NAME :- *अंतुले अनमोल*

MOBILE :- *9826051212*

VILLAGE/MO-HALLA :- *...*


P.S. :- *...*

BLOCK :- *...*

DISTRICT :- *...*

NEGATIVE

DISTRICT HEALTH SOCIETY, PATNA



Antule Anmol

भारतीय विशिष्ट पहचान प्राधिकरण
Unique Identification Authority of India

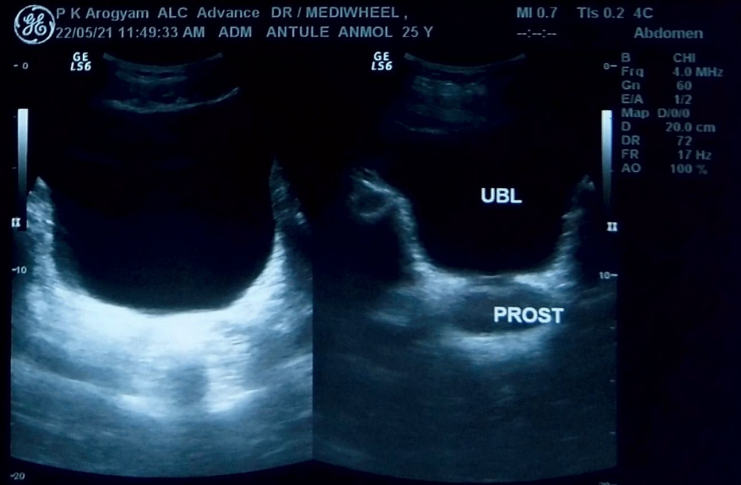
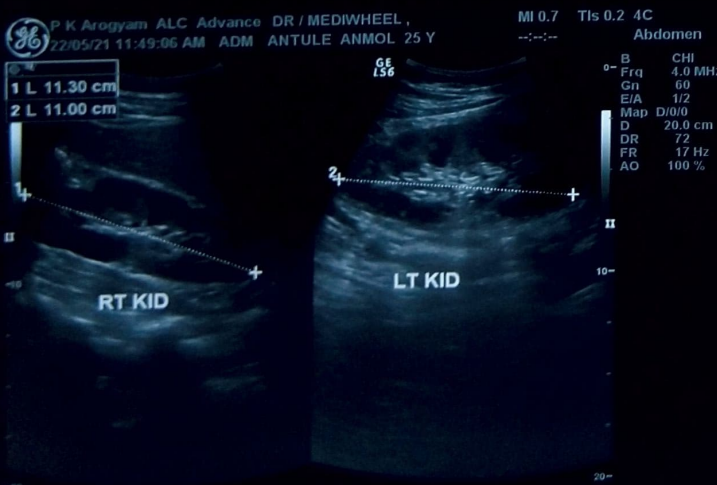
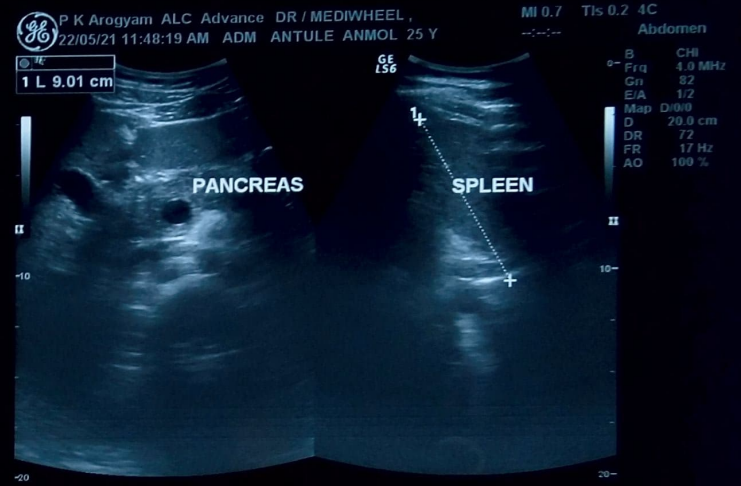
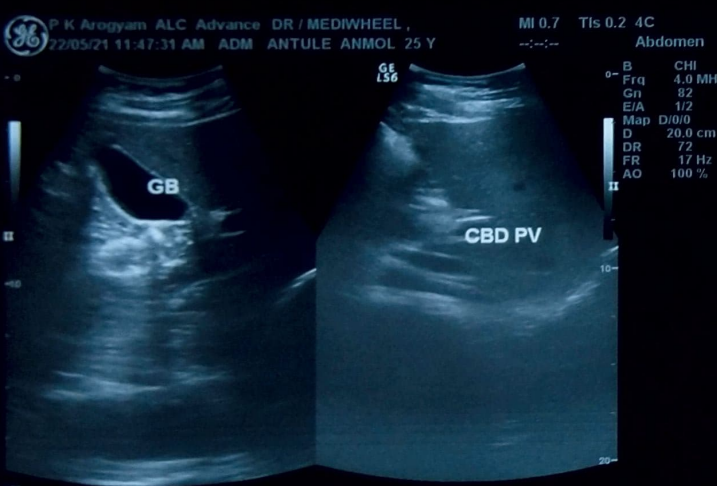
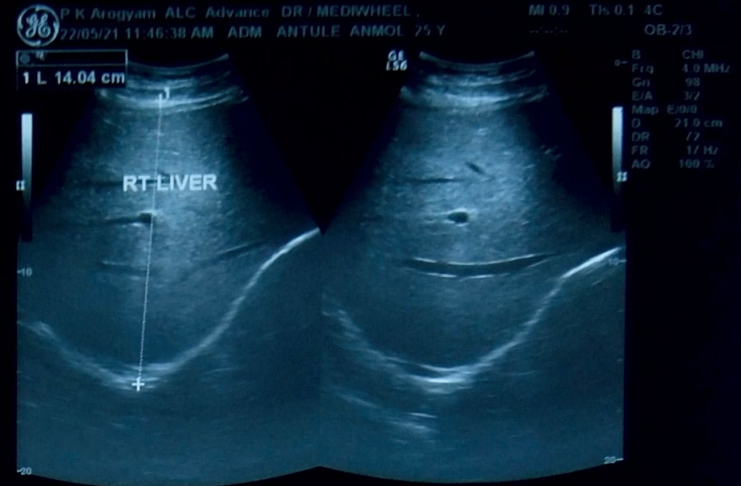
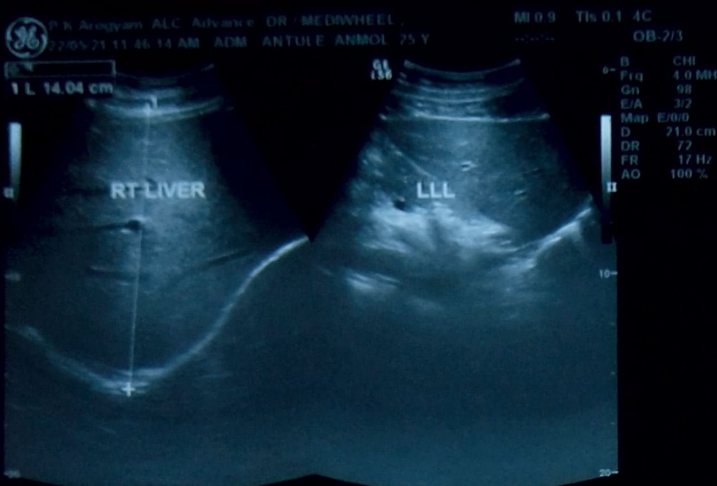
पता:
संबोधित: शंकर कुमार गुप्ता, पुरन्दर पुर, देवी स्थान,
डी.एम.दास, सम्पत्तचक, पटना,
बिहार - 800004

Address:
S/O: Shankar Kumar Gupta, PURANDAR
PUR, DEVI STHAN, B.M.DAS, Sampatchak,
Patna,
Bihar - 800004

2859 1465 5529
VID : 9156 7021 1303 5171

1947 | help@uidai.gov.in | www.uidai.gov.in

Antelle Amone





A.L.C. Advance Imaging Dignostics

ISO 9001:2015 Certified center

(A Unit of P.K.Arogyam Health & Wellness Center)

E-95, P.C. Colony, Near Sai Netryalaya Transformer, Kankarbagh, Patna - 20

alcdiagnostics@gmail.com

www.alhealthcheckup.in

7050037694, 8271206196

OPINION MUST BE CORRELATES WITH CLINICALLY & OTHER INVESTIGATION FOR FINAL DIAGNOSIS. NOT FOR MEDICO LEGAL PURPOSE

Pt. Name :- ANTUL ANMOL
Ref. By :- DR / MEDI WHEEL

Date:- 25-May-21
Age / Sex -25 Yrs. M

Thanks for your kind referral

X-RAYCHEST (P.A.VIEW)

The lungs on the either side show equal translucency.

The peripheral pulmonary vasculature is normal.

No focal lung lesion is seen.

The pleural spaces are normal.

Both hila are normal in size, have equal density and bear normal relationship.

The heart and trachea are central in position and no mediastinal abnormality is visible.

The cardiac size is normal.

The domes of the diaphragms are normal in position, and show smooth outline.

IMPRESSION

- NO EVIDENCE OF PULMONARY OR CARDIAC PATHOLOGY IS NOTED.

Le
25/5/21

ESTB BY:-

Dr. P. K. Tiwari
MD, BRIT (Radio Imaging)
Consultant Imagonologist

Dr. S. Kumar
MD (Pat)
Consultant Pathologist

Dr. Abhishek Kumar
MBBS, MD
Consultant Neuropatho Physiologist

Dr. Anjali
MBBS, MD
Consultant(TMT,EEG Specialist)

Dr. Kumari Suman
MBBS, DGO, MD
Consultant (TVS & HSG Specialist)

Consultant Radiologist

ID: 520 CASE: 1
AGE: 25 Y 05 M 23 D
165 Cms 66 Kg

ANTULE ANMOL
MALE

22/05/2021 13:03:32
ALC ADVANCE IMAGING DIAGNOSTICS
E95 PC COLONY KANKARBAGH PATNA

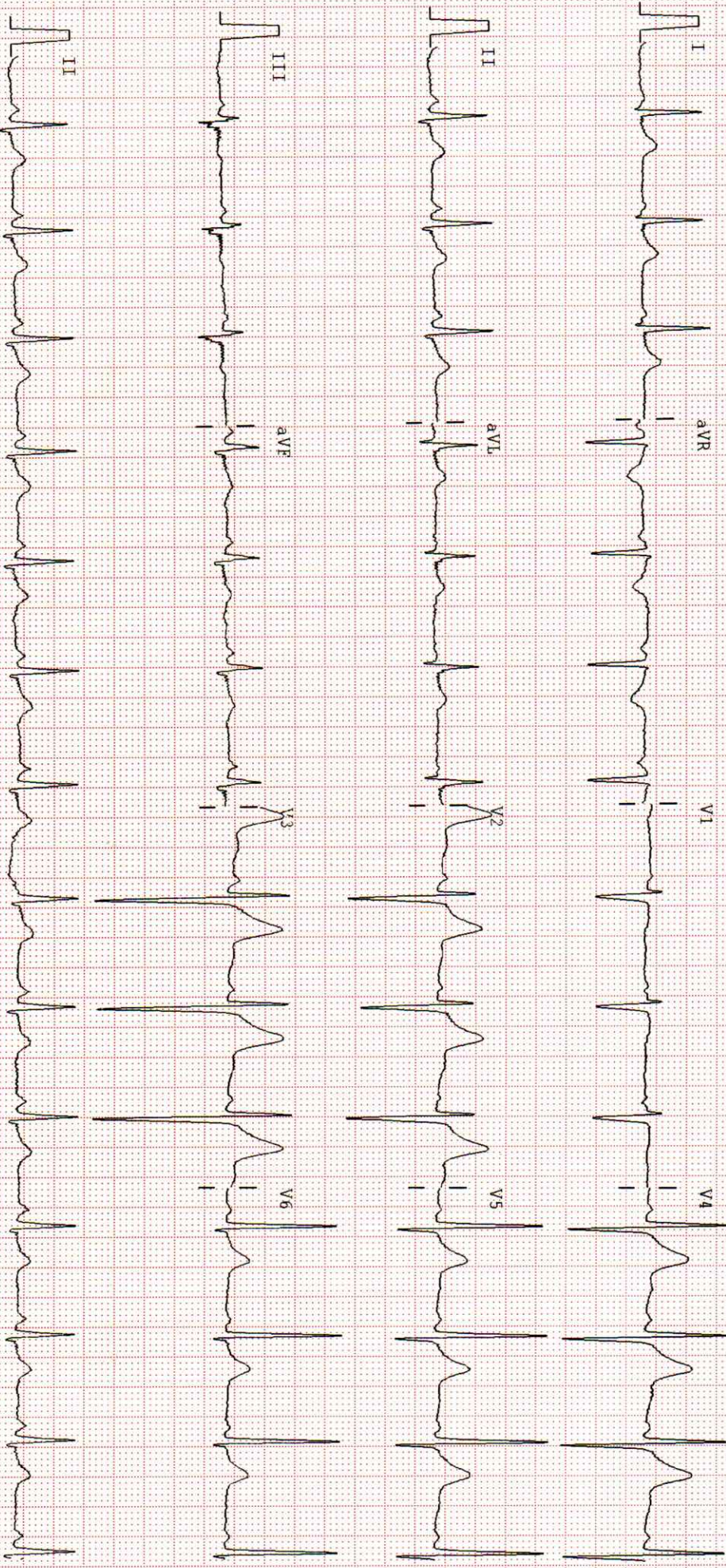
RATE : 81 bpm SINUS RHYTHM
R-R : 735 ms
P-R : 118 ms
QRS : 84 ms
QT : 350 ms
QTc : 387 ms

P : 59°
QRS : 28°
T : 18°

12 SL. REPORT FORMAT 3x4+1L SQ

REF: MEDIWHEEL, TPA BOB

Dr. DR. ABHISHEK KUMAR MBBS MD



25mm/sec 10mm/mV Notch: ON BLC: ON 0.05-35Hz

CHALLENGERS PROPERTY. USE ONLY AS A CLINICALLY CORRELATE THE FINDINGS.



A.L.C. Advance Imaging Dignostics

ISO 9001:2015 Certified center

(A Unit of P.K.Arogyam Health & Wellness Center)

E-95, P.C. Colony, Near Sai Netryalaya Transformer, Kankarbagh, Patna - 20

alcdiagnostics@gmail.com

www.alchealthcheckup.in

7050037694, 8271206196

OPINION MUST BE CORRELATES WITH CLINICALLY & OTHER INVESTIGATION FOR FINAL DIAGNOSIS. NOT FOR MEDICO LEGAL PURPOSE

PATIENT NAME : Mr. ANTULE ANMOLE PATIENT ID: 46
COL DATE : 22/05/2021 REPORTING DATE: 22/05/2021 AGE SEX:- 26 YRS/M
REF.BY : DR. / MEDIWHEAL TPA B.O.B.

TEST NAME	RESULT	Unit	REF.RANGE
-----------	--------	------	-----------

BLOOD GROUP	:	'B'	
Rh Typing	:	POSITIVE	

Note: Do always cross – matching before blood transfusion

ESTB BY:-

Dr. P. K. Tiwari
MD, BRIT (Radio Imaging)
Consultant Imacionologist

Dr. S. Kumar
MD (Pat)
Consultant Pathologist

Dr. Abhishek Kumar
MBBS, MD
Consultant Neuropatho Physiologist

Dr. Anjali
MBBS, MD
Consultant(TMT,EEG Specialist)

Dr. Kumari Suman
MBBS, DGO, MD
Consultant (TVS & HSG Specialist)

Consultant Radiologist

PRINTING MISTAKE SHOULD BE REPORTED BACK IMMEDIATELY/ यहाँ जन्म से पहले भ्रुण का लिंग जाँच नहीं होता है ।



A.L.C. Advance Imaging Diagnostics

ISO 9001:2015 Certified center

(A Unit of P.K.Arogyam Health & Wellness Center)

E-95, P.C. Colony, Near Sai Netryalaya Transformer, Kankarbagh, Patna - 20

alcdiagnostics@gmail.com

www.alhealthcheckup.in

7050037694, 8271206196

OPINION MUST BE CORRELATES WITH CLINICALLY & OTHER INVESTIGATION FOR FINAL DIAGNOSIS. NOT FOR MEDICO LEGAL PURPOSE

PATIENT NAME : Mr. ANTULE ANMOLE

PATIENT ID: 46

COL DATE : 22/05/2021 REPORTING DATE: 22/05/2021 AGE SEX : 26YRS/M

REF.BY : DR./ MEDIWHEAL TPA B.O.B.

GLYCOSYLATED HEMOGLOBIN

TEST NAME	RESULT	Unit	REF.RANGE
HbA1c	4.7 %		Below 5.7 % : Normal 5.7 – 6.4 % : Prediabetic > = 6.5 % : Diabetic
AVERAGE PLASMA GLUCOSE	112.0	mg/dl	90 – 120 mg/dl : Good Control 121– 150 mg/dl : Fair Control 151- 180 mg/dl: Unsatisfactory Control >180 mg/dl : Poor Control

ESTB BY:-

Consultant Radiologist

Dr. P. K. Tiwari
MD, BRIT (Radio Imaging)
Consultant Imaginologist

Dr. S. Kumar
MD (Pat)
Consultant Pathologist

Dr. Abhishek Kumar
MBBS, MD
Consultant Neuropatho Physiologist

Dr. Anjali
MBBS, MD
Consultant(TMT,EEG Specialist)

Dr. Kumari Suman
MBBS, DGO, MD
Consultant (TVS & HSG Specialist)



A.L.C. Advance Imaging Dignostics

ISO 9001:2015 Certified center

(A Unit of P.K.Arogyam Health & Wellness Center)

E-95, P.C. Colony, Near Sai Netryalaya Transformer, Kankarbagh, Patna - 20

alcdiagnostics@gmail.com

www.alhealthcheckup.in

7050037694, 8271206196

OPINION MUST BE CORRELATES WITH CLINICALLY & OTHER INVESTIGATION FOR FINAL DIAGNOSIS. NOT FOR MEDICO LEGAL PURPOSE

PATIENT NAME : Mr. ANTULE ANMOLE PATIENT ID: 46
COL DATE : 22/05/2021 REPORTING DATE: 22/05/2021 AGE SEX:- 26 YRS/M
REF.BY : DR./ MEDIWHEAL B.O.B.

TEST NAME	RESULT	Unit	REF.RANGE
ESR	10 mm/hr		<20 mm/hr
CBC			
Total W.B.C. Count	6200 /cumm		4000-11,000 /cumm
R B C COUNT	5.1 Million/ CUmm		4.-7 Million/ CUmm
Platelets count	1.74 Lakh/ cumm		1.5-5.0 Lakh/ cumm
Differential Count of W.B.C.			
Neutrophils	65 %		40-70%
Lymphocytes	30 %		25-40%
Eosinophils	03 %		01-05%
Mnonocytes	02 %		00-02%
Basophiles	00 %		00-0%
HAEMOGLOBIN	14.0 gm/dl (95.8 %)		14.6 gm/dl = 100%
PCV	41.5 %		35-47 %
MCV	81.5 fl		76-96 fl
MCH	27.9 pg		29-35 pg
MCHC	33.8 %		30-38 %

ESTB BY:-

Dr. P. K. Tiwari
MD, BRIT (Radio Imaging)
Consultant Imagonologist

Dr. S. Kumar
MD (Pat)
Consultant Pathologist

Dr. Abhishek Kumar
MBBS, MD
Consultant Neuropatho Physiologist

Dr. Anjali
MBBS, MD
Consultant(TMT,EEG Specialist)

Dr. Kumari Suman
MBBS, DGO, MD
Consultant (TVS & HSG Specialist)

Consultant Radiologist



A.L.C. Advance Imaging Dignostics

ISO 9001:2015 Certified center

(A Unit of P.K.Arogyam Health & Wellness Center)

E-95, P.C. Colony, Near Sai Netryalaya Transformer, Kankarbagh, Patna - 20

alcdiagnostics@gmail.com

www.alchealthcheckup.in

7050037694, 8271206196

OPINION MUST BE CORRELATES WITH CLINICALLY & OTHER INVESTIGATION FOR FINAL DIAGNOSIS. NOT FOR MEDICO LEGAL PURPOSE

PATIENT NAME : Mr. ANTULE ANMOLE

PATIENT ID: 46

COL DATE : 22/05/2021 REPORTING DATE: 22/05/2021 AGE SEX:- 26 YRS/F

REF.BY : DR / MEDIWHEAL TPA B.O.B.

TEST NAME	RESULT	Unit	REF.RANGE
-----------	--------	------	-----------

LFT:-

SGPT	15.7	IU/L	5 - 40 IU/L
S G O T	27.4	IU/L	5 - 40 IU/L
ALKALINE PHOSPHATASE	102.3	IU/L	25-147 IU/L
SERUM ALBUMIN	5.1	g/dl	3.5 --5.4 g/dl
SERIUM GLUBLINE	2.8	g/dl	2.3 -- 3.6 g/dl
AG RATIO	1.8 : 1		1.0—2.3 g/dl
BILIRUBIN			
TOTAL	0.7	mg/dl	0.1- 1.0mg/dl
DIRECT	0.3	mg/dl	0.0- 0.3mg/dl
INDIRECT	0.4	mg/dl	0.0- 0.7 mg/dl

KFT/RFT

URIC ACID	4.3	mg/dl	3.2—7.0 mg/dl
TOTAL PROTIN	7.9	g/dl	6.0--8.7 g/dl
SERUM CREATNINE	0.7	mg/dl	0.6-1.5 mg/dl
BLOOD UREA	29.6	mg/dl	5 - 45 mg/dl
BLOOD URIA NITROZEN(BUN).	13.8	mg/dl	13- 39 mg/dl
BUN/CREATININE RATIO	19.7:1		

ESTB BY:-

Consultant Radiologist

Dr. P. K. Tiwari
MD, BRIT (Radio Imaging)
Consultant Imagonologist

Dr. S. Kumar
MD (Pat)
Consultant Pathologist

Dr. Abhishek Kumar
MBBS, MD
Consultant Neuropatho Physiologist

Dr. Anjali
MBBS, MD
Consultant(TMT,EEG Specialist)

Dr. Kumari Suman
MBBS, DGO, MD
Consultant (TVS & HSG Specialist)



A.L.C. Advance Imaging Dignostics

ISO 9001:2015 Certified center

(A Unit of P.K.Arogyam Health & Wellness Center)

E-95, P.C. Colony, Near Sai Netryalaya Transformer, Kankarbagh, Patna - 20

alcdiagnostics@gmail.com

www.alhealthcheckup.in

7050037694, 8271206196

OPINION MUST BE CORRELATES WITH CLINICALLY & OTHER INVESTIGATION FOR FINAL DIAGNOSIS. NOT FOR MEDICO LEGAL PURPOSE

PATIENT NAME : Mr. ANTULE ANMOLE PATIENT ID: 46
COL DATE : 22/05/2021 REPORTING DATE: 22/05/2021 AGE SEX : 26 YRS/M
REF.BY : DR. /MEDIWHEAL TPA B.O.B.

TEST NAME	RESULT	Unit	REF.RANGE
BLOOD SUGAR (F)	82.0 mg/dl		70-110 mg/dl
BLOOD SUGAR (PP)	117.0 mg/dl		70-140 mg/dl
LIPID PROFILE:-			
TOTAL CHOLESTROL	192.4 mg/dl		130-250 mg/dl
TRIGLYCERIDE	122.5 mg/dl		50-160 mg/dl
HDL CHOLESTROL	46.0 mg/dl		30- 60 mg/dl
LDL CHOLESTROL	121.9 mg/dl		80-130 mg/dl
VLDL CHOLESTROL	24.5 mg/dl		15-40 mg/dl
T.CH./HDL RATIO	4.0:1		
LDL./HDL RATIO	2.6:1		

ESTB BY:-

Consultant Radiologist

Dr. P. K. Tiwari
MD, BRIT (Radio Imaging)
Consultant Imagonologist

Dr. S. Kumar
MD (Pat)
Consultant Pathologist

Dr. Abhishek Kumar
MBBS, MD
Consultant Neuropatho Physiologist

Dr. Anjali
MBBS, MD
Consultant(TMT,EEG Specialist)

Dr. Kumari Suman
MBBS, DGO, MD
Consultant (TVS & HSG Specialist)

PRINTING MISTAKE SHOULD BE REPORTED BACK IMMEDIATELY/ यहाँ जन्म से पहले भ्रुण का लिंग जाँच नहीं होता है ।



A.L.C. Advance Imaging Dignostics

ISO 9001:2015 Certified center

(A Unit of P.K.Arogyam Health & Wellness Center)

E-95, P.C. Colony, Near Sai Netryalaya Transformer, Kankarbagh, Patna - 20

alcdiagnostics@gmail.com

www.alhealthcheckup.in

7050037694, 8271206196

OPINION MUST BE CORRELATES WITH CLINICALLY & OTHER INVESTIGATION FOR FINAL DIAGNOSIS. NOT FOR MEDICO LEGAL PURPOSE

PATIENT NAME : Mr . ANTULE ANMOLE

PATIENT ID: 46

COL DATE : 22/05/2021 REPORTING DATE: 22/05/2021 AGE SEX:- 26 YRS/F

REF.BY : DR./MEDIWHEAL TPA B.O.B.

ROUTINE EXAMINATION OF URINE

PHYSICAL EXAMINATION

Volume 20 ml

Colour Straw

Appearance Clear

Sediments Nil

Specific Gravity 1.010

CHEMICAL EXAMINATION

PH 5.0

Reaction ACIDIC

Sugar NIL

Albumin NIL

Phosphate.... Nil

Nitrite Not done

MICROSCOPIC EXAMINATION

Erythrocytes.... Nil

Pus cells 1-3 / HPE

Epithelial Cells A, Few

Other Nil

ESTB BY:-

Consultant Radiologist

Dr. P. K. Tiwari
MD, BRIT (Radio Imaging)
Consultant Imagonologist

Dr. S. Kumar
MD (Pat)
Consultant Pathologist

Dr. Abhishek Kumar
MBBS, MD
Consultant Neuropatho Physiologist

Dr. Anjali
MBBS, MD
Consultant(TMT,EEG Specialist)

Dr. Kumari Suman
MBBS, DGO, MD
Consultant (TVS & HSG Specialist)



A.L.C. Advance Imaging Dignostics

ISO 9001:2015 Certified center

(A Unit of P.K.Arogyam Health & Wellness Center)

E-95, P.C. Colony, Near Sai Netryalaya Transformer, Kankarbagh, Patna - 20

alcdiagnostics@gmail.com

www.alchealthcheckup.in

7050037694, 8271206196

OPINION MUST BE CORRELATES WITH CLINICALLY & OTHER INVESTIGATION FOR FINAL DIAGNOSIS, NOT FOR MEDICO LEGAL PURPOSE

PATIENT NAME : Mr. ANTELE ANMOLE

PATIENT ID: 46

COL DATE : 22/05/2021 REPORTING DATE: 22/05/2021 AGE SEX : 26 YRS/M

REF.BY : DR./ MEDIWHEAL TPA B.O.B.

ROUTINE EXAMINATION OF STOOL

PHYSICAL EXAMINATION

Colour : Brownish

Consistency : Semisolid

Mucus : Absent

Blood : Absent

CHEMICAL EXAMINATION

Reaction : Acidic

Reducing Substance: Absent

Occult Blood : Absent

MICROSCOPIC EXAMINATION

Pus cell : 0-4

RBCs : Absent

Ova/Eggs : Absent

Veg. Cell/ Fibres : Present

Cyst : Absent

Fat globules : Absent

Macrophages : Absent

ESTB BY:-

Dr. P. K. Tiwari
MD, BRIT (Radio Imaging)
Consultant Imagiologist

Dr. S. Kumar
MD (Pat)
Consultant Pathologist

Dr. Abhishek Kumar
MBBS, MD
Consultant Neuropathologist

Dr. Anjali
MBBS, MD
Consultant(TMT,EEG Specialist)

Dr. Kumari Suman
MBBS, DGO, MD
Consultant (TVS & HSG Specialist)

Consultant Radiologist



A.L.C. Advance Imaging Dignostics

ISO 9001:2015 Certified center

(A Unit of P.K.Arogyam Health & Wellness Center)

E-95, P.C. Colony, Near Sai Netryalaya Transformer, Kankarbagh, Patna - 20

alcdiagnostics@gmail.com

www.alhealthcheckup.in

7050037694, 8271206196

OPINION MUST BE CORRELATES WITH CLINICALLY & OTHER INVESTIGATION FOR FINAL DIAGNOSIS. NOT FOR MEDICO LEGAL PURPOSE

Pt. Name :- ANTUL ANMOL
Ref. By :- DR / MEDI WHEEL

Date:- 25-May-21
Age / Sex -25 Yrs. M

REAL TIME U.S.G. OF WHOLE ABDOMEN

Thanks for your kind referral

(Report.)

- LIVER** :- Measures 12.35 cm. Normal in shape, size and echo texture. I.H.B.R. are not dilated. Hepatic veins are normal. No SOL seen.
- G.BL.** :- Lumen is echo free. Wall thickness appears normal.
- C.B.D.** :- Measures 3.3 mm in diameter with echo free lumen. No calculi or mass seen.
- P.V.** :- Measures 7.2 mm in diameter. Appears normal. No thrombus seen.
- PANCREAS** :- Normal in shape, size and echo texture. No calcification mass seen.
- SPLEEN** :- Measures 9.0 cm. Normal in shape, size and echo texture. No SOL seen.
- KIDNEY** :- Both kidney shows normal shape, size & echotexture. C.M.D.intact. P.C.S.is not dilated. No calculi, cyst or hydronephrosis seen on either side.
Right Kidney :- Measures 11.30 X 4.7 cm.
Left Kidney :- Measures 11.0 X 4.6 cm.
- cm.**
- URETER** :- Not dilated. No apparent calculi seen.
- U.BLADDER**:- Shows normal in outline with echo free lumen. No calculi or mass seen.
Pre void - 210 ml. Post void - is in significant
- PROSTATE** :- Normal in Size Shape Capsule is intact
- R.I.F.** :- Son graphically no appendicular mass or collection seen.
- OTHERS** :- No Ascites. no Lymph Adenopathy. No pleural effusion seen on either side.

IMPRESSION

➤ **Son graphically normal scan no detectable lesion seen**

25/5/21

Consultant Radiologist

ESTB BY:-

Dr. P. K. Tiwari
MD, BRIT (Radio Imaging)
Consultant Imaginationologist

Dr. S. Kumar
MD (Pat)
Consultant Pathologist

Dr. Abhishek Kumar
MBBS, MD
Consultant Neuropathologist

Dr. Anjali
MBBS, MD
Consultant (TMT, EEG Specialist)

Dr. Kumari Suman
MBBS, DGO, MD
Consultant (TVS & HSG Specialist)