



YASHFEEN CARDIAC HOSPITAL

Kaivan Shah
 CH22043573 28/01/2023
 VAISHALI NIKUNJ PATEL
 32/F
 Valsad, Valsad 9601267949



Chief Complaint :

Medical History : DM / HT / Asthama / Allergy / Heart / Thyroid / ...

Ocular History :

H/O ciliary muscle

Visual Acuity :

6/18 R
6/18 L

NAME |
 28 JAN 2023 PM 12:52
 NO. 0169
 SN: 4771998
 REF. DATA
 VD: 12.00 CYL: MIX
 <R> S C A
 - 1.00 - 0.75 178
 - 1.00 - 0.75 177
 - 1.00 - 1.00 177
 - 1.00 - 0.75 177
 S. E. - 1.50
 <L> S C A
 - 1.50 - 0.50 18
 - 1.50 - 0.50 18

TOP :

	RIGHT EYE (PH.....)				LEFT EYE (PH.....)			
	Sph.	Cyl.	Axis	V/A	Sph.	Cyl.	Axis	V/A
Distance	-1.00	-0.75	180	6/18	-1.50	-	-	6/18
Near	-	-	-	all	-	-	-	No

Distance/Reading/Bi-Focal/Progressive/Separate Glasses

Sle :



Asy
Reg. Kees
Alta 1yr



YASHFEEN IMAGING & RADIOLOGY DEPARTMENT

MANAGED BY :- YASHFEEN FOUNDATION

VIRAVAL, NAVSARI. 396 445. PHONE : (H) (02637) 235725

Website : www.yashfeenhospital.in E-mail : info@yashfeenhospital.in

Name	VAISHALI NIKUNJ PATEL	Age	32Y/F
Ref by Dr	Self	Date	28/01/2023

USG ABDOMEN & PELVIS (SCREENING) (TVS)

Liver appears normal in size & shape with normal echopattern.
No e/o focal or diffuse lesion. IHBR appear normal.
PV and CBD appear normal.

Gall bladder appears distended & normal in shape & size. No e/o calculus or mass seen.
Walls appear normal.

Pancreas appears normal in size and echogenicity. No e/o focal or diffuse lesion.

Spleen appears normal in size and shows normal echopattern. No e/o focal lesion.

Both Kidneys appear normal in size and echopattern. CM Differentiation is preserved.
No e/o calculus or hydronephrosis on either side.
Perirenal spaces appear normal on either side.
Suprarenal regions appear normal on either side. No e/o mass lesion.

Bladder is empty (due to non-compliance of patient). Adv: Follow up USG with normally distended bladder.

Uterus appears anteverted, normal in size & shows normal echopattern.
Endometrial cavity is empty. ET- 5 mm. No e/o focal or diffuse mass lesion.
Both ovaries appear normal in size & echopattern.
No e/o adnexal mass on either side.

RIF region appears normal.

No e/o ascites.

IMPRESSION:

No significant abnormality detected.



Dr. DHARMESH DESAI
(M.D. Radiology)
Reg. No. G - 45284
Dr. Dharmesh Desai
YASHFEEN GROUP OF HOSPITAL



YASHFEEN CARDIAC HOSPITAL™

MANAGED BY :- YASHFEEN FOUNDATION

VIRAVAL, NAVSARI. 396 445. PHONE : (H) (02637) 235725

Website : www.yashfeenhospital.in E-mail : info@yashfeenhospital.in



(Regd. No. E / 1390 / Navsari)

2D ECHO CARDIOGRAPHY COLOUR DOPPLER REPORT

Patient Name & No	: VAISHALI NIKUNJ PATEL CH22043475	Age/Sex	UHID :	: 6708
Doctor	: Mohil Nagad	32/ F	No :	: 6920
Referred By	:		Date :	: 28/01/2023

M-Mode findings

LVIDd : 40mm
 LVIDs : 28mm
 IVSd : 10mm
 PWd : 10mm
 EF : 60%
 Aorta : 22mm
 LA : 38mm

2D Imaging

Aortic Valve : Trileaflet, Normal
 Mitral Valve : Thin, Pliable, Normal Mobility, Mild MR.
 Tricuspid Valve : Trivial TR, RVSP: 20+ RAP
 Pulmonary Valve : Normal

=> : Dilated LA
 => : No regional wall motion abnormality.
 => : Normal LV systolic function.
 => : Normal LV diastolic function.
 => : IAS/IVS intact.
 => : No obvious clots/ vegetations/ or effusion.
 => : IVC Normal size.

Doppler Findings

=> : No MS/Mild MR, No TS/Trivial TR, No AS/AR & No PS/PR
 Mitral inflow Pattern : E > A
 Tissue Doppler Findings : E' > A'

Impression : Normal LVEF:60%, No RWMA, Mild MR, Dilated LA.



Report Prepared By

Report Checked By
DR. MOHIL NAGAD
 M.D. Medicine, DM, Cardiology
 Senior Consultant- Interventional Cardiology
 Non-Invasive Cardiologist
 Reg. No. G-22893
 YASHFEEN HOSPITAL, NAVSARI

Designed By : Sarita Infotech Pvt. Ltd., Navsari

YASHFEEN IMAGING & RADIOLOGY DEPARTMENT

MANAGED BY :- YASHFEEN FOUNDATION

VIRAVAL, NAVSARI. 396 445. PHONE : (H) (02637) 235725

Website : www.yashfeenhospital.in E-mail : info@yashfeenhospital.in

Patient's Name:	VAISHALI N. PATEL	Age & Sex:	32Yrs/F
Ref. by Dr.	Self	Date:	28-01-2023

X RAY CHEST (PA VIEW)

Both lung fields appear normal.

Both hila appear normal.

Both CP angles appear clear.

Cardiac size appears within normal limit.


Both domes of diaphragm appear normal.

Bony thoracic cage appears normal.

IMPRESSION:

- Normal X-ray chest (PA view).




Dr. DHARMESH DESAI
(M.D. Radiology)
Reg. No. MB - 45284
YASHFEEN GROUP OF HOSPITAL

Please contact immediately for any typographical error.
This is only professional opinion, not a final diagnosis. Kindly correlate clinically. Not valid for medicolegal purpose.



YASHFEEN CARDIAC HOSPITAL™

At. & Po. Viraval, Navsari. 396 445. Phone (H) (02637) 235725

Website : www.yashfeenhospital.in E-mail : info@yashfeenhospital.in
(For Laboratory Reports Only)



Patient Name : VAISHALI NIKUNJ PATEL

Age : 32 Years Sex : F

Ref By Dr. : -

Area : Valsad

Date : 28/01/2023

Sample Time : 28/01/2023 09:00 No : 9

Time : 12:12PM

ROUTINE URINE ANALYSIS

Test	Findings	UOM	Normal Range
------	----------	-----	--------------

PHYSICAL EXAMINATION

Quantity	-	-	-
Colour	YELLOW	-	-
Appearance	CLEAR	-	-
Reaction	ACIDIC	-	-
Sp. Gravity	1.002	-	-

CHEMICAL EXAMINATION

U.Albumin	NIL	-	-
Sugar	NIL	-	-
Acetone	NIL	-	-
Bile Salt	NIL	-	-
Bile Pigment	NIL	-	-
Occult Blood	NIL	-	-

MICROSCOPIC EXAMINATION

Pus Cells	<u>2-3</u>	/hpf	
Epithelial cells	<u>2-3</u>	/hpf	
Red cells	ABSENT	/hpf	
Casts	-	/hpf	
Crystals	<u>AMORPHOUS SEEN</u>	/hpf	
Others	<u>BACTERIA {FEW} SEEN</u>	/hpf	



f. Chaudh.
Dr. PIYUSH B. CHAUDHARI
M.D. Medicine
Reg. No. G-21518

Remarks

Designed By : Sarita Infotech Pvt. Ltd., Navsari

Yashfeen Cardiac Hospital

H. Patel
signature

Technician

Thanks for Reference

Test reports are subject to technical limitations and should be clinically co-related. Laboratory may be contacted whenever required.



YASHFEEN CARDIAC HOSPITAL™

At. & Po. Viraval, Navsari. 396 445. Phone (H) (02637) 235725

Website : www.yashfeenhospital.in E-mail : info@yashfeenhospital.in
(For Laboratory Reports Only)



Patient Name : VAISHALI NIKUNJ PATEL

Age : 32 Years Sex : F

Ref By Dr. : -

Area : Valsad

Date : 28/01/2023

Sample Time : 28/01/2023 09:00 No : 9

Time : 12:12PM

GGT TEST REPORT

Test	Findings	UOM	Normal Range
SERUM GGT	38	U/L	10-71 U/L



P. Chaudhary
Dr. PIYUSH B. CHAUDHARI
M.D. Medicine
Reg. No. G-21518

Remarks

Designed By : Sarita Infotech Pvt. Ltd., Navsari

Yashfeen Cardiac Hospital

H. Patel
Signature

Technician

Thanks for Reference



YASHFEEN CARDIAC HOSPITAL™

At. & Po. Viraval, Navsari. 396 445. Phone (H) (02637) 235725

Website : www.yashfeenhospital.in E-mail : info@yashfeenhospital.in
(For Laboratory Reports Only)



Patient Name : VAISHALI NIKUNJ PATEL

Age : 32 Years Sex : F

Ref By Dr. : -

Area : Valsad Date : 28/01/2023

Sample Time : 28/01/2023 09:00 No : 9

Time : 12:12PM

THYROID FUNCTION TEST REPORT

Test	Findings	UOM	Normal Range
T3 (TRIODOTHYRONINE)	1.23	ng/ml	NEWBORNS:0.73-2.88 6DAYS-3MONTHS:0.80-2.75 4-12MONTHS:0.86-2.65 1-6YEARS:0.92-2.48 7-11YEARS:0.93-2.31 12-20YEARS:0.91-2.18 ADULT:0.80-2.00
T4(THYROXINE)	10.46	µg/dl	NEWBORNS:5.04-18.5, 6DAYS-3MONTHS:5.41-17.0, 4-12 MONTHS:5.67-16.0, 1-6YEARS:5.95-14.7, 7-11 YEARS:5.99-13.8, 12-20 YEARS:5.91-13.2, ADULTS:5.10-14.1
TSH	<u>11.42</u>	µIU/ml	NEWBORNS:0.70-15.2, 6DAYS-3MONTHS:0.72-11.0, 4-12MONTHS:0.73-8.35, 1-6YEARS:0.70-5.97, 7-11YEARS:0.60-4.84, 12-20YEARS:0.51-4.30, ADULTS:0.27-4.20

TECHNIQUE

ELECTROCHEMILUMINESCENCE



P. Chaudhary
Dr. PIYUSH B. CHAUDHARI
M.D. Medicine
Reg. No. G-21518

Remarks

Designed By : Sania Infotech Pvt. Ltd., Navsari

Yashfeen Cardiac Hospital

Signature
signature

Technician

Thanks for Reference



YASHFEEN CARDIAC HOSPITAL™

At. & Po. Viraval, Navsari. 396 445. Phone (H) (02637) 235725

Website : www.yashfeenhospital.in E-mail : info@yashfeenhospital.in
(For Laboratory Reports Only)



Patient Name : VAISHALI NIKUNJ PATEL

Age : 32 Years Sex : F

Ref By Dr. : -

Area : Valsad

Date : 28/01/2023

Sample Time : 28/01/2023 09:00 No : 9

Time : 12:12PM

LIVER FUNCTION TEST REPORT

Test	Findings	UOM	Normal Range
TOTAL BILIRUBIN	0.2	mg/dL	0-1.0
DIRECT BILIRUBIN	0.1	mg/dL	0-0.8
INDIRECT BILIRUBIN	0.1	mg/dL	0-0.2
SGPT	14.8	U/L	Below 40.0
S.ALKALINE PHOSPHATASE	86.1	U/L	CH . 170.0-515.0 A. 37.0-147.0
TOTAL PROTEIN	7.1	g/dl	6.0-8.0
ALBUMIN	4.7	g/dl	3.0-5.0
GLOBULIN	2.4	g/dl	3.0-3.5
A/G	2.0	g/dl	
SGOT	14.1	U/L	Below 40.0



P. Chaudhari
Dr. PIYUSH B. CHAUDHARI
M.D. Medicine
Reg. No. G-21518

Remarks

Designed By : Sarita Infotech Pvt. Ltd., Navsari

Yashfeen Cardiac Hospital

Signature
Signature

Technician

Thanks for Reference



YASHFEEN CARDIAC HOSPITAL™

At. & Po. Viraval, Navsari. 396 445. Phone (H) (02637) 235725

Website : www.yashfeenhospital.in E-mail : info@yashfeenhospital.in
(For Laboratory Reports Only)



Patient Name : VAISHALI NIKUNJ PATEL

Age : 32 Years Sex : F

Ref By Dr. : -

Area : Valsad

Date : 28/01/2023

Sample Time : 28/01/2023 09:00 No : 9

Time : 12:12PM

LIPID PROFILE TEST REPORT

Test	Findings	UOM	Normal Range
S.CHOLESTEROL	198.6	mg/dL	<200:Desirable, 200-239:Borderline High, >=240:High
HDL CHOLESTEROL	49.6	mg/dL	<40:Low(High Risk), >=60:High(Low Risk)
LDL CHOLESTEROL	149.7	mg/dL	<100: Optimal, 100-129: Nearoptimal/ Aboveoptimal, 130-159:BorderlineHigh,16 0-189:High,>=190:Very
VLDL CHOLESTEROL	17.9	mg/dL	UPTO 40
S.TRIGLYCERIDES	89.3	mg/dL	<150:Normal, 150-199:Borderline High,200-499:High, >=500:Very Hi
CHOL/ HDL RATIO	4.0	mg/dL	LESS THAN 5
LDL/ HDL RATIO	3.0	mg/dL	LESS THAN 5



p. Chaval
Dr. PIYUSH B. CHAUDHARI
M.D. Medicine
Reg. No. G-21518

Remarks

Designed By : Sarita Infotech Pvt. Ltd., Navsari

Yashfeen Cardiac Hospital

Signature
Signature

Technician

Thanks for Reference



YASHFEEN CARDIAC HOSPITAL™

At. & Po. Viraval, Navsari. 396 445. Phone (H) (02637) 235725

Website : www.yashfeenhospital.in E-mail : info@yashfeenhospital.in
(For Laboratory Reports Only)



Patient Name : VAISHALI NIKUNJ PATEL

Age : 32 Years Sex : F

Ref By Dr. : -

Area : Valsad

Date : 28/01/2023

Sample Time : 28/01/2023 09:00 No : 9

Time : 12:12PM

BIOCHEMICAL TEST REPORT

Test	Findings	UOM	Normal Range
S.CREATININE	<u>0.6</u>	mg/dL	M .0.9-1.4 , F. 0.8-1.2
S.URIC ACID	4.2	mg/dL	Male:3.5-7.2, Female:2.6-6.0
BLOOD UREA NITROGEN	7.7	mg/dL	4.7-23.0



f. Chaudh
Dr. PIYUSH B. CHAUDHARI
M.D. Medicine
Reg. No. G-21518

Remarks

Designed By : Sarita Infotech Pvt. Ltd., Navsari

Yashfeen Cardiac Hospital

Signature

signature

Thanks for Reference

Technician



YASHFEEN CARDIAC HOSPITAL™

At. & Po. Viraval, Navsari. 396 445. Phone (H) (02637) 235725

Website : www.yashfeenhospital.in E-mail : info@yashfeenhospital.in
(For Laboratory Reports Only)



Patient Name : VAISHALI NIKUNJ PATEL

Age : 32 Years Sex : F

Ref By Dr. : -

Area : Valsad

Date : 28/01/2023

Sample Time : 28/01/2023 09:00 No : 9

Time : 12:12PM

HAEMOGLOBIN A1 C ESTIMATION

Test	Findings	UOM	Normal Range
Hb A1C	6.0	%	>8 :Action Suggested, 7-8 :Good Control, <7 :Goal, 6-7 :Near Normal Glycemia, <6 :Non-diabetic Level
Technique METHOD - HPLC			
Mean Blood Glucose	126.2	mg/dL	



P. Chaudhari
Dr. PIYUSH B. CHAUDHARI
M.D. Medicine
Reg. No. G-21518

Remarks

Designed By : Sarita Infotech Pvt. Ltd., Navsari

Yashfeen Cardiac Hospital

A. Chaudhari

signature

Thanks for Reference

Technician



YASHFEEN CARDIAC HOSPITAL™

At. & Po. Viraval, Navsari. 396 445. Phone (H) (02637) 235725

Website : www.yashfeenhospital.in E-mail : info@yashfeenhospital.in
(For Laboratory Reports Only)



Patient Name : VAISHALI NIKUNJ PATEL

Age : 32 Years Sex : F

Ref By Dr. : -

Area : Valsad

Date : 28/01/2023

Sample Time : 28/01/2023 09:00 No : 9

Time : 12:35PM

BLOOD SUGAR TEST REPORT

Test	Findings	UOM	Normal Range
FASTING BLOOD SUGAR	100.7	mg/dL	70-110
FASTING URINE SUGAR	NIL	-	NIL
POSTPANDRIAL BLOOD SUGAR	70.0	mg/dL	70-140
POSTPANDRIAL URINE SUGAR	NIL	-	NIL



P. Chaudhary
Dr. PIYUSH B. CHAUDHARI
M.D. Medicine
Reg. No. G-21518

Remarks

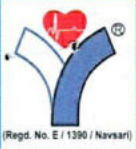Designed By : Sarita Infotech Pvt. Ltd., Navsari

Yashfeen Cardiac Hospital

A. Chaudhary
Signature

Thanks for Reference

Technician



YASHFEEN CARDIAC HOSPITAL™

At. & Po. Viraval, Navsari. 396 445. Phone (H) (02637) 235725

Website : www.yashfeenhospital.in E-mail : info@yashfeenhospital.in
(For Laboratory Reports Only)



Patient Name : VAISHALI NIKUNJ PATEL

Age : 32 Years Sex : F

Ref By Dr. : -

Area : Valsad

Date : 28/01/2023

Sample Time : 28/01/2023 08:59 No : 9

Time : 12:12PM

HAEMOGRAM REPORT

Test	Findings	UOM	Normal Range
HAEMOGLOBIN	9.4	gm/dl	M-13.5-17.0 F-11.5-15.5
HAEMOGRAM			
RED BLOOD CELL	5.42	10 ⁶ /μL	3.76 - 5.70
TOTAL LEUCOCYTE COUNT	4700	cells/cumm	4,000-11,000
Differential Count			
Neutrophil	60	%	40-75
Lymphocytes	28	%	20-40
Eosinophil	8	%	1-6
Monocytes	4	%	2-10
Basophils	0	%	0-0
PLATELET COUNT	397000	lacs/cumm	1.5-5.5 Lacs
RBC INDICES			
P.C.V.	30.7	%	M-40-56% F-37-47%
M.C.V.	56.6	cu/microns	76-94
M.C.H.	17.4	pg	27-30
M.C.H.C.	30.7	-	30-35
BLOOD GROUP	" A "	-	-
RH FACTOR	POSITIVE	-	-
E.S.R.(1 hour)	20	mm/hr.	M-5-10, F-5-20

Remarks

Designed By : Sarth Infotech Pvt. Ltd. Navsari



P. Chaudhari

Dr. PIYUSH B. CHAUDHARI

M.D. Medicine

Reg. No. G-21518

H. Patel

signature

Technician

Thanks for Reference

VAISHALI,
ID:
DOB:
Female, Unknown
Med.:
Location:
Referring Physician:
Notes:

26-01-2023 22:51:25

Vent. Rate:	74 BPM
PR int:	131 ms
QRS dur:	81 ms
QT/QTc:	355/383 ms
P-R-T axes:	62 69 25
Avg. RR:	801 ms
QTcB:	396 ms
QTcF:	382 ms

SINUS RHYTHM
NONSPECIFIC ST & T-WAVE ABNORMALITY
BORDERLINE ECG
INTERPRETATION BASED ON A DEFAULT AGE OF 40 YEARS

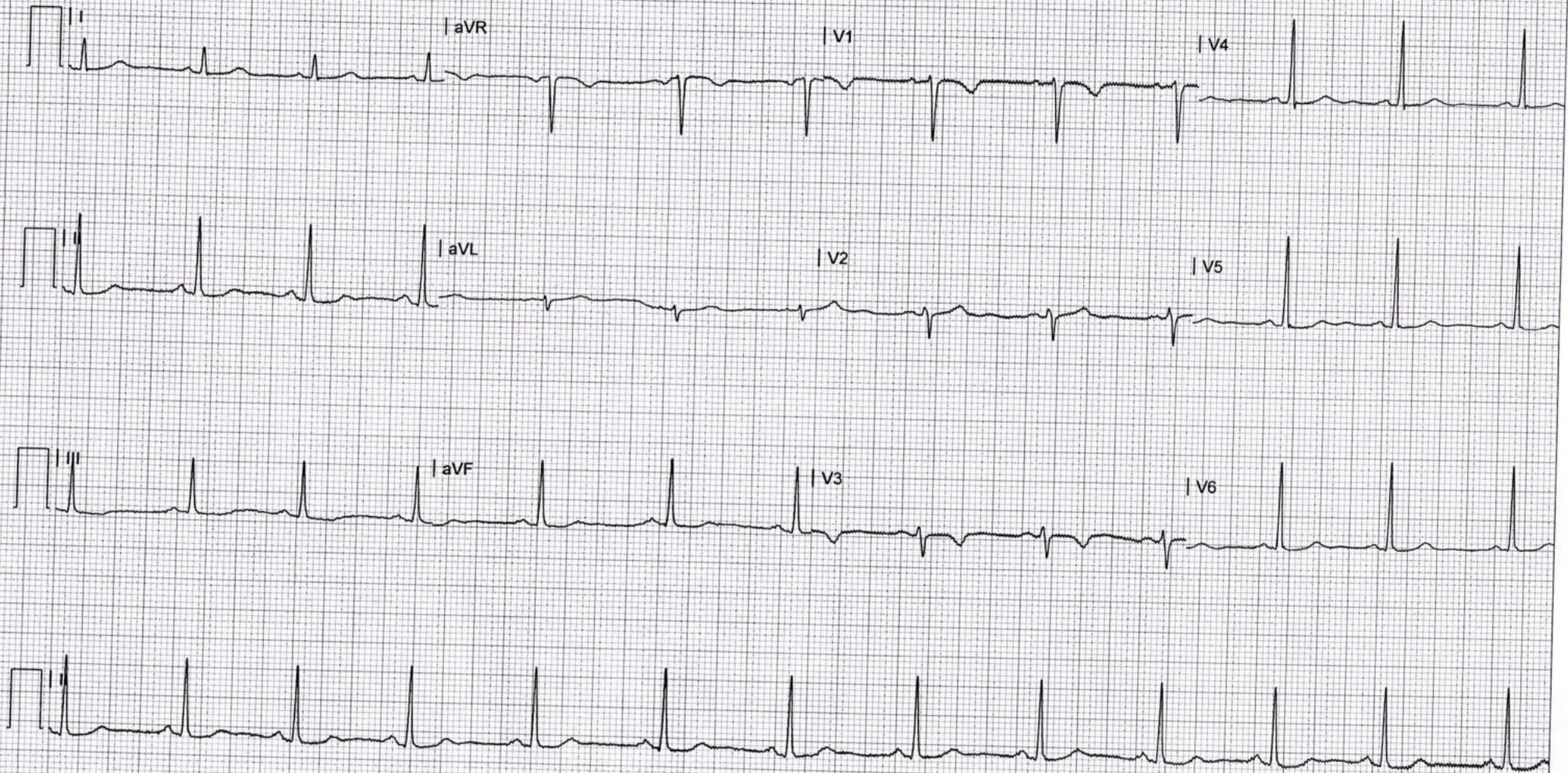
UNCONFIRMED REPORT
Reviewed by:

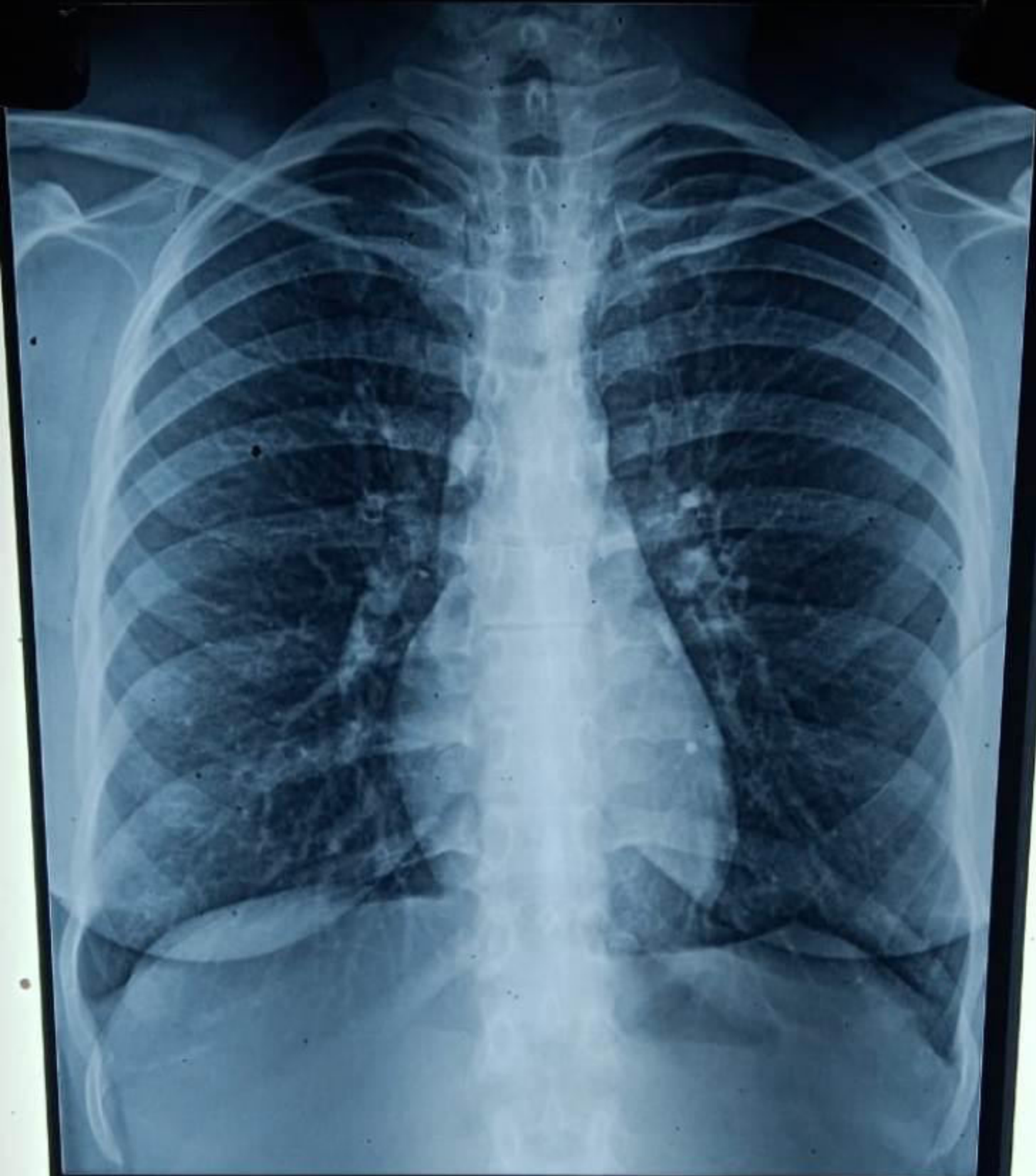
P. Chaudhari
Dr. PIYUSH B. CHAUDHARI
M.D. Medicine
Reg. No. G-21518

Signed by:
Date:



Vaishali N. Patel Age - 32/F





CH22043475 VAISHALI N PATEL 32/Y 2801231828 CHEST PA 28
YASHFEEN GROUP OF HOSPITALS NAVSARI PH:9924047789