

Health Check up Booking Request(bobE35155),Package Code(PKG1000241),Beneficiary Code(16246)

1 message

Mediwheel <wellness@mediwheel.in>
 To: vidhidiagnostics@gmail.com
 Cc: customercare@mediwheel.in

22 March 2023 at 13:47

011-41195959
Email:wellness@mediwheel.in

Dear Vidhi Diagnostics,
 City : Ahmedabad . Location : .New Wadaj,

We have received the following request for Health Check up from

Name : MS. KATARA FORAM PRAVINBHAI
Age : 31
Gender : Female
Member Relations : Employee
Package Name : Medi-Wheel Metro Full Body Health Checkup Female Below 40
Package Code : PKG1000241
User Location : Gujarat,AHMEDABAD,380022
Contact Details : 9510297980
Booking Date : 22-03-2023
Appointment Date : 25-03-2023

Member Information			
Booked Member Name	Age	Gender	Cost(In INR)
MS. KATARA FORAM PRAVINBHAI	31	Female	Cashless
Total amount to be paid			Cashless

Please login to your account to confirm the same. Also you mail us for confirmation

Package Name : Medi-Wheel Metro Full Body Health Checkup Female Below 40 - Includes (37)Tests

Tests included in this Package :

Ecg, TSH, X-ray Chest, Stress Test (tmt)/ 2d Echo, Blood Sugar Postprandial, A:g Ratio, Blood Group, Total Cholesterol, Triglycerides, Fasting Blood Sugar, Ultrasound Whole Abdomen , Glycosylated Haemoglobin (hba1c), Hdl, Vldl, Urine Analysis, LDL, Total Protine, General Consultation, HDL/ LDL ratio, GGT(Gamma-glutamyl Transferase), Eye Check-up consultation, ALP (ALKALINE PHOSPHATASE), Uric Acid, AST/ALT Ratio, Serum Protein, CBC with ESR, Stool Analysis, Urine Sugar Fasting, Urine Sugar PP, T3, T4, Cholesterol Total / HDL Ratio, BUN, BUN/Creatinine Ratio, Bilirubin Total & Direct and Indirect, Albumin, Globulin

Medical Examination Report

Date : 04/04/2023









1. Personal Particulars

Name : Kateraci Jodan Pavninbhai
Age : 34 years Gender : Male / Female
Marital Status : Married

Past & Present Medical History : H/O LSCS on 2020
HIV since 2yr
: taking TB Telmiflu 20mg Co-0-1/2
: H/O Home quarantine for 7 weeks due to
Covid positive on April 2021

2. Clinical Medical Examination

Height : 158 cm Weight : 64 kg
Blood Pressure : 106/80 mmHg Pulse : 78 p/min

General Condition :  Skin : 
Central Nervous System :  Head & Neck : 
Cardiovascular System :  Chest : 
Abdomen :  Limbs : 
Last menstrual period : -

Vision: : Right: 6/6 with specks Left: 6/6 with specks
NIL 10/6
Colour vision : Normal/Colour Blind

Personal Habit : NO

Remarks : Fit / Unfit for employment

Dr's name, signature & chop : Dr. Vidhi D. Modh
Reg. No. G-74540

Vidhi Diagnostics
L-86, Swatantra-Senani Nagar,
Opp. Akharnagar Bus Terminals,
Nr. Akharnagar Circle,
New Wadaj, Ahmedabad-13.

HR : 79 bpm
 PR : 130 ms
 QRS : 88 ms
 QT/QTc : 372/426 ms
 P/QRS/T : 71/73/48 deg.
 RV5/SV1 : 0.846/-0.475 mv
 RV5+SV1 : 1.321 mv

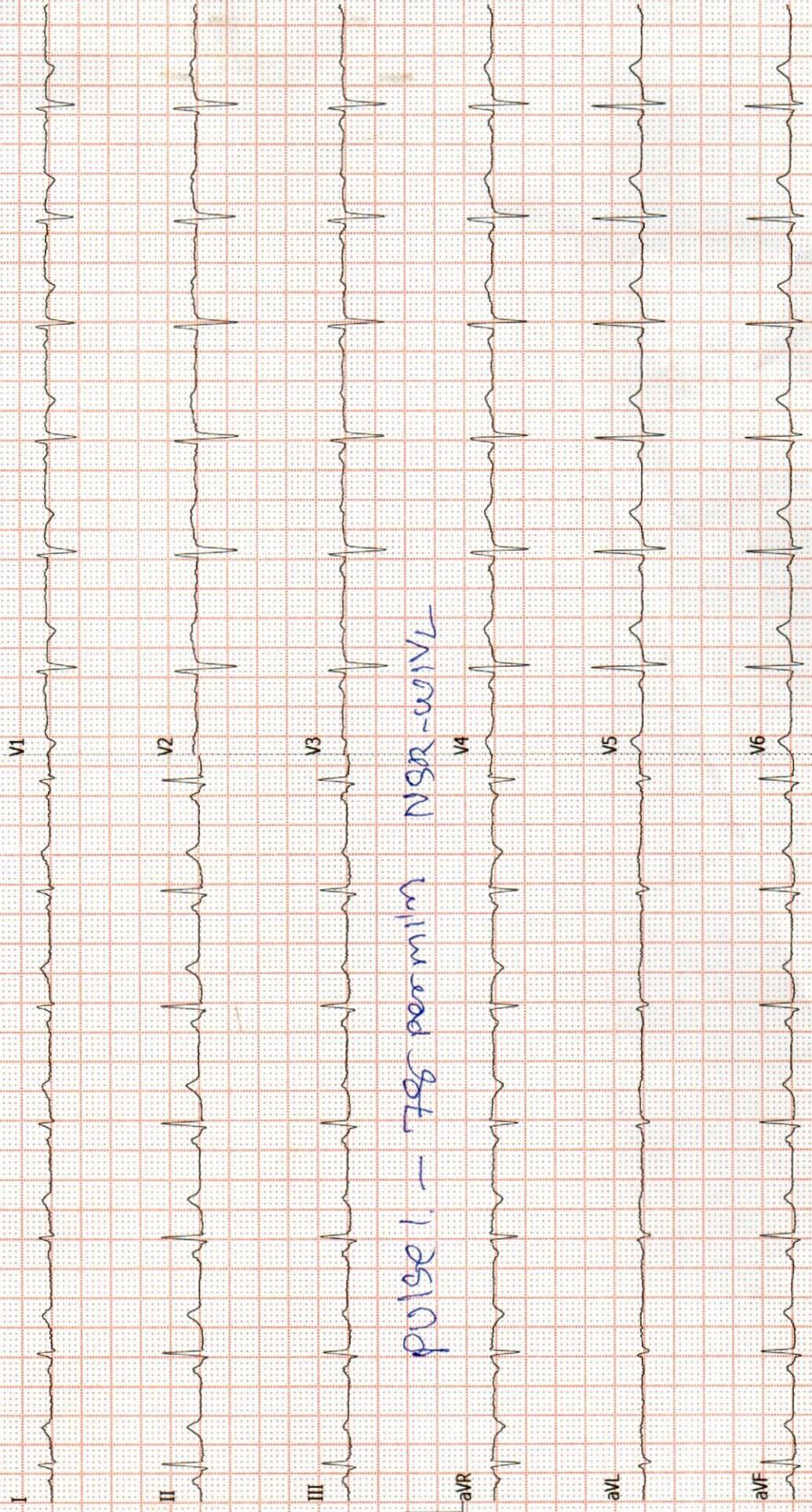
** normal ECG **
 Sinus rhythm

Vidhi Diagnostics
 1/16, Swatntra-Ganeshi Nagar,
 C.P. Akhbarnagar, East, Terminiels,
 Nr. Akhbarnagar Circle,
 New Madaj, Ahmedabad-380013.

ID: 8880
 Name: katara foram pravimbhai
 Age: 34yrs
 Sex: Female
 Hospital: **Dr. Avinash Bhaskar**
 Department: **ANMBSB, D Cardio**
 Reg. No.: **G-45946**

Need to be confirmed by doctor. Doctor Name:

0.67Hz - 35Hz AC 50Hz 25 mm/s 10 mm/mv



Dr. Dinesh S. Modh

M.D., D.M.R.E. (Radiodiagnosis)

Consultant Radiologist & Sonologist

Ex. Junior Lecturer, B.J. Medical College, Civil Hospital, A'bad.

Panel Doctor of L.I.C.



Patient's name : FORAM PRAVINBHAI KATARA

Reg. ID : R-130-23

Referred by : Dr. MEDIWHEEL

Age/Sex : 34 Years/Female

Accession : 3153

Date : 04/04/2023

X-RAY CHEST (PA VIEW)

Both lung fields appear normal.
No e/o consolidation or cavitations is seen.
Both costo-phrenic angles appear clear.
Cardiac size is with in normal limits.
Both domes of diaphragm appear normal.
Bony thoracic cage appears normal.

Thanks for reference.

Dr Dinesh S. Modh

MD DMRE (Radiodiagnosis)

DR DINESH S. MODH

M.D. DMRE(RADIODIAGNOSIS)

ISO 9001:2015 Certified Diagnostics Center

Vidhi Imaging Center

L-86, Swatantra Senani Nagar, Opp. Indian Oil Petrol Pump, Akhbarnagar Circle, Nava Vadaj, Ahmedabad - 380 013.

Phone : (Radiology) 079-2762 1406 | M. 98799 29406, 98250 09406 | Time (Radiology) : Mon. to Sat. 9 am to 2 pm, 5 to 9 pm, Sunday 9 am to 12 Noon

E-mail : vidhidiagnostics@gmail.com, Website : www.vidhidiagnostics.com

Multislice CT Scan | CBCT-Dental Scan | Live 3D-4D Sonography | Colour Doppler | Echo Cardiography | Interventional Radiology | Maxillofacial Radiology | Fetal Medicine
Digital X-Ray | Digital Mammography | Digital OPG/TMJ | ECG/TMT/PFT/EEG/EMG | Audiometry | Pathology Laboratory | Health Check Up Plans | Pre Employment Check Up

CT SCAN & CBCT FACILITY NOW AVAILABLE

Dr. Dinesh S. Modh

M.D., D.M.R.E. (Radiodiagnosis)

Consultant Radiologist & Sonologist

Ex. Junior Lecturer, B.J. Medical College, Civil Hospital, A'bad.

Panel Doctor of L.I.C.



Patient's name: FORAM PRAVINBHAI KATARA
Reg. ID : R-130-23
Referred by : Dr. MEDIWHEEL

Age/Sex : 34 Years/Female
Accession : 3153
Date : 04/04/2023

2D- ECHO REPORT

FINAL CONCLUSION:

LV IS NORMAL SIZE. GOOD LV SYSTOLIC FUNCTION NO RWMA.
LVEF - 60%. NO CONCENTRIC LVH.
NORMAL LV COMPLIANCE.
LA IS NORMAL SIZE. NO LA CLOT.
RV IS NORMAL SIZE. GOOD RV SYSTOLIC FUNCTION.
RA IS NORMAL SIZE.
MITRAL VALVE IS NORMAL. NO MS. MILD MR (15%). NO MVP.
AORTIC VALVE IS NORMAL. NO AS. NO AR.
TRICUSPID VALVE IS NORMAL. NO TR. RVSP-26 mmHg. NO PAH.
NO CLOT, NO VEGETATION, NO PERICARDIAL EFFUSION.

DIMENSIONS:

AORTA	2.6 C.M
LEFT ATRIUM	2.7 C.M
LVDD	4.1 C.M.
IVSD	1.0 C.M
PWD	1.0 C.M
LVDS	2.6 C.M.

COLOUR DOPPLER FINDING:

STRUCTURE	VELOCITY m/sec
	Max
PULMONARY VALVE	0.7
MITRAL VALVE	E : 0.7 A : 0.4
AORTIC VALVE	1.0

Dr. Avinash Bhaskar
MBBS, D Cardio
DR AVINASH BHASKAR
Reg. No.: 545946

ISO 9001:2015 Certified Diagnostics Center

Vidhi Imaging Center

L-86, Swatantra Senani Nagar, Opp. Indian Oil Petrol Pump, Akhbarnagar Circle, Nava Vadaj, Ahmedabad - 380 013.

Phone : (Radiology) 079-2762 1406 | M. 98799 29406, 98250 09406 | Time (Radiology) : Mon. to Sat. 9 am to 2 pm, 5 to 9 pm, Sunday 9 am to 12 Noon

E-mail : vidhidiagnostics@gmail.com, Website : www.vidhidiagnostics.com

Multislice CT Scan | CBCT-Dental Scan | Live 3D-4D Sonography | Colour Doppler | Echo Cardiography | Interventional Radiology | Maxillofacial Radiology | Fetal Medicine
Digital X-Ray | Digital Mammography | Digital OPG / TMJ | ECG / TMT / PFT / EEG / EMG | Audiometry | Pathology Laboratory | Health Check Up Plans | Pre Employment Check Up

CT SCAN & CBCT FACILITY NOW AVAILABLE

Dr. Dinesh S. Modh

M.D., D.M.R.E. (Radiodiagnosis)

Consultant Radiologist & Sonologist

Ex. Junior Lecturer, B.J. Medical College, Civil Hospital, A'bad.

Panel Doctor of L.I.C.



Patient's name: FORAM PRAVINBHAI KATARA

Reg. ID : R-130-23

Referred by : Dr. MEDIWHEEL

Age/Sex : 34 Years/Female

Accession : 3153

Date : 04/04/2023

USG ABDOMEN

LIVER:- Liver shows normal in size & normal echotexture. No e/o diffuse or focal lesion is seen. IHBR appear normal. PV & CBD appears normal. No e/o calculus is seen in bile duct.

GALL BLADDER:- Gall bladder is distended & shows 3-4 small non-mobile nodule measures 4-5mm in neck of GB suggests p/o GB polyp likely. No evidence of pericholecystic fluid is seen.

SPLEEN:- Spleen appears normal in size & shows normal echotexture. No evidence of diffuse or focal lesion is seen.

PANCREAS:- Pancreas appears normal size and echo pattern. No e/o diffuse or focal lesion is seen. Main pancreatic duct appears normal.

KIDNEY:- Both Kidneys appear normal in size & echotexture.

No e/o calculus or hydronephrosis or hydroureter is seen in both sides.

Cortico-medullary differentiation is maintained on either side.

Both suprarenal regions appear normal.

RIF & BOWEL (by high frequency probe-10Mhz): -Normal.

No evidence of pre & para aortic lymphadenopathy is seen.

No evidence of free fluid is seen in abdomen.

No evidence of dilated or thickened bowel loops is seen.

Urinary bladder:- appear normal. No e/o calculus or mass lesion is seen in bladder.

Uterus appears normal size and echopattern.

Both adenexal regions appear normal.

No e/o free fluid is seen in pouch of Douglas.

Thanks for reference.

Dr. Dinesh S. Modh
DR DINESH S. MODH (Radiodiagnosis)
G-23825
M.D. DMRE(RADIODIAGNOSIS)

ISO 9001:2015 Certified Diagnostics Center

Vidhi Imaging Center

L-86, Swatantra Senani Nagar, Opp. Indian Oil Petrol Pump, Akharnagar Circle, Nava Vadaj, Ahmedabad - 380 013.

Phone : (Radiology) 079-2762 1406 | M. 98799 29406, 98250 09406 | Time (Radiology) : Mon. to Sat. 9 am to 2 pm, 5 to 9 pm, Sunday 9 am to 12 Noon

E-mail : vidhidiagnostics@gmail.com, Website : www.vidhidiagnostics.com

Multislice CT Scan | CBCT-Dental Scan | Live 3D-4D Sonography | Colour Doppler | Echo Cardiography | Interventional Radiology | Maxillofacial Radiology | Fetal Medicine
Digital X-Ray | Digital Mammography | Digital OPG/TMJ | ECG/TMT/PFT/EEG/EMG | Audiometry | Pathology Laboratory | Health Check Up Plans | Pre Employment Check Up

CT SCAN & CBCT FACILITY NOW AVAILABLE

Dr. Dinesh S. Modh

M.D., D.M.R.E. (Radiodiagnosis)

Consultant Radiologist & Sonologist

Ex. Junior Lecturer, B.J. Medical College, Civil Hospital, A'bad.

Panel Doctor of L.I.C.



There is not required to give stool Analysis test.
So i am not willing to do so.

Thanks

Regards

A handwritten signature in black ink, appearing to read "Foram Katara", with a horizontal line drawn through it.

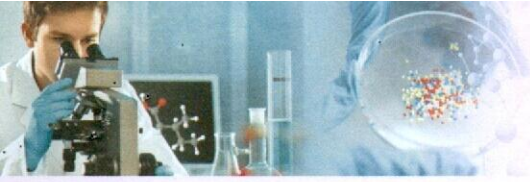Foram Katara.

ISO 9001:2015 Certified Diagnostics Center

Vidhi Imaging Center, L-86, Swatantra Senani Nagar, Opp. Akhbarnagar Petrol Pump, Nr. Akhbarnagar Circle, Nava-Vadaj, Ahmedabad - 380 013.

Phone : 079-2762 1406, Mobile : 98799 29406, 98250 09406, E-mail : vidhidiagnostics@gmail.com, Website : www.vidhidiagnostics.com

FACILITIES : Live 3D-4D Sonography | Colour Doppler | Echo Cardiography | Interventional Radiology | Fetal Medicine | Digital X-Ray
Digital Mammography | Digital OPG / TMJ | ECG / TMT / PFT / EEG / EMG | Pathology Laboratory | Health Check Up Plans | Pre Employment Check Up



Pathology Department

VIDHI[®]
DIAGNOSTICS



Patient's name : KATARA FORAM PRAVINBHAI
Age/Sex : 34 Years/Female
Referred by : Dr. MEDIWHEEL
Collection Time : 09:34

Reg. ID : P-68-23
Accession : 3150
Order Dt/time : 04/04/2023 09:34

Complete Blood Count

Sample Type: EDTA

Test Name	Result	Units	Biological Reference Interval
<u>Blood Counts</u>			
Haemoglobin :	9.9	Gms%	12.5 - 16.0
Total R.B.C. :	4.61	mill/c.mm	4.2 - 5.4
Total W. B. C. :	4070	/cu mm	4000 - 10500
Platelet Count :	253000	/cu.mm	1,50,000 - 4,50,000
<u>Differential Count</u>			
Neutrophils :	42	%	40 - 70
Lymphocytes :	49	%	20 - 40
Eosinophils :	04	%	1 - 4
Monocytes :	05	%	2 - 6
Basophils :	00	%	0 - 01
<u>Blood Indices</u>			
P. C. V :	33.0	%	37 - 47
M. C. V. :	71.7	fl	78 - 100
M.C.H :	21.5	pg	27 - 31
M. C. H. C :	30.0	%	32 - 36
R.D.W :	14.2	%	11.5 - 14.0
<u>E.S.R.(Westergren Method)</u>			
After one hour :	08	mm/hr	3 - 12

TESTS DONE ON FULLY AUTOMATED HEMATOLOGY ANALYZER.

Dr. Gayatri M. Mehta
M. D. (Patho)
Reg. No. G-32215

DR GAYATRI MEHTA
MD(PATHOLOGY)

DR. ANAND D. PARIKH
MD(PATHOLOGY)

LAB USE ONLY (Entered by :GM Enter Date/Time:04/04/2023 6:07:00 PM) (Verify by :GM Verify Date/Time:04/04/2023 6:07:00 PM)

ISO 9001:2015 Certified Diagnostics Center

Vidhi Imaging Center | Pathology Department

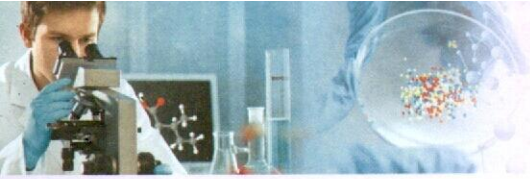L-86, Swatantra Senani Nagar, Opp. Akhbar Nagar Petrol Pump, Nr. Akhbar Nagar Circle, Nava-Vadaj, Ahmedabad - 380 013.

Ph. (Pathology) : 079-2762 1406, 8849893954 M. 98799 29406, 98250 09406, E-mail : vidhidiagnostics@gmail.com, Web. : www.vidhidiagnostics.com

Time (Pathology) : Mon. to Sat. 8.30 am to 8.00 pm, Sunday 9 am to 12 Noon

Pathology means science behind medicine

CT SCAN & CBCT FACILITY NOW AVAILABLE



Pathology Department



Patient's name : KATARA FORAM PRAVINBHAI
Age/Sex : 34 Years/Female
Referred by : Dr. MEDIWHEEL
Collection Time : 09:34

Reg. ID : P-68-23
Accession : 3150
Order Dt/time : 04/04/2023 09:34

Blood Group

Sample Type: EDTA sample.

Test Name	Result
BG :	" A "
RH :	POSITIVE
Remarks	Done by forward grouping method.

Blood Glucose

Sample Type: Serum

Test Name	Result	Units	Biological Reference Interval
Fasting Blood Glucose :	97.2	mg/dl	70 - 110
<i>GOD-POD Method.</i>			

Dr. Gayatri M. Mehta
M. D. (Patho)
Reg. No. G-32215

DR GAYATRI MEHTA
MD(PATHOLOGY)

DR. ANAND D. PARIKH
MD(PATHOLOGY)

LAB USE ONLY (Entered by :GM Enter Date/Time:04/04/2023 6:07:00 PM) (Verify by :GM Verify Date/Time:04/04/2023 6:07:00 PM)

ISO 9001:2015 Certified Diagnostics Center

Vidhi Imaging Center | Pathology Department

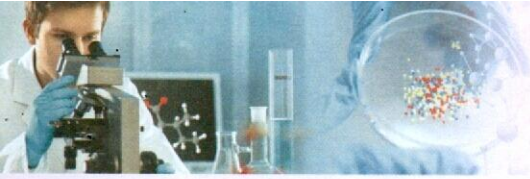L-86, Swatantra Senani Nagar, Opp. Akhbarnagar Petrol Pump, Nr. Akhbarnagar Circle, Nava-Vadaj, Ahmedabad - 380 013.

Ph. (Pathology) : 079-2762 1406, 8849893954 M. 98799 29406, 98250 09406, E-mail : vidhidiagnostics@gmail.com, Web. : www.vidhidiagnostics.com

Time (Pathology) : Mon. to Sat. 8.30 am to 8.00 pm, Sunday 9 am to 12 Noon

Pathology means science behind medicine

CT SCAN & CBCT FACILITY NOW AVAILABLE



Pathology Department

VIDHI[®]
DIAGNOSTICS



Patient's name : KATARA FORAM PRAVINBHAI
Age/Sex : 34 Years/Female
Referred by : Dr. MEDIWHEEL
Collection Time : 09:34

Reg. ID : P-68-23
Accession : 3150
Order Dt/time : 04/04/2023 09:34

Lipid Profile

Sample Type: Serum

Test Name	Result	Units	Biological Reference Interval
S. Cholesterol : Oxidase-esterase method.	120	mg/dl	0 - 200
S. Triglyceride : Enzymatic Colorimetry method	43.9	mg/dL	0 - 200
S. HDL - Cholesterol : Serum by Enzymatic method.	50.6	mg/dL	35 - 65
S. LDL - Cholesterol : Serum by Enzymatic method	60.62	mg/dL	0 - 130
S. VLDL - Cholesterol :	8.78	mg/dL	0 - 30
S. Chole/HDL.Ratio :	2.37		1 - 6
S. LDL / HDL Cholesterol Ratio :	1.2		0 - 3.5

Dr. Gayatri M. Mehta
M. D. (Patho)

Reg. No. G-32215

DR GAYATRI MEHTA
MD(PATHOLOGY)

DR. ANAND D. PARIKH
MD(PATHOLOGY)

LAB USE ONLY (Entered by :GM Enter Date/Time:04/04/2023 6:08:00 PM) (Verify by :GM Verify Date/Time:04/04/2023 6:08:00 PM)

ISO 9001:2015 Certified Diagnostics Center

Vidhi Imaging Center | Pathology Department

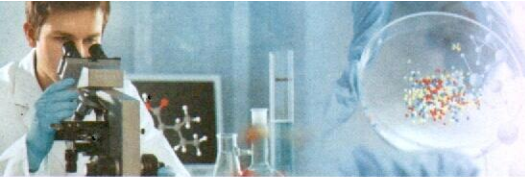L-86, Swatantra Senani Nagar, Opp. Akhbarnagar Petrol Pump, Nr. Akhbarnagar Circle, Nava-Vadaj, Ahmedabad - 380 013.

Ph. (Pathology) : 079-2762 1406, 8849893954 M. 98799 29406, 98250 09406, E-mail : vidhidiagnostics@gmail.com, Web. : www.vidhidiagnostics.com

Time (Pathology) : Mon. to Sat. 8.30 am to 8.00 pm, Sunday 9 am to 12 Noon

Pathology means science behind medicine

CT SCAN & CBCT FACILITY NOW AVAILABLE



Pathology Department



Patient's name : KATARA FORAM PRAVINBHAI
Age/Sex : 34 Years/Female
Referred by : Dr. MEDIWHEEL
Collection Time : 09:34

Reg. ID : P-68-23
Accession : 3150
Order Dt/time : 04/04/2023 09:34

HbA1C

Sample Type: Serum

Test Name	Result	Units	Biological Reference Interval
HbA1C :	5.3	%	Non-diabetic: 4.2-6.2 Pre-diabetic : 6.3-7.2 Diabetic : 7.3-8.2
Mean Blood Glucose of Last 03 months.	105	mg/dl	

Comment

*As per the new 2009 update of American Diabetes Association regarding HbA1C & Mean Blood Glucose relationship.

NOTE:

This test is used to monitor diabetic patients compliance with the therapeutic regimen and logo It's level is proportional to both the average blood glucose concentration and the life span of the red blood cells (RBC) in circulation. HbA1c values are free of day to day glucose fluctuations and are unaffected by exercise or recent food intake.

DR GAYATRI MEHTA
MD(PATHOLOGY)

Dr. Gayatri Mehta
M. D. (Patho)
Reg. No. G-32215

DR. ANAND D. PARIKH
MD(PATHOLOGY)

LAB USE ONLY (Entered by :DM Enter Date/Time:04/04/2023 6:40:00 PM) (Verify by :DM Verify Date/Time:04/04/2023 6:40:00 PM)

ISO 9001:2015 Certified Diagnostics Center

Vidhi Imaging Center | Pathology Department

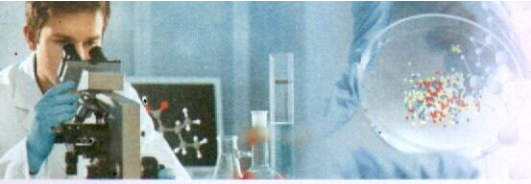L-86, Swatantra Senani Nagar, Opp. Akharnagar Petrol Pump, Nr. Akharnagar Circle, Nava-Vadaj, Ahmedabad - 380 013.

Ph. (Pathology) : 079-2762 1406, 8849893954 M. 98799 29406, 98250 09406, E-mail : vidhidiagnostics@gmail.com, Web. : www.vidhidiagnostics.com

Time (Pathology) : Mon. to Sat. 8.30 am to 8.00 pm, Sunday 9 am to 12 Noon

Pathology means science behind medicine

CT SCAN & CBCT FACILITY NOW AVAILABLE



Pathology Department

VIDHI[®]
DIAGNOSTICS

Creating Life in
Jungles

Patient's name : KATARA FORAM PRAVINBHAI
Age/Sex : 34 Years/Female
Referred by : Dr. MEDIWHEEL
Collection Time : 09:34

Reg. ID : P-68-23
Accession : 3150
Order Dt/time : 04/04/2023 09:34

BIOCHEMISTRY

Sample type : Serum

Test Name	Result	Units	Biological Reference Interval
Urea, (Serum by GLDH method) :	19.8	mg/dl	10 - 50
S.Uric acid, (Serum by Uricase method) :	4.1	mg/dl	2.6-6.0
Bun :	9.3	mg/dl	6-20
Creatinine, (Serum by Enzymatic reaction) :	0.76	mg/dl	0.5-1.2
S.G.P.T (ALT) : (Serum by IFCC method)	12.8	U/L	0 - 40
S.G.O.T (AST) : (Serum by IFCC method)	11.6	U/L	0 - 37
ALK.PHOSPHATASE : (Serum by PNP method)	41	U/L	35-104
G.G.T :	14.8	U/L	8 - 78
<u>BILIRUBIN</u>			
Total :	0.22	mg/dl	Up to 1.2
Direct :	0.14	mg/dl	0-0.7
Indirect :	0.08	mg/dl	0 - 0.5
<u>SERUM PROTEINS</u>			
Total Protein (Serum by Biuret method) :	6.62	gms/dl	6.4 - 8.5
Albumin (Serum by BCG method) :	3.98	gms/dl	3.97-4.94
Globulins :	2.64	gms/dl	2.3 - 3.5
A/G Ratio :	1.508		0.9 - 2.9

Dr. Gayatri M. Mehta

M. D. (Patho)

Reg. No. G-32215
DR GAYATRI MEHTA
MD(PATHOLOGY)

DR. ANAND D. PARIKH
MD(PATHOLOGY)

LAB USE ONLY (Entered by :GM Enter Date/Time:04/04/2023 6:06:00 PM) (Verify by :GM Verify Date/Time:04/04/2023 6:06:00 PM)

ISO 9001:2015 Certified Diagnostics Center

Vidhi Imaging Center | Pathology Department

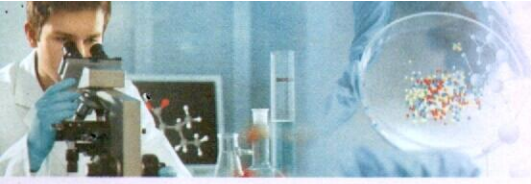L-86, Swatantra Senani Nagar, Opp. Akhbarnagar Petrol Pump, Nr. Akhbarnagar Circle, Nava-Vadaj, Ahmedabad - 380 013.

Ph. (Pathology) : 079-2762 1406, 8849893954 M. 98799 29406, 98250 09406, E-mail : vidhidiagnostics@gmail.com, Web. : www.vidhidiagnostics.com


Time (Pathology) : Mon. to Sat. 8.30 am to 8.00 pm, Sunday 9 am to 12 Noon

Pathology means science behind medicine

CT SCAN & CBCT FACILITY NOW AVAILABLE



Pathology Department



Patient's name : KATARA FORAM PRAVINBHAI
Age/Sex : 34 Years/Female
Referred by : Dr. MEDIWHEEL
Collection Time : 09:34

Reg. ID : P-68-23
Accession : 3150
Order Dt/time : 04/04/2023 09:34

Thyroid Function Test

Sample Type: Serum

Test Name	Result	Units	Biological Reference Interval
TOTAL T3 :	1.14	ng/ml	0.84 - 2.0
TOTAL T4 :	7.4	ug/dl	5.1 - 14.0
TSH(Ultra sensitive) :	2.308	mIU/L	0.27 - 4.2

Dr. Gayatri M. Mehta

M. D. (Patho)

Reg. No. G-32215

DR GAYATRI MEHTA
MD(PATHOLOGY)

DR. ANAND D. PARIKH
MD(PATHOLOGY)

LAB USE ONLY (Entered by :GM Enter Date/Time:04/04/2023 6:09:00 PM) (Verify by :GM Verify Date/Time:04/04/2023 6:09:00 PM)

ISO 9001:2015 Certified Diagnostics Center

Vidhi Imaging Center | Pathology Department

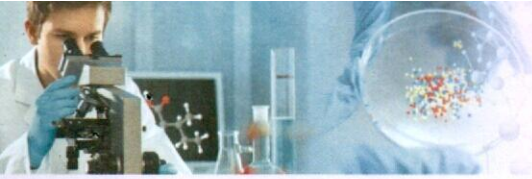L-86, Swatantra Senani Nagar, Opp. Akhbarnagar Petrol Pump, Nr. Akhbarnagar Circle, Nava-Vadaj, Ahmedabad - 380 013.

Ph. (Pathology) : 079-2762 1406, 8849893954 M. 98799 29406, 98250 09406, E-mail : vidhidiagnostics@gmail.com, Web. : www.vidhidiagnostics.com

Time (Pathology) : Mon. to Sat. 8.30 am to 8.00 pm, Sunday 9 am to 12 Noon

Pathology means science behind medicine

CT SCAN & CBCT FACILITY NOW AVAILABLE



Pathology Department



Patient's name : KATARA FORAM PRAVINBHAI
 Age/Sex : 34 Years/Female
 Referred by : Dr. MEDIWHEEL
 Collection Time : 09:34

Reg. ID : P-68-23
 Accession : 3150
 Order Dt/time : 04/04/2023 09:34

Urine Analysis

Sample Type: Urine

Test Name	Result	Units	Biological Reference Interval
<u>Physical Examination</u>			
Quantity :	30	ml	0 - 500 ml
Colour :	Yellow		Pale Yellow
Transparency :	Slight Turbid.		Clear
Reaction :	Acidic		4.6 - 8.0
Specific Gravity :	1.030		1.016 - 1.022
Sediment :	Present		
<u>Chemical Examination</u>			
Albumin :	Present (Faint Trace)		Absent
Sugar :	NIL		Absent
Acetone :	Absent		Absent
Bile Salts :	Absent		Absent
Bile Pigments :	Absent		Absent
Urobilogen :	Absent		Absent
Nitrites :	Absent		Absent
<u>Microscopic Examination</u>			
Red blood Cells :	2-3	/h.p.f	Absent
Pus Cells :	2-3	/h.p.f	Absent
Epithelial Cells :	1-2	/h.p.f	< 10.0
Amorphous :	Absent	/h.p.f	Absent
Bacteria :	Absent	/h.p.f	Absent
Crystals :	Absent	/h.p.f	Absent
Casts :	Absent	/h.p.f	Absent
Fungus :	Not seen	/h.p.f	Absent

Dr. Gayatri M. Mehta

M. D. (Patho)

Reg. No. G-32215

DR GAYATRI MEHTA
 MD(PATHOLOGY)

DR. ANAND D. PARIKH
 MD(PATHOLOGY)

ISO 9001:2015 Certified Diagnostics Center

LAB USE ONLY (Entered by :GM Entered Date/Time:04/04/2023 6:09:00 PM Verify Date/Time:04/04/2023 6:09:00 PM)

L-86, Swatantra Senani Nagar, Opp. Akhbarnagar Petrol Pump, Nr. Akhbarnagar Circle, Nava-Vadaj, Ahmedabad - 380 013.

Ph. (Pathology) : 079-2762 1406, 8849893954 M. 98799 29406, 98250 09406, E-mail : vidhidiagnostics@gmail.com, Web. : www.vidhidiagnostics.com

Time (Pathology) : Mon. to Sat. 8.30 am to 8.00 pm, Sunday 9 am to 12 Noon

Pathology means science behind medicine

CT SCAN & CBCT FACILITY NOW AVAILABLE



ભારત સરકાર
Unique Identification Authority of India
Government of India

નોંધણીની ઓળખ / Enrollment No.: 1249/01303/00388

To
કટારા ફોરમ પ્રવિણભાઈ
Katara Forum Pravinbhai
D/O: Pravinbhai Katara
9/98 gayatri appartment
opp.ghatlodia police station sola road, naranpura
Ahmadabad City
Sola H B C
Ahmadabad City Ahmedabad
Gujarat 380063
9510297980

14/05/2014

145634281



ML456342815FT



તમારો આધાર નંબર / Your Aadhaar No. :

6627 8204 8396

આધાર - સામાન્ય માણસનો અધિકાર

Dr. Vidhi D. Modh
Reg. No. G-74540



ભારત સરકાર
Government of India



કટારા ફોરમ પ્રવિણભાઈ
Katara Forum Pravinbhai
જન્મ તારીખ / DOB : 04/03/1989
સ્ત્રી / Female



6627 8204 8396

Vidhi Diagnostics
1-86, Swatantra-Senani Nagar,
Opp. Akhbarnagar Bus Terminals,
Nr. Akhbarnagar Circle,
New Wadaj, Ahmedabad-13.

Pravin

Kelshree

Foram: Panchimbari

34/17 female



Tuesday, 4 April 2023 9:43 am

Nirnay Nagar
Ahmedabad

Gujarat

Altitude: 64.3ft

Index number: 127

Vidhi Diagnostics
L-86, Swatantra-Senani Nagar,
Opp. Akhbarnagar Bus Terminal,
Opp. Akhbarnagar Circle,
New Wadaj, Ahmedabad-13.

Dr. Vidhi D. Modh
MBBS
Reg. No. G-74540