

Name : Mrs. HETAL PATEL (35 /F)
 Address : AHMEDABAD, AHMEDABAD, AHMEDABAD, GUJARAT, INDIA
 Examined by: Dr .BHAWANA DAGA
 Package : MEDIWHEEL-FULL BODY CHK-BELOW40-FEMALE

Date : 11/02/2023

UHID : AHCC 0000127053
 AHC No : AHCCA4471



CHIEF COMPLAINTS

For corporate health checkup
 Head ache

PRESENT KNOWN ILLNESS

No history of - Diabetes mellitus,
 Hypertension,
 Dyslipidemia, Thyroid
 disorder, Heart disease,
 Stroke, Asthma, COPD,
 Cancer, Impaired Glycemia



DRUG ALLERGY

NO KNOWN ALLERGY :11/02/2023



SYSTEMIC REVIEW

Cardiovascular system

- Nil Significant



Past medical history

Do you have any - No
 allergies?
 Covid 19 - Yes
 Hospitalization for - No
 Covid 19



Surgical history

Surgical history - Nil

Immunization history

- Covid Dose1, Covid Dose2



Personal history

Marital status - Married
 No. of children - 2
 Diet - Vegetarian
 Alcohol - does not consume alcohol
 Smoking - No

Chews tobacco - No
 Physical activity - Moderate

Family history

Diabetes - father
 Hypertension - mother
 Coronary artery
 disease - none
 Cancer - None

PHYSICAL EXAMINATION

General

General appearance - normal
 Height - 151
 Weight - 71.4
 BMI - 31.31
 Pallor - No
 Oedema - no



Cardiovascular system

Heart rate (Per minute) - 98
 Rhythm - Regular
 Systolic(mm of Hg) - 122
 Diastolic(mm of Hg) - 87
 Heart sounds - S1S2+

Respiratory system

Breath sounds - Normal vesicular breath
 sounds



Abdomen

Organomegaly - No
 Tenderness - No

Printed By : BHAWANA DAGA

Name : Mrs. HETAL PATEL (35 /F)

UHID : AHCC.0000127063

Date : 11/02/2023

Package : MEDIWHEEL-FULL BODY CHK-BELOW40-FEMALE

AHC No : AHCCA4471



URINE FOR ROUTINE EXAMINATION

Test Name	Result	Unit	Level	Range
Specific Gravity	1.015			
Colour:	Pale-Yellow			
Transparency:	Clear			
pH	6			
Protein :	Nil			
Sugar:	Nil			
Blood:	Negative			
Ketone	Absent			
Bile Pigments:	Absent			
Urobilinogen	Normal	E.U./d L		
Nitrite	Negative			
Pus Cells	Nil		0-5	
RBC	Nil	/hpf	0-5/hpf	
Epithelial Cells	Nil			
Casts:	Absent			
Crystals:	Absent			

Basophils	00	%	●	0-1
Platelet Count (Impedance)	332000	/cu mm	●	150000-450000
MPV (Calculated)	8	fl	●	7-11
RBC:	Normocytic Normochromic cells			
WBC:	Lymphocytosis noted			
Platelets:	Adequate on the smear			
Parasite	No Parasites Seen			
ERYTHROCYTE SEDIMENTATION RATE (ESR) (Automated/ optic-electronic)	09	mm/1st hr	●	0-20
SUGGEST :	Please correlate clinically			

URINE GLUCOSE(POST PRANDIAL)

Test Name	Result	Unit	Level	Range
Urine Glucose (Post Prandial)	Nil			

BLOOD GROUPING AND TYPING (ABO and Rh)

Test Name	Result	Unit	Level	Range
BLOOD GROUP:	A Positive			

COMPLETE BLOOD COUNT WITH ESR

Test Name	Result	Unit	Level	Range
Hemoglobin (Photometric Measurement)	11.8 *	gm%	●	12-16
Packed cell volume(Calculated)	36	%	●	36-46
RBC COUNT (Impedance)	4.07	Million/ ul	●	3.8-5.2
MCV (From RBC Histogram)	88.4	fl	●	80-100
MCH(Calculated)	29	pg	●	27-32
MCHC(Calculated)	32.8	%	●	31-36
RDW(Calculated)	12.8	%	●	11.5-14.5
WBC Count (Impedance)	6700	/cu mm	●	4000-11000
Neutrophils	47	%	●	40-75
Lymphocytes	44 *	%	●	20-40
Monocytes	07	%	●	2-10
Eosinophils	02	%	●	01-06

LFT (LIVER FUNCTION TEST)

Test Name	Result	Unit	Level	Range
ALT(SGPT) - SERUM / PLASMA	27	U/L	●	0-35
ALKALINE PHOSPHATASE - SERUM/PLASMA	51	U/L	●	Adult(Female): 35 - 104
AST (SGOT) - SERUM	29	U/L	●	>1 year Female : <32
Total Bilirubin	0.254 *	mg/dL	●	0.300-1.200
Direct Bilirubin	0.136	mg/dL	●	Upto 0.3 mg/dl

● Within Normal Range ● Borderline High/Low ● Out of Range

Name : Mrs. HETAL PATEL (35 /F)

UHID : AHCC.0000127063

Date : 11/02/2023

Package : MEDIWHEEL-FULL BODY CHK-BELOW40-FEMALE

AHC No : AHCCA4471



Indirect Bilirubin

0.12

mg/dL ●

1 Day ≤5.1 mg/dL
 2 Days ≤7.2 mg/dL
 3-5 Days ≤10.3 mg/dL
 6-7 Days ≤8.4 mg/dL
 8-9 Days ≤6.5 mg/dL
 10-11 Days ≤4.6 mg/dL
 12-13 Days ≤2.7 mg/dL
 14 Days - 9 Years 0.2-0.8 mg/dL
 10-19 Years 0.2-1.1 mg/dL
 ≥20 Years 0.2-1.2 mg/dL

GLYCOSYLATED HEMOGLOBIN (HBA1C) - WHOLE BLOOD

Test Name	Result	Unit	Level	Range
Glycosylated Hemoglobin (HbA1c)	5.73 *	%	●	Normal < 5.7
				%Increased risk for Diabetes 5.7 - 6.4%
				Diabetes ≥= 6.5%
				Monitoring criteria for Diabetes Mellitus <7.0 : Well Controlled Diabetes 7.1 – 8.0 : Unsatisfactory Control > 8.0 : Poor Control & Needs Immediate Treatment

CREATININE - SERUM / PLASMA

Test Name	Result	Unit	Level	Range
CREATININE - SERUM / PLASMA	0.67	mg/dL	●	Adult Female: 0.5 - 1.2

LFT (LIVER FUNCTION TEST)

Test Name	Result	Unit	Level	Range
GGTP: GAMMA GLUTAMYL TRANSPEPTIDASE - SERUM	15	U/L	●	Male : 10 - 71 Female : 6 - 42

GLUCOSE - SERUM / PLASMA (FASTING)

Test Name	Result	Unit	Level	Range
Glucose - Plasma (Fasting)	109 *	mg/dL	●	70 - 100 : Normal 100 - 125 : Impaired Glucose Tolerance ≥= 126 : Diabetes Mellitus

GLUCOSE - SERUM / PLASMA (POST PRANDIAL) - PPBS

Test Name	Result	Unit	Level	Range
Glucose - Plasma (Post Prandial)	113.2	mg/dL	●	70-140

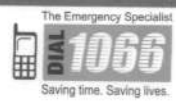● Within Normal Range ● Borderline High/Low ● Out of Range

For Enquiry/Appointments Contact +91 76988 15003 / +91 79 66701880

Apollo Hospitals International Limited
 Plot No - 1A, Bhat, GIDC, Gandhinagar, Gujarat - 382428, India.
 Phone : +91 79 66701800 | Fax No. : +91 79 66701843
 E-mail : info@apolloahd.com | www.ahmedabad.apollohospitals.com

Apollo Hospitals - City Centre (NON NABH-JCI)
 1, Tulsibaug Society, Nr. Parimal Garden, Ahmedabad.
 Phone : +91 79 66305800 / 01 or +91 76988 15148
 E-mail : infoahcc@apolloahd.com

Regd. Office
 19, Bishop Gardens, R.A. Puram, Chennai - 600 028
 CIN No. : U85110TN1997PLC039016 | GSTin : 24AABCA4150H225
 For online appointment : www.askapollo.com



For online appointment : www.askapollo.com
 Keep the records carefully and bring them along during your next visit to our Hospital

Organization is Accredited International

Glycosylated Hemoglobin (HbA1c)	5.73 *	%	●	Normal < 5.7 %Increased risk for Diabetes 5.7 - 6.4% Diabetes >= 6.5% Monitoring criteria for Diabetes Mellitus <7.0 : Well Controlled Diabetes 7.1 – 8.0 : Unsatisfactory Control > 8.0 : Poor Control & Needs Immediate Treatment
Mean Blood Sugar	118			

Test Name	Result	Unit	Level	Range
URIC ACID - SERUM	4.0	mg/dL	●	Male : 3.4-7.0 Female : 2.4-5.7

BUN (BLOOD UREA NITROGEN)

Test Name	Result	Unit	Level	Range
BUN (BLOOD UREA NITROGEN)	11	mg/dL	●	6-20
UREA - SERUM / PLASMA	24	mg/dL	●	15 - 50

LIPID PROFILE - SERUM

Test Name	Result	Unit	Level	Range
Total Cholesterol	128	mg/dl	●	0 - 200 : Desirable 200 - 240 : Borderline High 240 - 280 : High > 280 : Very High
Triglycerides - Serum	33	mg/dL	●	0-150
HDL CHOLESTEROL - SERUM / PLASMA (Direct Enzymatic Colorimetric)	59 *	mg/dL	●	< 40 : Major risk factor for heart disease 40 - 59 : The higher The better. >=60 : Considered protective against heart disease
LDL Cholesterol (Direct LDL)	68	mg/dL	●	100 : Optimal 100-129 : Near Optimal 130-159 : Borderline High 160-189 : High >=190 : Very High
VLDL CHOLESTEROL	6.7		●	< 40 mg/dl
C/H RATIO	2.2		●	0-4.5

LFT (LIVER FUNCTION TEST)

Test Name	Result	Unit	Level	Range
PROTEIN TOTAL - SERUM / PLASMA	7.6	g/dL	●	6.00-8.00
ALBUMIN - SERUM	4.69	g/dL	●	Adult(18 - 60 Yr): 3.5 - 5.2
Globulin-Serum/Plasma	2.9		●	2.20-4.20
A/G ratio	1.6		●	1.00-2.00

THYROID PROFILE (T3,T4 AND TSH)

Test Name	Result	Unit	Level	Range
TOTAL T3: TRI IODOTHYRONINE - SERUM	1.0	ng/mL	●	0.8 - 2.0
TOTAL T4: THYROXINE - SERUM	8 *	ug/dL	●	5.1 - 14.1
TSH: THYROID STIMULATING HORMONE - SERUM	2.54	μIU/mL	●	14-120 years : 0.27 - 4.20

URIC ACID - SERUM

● Within Normal Range ● Borderline High/Low ● Out of Range

USG WHOLE ABDOMEN

Name : Mrs. HETAL PATEL (35 /F)

UHID : AHCC.0000127063

Date : 11/02/2023

Package : MEDIWHEEL-FULL BODY CHK-BELOW40-FEMALE

AHC No : AHCCA4471

Apollo
HOSPITALS

Liver appears normal in size and shows uniform normal echotexture. No evidence of focal or diffuse pathology seen. Intra and extra hepatic biliary radicles are not dilated. Portal vein is normal in caliber. Intrahepatic portal radicles appear normal.

Gall bladder appears normal with no evidence of calculus. Wall thickness appears normal. No evidence of pericholecystic collection.

Visualized pancreas appear normal in size and echotexture. No focal lesions identified. Visualize pancreatic duct appears normal in caliber. Spleen is normal in size and shows uniform echotexture.

Both kidneys are normal in size and show normal echopattern with good corticomedullary differentiation. Cortical outlines appear smooth. No evidence of calculi. Pelvicalyceal system on both sides appear normal.

No evidence of ascites or significant lymphadenopathy. Visualized bowel loops appear normal and shows normal peristalsis.

Urinary bladder is normal in contour and outline. Wall thickness appears normal. No evidence of any intraluminal pathology seen.

On transabdominal scan;
Uterus measures 8.4 x 5.4 x 4.4 cm. IUCD in situ
Uterus is anteverted and appears normal in size and echotexture. No focal lesion noted. Myometrial and endometrial echotexture appears normal.
Both ovaries appears normal in size and echotexture. No definite evidence of adnexal/pelvic mass is seen.

IMPRESSION :
No significant abnormality detected.

X-RAY CHEST PA

NORMAL STUDY.

INVESTIGATIONS NOT DONE / NOT YET REPORTED / NOT PART OF PACKAGE(LAB,RADIOLOGY & CARDIOLOGY)

Haematology

STOOL ROUTINE

URINE GLUCOSE(FASTING)

Histopathology

CONVENTIONAL PAP SMEAR /CERVICAL SMEAR

CARDIOLOGY

ECHO/TMT

ECG

● Within Normal Range

● Borderline High/Low

● Out of Range

Name : Mrs. HETAL PATEL (35 /F)

UHID : AHCC.0000127063

Date : 11/02/2023

Package : MEDIWHEEL-FULL BODY CHK-BELOW40-FEMALE

AHC No : AHCCA44471



Executive Summary

ALL PHYSICAL FINDINGS ARE WNL.
PREDIABETIC.

Wellness Prescription

Advice On Diet :-

LOW CARB DIET.

Advice On Physical Activity :-

REGULAR EXERCISE.

Printed By BHAWANA DAGA



Note :- The Health Check-up examinations and routine investigations have certain limitations and may not be able to detect all the diseases. Any new or persisting symptoms should be brought to the attention of the Consulting Physician. Additional tests, consultations and follow up may be required in some cases.

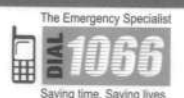For Enquiry/Appointments Contact +91 76988 15003 / +91 79 66701880

Apollo Hospitals International Limited
Plot No. -1A, Bhat, GIDC, Gandhinagar, Gujarat - 382428, India.
Phone : +91 79 66701880 | Fax No. : +91 79 66701843
E-mail : info@apolloahd.com | www.ahmedabad.apollohospitals.com

Apollo Hospitals - City Centre (NON NABH-JCI)
1, TulsiBaag Society, Nr. Parimal Garden, Ahmedabad.
Phone : +91 79 66305800 / 01 or +91 76988 15148
E-mail : infoahcc@apolloahd.com

Regd. Office
19, Bishop Gardens, R.A. Puram, Chennai - 600 028
CIN No. : U85110TN1997PLC039016 | GSTIN : 24AABCA4150H225
For online appointment : www.askapollo.com

For online appointment : www.askapollo.com
Keep the records carefully and bring them along during your next visit to our Hospital





Organization is Accredited
by Joint Commission International

DEPARTMENT OF BIOCHEMISTRY AND IMMUNOLOGY



Name : Mrs. HETAL PATEL
 UHID : AHCC.0000127063 / AHCCA4471
 SIN \ LRN : 3750614 \ 3750613 \ 3750616 \ 3750618 \ 1608362
 Specimen : Serum
 Ref Doctor : DR. MHC

Age : 35Yr 4Mth 24Days Gender : Female
 W/BN/RefNo : AHC



Collected on : 11-FEB-2023 08:45:40 AM Received on : 11-FEB-2023 09:00:51 AM Reported on : 11-FEB-2023 04:21:12 PM

MEDIWHEEL-FULL BODY CHK-BELOW40-FEMALE

TEST NAME	RESULT	BIOLOGICAL REFERENCE INTERVALS	UNITS
GLYCOSYLATED HEMOGLOBIN (HBA1C) - WHOLE BLOOD (Immunoturbidimetric)	5.73 *	Normal < 5.7% Increased risk for Diabetes 5.7 - 6.4% Diabetes >= 6.5% Monitoring criteria for Diabetes Mellitus <7.0 : Well Controlled Diabetes 7.1 - 8.0 : Unsatisfactory Control > 8.0 : Poor Control & Needs Immediate Treatment	%
Mean Blood Sugar GLUCOSE - SERUM / PLASMA (FASTING) (Hexokinase)	118 109 *	70 - 100 : Normal 100 - 125 : Impaired Glucose Tolerance >= 126 : Diabetes Mellitus Adult Female : <34	mg/dL
ALT(SGPT) - SERUM / PLASMA (UV without P5P)	27	Adult(Female): 35 - 104	U/L
ALKALINE PHOSPHATASE - SERUM/PLASMA (PNP AMP BUFFER)	51	>1 year Female : <32	U/L
AST (SGOT) - SERUM	29		U/L

For Enquiry/Appointments Contact +91 76988 15003 / +91 79 66701880

Apollo Hospitals International Limited
 Plot No -1A, 3rd, GIDC, Gandhinagar, Gujarat - 382428, India.
 Phone : +91 79 66701800 | Fax No. : +91 79 66701843
 E-mail : info@apolloahd.com | www.ahmedabad.apollohospitals.com

Apollo Hospitals - City Centre (NON NABH-JCI)
 1, Tulsibaug Society, Nr. Parimal Garden, Ahmedabad.
 Phone : +91 79 66305800 / 01 or +91 76988 15148
 E-mail : infoahcc@apolloahd.com

Regd. Office
 19, Bishop Gardens, R.A. Puram, Chennai - 600 028
 CIN No. : U85110TN1997PLC039016 | GSTin : 24AABCA4150H2Z5
 For online appointment : www.askapollo.com






Organization is Accredited
by Joint Commission International

DEPARTMENT OF BIOCHEMISTRY AND IMMUNOLOGY



Name : Mrs. HETAL PATEL
 UHID : AHCC.0000127063 / AHCCA4471
 SIN \ LRN : 3750614 \ 3750613 \ 3750616 \ 3750618 \
 Specimen : 1608362 Serum
 Ref Doctor : DR. MHC

Age : 35Yr 4Mth 24Days Gender : Female
 W/BNo/RefNo : AHC



Collected on : 11-FEB-2023 08:45:40 AM Received on : 11-FEB-2023 09:00:51 AM Reported on : 11-FEB-2023 04:21:12 PM

(UV without P5P)

BILIRUBIN (DIRECT/INDIRECT/TOTAL) - SERUM

(Diazotization)

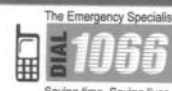Bilirubin Total	0.254 *	0-1 days : 0 - 6mg/dl 1-2 days : 0 - 8mg/dl 2-5 days : 0 - 12mg/dl 5days - 4 months : 0.3 -1.2mg/dl >4 months : 0.3-1.2 mg/dl	mg/dL
Direct Bilirubin	0.136	Upto 0.3 mg/dl	mg/dL
Indirect Bilirubin	0.12	1 Day ≤5.1 mg/dL 2 Days ≤7.2 mg/dL 3-5 Days ≤10.3 mg/dL 6-7 Days ≤8.4 mg/dL 8-9 Days ≤6.5 mg/dL 10-11 Days ≤4.6 mg/dL 12-13 Days ≤2.7 mg/dL 14 Days - 9 Years 0.2-0.8 mg/dL 10-19 Years 0.2-1.1 mg/dL ≥20 Years 0.2-1.2 mg/dL Adult Female: 0.5 - 1.2	mg/dL
CREATININE - SERUM / PLASMA (Alkaline picrate - kinetic rate blanked)	0.67		mg/dL
GGTP: GAMMA GLUTAMYL TRANSPEPTIDASE - SERUM (IFCC)	15	Male : 10 - 71 Female : 6 - 42	U/L
PROTEIN TOTAL - SERUM / PLASMA (Biuret)	7.6	>2 Year: 6.0 - 8.0	g/dL
ALBUMIN - SERUM	4.69	Adult(18 - 60 Yr): 3.5 - 5.2	g/dL

For Enquiry/Appointments Contact +91 76988 15003 / +91 79 66701880

Apollo Hospitals International Limited
 Plot No.-1A, 8th, GIDC, Gandhinagar, Gujarat - 382428, India.
 Phone : +91 79 66701800 | Fax No. : +91 79 66701843
 E-mail : info@apolloahd.com | www.ahmedabad.apollohospitals.com

Apollo Hospitals - City Centre (NON NABH-JCI)
 1, Tulsibaug Society, Nr. Parimal Garden, Ahmedabad.
 Phone : +91 79 66305800 / 01 or +91 76988 15148
 E-mail : infoahcc@apolloahd.com

Regd. Office
 19, Bishop Gardens, R.A. Puram, Chennai - 600 028
 CIN No. : U85110TN1997PLC039016 | GSTIn : 24AABCA4150H2Z5
 For online appointment : www.askapollo.com



For online appointment : www.askapollo.com
 Keep the records carefully and bring them along during your next visit to our Hospital.

The Emergency Specialist
 Saving time. Saving lives.



Organization is Accredited
by Joint Commission International

DEPARTMENT OF BIOCHEMISTRY AND IMMUNOLOGY



Name : Mrs. HETAL PATEL
 Age : 35Yr 4Mth 24Days Gender : Female
 UHID : AHCC.0000127063 / AHCCA4471
 W/BN/RefNo : AHC
 SIN \ LRN : 3750614 \ 3750613 \ 3750616 \ 3750618 \
 Specimen : Serum
 Ref Doctor : DR. MHC



Collected on : 11-FEB-2023 08:45:40 AM Received on : 11-FEB-2023 09:00:51 AM Reported on : 11-FEB-2023 04:21:12 PM

Globulin-Serum/Plasma	2.9	2.2 - 4.2	
A/G ratio	1.6	1.00 - 2.00	
TOTAL T3: TRI IODOTHYRONINE - SERUM (Electrochemiluminescence:ECLIA)	1.0	0.8 - 2.0	ng/mL
TOTAL T4: THYROXINE - SERUM (Electrochemiluminescence:ECLIA)	8 *	5.1 - 14.1	ug/dL
TSH: THYROID STIMULATING HORMONE - SERUM (Electrochemiluminescence:ECLIA)	2.54	14-120 years : 0.27 - 4.20	µIU/mL
URIC ACID - SERUM (Uricase, colorimetric)	4.0	Male : 3.4-7.0 Female : 2.4-5.7	mg/dL
BUN (BLOOD UREA NITROGEN) (Histology)	11	Adult : 6 - 20	mg/dL
UREA - SERUM / PLASMA	24	15 - 50	mg/dL
LIPID PROFILE - SERUM			
TOTAL CHOLESTEROL (CHOD POD)	128	0 - 200 : Desirable 200 - 240 : Borderline High 240 - 280 : High > 280 : Very High	mg/dl
TRIGLYCERIDES - SERUM (Enzymatic Endpoint)	33	Normal: <150 High: 150 - 199 Hypertriglyceridemic: 200 - 499 Very High: >=500	mg/dL
HDL CHOLESTEROL - SERUM / PLASMA (Direct Enzymatic Colorimetric)	59 *	< 40 : Major risk factor for heart disease 40 - 59 : The higher The better.	mg/dL

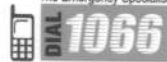For Enquiry/Appointments Contact +91 76988 15003 / +91 79 66701880

Apollo Hospitals International Limited
 Plot No.-1A, 1st, GIDC, Gandhinagar, Gujarat - 382428, India.
 Phone : +91 79 66701800 | Fax No. : +91 79 66701843
 E-mail : info@apolloahd.com | www.ahmedabad.apollohospitals.com

Apollo Hospitals - City Centre (NON NABH-JCI)
 1, Tulsibaug Society, Nr. Parimal Garden, Ahmedabad.
 Phone : +91 79 66305800 / 01 or +91 76988 15148
 E-mail : infoahcc@apolloahd.com

Regd. Office
 19, Bishop Gardens, R.A. Puram, Chennai - 600 028
 CIN No. : U85110TN1997PLC039016 | GSTIn : 24AABCA4150H225
 For online appointment : www.askapollo.com

The Emergency Specialist



Saving time. Saving lives.



Organization is Accredited
by Joint Commission International



DEPARTMENT OF CLINICAL PATHOLOGY

--

Name	: Mrs. HETAL PATEL	Age	: 35Yr 4Mth 24Days	Gender	: Female
UHID	: AHCC.0000127063 / AHCCA4471	W/BNo/RefNo	: AHC		
SIN \LRN	: 3750611 \ 1608362				
Specimen	: Urine				
Ref Doctor	: DR. MHC				
Collected on	: 11-FEB-2023 08:45:40 AM	Received on	: 11-FEB-2023 04:22:24 PM	Reported on	: 11-FEB-2023 04:56:13 PM

MEDIWHEEL-FULL BODY CHK-BELOW40-FEMALE

TEST NAME	RESULT
-----------	--------


URINE GLUCOSE(POST PRANDIAL)	
\$ URINE GLUCOSE(POST PRANDIAL)	Nil

*11/02/2023

Report Status:Final

* END OF REPORT *

CHECKED BY : 1060162
717880



Printed On : 12-FEB-2023 10:02:17 AM

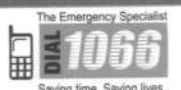Dr.HARDIK KOSHTI
MD PATHOLOGY,
CONSULTANT

For Enquiry/Appointments Contact +91 76988 15003 / +91 79 66701880

Apollo Hospitals International Limited
Plot No. -1A, Bhat, GIDC, Gandhinagar, Gujarat - 382428, India.
Phone : +91 79 66701800 | Fax No. : +91 79 66701843
E-mail : info@apolloahd.com | www.ahmedabad.apollohospitals.com

Apollo Hospitals - City Centre (NON HADH-JCI)
1, TulsiBaag Society, Nr. Parimal Garden, Ahmedabad.
Phone : +91 79 66305800 / 01 or +91 76988 15148
E-mail : infoahcc@apolloahd.com

Regd. Office
19, Bishop Gardens, R.A. Puram, Chennai - 600 028
CIN No. : U85110TN1997PLC039016 | GSTIn : 24AABCA4150H225
For online appointment : www.askapollo.com







Organization is Accredited
by Joint Commission International



DEPARTMENT OF CLINICAL PATHOLOGY

--

Name : Mrs. HETAL PATEL Age : 35Yr 4Mth 24Days Gender : Female
 UHID : AHCC.0000127063 / AHCCA4471 W/BN/RefNo : AHC
 S/N\LRN : 3750617 \ 1608362
 Specimen : Urine
 Ref Doctor : DR. MHC

Collected on : 11-FEB-2023 08:45:40 AM Received on : 11-FEB-2023 09:01:02 AM Reported on : 11-FEB-2023 04:59:41 PM


MEDIWHEEL-FULL BODY CHK-BELOW40-FEMALE

TEST NAME	RESULT	BIOLOGICAL REFERENCE INTERVALS	UNITS
URINE FOR ROUTINE EXAMINATION : (Solubility Method)			
PHYSICAL EXAMINATION			
Specific Gravity	1.015		
Colour:	Pale-Yellow		
Transparency:	Clear		
CHEMICAL EXAMINATION			
pH	6		
Protein :	Nil		
Sugar:	Nil		
Blood:	Negative		
Ketone	Absent		
Bile Pigments:	Absent		
Urobilinogen	Normal		E.U./dL
Nitrite	Negative		
Cells:			
Pus Cells	Nil	0-5/hpf	
RBC	Nil	0-5/hpf	/hpf
Epithelial Cells	Nil		
Casts:	Absent		
Crystals:	Absent		

*11/02/2023
 Report Status:Final

* END OF REPORT *

CHECKED BY : 1060162
 717880



Printed On : 12-FEB-2023 10:02:32 AM

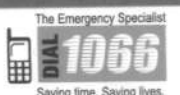Dr.HARDIK KOSHTI
 MD PATHOLOGY,
 CONSULTANT

For Enquiry/Appointments Contact +91 76988 15003 / +91 79 66701880

Apollo Hospitals International Limited
 Plot No.-1A, Bhat, GIDC, Gandhinagar, Gujarat - 382428, India.
 Phone : +91 79 66701800 | Fax No. : +91 79 66701843
 E-mail : info@apolloahd.com | www.ahmedabad.apollohospitals.com

Apollo Hospitals - City Centre (NON NABH-JCI)
 1, TulsiBaag Society, Nr. Parimal Garden, Ahmedabad.
 Phone : +91 79 66305800 / 01 or +91 76988 151-18
 E-mail : infoahcc@apolloahd.com

Regd. Office
 19, Bishop Gardens, R.A. Puram, Chennai - 600 028
 CIN No. : U85110TN1997PLC039016 | GSTIn : 24AABCA4150H225
 For online appointment : www.askapollo.com





Organization is Accredited
by Joint Commission International

DEPARTMENT OF HAEMATOLOGY



Name : Mrs. HETAL PATEL
 UHID : AHCC.0000127063 / AHCCA4471
 SIN \LRN : 3750620 \ 1608362
 Specimen : Whole Blood (EDTA)
 Ref Doctor : DR. MHC

Age : 35Yr 4Mth 24Days Gender : Female
 W/BNo/RefNo : AHC



Collected on : 11-FEB-2023 08:45:40 AM Received on : 11-FEB-2023 09:00:37 AM Reported on : 11-FEB-2023 12:03:11 PM

MEDIWHEEL-FULL BODY CHK-BELOW40-FEMALE

TEST NAME	RESULT	BIOLOGICAL REFERENCE INTERVALS	UNITS
COMPLETE BLOOD COUNT WITH ESR			
Hemoglobin (Photometric Measurement)	11.8 *	12 - 16	gm%
Packed cell volume(Calculated)	36	36 - 46	%
RBC COUNT (Impedance)	4.07	3.8 - 5.2	Million/ul
MCV (From RBC Histogram)	88.4	80 - 100	fl
MCH(Calculated)	29	27 - 32	pg
MCHC(Calculated)	32.8	31 - 36	%
RDW(Calculated)	12.8	11.5 - 14.5	%
WBC Count (Impedance)	6700	4000 - 11000	/cu mm
Differential Count (VCS Technology and Microscopy)			
Neutrophils	47	40 - 75	%
Lymphocytes	44 *	20 - 40	%
Monocytes	07	2 - 10	%
Eosinophils	02	01 - 06	%
Basophils	00	0 - 1	%
Platelet Count (Impedance)	332000	150000 - 450000	/cu mm
MPV (Calculated)	8	7 - 11	fl
PERIPHERAL SMEAR(Microscopy)			
RBC:	Normocytic Normochromic cells		
WBC:	Lymphocytosis noted		
Platelets:	Adequate on the smear		
Parasite:	No Parasites Seen		
ERYTHROCYTE SEDIMENTATION RATE (ESR) (Automated/ optic-electronic)	09	0 - 20	mm/1st hr
SUGGEST :	Please correlate clinically		

For Enquiry/Appointments Contact +91 76988 15003 / +91 79 66701880

Apollo Hospitals International Limited
 Plot No-1A, Bhat, GIDC, Gandhinagar, Gujarat - 382428, India.
 Phone : +91 79 66701800 | Fax No. : +91 79 66701843
 E-mail : info@apolloahd.com | www.ahmedabad.apollohospitals.com

Apollo Hospitals - City Centre (NON NABH-JCI)
 1, TulsiBaag Society, Nr. Parimal Garden, Ahmedabad.
 Phone : +91 79 66305800 / 01 or +91 76988 15148
 E-mail : infoahcc@apolloahd.com

Regd. Office
 19, Bishop Gardens, R.A. Puram, Chennai - 600 028
 CIN No. : U85110TN1997PLC039016 | GSTIn : 24AA8CA4150H225
 For online appointment : www.askapollo.com



For online appointment : www.askapollo.com
 Keep the records carefully and bring them along during your next visit to our Hospital

The Emergency Specialist
 Saving time. Saving lives.



Organization is Accredited
by Joint Commission International

DEPARTMENT OF HAEMATOLOGY



Name : Mrs. HETAL PATEL
 Age : 35Yr 4Mth 24Days Gender : Female
 UHID : AHCC.0000127063 / AHCCAH4471
 W/BNo/RefNo : AHC
 SIN LRN : 3750620 \ 1608362
 Specimen : Whole Blood (EDTA)
 Ref Doctor : DR. MHC



Collected on : 11-FEB-2023 08:45:40 AM Received on : 11-FEB-2023 09:00:37 AM Reported on : 11-FEB-2023 12:03:11 PM

11/02/2023

Report Status:Final

* END OF REPORT *

CHECKED BY : 1010616
 723343

Printed On : 12-FEB-2023 10:02:46 AM

DR. JAYDEEP BARIYA,
 MD PATHOLOGY,
 CONSULTANT

For Enquiry/Appointments Contact +91 76988 15003 / +91 79 66701880





Organization is Accredited
by Joint Commission International

DEPARTMENT OF BLOOD BANK



Name : Mrs. HETAL PATEL
 UHID : AHCC.0000127063 / AHCCAH4471
 SIN \LRN : 3750619 \ 1608362
 Specimen : Blood
 Ref Doctor : DR. MHC

Age : 35Yr 4Mth 24Days Gender : Female

W/BNo/RefNo : AHC



Collected on : 11-FEB-2023 08:45:40 AM Received on : 11-FEB-2023 04:02:20 PM Reported on : 11-FEB-2023 04:51:14 PM

MEDIWHEEL-FULL BODY CHK-BELOW40-FEMALE

TEST NAME RESULT


BLOOD GROUPING AND TYPING (ABO and Rh)

BLOOD GROUP: A Positive

Report Status: Final

* END OF REPORT *

CHECKED BY : 1010661
717844



Printed On : 12-FEB-2023 10:03:02 AM

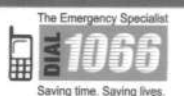Dr. SANJAY GUPTA
MBBS, DIHBT,
CONSULTANT, BLOOD BANK

For Enquiry/Appointments Contact +91 76988 15003 / +91 79 66701880

Apollo Hospitals International Limited
Plot No. - A, Bhat, GIDC, Gandhinagar, Gujarat - 382428, India.
Phone : +91 79 66701800 | Fax No. : +91 79 66701843
E-mail : info@apolloahd.com | www.ahmedabad.apollohospitals.com

Apollo Hospitals - City Centre (NON NABH-JCI)
1, TulsiBaag Society, Nr. Parimal Garden, Ahmedabad.
Phone : +91 79 66305800 / 01 or +91 76988 15148
E-mail : infoahcc@apolloahd.com

Regd. Office
19, Bishop Gardens, R.A. Puram, Chennai - 600 028
CIN No. : U85110TN1997PLC039016 | GSTin : 24AACBA4150H225
For online appointment : www.askapollo.com





Organization is Accredited
by Joint Commission International



DEPARTMENT OF HISTOPATHOLOGY

**

Name : Mrs. HETAL PATEL Age : 35Yr Gender : Female
 UHID : AHCC.0000127063 / AHCCAH4471 W/BNo/RefNo : AHC
 Lab No : AHIL01.H2300306 LRN : 1608362
 Ref Doctor : DR. BHAWANA DAGA



Collected on : 11-FEB-2023 08:45:40 AM Received on : 11-FEB-2023 04:03:49 PM Reported on : 13-FEB-2023 03:11:54 PM

MEDIWHEEL-FULL BODY CHK-BELOW40-FEMALE

CONVENTIONAL PAP SMEAR /CERVICAL SMEAR

Ref No:
CY 267/23

Brief Clinical History:
LMP: 10.1.2023

SPECIMEN TYPE:
Conventional
Cervical smear

One wet fixed smear received, labeled as 'Hetal AHCC 127063'.

SPECIMEN ADEQUACY:
Satisfactory for evaluation with endocervical cells.

INTERPRETATION/RESULT:

*

Negative for intraepithelial lesion or malignancy associated with moderate inflammation

* END OF REPORT *

Dr. SUCHITA K PATEL
MD PATHOLOGY

Typed By: 1058420

Printed On : 14-FEB-2023 09:25:59 AM


For Enquiry/Appointments Contact +91 76988 15003 / +91 79 66701880



Organization is Accredited
by Joint Commission International



DEPARTMENT OF RADIOLOGY AND IMAGING SCIENCES

Patient Details : Mrs. HETAL PATEL | Female | 35Yr 4Mth 24Days
UHID : AHCC.0000127063 **Patient Location:** AHC
Patient Identifier: AHCCA4471 
DRN : 123019018 **Completed on :** 11-FEB-2023 10:49
Ref Doctor : DR. MHC

X-RAY CHEST PA

FINDINGS :

Both lung fields appear normal. No evidence of consolidation or collapse.
 Bilateral hilar shadows appear normal. Trachea and major bronchi appear normal.
 Cardiothoracic ratio is normal.
 Both costophrenic angles are clear. Domes of diaphragm are well delineated.
 Visualized bony thorax appear normal.

IMPRESSION

NORMAL STUDY.

— END OF THE REPORT —

T.V. Parikh

TIRTH VINAYKUMAR PARIKH

Printed on : 11-Feb-2023 14:15

Printed By : 1232062

Reported By : 717876

Page 1 of 1

For Enquiry/Appointments Contact +91 76988 15003 / +91 79 66701880

Apollo Hospitals International Limited

Plot No.-1A, Bhat, GIDC, Gandhinagar, Gujarat - 382428, India.
 Phone : +91 79 66701800 | Fax No. : +91 79 66701843
 E-mail : info@apolloahd.com | www.ahmedabad.apollohospitals.com

Apollo Hospitals - City Centre (NOW NABH-JCI)

1, TulsiBaag Society, Nr. Parimal Garden, Ahmedabad.
 Phone : +91 79 66305800 / 01 or +91 76988 15148
 E-mail : infoahcc@apolloahd.com

Regd. Office

19, Bishop Gardens, R.A. Puram, Chennai - 600 028
 CIN No. : U85110TN1997PLC039016 | GSTin : 24AABCA4150H225
 For online appointment : www.askapollo.com

The Emergency Specialist



Saving time. Saving lives.

For online appointment : www.askapollo.com


Keep the records carefully and bring them along during your next visit to our Hospital



Organization is Accredited
by Joint Commission International



DEPARTMENT OF RADIOLOGY AND IMAGING SCIENCES

Patient Details : Mrs. HETAL PATEL | Female | 35Yr 4Mth 24Days
UHID : AHCC.0000127063 **Patient Location:** AHC
Patient Identifier: AHCCA4471 
DRN : 223007733 **Completed on :** 11-FEB-2023 09:43
Ref Doctor : DR. MHC

USG WHOLE ABDOMEN

IMPRESSION

Liver appears normal in size and shows uniform normal echotexture. No evidence of focal or diffuse pathology seen. Intra and extra hepatic biliary radicles are not dilated. Portal vein is normal in caliber. Intrahepatic portal radicles appear normal.

Gall bladder appears normal with no evidence of calculus. Wall thickness appears normal. No evidence of pericholecystic collection.

Visualized pancreas appear normal in size and echotexture. No focal lesions identified.

Visualize pancreatic duct appears normal in caliber.

Spleen is normal in size and shows uniform echotexture.

Both kidneys are normal in size and show normal echopattern with good corticomedullary differentiation. Cortical outlines appear smooth. No evidence of calculi. Pelvicalyceal system on both sides appear normal.

No evidence of ascites or significant lymphadenopathy. Visualized bowel loops appear normal and shows normal peristalsis.

Urinary bladder is normal in contour and outline. Wall thickness appears normal. No evidence of any intraluminal pathology seen.

On transabdominal scan;

Uterus measures 8.4 x 5.4 x 4.4 cm. IUCD in situ

Uterus is anteverted and appears normal in size and echotexture. No focal lesion noted.

Myometrial and endometrial echotexture appears normal.

Both ovaries appears normal in size and echotexture. No definite evidence of adnexal/pelvic mass is seen.

IMPRESSION :

Printed on : 11-Feb-2023 14:15

Printed By : 1232062

Reported By : 717876

Page 1 of 2

For Enquiry/Appointments Contact +91 76988 15003 / +91 79 66701880



Organization is Accredited
by Joint Commission International



Mrs. HETAL PATEL

AHCC.0000127063

AHCCA4471

USG WHOLE ABDOMEN

No significant abnormality detected.

— END OF THE REPORT —

T.V. Parikh

TIRTH VINAYKUMAR PARIKH

Printed on : 11-Feb-2023 14:15

Printed By : 1232062

Reported By : 717876

Page 2 of 2

For Enquiry/Appointments Contact +91 76988 15003 / +91 79 66701880

Apollo Hospitals International Limited

Plot No.-1A, Bhat, GIDC, Gandhinagar, Gujarat - 382428, India.
Phone : +91 79 66701800 | Fax No. : +91 79 66701843
E-mail : info@apolloahd.com | www.ahmedabad.apollohospitals.com

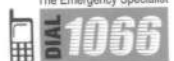Apollo Hospitals - City Centre (NON HASH-JCI)

1, TulsiBaag Society, Nr. Parimal Garden, Ahmedabad.
Phone : +91 79 66305800 / 01 or +91 76988 15148
E-mail : infoahcc@apolloahd.com

Regd. Office

19, Bishop Gardens, R.A. Puram, Chennai - 600 028
CIN No. : U85110TN1997PLC039016 | GSTIN : 24AABCA4150H225
For online appointment : www.askapollo.com

The Emergency Specialist



Saving time. Saving lives.

For online appointment : www.askapollo.com

Keep the records carefully and bring them along during your next visit to our Hospital



ELECTROCARDIOGRAM REPORT

AHCC:0000127063
 MRS. HETAL PATEL
 Age: 35 Year(s) Year(s)/Female
 11 Feb 2023 8:18:30 AM



Name: _____ Age/Sex: _____ Date: _____
 Ref. By: _____ ECG No. _____ UHID/IP: _____

Referral Diagnosis:

Atria - Rate:

Rhythm:

Axis:

PR Interval:

P Wave:

Voltage:

Q Wave:

S-T Changes:

Final Impression:

Reported By: _____

Ventricular Rate:

QRS:

QTc:

	V _{4R}	V ₁	V ₂	V ₅	V ₆
R/S					



*Caution: Please get the ECG photocopied for future reference.

Name:

Sex: Birth date: /

years mmHg

1100 Sinus rhythm
9110 ** normal ECG **

Medication:

Symptoms:

History:

Vent. rate 92 bpm
 PR int 152 ms
 QRS dur 80 ms
 QT/QTc(E) int 338/388 ms
 P/QRS/T axis 54/ 56/ 0 °
 RV5/SV1 amp 0.32/ 0.26 mV
 RV5+SV1 amp 0.58 mV

AHCC:0000127063

MRS. HETAL PATEL

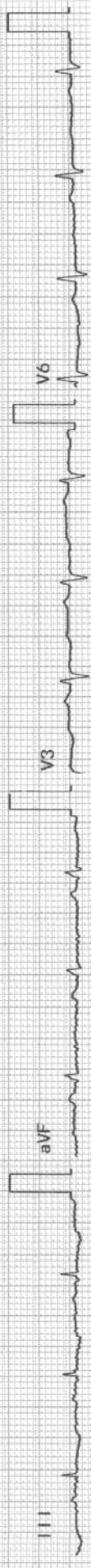
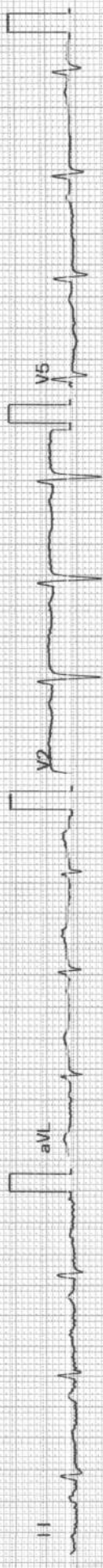
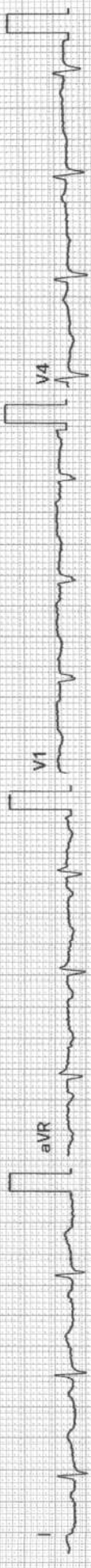
Age: 35 Year(s) Female

11 Feb 2023 8:18:31 AM



Unconfirmed Report
Reviewed by:

10 mm/mV 25 mm/s Filter: H50 D 35 Hz 10 mm/mV 10 mm/mV 10 mm/mV



EYE CHECK UP

NAME Mrs Helal Patel

Date

11/10/23
35/F

VA $\leftarrow \begin{matrix} 6/9 \\ 9/6P \end{matrix}$ *normal*

flo

BCVA(Distance & Near)

RE +1.0 x 170 ~ 6/6

LE +0.75 x 180 ~ 6/6

Colour Vision Normal

Advice:



Anterior Segment

Fundus

Advice:

Diagnosis



AHCC.0000127063
MRS. HETAL PATEL
Age: 35 Year(s) Year(s)/Female
11 Feb 2023 8:18:27 AM



Physician

OBSTETRICS & GYNAECOLOGY - AHC

Name :	Date :	Unit No. :
Occupation :	Ref. Physician :	
Age : Sex : <input type="checkbox"/> Male <input type="checkbox"/> Female	Copies to :	

GYNAEC CHECK UP

Chief Complaint:

~~Passage~~ Passage of urine during coughing, vaginal discharge

Children: 2 FTND (♂ - 10 yrs, ♀ - 4 yrs)

Weight:

BP:

Last Child: 4 yrs

Breasts: NAD

PAP Smear: Taken

Abortions:

Previous Medical H/O:

Nil

Periods: Regular

Previous Surgical H/O:

Nil

LMP: ~~10/01/23~~ 10/01/23

Menopause:

G. Condition: Good

P/A: Soft

S/E: Erosion cervix

P/V: ut. Ad. Ns, fx clear

P/R:

Impression: Adv. colpocopy sis

J. Chavri

Doctor Signature
Date & Time



AHCC.0000127063
 MRS. HETAL PATEL
 Age: 35Year(s) Year(s)/Female
 11 Feb 2023 8:18:21 AM



DENTISTRY

Name : Date : 11/02/23 Unit No. :

Occupation : Ref. Physician :

Age : Sex : Male Female Copies to :

DENTAL RECORD

ALLERGIES :

PAIN : Score (0-10) _____ Location : _____ Character : _____

DENTAL CLEANING HABIT

<input checked="" type="checkbox"/> Once	<input type="checkbox"/> Twice	<input type="checkbox"/> Occasionally
<input checked="" type="checkbox"/> Brush	<input type="checkbox"/> Finger	<input type="checkbox"/> Stick
<input checked="" type="checkbox"/> Tooth Paste	<input type="checkbox"/> Powder	<input type="checkbox"/> Any other
		<input type="checkbox"/> Any other

DO THE GUMS BLEED WHEN YOU BRUSH YOUR TEETH?

Yes No

ARE YOUR TEETH SENSITIVE TO HEAT / COLD?

Yes No

ORAL HYGIENE

Good Fair Poor

ORAL TISSUE EXAMINATION		PERIODONTAL EXAMINATION			OCCLUSION			
NORMAL FINDINGS IN DISEASE		MILD	MOD	SEV	CLASS	I	II	III
Lips	:			<input checked="" type="checkbox"/>	CROSSBITE			
Cheeks	:			<input checked="" type="checkbox"/>	Hypoplasia			
Tongue	:			<input checked="" type="checkbox"/>	Impaction			
Floor of the mouth	:			<input checked="" type="checkbox"/>	Non-vital			
Palate	:			<input checked="" type="checkbox"/>	Fracture			
Tonsillar Area	:			<input checked="" type="checkbox"/>	Abcess			
Any other	:			<input checked="" type="checkbox"/>	Ulcers			
				<input checked="" type="checkbox"/>	Caries			
				<input checked="" type="checkbox"/>	Missing Teeth			
				<input checked="" type="checkbox"/>	Supernumerary			
				<input checked="" type="checkbox"/>	Others			

PRESENT COMPLAINT :

PRE-MEDICAL HISTORY: DM HTN Thyroid Acidity Pregnancy
 Anticoagulant Under Drug Therapy

APOLLO HOSPITAL - CITY CENTER

OPP. DOCTOR HOUSE, ELLISBRIDGE, AHMEDABAD

Ms. MRS HETAL PATEL

ID : 127063

Ht/Wt : 151/71

Recorded : 11-2-2023 10:41

TREADMILL TEST SUMMARY REPORT

Protocol: BRUCE PROCTOCAL

History: Routine Check Up.

Indication1: CVS EVALUATION

Indication2: TECH JAYESH N SHAH

Indication3:

Medication1: NIL

Medication2: NIL

Medication3: NIL

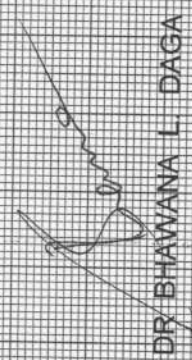
PHASE	PHASE TIME	STAGE TIME	SPEED (Km/Hr.)	GRADE (%)	H.R. (BPM)	B.P. (mmHg)	RPP X100	II	ST LEVEL (mm) V2	V5	METS
SUPINE											
STAGE 1	2:59	2:59	2.70	10.00	103	120/80	123	-0.9	0.3	-0.7	
STAGE 2	5:59	2:59	5.40	14.00	123 125	122/82 128/84	150 160	-1.1 -1.8	0.2 0.5	-0.8 -1.5	4.80 7.10
PEAK EXER	6:10	0:10			160	134/86	214	-1.6	0.4	-1.3	7.26

RESULTS

Exercise Duration : 6:10 Minutes
 Max Heart Rate : 160 bpm 86 % of target heart rate 185 bpm
 Max Blood Pressure : 134/86 mmHg
 Max Work Load : 7.26 METS
 Reason of Termination :

IMPRESSIONS

TEST IS NEGATIVE AT MODERATE WORKLOAD
 NO ANGINA OR ARRHYTHMIA PROVOKED
 NORMAL HEAMODYNAMIC RESPONSE
 NO GALLOP OR MURMUR HEART AT PEAK EXERCISE
 TEST TERMINATED DUE TO THR ACHIEVED.
 TACHYCARDIA PRESENT.
 MODERATE EFFORT TOLERANCE


 DR BHAWANA L. DAGA