


Mediwheel.


*[Signature]*  
**DR. HARI CHHABLANI**  
M.B.B.S. (DIPLOMA IN MEDICAL RADIOLOGY)  
FELLOW INTENSIVE CARE  
MMC REG. NO. - 91702

**'DR. PLUS HEALTHCARE CENTRE'**  
NATHANI HEIGHTS', B-WING,  
42, MUMBAI CENTRAL (EAST)

*[Signature]*

32/m

 भारत सरकार  
GOVERNMENT OF INDIA

 सुशांत कुमार बिहारी  
Sushant Kumar Behera  
जन्म तिथि / DOB: 04/03/1989  
पुरुष / MALE  
Mobile No.: 9861994145

**2972 5709 2420**  
VID: 9157 2109 4963 1092

**मेरा आधार, मेरी पहचान**



# Dr-Plus Healthcare Centre

NATHANI HEIGHTS, B-Wing, Shop No. 42, Ground Floor, Opp. Mumbai Central Station (East), Mumbai - 400 008.

NAME : SUSHANT BEHERA

32/M

DATE:26/03/2022

REF BY : DR. HARI CHHABLANI

## 2D-ECHO. AND COLOR DOPPLER REPORT

- NORMAL CARDIAC VALVES WITH TRIVIAL TR.
- NORMAL CARDIAC CHAMBERS
- NO E/O REGIONAL WALL MOTION ABNORMALITY. WITH NORMAL LVEF OF 62 %.
- NO E/O PULMONARY HYPERTENSION .PASP 34 mmHg by TR jet.
- NO E/O LEFT VENTRICULAR HYPERTROPHY.
- NO E/O DIASTOLIC DYSFUNCTION.
- NO E/O PERICARDIAL EFFUSION.
- NO E/O INTRACARDIAC CLOT OR VEGETATION
- INTACT IAS / IVS

### - CONVENTIONL DOPPLER :

E TO A RATIO IS MORE THAN ONE IN LV INFLOW.


THERE IS NO GRADIENT ACROSS AV, LVOT OR RVOT

PASP FROM TR JET IS 34 mm OF Hg.

### - COLOUR DOPPLER:

TRIVIAL TR

EF Slope	109	mm/sec		
Opening Amplitude	21			
Posterior leaflet				
E.P.S.S	02	mm		
Mitral valve prolapse				
Vegetations				
<b>TRICUSPID VALVE</b>	<b>OBSERVED</b>	<b>NORMAL VALUES</b>		
<b>PULMONARY VALVE</b>	<b>OBSERVED</b>	<b>NORMAL VALUES</b>		
EF Slope				
'A' Wave				
Midsystolic notch				
Flutter				
Other Findings				
<b>AORTIC VALVE</b>	<b>OBSERVED</b>	<b>NORMAL VALUES</b>		
Cuspal opening	18	mm		
Closure line	Central			
Eccentricity index	1			
Other Findings				
<b>DIMENSIONS</b>	<b>OBSERVED</b>	<b>NORMAL VALUES</b>		
1. Lvd (Diastolic)	45	26-52		
2. Lvd (Systolic )	27	24-42mm		
3. RVD (Diastolic)	18	7-23mm		
4. IVST (Diastolic)	08	6-11mm		
5. IVST (Systolic )	15			
6. LVPWT (Diastolic)	08	6-11mm		
7. LVPWT (Systolic )	16			
8. Aortic root	34	22-37mm		
9. left Atrium	25	19-40mm		
	<b>STRUCTURE</b>	<b>REGURG GRADING</b>	<b>VELOCITY m/sec</b>	<b>STENOSIS GRADIENT mm/Hg</b>
			Max mean	Peak mean
<b>MITRAL VALVE</b>	NORMAL	0/3	/	/
<b>TRICUSPID VELVE</b>	NORMAL	TRIVIAL	/	/
<b>PULMONARY VELVE</b>	NORMAL	0/4	/	/
<b>AORTIV VALVE</b>	NORMAL	0/4	/	/

  
**DR.P.H.CHHABLANI**  
 M.B.B.S, DNB.(MEDICINE)  
 CONSULTANT PHYSICIAN AND CARDIOLOGIST.

**DR. PURVI CHHABLANI**  
 M.B.B.S, DNB. (Medicine)  
 Consultant Physician And Internist  
 Reg No 77892

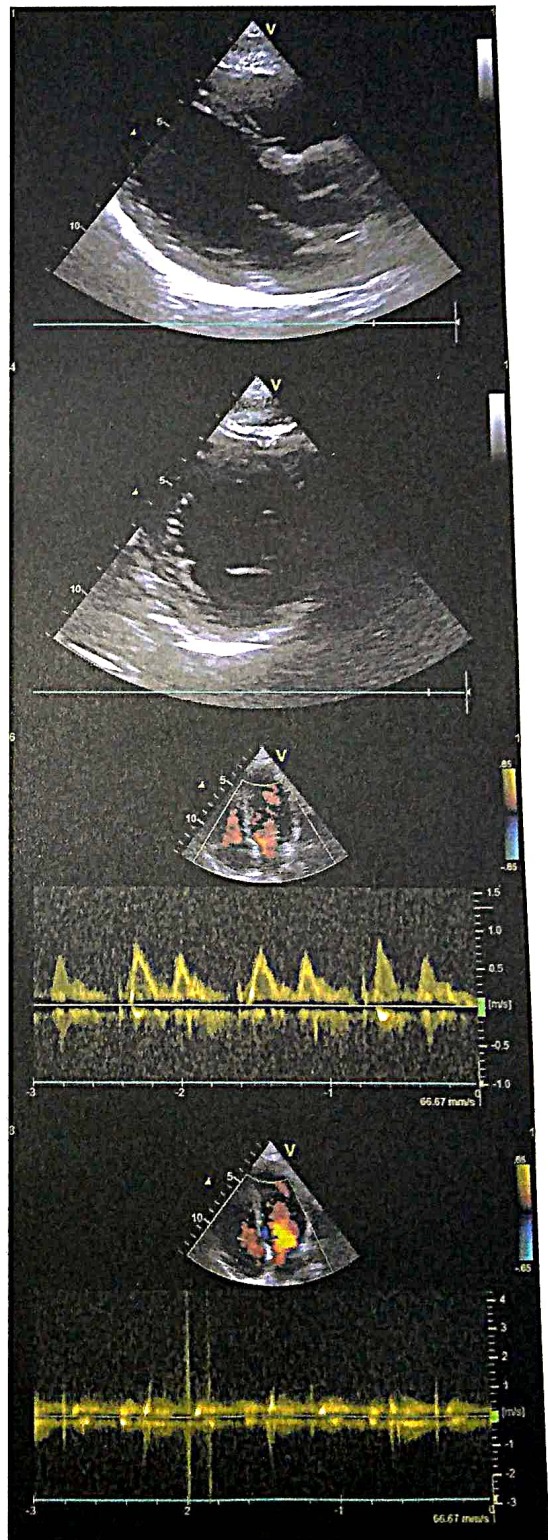
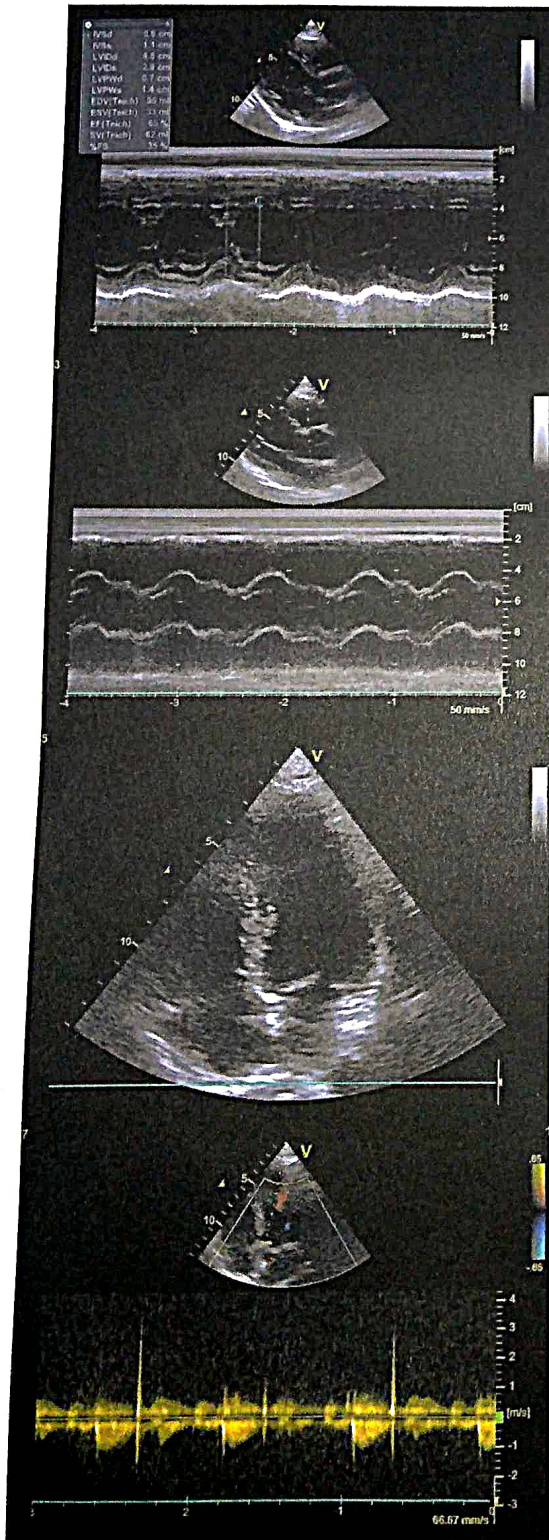
Handwritten mark

Name **SUSHANT BEHERA**

Sex **Male**

Age **32**

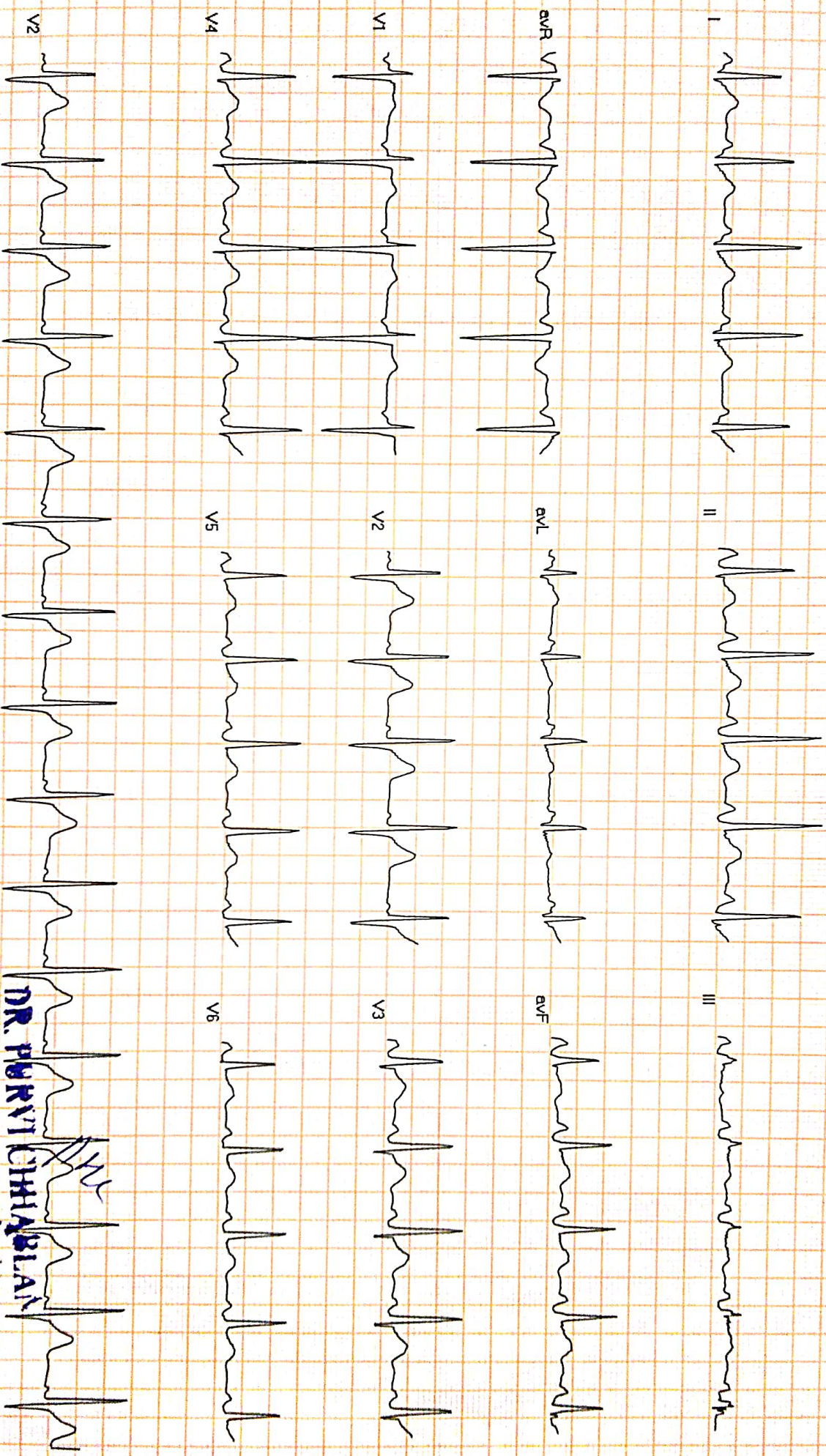
Date **26/03/2022**



**DR PLUS HEALTHCARE CENTRE- MUMBAI CENTRAL**

**ECG**

1592 / SUSHANT BEHERA / 32 Yrs / M  
Heart Rate : 96 bpm / Tested On : 26-Mar-22 12:56:56 / HF 0.05 Hz - LF 100 Hz / Notch 50 Hz / Sn 1.00 Cm/mV / Sw 25 mm/s  
/ Refd By: DR. HARI CHHABLANI



DR. PLUS HEALTHCARE CENTRE  
NATHANI HEIGHTS, B-WING  
42, MUMBAI CENTRAL (EAS)

DR. PURVI CHHABLANI  
MBBS, DNB- (Medicine),  
Consultant Physician And Interventional  
Cardiologist  
Reg. No 77997  
Reported By: DR. PURVI CHHABLANI



# Dr-Plus Healthcare Centre

NATHANI HEIGHTS, B-Wing, Shop No. 42, Ground Floor, Opp. Mumbai Central Station (East), Mumbai - 400 008.

Patient Name	:	SUSHANT BEHERA	Sex:	MALE
Doctor's Name	:	DR. H. CHHABLANI	Age:	32 YEARS
Date	:	26/03/2022		

## ULTRASONOGRAPHY OF THE ABDOMEN AND THE PELVIS:

The relevant sonographic findings include the following:

### HEPATOBIILIARY APPARATUS

The liver is normal in size and echogenicity. No obvious focal parenchymal lesion is seen. Extrahepatic biliary radicals are not dilated. The portal vein and the common bile duct are normal.

### GALL BLADDER

The gall bladder is adequately distended. The wall thickness is normal. No echogenic contents are noted in its lumen. There is no pericholecystic collection noted.

### PANCREAS

The pancreas shows normal echogenicity and size. No focal or diffuse lesions are noted. No evidence of calcification is noted.

### SPLEEN

The spleen appears normal in size and echogenicity. No focal or diffuse lesions are noted. No evidence of calcification is noted.

### KIDNEYS

Right Kidney measure: 10.7 x 5.2 cm, Left kidney measure: 10.4 x 4.8 cm

Both the kidneys appear normal in size, shape and echogenicity. Both the pelvicalyceal system is normal and both corticomedullary differentiations are well maintained. There is no obvious focal or diffuse lesion noted. No evidence of any calculus seen in either kidney.

### PROSTATE

The Prostate appears normal and shows a normal echogenicity.

### URINARY BLADDER

The urinary bladder shows anechoic contents. Its wall thickness appears normal. No evidence of calcification is seen. There is no obvious evidence of abdominal or pelvic lymphadenopathy or ascites noted.

**IMPRESSION: No significant abnormality is detected.**

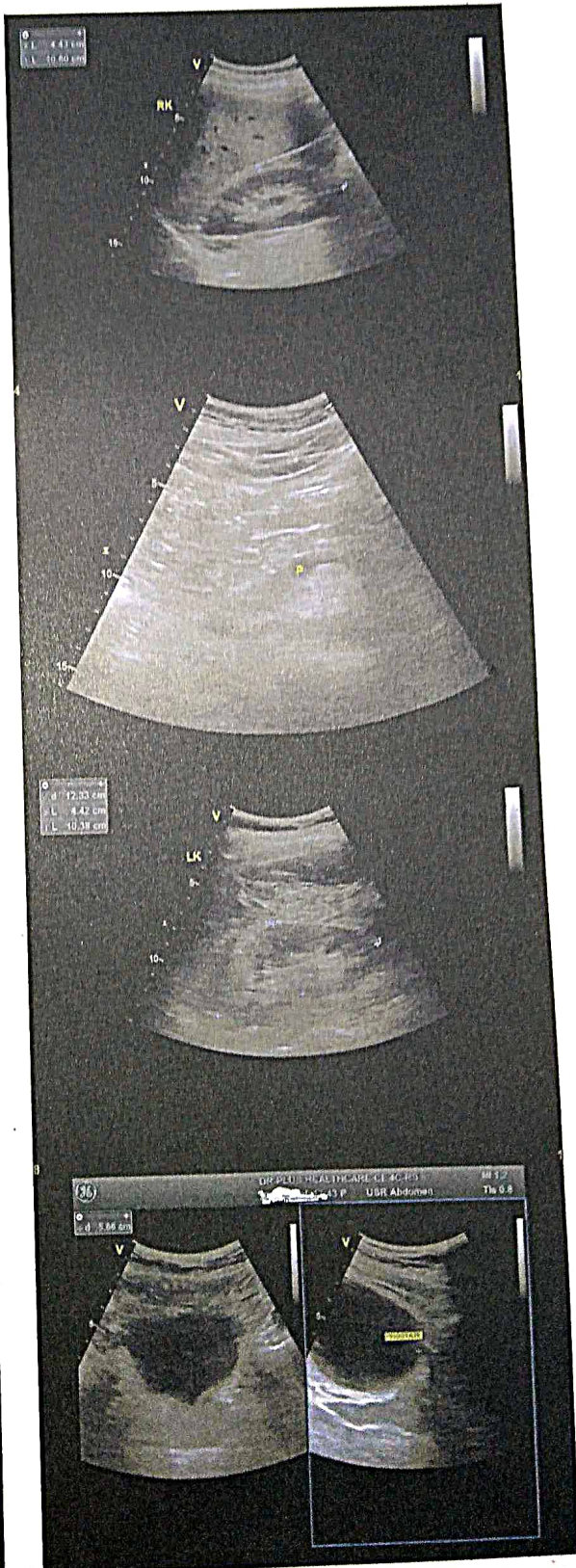
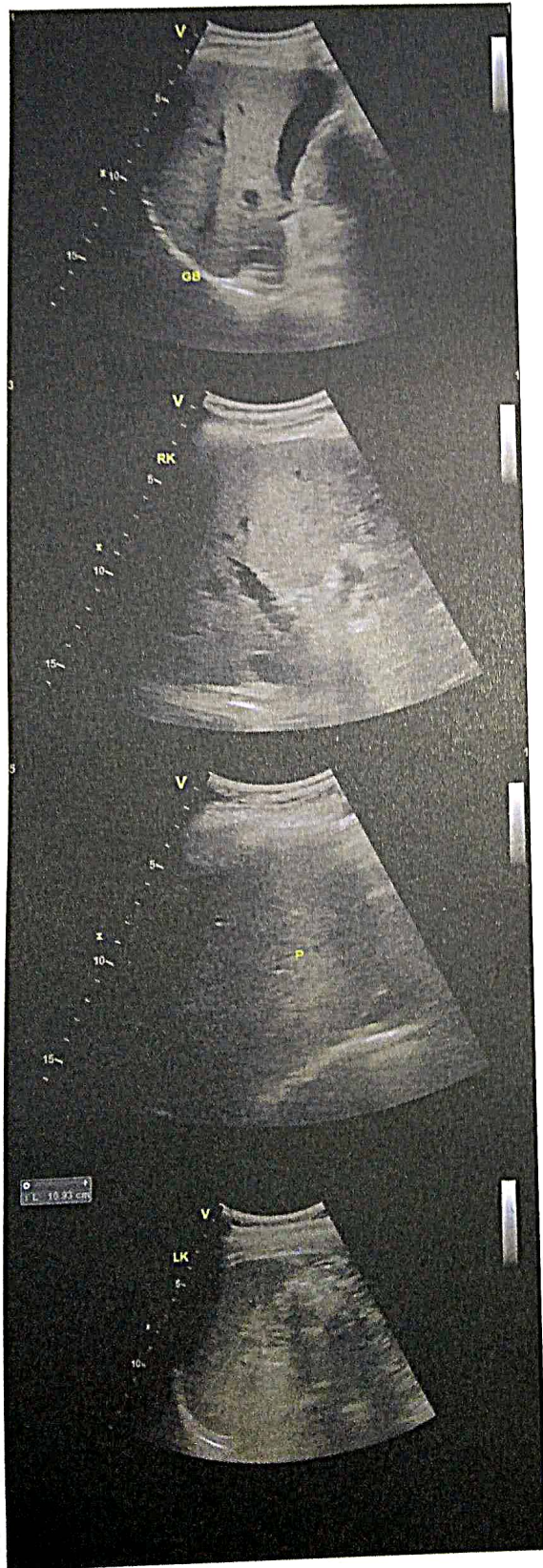  
Dr. Parag Jhaveri  
MBBS (BOM), DMRE (BOM)  
Radio-Sonologist

**"DR. PLUS HEALTHCARE CENTRE"  
NATHANI HEIGHTS', B-WING,  
42, MUMBAI CENTRAL (EAST)**

Name **SUSHANT BEHERA**

Sex **Male**

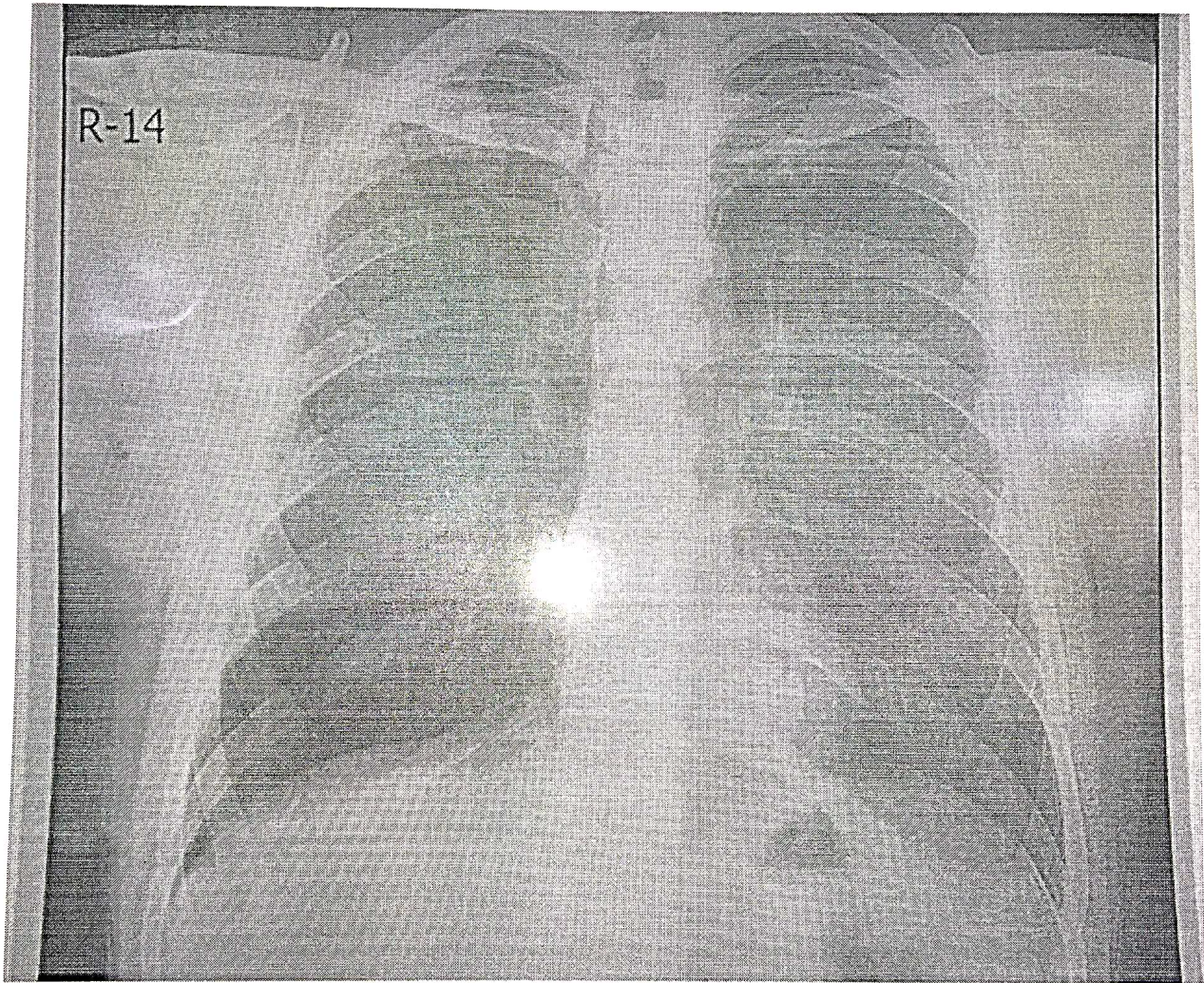
Age **32**



NAME : SUSHANT BEHERA

32/M

26/03/2022







# Dr-Plus Healthcare Centre

NATHANI HEIGHTS, B-Wing, Shop No. 42, Ground Floor, Opp. Mumbai Central Station (East), Mumbai - 400 008.

Patient's Name : SUSHANT BEHERA

Report Date : 26/03/2022

Referred By : SELF

Age : 32 Years

Sex : MALE

## X- RAY CHEST

BOTH THE LUNG FIELED ARE CLEAR.


THE HILAR SHADOWS APPEAR NORMAL.

THE COSTO-PHRENIC ANGELS ARE CLEAR.

THE CARDIAC SHADOWS APPEAR NORMAL.

THE TRACHEAL IS CENTRAL IN POSITION.

THE BONY CAGE APPEARS NORMAL.

  
DR. A. J. MAZUMDAR

MD. DMRE, MDRD

**"DR. PLUS HEALTHCARE CENTRE"**  
NATHANI HEIGHTS, B-WING,  
42, MUMBAI CENTRAL (E-WING)



# Dr-Plus Healthcare Centre

NATHANI HEIGHTS, B-Wing, Shop No. 42, Ground Floor, Opp. Mumbai Central Station (East), Mumbai - 400 008.

Full Name

SUSHANT BEHERA

32/M

26/03/2022

Life to be assured:

	Type of Test	Actual Reading	Normal Range
1	Fasting Blood Sugar	85.7	70-100 mg%
2	PPBS	124.2	110 TO 140 mg%
3	Total Cholesterol	191	120-200 mg%
4	VERY LOW DENSITY LEVEL(VLDL)	16	10-30 mg/dl
5	High Density Lipid (HDL)	55	40-60 mg%
6	Low Density Lipid (LDL)	120	<u>Upto 150</u>
7	S. Triglycerides	119.6	50-150 mg%
8	CHOL/HDL	3.4	Upto 5
9	HDL/LDL	0.4	
10	S. Creatinine	0.8	0.5-1.2 mg%
11	Blood Urea Nitrogen (BUN)	18	7-21 mg%
12	BUN/CREAT RATIO	22.5	
13	S. Proteins	6.6	6.0-7.9 mg%
14	(a) Albumin	3.5	3.5-5.5 mg%
15	(b) Globulin	3.1	2.0-3.5 mg%
16	A/G RATIO	1.1	
17	S. Bilirubin	0.8	0.3-1.3mg%
18	(a) Direct	0.5	0.0-0.8 mg%
19	(b) Indirect	0.30	0.0-0.5 mg%
20	SGOT (AST)	23.1	05-34 IU
21	SGPT (ALT)	30.5	05-40 IU
22	GGTP (GGT)	41.2	05-50 IU
23	SGOT/SGPT	0.7	
24	HBA1C	5.3	UPTO 6.5
25	S. Alkaline Phosphatase	90.1	30-115 IU
26	T3	165.2	80-180ng/dl
27	T4	4.9	4.6-12 ug/dl
28	TSH	2.1	0.4-4.0 mIU/L
29	SERUM URIC ACID	7.2	2.5-7.2mg/dl
30	URINE SUGAR PP	ABSENT	
31	URINE SUGAR FASTING	ABSENT	
32	BLOOD GROUP	" B POSITIVE "	

DR. RAKESH PATKAR  
M.D., D.M.B. (Pathology)  
Reg. No. 2013/05/1860



# Dr-Plus Healthcare Centre

NATHANI HEIGHTS, B-Wing, Shop No. 42, Ground Floor, Opp. Mumbai Central Station (East), Mumbai - 400 008.

Full Name of life to be assured:

SUSHANT BEHERA

32/M

DATE:26/03/2022

## HAEMOGRAM

### Normal Range

1.	Red Blood Cell Count	4.6	[M : 4.5 - 5.6 / F : 3.5 - 5.5/cu.mm]
2.	Hb%	14.8	[M: 14-18 / F : 11-16%]
3.	Hematocrit	46.3	[M : 40-53 / F : 30-47 %]
4.	Indices:		
(a)	MCV(Mean Corpuscular Volume)	87.5	[79-101 cu.mi.]
(b)	MCH(Mean Corpuscular Hb)	30.2	[27-32 pg]
(c)	MCHC(Mean Corpuscular Hb Concentration)	32.6	[32-38%]
5.	Morphology		
	Macrocytes : --	Microcytes: --	Hypochromia: --
	Piokilocytosis: --	Anisocytosis: --	
6.	Target cells: --		
	Spherocytes: --	Elliptocytes: --	
7.	<b>TOTALW.B.C.Count</b>	6,700	{4000-11000/cu.mm}
Differential Count0			
a)	Neutrophils :	61	[45 -70%]
b)	Lymphocytes :	30	[20 - 45%]
c)	Eosinophils:	05	[01 - 06%]
d)	Monocytes:	04	[00 - 08%]
e)	Basophils :	00	[00 - 01%]
8.	<b>Platelets :3.54</b>		1.5-4.5 Lacks/cu.mm
9.	<b>Erythrocyte Sedimentation Rate:10</b>		20 mm at end of 1 hour
			Method : Westergrens

## ROUTINE URINE EXAMINATION (RUA)

### 1. Physical Examination:

(i)	Colour:	PLAN YELLOW	(ii)	Sediment:	CLEAR
(iii)	Transparency:	ABSENT	(iv)	Reaction:	ACIDIC
(v)	Specific gravity	1.010			

### 2. Chemical Examination:

(i)	Protein :	ABSENT	(ii)	Sugar:	ABSENT
(iii)	Bile salt:	ABSENT	(iv)	Bile pigment:	ABSENT

### 3. Microscopic Examination:

(i)	Red Blood Cells:	ABSENT	(ii)	Epithelial Cells:	ABSENT
(iii)	Crystals:	ABSENT	(iv)	Pus Cells:	04 TO 05/HPF
(v)	Casts:	ABSENT	(vi)	Deposits:	ABSENT
(vii)	Bacteria's :	ABSENT			

**DR. RAKESH PATKAR**  
M.D., D.N.B. (Pathology)  
Reg. No. 2013/05/1660



**Dr. Hari Chhablani**

Cardiometabolic Physician & Intensivist  
M.B.B.S., F.C.C.P. (RESP. MED.), PGDHHM,  
PGDMLS, FELLOW INTENSIVE CARE MED.

ATTACHED TO: Wockhardt Hospital • Saifee Hospital • Apollo Spectra Hospital

NATHANI HEIGHTS, B-Wing, Shop No. 42, Ground Floor, Opp. Mumbai Central Station (East),  
Mumbai - 400 008. • Cell : 98206 46163 • E : drharichhablani@gmail.com

## PHYSICIAN REPORT

DATE : 26/03/2022

NAME : SUSHANT BEHERA 32/M

PRESENTING COMPLAINS : K/C/O ALLERGIC BRONCHITIS AND GERD ON HOMEOPATHIC TREATMENT

C/O LEFT HYPOCHONDRIAC PAIN SINCE FEW MONTHS

PAST HISTORY : COVID +VE APRIL 2021--IN ISOLATION CENTRE

FAMILY HISTORY: NOT SIGNIFICANT.

HABITS: NIL

HT.- 175 CM. WT.- 58 Kg. BMI.-18.9

P: 96/MIN., REGULAR BP: 110/74

EYE EXAMINATION : NEAR VISION - B/E - N/6, DISTANT VISION -B/E -6/6

COLOR VISION : NORMAL

RS: CLEAR

CVS: S1,S2 REGULAR

PA: SOFT

CNS: CLINICALLY NAD

LABS: ATTACHED

USG - WNL

2D-ECHO- WNL

ECG: WNL

X-RAY - WNL

IMPRESSION : REFER TO GASTROENTROLOGIST.

**DR. HARI CHHABLANI**  
M.B.B.S., F.C.C.P. (RESP. MEDICINE) PGDHHM, PGDMLS  
FELLOW INTENSIVE CARE  
MMC REG. NO. - 91702



आज हदीत, लीगन हदीत  
बासकोपन हदीत मा  
सुनली का नको


मम मासुा पुा प्रलकुपुा गिवाग  
गिवागीत प्रीकुव) १११४ अलगीत  
सुवा मदी आदे कोगीरी व्वासी  
आवकव्वास व्वा व्वासीत १ हास  
होऊ हावलो

गुास गुासी व्वाव्वाग,  
लाग हास गीगीतगिवाग

या सेंटरमध्ये गीगिग रापरगी होत



GPS Map Camera



**Mumbai, Maharashtra, India**  
Shop No 65, Nathani Heights, Marzban Parsi Colony, Dalal  
Estate, Mumbai Central, Mumbai, Maharashtra 400008, India  
Lat 18.968747°  
Long 72.819962°  
26/03/22 09:53 AM