



CID : 2308808565
Name : MR.MAHENDRA GANGARAM PAWAR
Age / Gender : 45 Years / Male
Consulting Dr. : -
Reg. Location : Borivali West (Main Centre)

Collected : 29-Mar-2023 / 08:07
Reported : 29-Mar-2023 / 13:19

Use a QR Code Scanner
Application To Scan the Code

MEDIWHEEL FULL BODY HEALTH CHECKUP MALE ABOVE 40/2D ECHO

CBC (Complete Blood Count), Blood

<u>PARAMETER</u>	<u>RESULTS</u>	<u>BIOLOGICAL REF RANGE</u>	<u>METHOD</u>
<u>RBC PARAMETERS</u>			
Haemoglobin	14.0	13.0-17.0 g/dL	Spectrophotometric
RBC	5.06	4.5-5.5 mil/cmm	Elect. Impedance
PCV	42.5	40-50 %	Measured
MCV	84	80-100 fl	Calculated
MCH	27.7	27-32 pg	Calculated
MCHC	32.9	31.5-34.5 g/dL	Calculated
RDW	15.8	11.6-14.0 %	Calculated
<u>WBC PARAMETERS</u>			
WBC Total Count	5260	4000-10000 /cmm	Elect. Impedance
<u>WBC DIFFERENTIAL AND ABSOLUTE COUNTS</u>			
Lymphocytes	39.0	20-40 %	
Absolute Lymphocytes	2051.4	1000-3000 /cmm	Calculated
Monocytes	9.6	2-10 %	
Absolute Monocytes	505.0	200-1000 /cmm	Calculated
Neutrophils	49.4	40-80 %	
Absolute Neutrophils	2598.4	2000-7000 /cmm	Calculated
Eosinophils	1.6	1-6 %	
Absolute Eosinophils	84.2	20-500 /cmm	Calculated
Basophils	0.4	0.1-2 %	
Absolute Basophils	21.0	20-100 /cmm	Calculated
Immature Leukocytes	-		
WBC Differential Count by Absorbance & Impedance method/Microscopy.			
<u>PLATELET PARAMETERS</u>			
Platelet Count	241000	150000-400000 /cmm	Elect. Impedance
MPV	8.5	6-11 fl	Calculated
PDW	15.0	11-18 %	Calculated
<u>RBC MORPHOLOGY</u>			



CID : 2308808565
Name : MR.MAHENDRA GANGARAM PAWAR
Age / Gender : 45 Years / Male
Consulting Dr. : -
Reg. Location : Borivali West (Main Centre)

Use a QR Code Scanner Application To Scan the Code
Collected : 29-Mar-2023 / 12:14
Reported : 29-Mar-2023 / 18:13

MEDIWHEEL FULL BODY HEALTH CHECKUP MALE ABOVE 40/2D ECHO

PARAMETER	RESULTS	BIOLOGICAL REF RANGE	METHOD
GLUCOSE (SUGAR) FASTING, Fluoride Plasma	95.2	Non-Diabetic: < 100 mg/dl Impaired Fasting Glucose: 100-125 mg/dl Diabetic: >/= 126 mg/dl	Hexokinase
GLUCOSE (SUGAR) PP, Fluoride Plasma PP/R	117.6	Non-Diabetic: < 140 mg/dl Impaired Glucose Tolerance: 140-199 mg/dl Diabetic: >/= 200 mg/dl	Hexokinase
Urine Sugar (Fasting)	Absent	Absent	
Urine Ketones (Fasting)	Absent	Absent	
Urine Sugar (PP)	Absent	Absent	
Urine Ketones (PP)	Absent	Absent	

*Sample processed at SUBURBAN DIAGNOSTICS (INDIA) PVT. LTD Borivali Lab, Borivali West
*** End Of Report ***

Bmhaskar

Dr.KETAKI MHASKAR
M.D. (PATH)
Pathologist





CID : 2308808565
Name : MR.MAHENDRA GANGARAM PAWAR
Age / Gender : 45 Years / Male
Consulting Dr. : -
Reg. Location : Borivali West (Main Centre)

Collected : 29-Mar-2023 / 08:07
Reported : 29-Mar-2023 / 16:02

Use a QR Code Scanner
Application To Scan the Code

MEDIWHEEL FULL BODY HEALTH CHECKUP MALE ABOVE 40/2D ECHO
KIDNEY FUNCTION TESTS

PARAMETER	RESULTS	BIOLOGICAL REF RANGE	METHOD
BLOOD UREA, Serum	22.7	12.8-42.8 mg/dl	Kinetic
BUN, Serum	10.6	6-20 mg/dl	Calculated
CREATININE, Serum	1.20	0.67-1.17 mg/dl	Enzymatic
eGFR, Serum	70	>60 ml/min/1.73sqm	Calculated
TOTAL PROTEINS, Serum	7.0	6.4-8.3 g/dL	Biuret
ALBUMIN, Serum	4.7	3.5-5.2 g/dL	BCG
GLOBULIN, Serum	2.3	2.3-3.5 g/dL	Calculated
A/G RATIO, Serum	2.0	1 - 2	Calculated
URIC ACID, Serum	6.3	3.5-7.2 mg/dl	Enzymatic
PHOSPHORUS, Serum	2.5	2.7-4.5 mg/dl	Molybdate UV
CALCIUM, Serum	9.2	8.6-10.0 mg/dl	N-BAPTA
SODIUM, Serum	140	135-148 mmol/l	ISE
POTASSIUM, Serum	5.0	3.5-5.3 mmol/l	ISE
CHLORIDE, Serum	106	98-107 mmol/l	ISE

*Sample processed at SUBURBAN DIAGNOSTICS (INDIA) PVT. LTD Borivali Lab, Borivali West
*** End Of Report ***

Bmhasakar

Dr.KETAKI MHASKAR
M.D. (PATH)
Pathologist



MC-2111



CID : 2308808565
Name : MR.MAHENDRA GANGARAM PAWAR
Age / Gender : 45 Years / Male
Consulting Dr. : -
Reg. Location : Borivali West (Main Centre)

Collected : 29-Mar-2023 / 08:07
Reported : 29-Mar-2023 / 13:32

Use a QR Code Scanner
Application To Scan the Code

**MEDIWHEEL FULL BODY HEALTH CHECKUP MALE ABOVE 40/2D ECHO
GLYCOSYLATED HEMOGLOBIN (HbA1c)**

PARAMETER	RESULTS	BIOLOGICAL REF RANGE	METHOD
Glycosylated Hemoglobin (HbA1c), EDTA WB - CC	6.4	Non-Diabetic Level: < 5.7 % Prediabetic Level: 5.7-6.4 % Diabetic Level: >/= 6.5 %	HPLC
Estimated Average Glucose (eAG), EDTA WB - CC	137.0	mg/dl	Calculated

Intended use:

- In patients who are meeting treatment goals, HbA1c test should be performed at least 2 times a year
- In patients whose therapy has changed or who are not meeting glycemic goals, it should be performed quarterly
- For microvascular disease prevention, the HbA1C goal for non pregnant adults in general is Less than 7%.

Clinical Significance:

- HbA1c, Glycosylated hemoglobin or glycated hemoglobin, is hemoglobin with glucose molecule attached to it.
- The HbA1c test evaluates the average amount of glucose in the blood over the last 2 to 3 months by measuring the percentage of glycosylated hemoglobin in the blood.

Test Interpretation:

- The HbA1c test evaluates the average amount of glucose in the blood over the last 2 to 3 months by measuring the percentage of Glycosylated hemoglobin in the blood.
- HbA1c test may be used to screen for and diagnose diabetes or risk of developing diabetes.
- To monitor compliance and long term blood glucose level control in patients with diabetes.
- Index of diabetic control, predicting development and progression of diabetic micro vascular complications.

Factors affecting HbA1c results:

Increased in: High fetal hemoglobin, Chronic renal failure, Iron deficiency anemia, Splenectomy, Increased serum triglycerides, Alcohol ingestion, Lead/opiate poisoning and Salicylate treatment.

Decreased in: Shortened RBC lifespan (Hemolytic anemia, blood loss), following transfusions, pregnancy, ingestion of large amount of Vitamin E or Vitamin C and Hemoglobinopathies

Reflex tests: Blood glucose levels, CGM (Continuous Glucose monitoring)

References: ADA recommendations, AACC, Wallach's interpretation of diagnostic tests 10th edition.

*Sample processed at SUBURBAN DIAGNOSTICS (INDIA) PVT. LTD Borivali Lab, Borivali West

*** End Of Report ***



Bmhasakar

Dr.KETAKI MHASKAR
M.D. (PATH)
Pathologist



CID : 2308808565
Name : MR.MAHENDRA GANGARAM PAWAR
Age / Gender : 45 Years / Male
Consulting Dr. : -
Reg. Location : Borivali West (Main Centre)

Collected : 29-Mar-2023 / 08:07
Reported : 29-Mar-2023 / 17:08

Use a QR Code Scanner
Application To Scan the Code

MEDIWHEEL FULL BODY HEALTH CHECKUP MALE ABOVE 40/2D ECHO
PROSTATE SPECIFIC ANTIGEN (PSA)

<u>PARAMETER</u>	<u>RESULTS</u>	<u>BIOLOGICAL REF RANGE</u>	<u>METHOD</u>
TOTAL PSA, Serum	0.771	<4.0 ng/ml	CLIA

Clinical Significance:

- PSA is detected in the serum of males with normal, benign hyper-plastic, and malignant prostate tissue.
- Monitoring patients with a history of prostate cancer as an early indicator of recurrence and response to treatment.
- Prostate cancer screening 4. The percentage of Free PSA (FPSA) in serum is described as being significantly higher in patients with BPH than in patients with prostate cancer. 5. Calculation of % free PSA (ie. FPSA/TPSA x 100), has been suggested as way of improving the differentiation of BPH and Prostate cancer.

Interpretation:

Increased In- Prostate diseases, Cancer, Prostatitis, Benign prostatic hyperplasia, Prostatic ischemia, Acute urinary retention, Manipulations like Prostatic massage, Cystoscopy, Needle biopsy, Transurethral resection, Digital rectal examination, Radiation therapy, Indwelling catheter, Vigorous bicycle exercise, Drugs (e.g., testosterone), Physiologic fluctuations. Also found in small amounts in other cancers (sweat and salivary glands, breast, colon, lung, ovary) and in Skene glands of female urethra and in term placenta, Acute renal failure, Acute myocardial infarction,

Decreased In- Ejaculation within 24-48 hours, Castration, Antiandrogen drugs (e.g., finasteride), Radiation therapy, Prostatectomy, PSA falls 17% in 3 days after lying in hospital, Artifactual (e.g., improper specimen collection; very high PSA levels). Finasteride (5- α -reductase inhibitor) reduces PSA by 50% after 6 months in men without cancer.

Reflex Tests: % FREE PSA , USG Prostate

Limitations:

- tPSA values determined on patient samples by different testing procedures cannot be directly compared with one another and could be the cause of erroneous medical interpretations. If there is a change in the tPSA assay procedure used while monitoring therapy, then the tPSA values obtained upon changing over to the new procedure must be confirmed by parallel measurements with both methods. Immediate PSA testing following digital rectal examination, ejaculation, prostatic massage, indwelling catheterization, ultrasonography and needle biopsy of prostate is not recommended as they falsely elevate levels.
- Patients who have been regularly exposed to animals or have received immunotherapy or diagnostic procedures utilizing immunoglobulins or immunoglobulin fragments may produce antibodies, e.g. HAMA, that interferes with immunoassays.
- PSA results should be interpreted in light of the total clinical presentation of the patient, including: symptoms, clinical history, data from additional tests, and other appropriate information.
- Serum PSA concentrations should not be interpreted as absolute evidence for the presence or absence of prostate cancer.

Reference:

- Wallach's Interpretation of diagnostic tests
- Total PSA Pack insert

Anupa

Dr. ANUPA DIXIT
M.D.(PATH)
Consultant Pathologist & Lab Director





Use a QR Code Scanner
Application To Scan the Code

CID : 2308808565
Name : MR.MAHENDRA GANGARAM PAWAR
Age / Gender : 45 Years / Male
Consulting Dr. : -
Reg. Location : Borivali West (Main Centre)

Collected : 29-Mar-2023 / 08:07
Reported : 29-Mar-2023 / 17:08

*Sample processed at SUBURBAN DIAGNOSTICS (INDIA) PVT. LTD SDRL, Vidyavihar Lab
*** End Of Report ***



CID : 2308808565
Name : MR.MAHENDRA GANGARAM PAWAR
Age / Gender : 45 Years / Male
Consulting Dr. : -
Reg. Location : Borivali West (Main Centre)

Collected : 29-Mar-2023 / 08:07
Reported : 29-Mar-2023 / 15:05

Use a QR Code Scanner
Application To Scan the Code

**MEDIWHEEL FULL BODY HEALTH CHECKUP MALE ABOVE 40/2D ECHO
URINE EXAMINATION REPORT**

PARAMETER	RESULTS	BIOLOGICAL REF RANGE	METHOD
<u>PHYSICAL EXAMINATION</u>			
Color	Pale yellow	Pale Yellow	-
Reaction (pH)	6.0	4.5 - 8.0	Chemical Indicator
Specific Gravity	1.015	1.001-1.030	Chemical Indicator
Transparency	Clear	Clear	-
Volume (ml)	40	-	-
<u>CHEMICAL EXAMINATION</u>			
Proteins	Absent	Absent	pH Indicator
Glucose	Absent	Absent	GOD-POD
Ketones	Absent	Absent	Legals Test
Blood	Absent	Absent	Peroxidase
Bilirubin	Absent	Absent	Diazonium Salt
Urobilinogen	Normal	Normal	Diazonium Salt
Nitrite	Absent	Absent	Griess Test
<u>MICROSCOPIC EXAMINATION</u>			
Leukocytes(Pus cells)/hpf	3-4	0-5/hpf	
Red Blood Cells / hpf	Absent	0-2/hpf	
Epithelial Cells / hpf	1-2		
Casts	Absent	Absent	
Crystals	Absent	Absent	
Amorphous debris	Absent	Absent	
Bacteria / hpf	6-8	Less than 20/hpf	
Others	-		

Interpretation: The concentration values of Chemical analytes corresponding to the grading given in the report are as follows:

- Protein:(1+ ~25 mg/dl, 2+ ~75 mg/dl, 3+ ~ 150 mg/dl, 4+ ~ 500 mg/dl)
- Glucose:(1+ ~ 50 mg/dl, 2+ ~100 mg/dl, 3+ ~300 mg/dl,4+ ~1000 mg/dl)
- Ketone:(1+ ~5 mg/dl, 2+ ~15 mg/dl, 3+ ~ 50 mg/dl, 4+ ~ 150 mg/dl)

Reference: Pack insert

*Sample processed at SUBURBAN DIAGNOSTICS (INDIA) PVT. LTD Borivali Lab, Borivali West

Bmhasakar

Dr.KETAKI MHASKAR
M.D. (PATH)
Pathologist



MC-2111



Use a QR Code Scanner
Application To Scan the Code

CID : 2308808565
Name : MR.MAHENDRA GANGARAM PAWAR
Age / Gender : 45 Years / Male
Consulting Dr. : -
Reg. Location : Borivali West (Main Centre)

Collected :
Reported :

*** End Of Report ***



CID : 2308808565
Name : MR.MAHENDRA GANGARAM PAWAR
Age / Gender : 45 Years / Male
Consulting Dr. : -
Reg. Location : Borivali West (Main Centre)

Collected : 29-Mar-2023 / 08:07
Reported : 29-Mar-2023 / 13:30

Use a QR Code Scanner
Application To Scan the Code

MEDIWHEEL FULL BODY HEALTH CHECKUP MALE ABOVE 40/2D ECHO
BLOOD GROUPING & Rh TYPING

<u>PARAMETER</u>	<u>RESULTS</u>
ABO GROUP	O
Rh TYPING	Positive

NOTE: Test performed by automated Erythrocytes magnetized technology (EMT) which is more sensitive than conventional methods.

Specimen: EDTA Whole Blood and/or serum

Clinical significance:
ABO system is most important of all blood group in transfusion medicine

Limitations:

- ABO blood group of new born is performed only by cell (forward) grouping because allo antibodies in cord blood are of maternal origin.
- Since A & B antigens are not fully developed at birth, both Anti-A & Anti-B antibodies appear after the first 4 to 6 months of life. As a result, weaker reactions may occur with red cells of newborns than of adults.
- Confirmation of newborn's blood group is indicated when A & B antigen expression and the isoagglutinins are fully developed at 2 to 4 years of age & remains constant throughout life.
- Cord blood is contaminated with Wharton's jelly that causes red cell aggregation leading to false positive result
- The Hh blood group also known as Oh or Bombay blood group is rare blood group type. The term Bombay is used to refer the phenotype that lacks normal expression of ABH antigens because of inheritance of hh genotype.

References:

1. Denise M Harmening, Modern Blood Banking and Transfusion Practices- 6th Edition 2012. F.A. Davis company. Philadelphia
2. AABB technical manual

*Sample processed at SUBURBAN DIAGNOSTICS (INDIA) PVT. LTD SDRL, Vidyavihar Lab
*** End Of Report ***

Dr.VRUSHALI SHROFF
M.D.(PATH)
Pathologist





CID : 2308808565
Name : MR.MAHENDRA GANGARAM PAWAR
Age / Gender : 45 Years / Male
Consulting Dr. : -
Reg. Location : Borivali West (Main Centre)

Collected : 29-Mar-2023 / 08:07
Reported : 29-Mar-2023 / 15:05

Use a QR Code Scanner
Application To Scan the Code

MEDIWHEEL FULL BODY HEALTH CHECKUP MALE ABOVE 40/2D ECHO
LIPID PROFILE

PARAMETER	RESULTS	BIOLOGICAL REF RANGE	METHOD
CHOLESTEROL, Serum	182.7	Desirable: <200 mg/dl Borderline High: 200-239mg/dl High: >/=240 mg/dl	CHOD-POD
TRIGLYCERIDES, Serum	142.9	Normal: <150 mg/dl Borderline-high: 150 - 199 mg/dl High: 200 - 499 mg/dl Very high:>/=500 mg/dl	GPO-POD
HDL CHOLESTEROL, Serum	26.2	Desirable: >60 mg/dl Borderline: 40 - 60 mg/dl Low (High risk): <40 mg/dl	Homogeneous enzymatic colorimetric assay
NON HDL CHOLESTEROL, Serum	156.5	Desirable: <130 mg/dl Borderline-high:130 - 159 mg/dl High:160 - 189 mg/dl Very high: >/=190 mg/dl	Calculated
LDL CHOLESTEROL, Serum	128.0	Optimal: <100 mg/dl Near Optimal: 100 - 129 mg/dl Borderline High: 130 - 159 mg/dl High: 160 - 189 mg/dl Very High: >/= 190 mg/dl	Calculated
VLDL CHOLESTEROL, Serum	28.5	< /= 30 mg/dl	Calculated
CHOL / HDL CHOL RATIO, Serum	7.0	0-4.5 Ratio	Calculated
LDL CHOL / HDL CHOL RATIO, Serum	4.9	0-3.5 Ratio	Calculated

*Sample processed at SUBURBAN DIAGNOSTICS (INDIA) PVT. LTD Borivali Lab, Borivali West
*** End Of Report ***

Bmhaskar

Dr.KETAKI MHASKAR
M.D. (PATH)
Pathologist



MC-2111





CID : 2308808565
Name : MR.MAHENDRA GANGARAM PAWAR
Age / Gender : 45 Years / Male
Consulting Dr. : -
Reg. Location : Borivali West (Main Centre)

Use a QR Code Scanner
Application To Scan the Code
Collected : 29-Mar-2023 / 08:07
Reported : 29-Mar-2023 / 18:45

MEDIWHEEL FULL BODY HEALTH CHECKUP MALE ABOVE 40/2D ECHO
THYROID FUNCTION TESTS

<u>PARAMETER</u>	<u>RESULTS</u>	<u>BIOLOGICAL REF RANGE</u>	<u>METHOD</u>
Free T3, Serum	4.0	3.5-6.5 pmol/L	ECLIA
Free T4, Serum	14.9	11.5-22.7 pmol/L	ECLIA
sensitiveTSH, Serum	10.5	0.35-5.5 microIU/ml	ECLIA



CID : 2308808565
Name : MR.MAHENDRA GANGARAM PAWAR
Age / Gender : 45 Years / Male
Consulting Dr. : -
Reg. Location : Borivali West (Main Centre)

Use a QR Code Scanner Application To Scan the Code
Collected : 29-Mar-2023 / 08:07
Reported : 29-Mar-2023 / 18:45

Interpretation:

A thyroid panel is used to evaluate thyroid function and/or help diagnose various thyroid disorders.

Clinical Significance:

- 1)TSH Values between high abnormal upto15 microIU/ml should be correlated clinically or repeat the test with new sample as physiological factors can give falsely high TSH.
- 2)TSH values may be transiently altered because of non thyroidal illness like severe infections,liver disease, renal and heart severe burns, trauma and surgery etc.

TSH	FT4 / T4	FT3 / T3	Interpretation
High	Normal	Normal	Subclinical hypothyroidism, poor compliance with thyroxine, drugs like amiodarone, Recovery phase of non-thyroidal illness, TSH Resistance.
High	Low	Low	Hypothyroidism, Autoimmune thyroiditis, post radio iodine Rx, post thyroidectomy, Anti thyroid drugs, tyrosine kinase inhibitors & amiodarone, amyloid deposits in thyroid, thyroid tumors & congenital hypothyroidism.
Low	High	High	Hyperthyroidism, Graves disease, toxic multinodular goiter, toxic adenoma, excess iodine or thyroxine intake, pregnancy related (hyperemesis gravidarum, hydatiform mole)
Low	Normal	Normal	Subclinical Hyperthyroidism, recent Rx for Hyperthyroidism, drugs like steroids & dopamine), Non thyroidal illness.
Low	Low	Low	Central Hypothyroidism, Non Thyroidal Illness, Recent Rx for Hyperthyroidism.
High	High	High	Interfering anti TPO antibodies, Drug interference: Amiodarone, Heparin, Beta Blockers, steroids & anti epileptics.

Diurnal Variation:TSH follows a diurnal rhythm and is at maximum between 2 am and 4 am , and is at a minimum between 6 pm and 10 pm. The variation is on the order of 50 to 206%. Biological variation:19.7%(with in subject variation)

Reflex Tests:Anti thyroid Antibodies,USG Thyroid ,TSH receptor Antibody. Thyroglobulin, Calcitonin

Limitations:

1. Samples should not be taken from patients receiving therapy with high biotin doses (i.e. >5 mg/day) until atleast 8 hours following the last biotin administration.
2. Patient samples may contain heterophilic antibodies that could react in immunoassays to give falsely elevated or depressed results. this assay is designed to minimize interference from heterophilic antibodies.

Reference:

- 1.O.koulouri et al. / Best Practice and Research clinical Endocrinology and Metabolism 27(2013)
- 2.Interpretation of the thyroid function tests, Dayan et al. THE LANCET . Vol 357
- 3.Tietz ,Text Book of Clinical Chemistry and Molecular Biology -5th Edition
- 4.Biological Variation:From principles to Practice-Callum G Fraser (AACC Press)

*Sample processed at SUBURBAN DIAGNOSTICS (INDIA) PVT. LTD Borivali Lab, Borivali West

*** End Of Report ***

VIPUL JAIN

Dr.VIPUL JAIN
M.D. (PATH)
Pathologist



MC-2111





CID : 2308808565
Name : MR.MAHENDRA GANGARAM PAWAR
Age / Gender : 45 Years / Male
Consulting Dr. : -
Reg. Location : Borivali West (Main Centre)

Collected : 29-Mar-2023 / 08:07
Reported : 29-Mar-2023 / 15:05

Use a QR Code Scanner
Application To Scan the Code

**MEDIWHEEL FULL BODY HEALTH CHECKUP MALE ABOVE 40/2D ECHO
LIVER FUNCTION TESTS**

PARAMETER	RESULTS	BIOLOGICAL REF RANGE	METHOD
BILIRUBIN (TOTAL), Serum	0.53	0.1-1.2 mg/dl	Colorimetric
BILIRUBIN (DIRECT), Serum	0.20	0-0.3 mg/dl	Diazo
BILIRUBIN (INDIRECT), Serum	0.33	0.1-1.0 mg/dl	Calculated
TOTAL PROTEINS, Serum	7.0	6.4-8.3 g/dL	Biuret
ALBUMIN, Serum	4.7	3.5-5.2 g/dL	BCG
GLOBULIN, Serum	2.3	2.3-3.5 g/dL	Calculated
A/G RATIO, Serum	2.0	1 - 2	Calculated
SGOT (AST), Serum	24.7	5-40 U/L	NADH (w/o P-5-P)
SGPT (ALT), Serum	24.8	5-45 U/L	NADH (w/o P-5-P)
GAMMA GT, Serum	41.4	3-60 U/L	Enzymatic

*Sample processed at SUBURBAN DIAGNOSTICS (INDIA) PVT. LTD Borivali Lab, Borivali West
*** End Of Report ***

Bmhaskar

Dr.KETAKI MHASKAR
M.D. (PATH)
Pathologist



SUBURBAN DIAGNOSTICS - BORIVALI WEST

Patient Name: MAHENDRA GANGARAM PAWAR
Patient ID: 2308808565

Date and Time: 29th Mar 23 9:58 AM

Age **45** **11** **28**
years months days

Gender **Male**

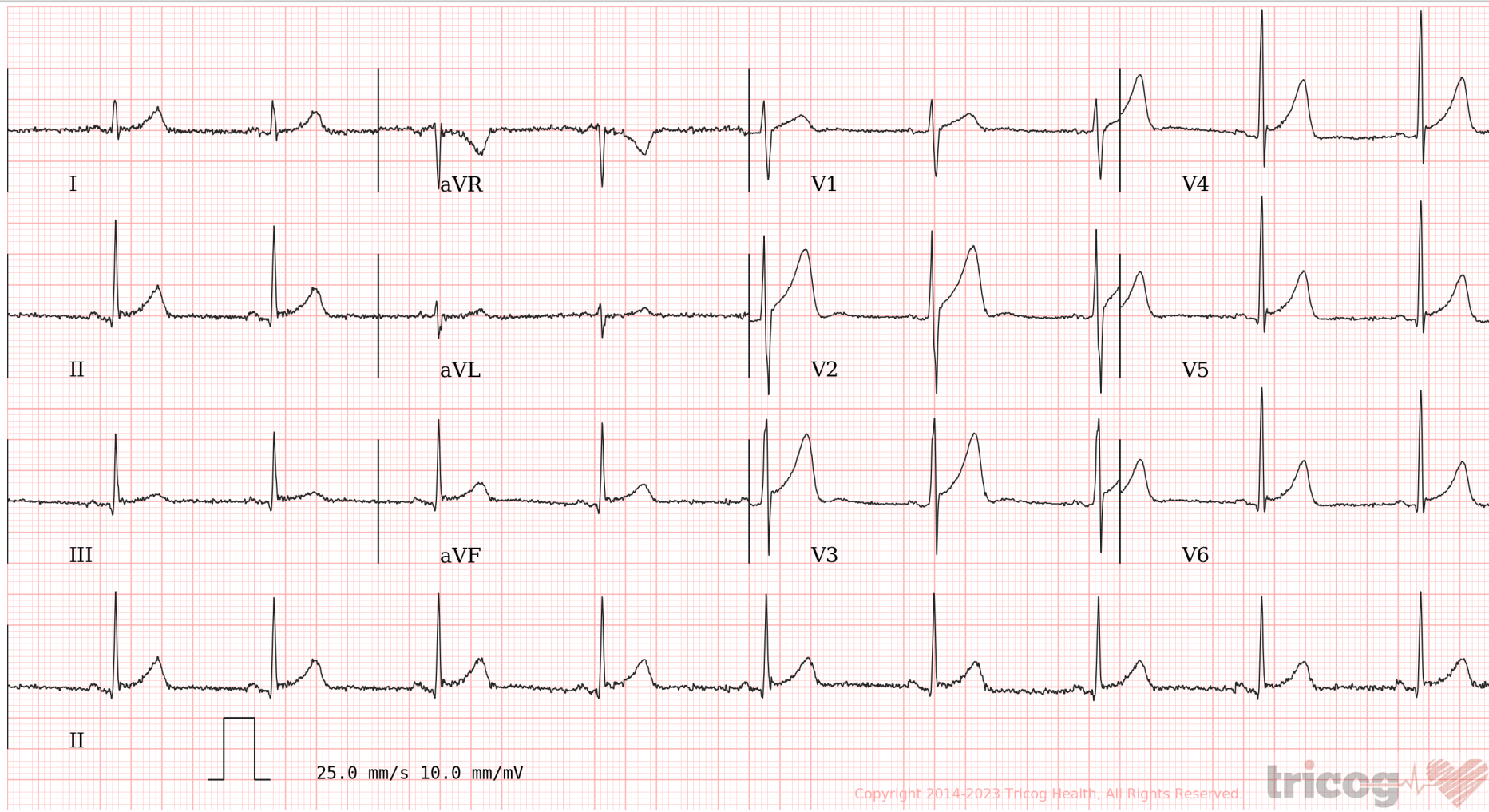
Heart Rate **57bpm**

Patient Vitals

BP: NA
Weight: NA
Height: NA
Pulse: NA
Spo2: NA
Resp: NA
Others: _____

Measurements

QRSD: 72ms
QT: 402ms
QTc: 391ms
PR: 142ms
P-R-T: 46° 73° 52°



Copyright 2014-2023 Tricog Health, All Rights Reserved.



ECG Within Normal Limits: Sinus Bradycardia, Early repolarization. Please correlate clinically.

REPORTED BY

Dr Nitin Sonavane
M.B.B.S.AFLH, D.DIAB,D.CARD
Consultant Cardiologist
87714

UE642424262IN



आपला आधार क्रमांक / Your Aadhaar No. :

4639 1092 9911

आधार – सामान्य माणसाचा अधिकार



भारत सरकार
GOVERNMENT OF INDIA



महेंद्र गंगाराम पवार
Mahendra Gangaram Pawar
जन्म वर्ष / Year of Birth : 1977
पुरुष / Male



4639 1092 9911

आधार – सामान्य माणसाचा अधिकार

Mypaw
29/03/23

Suburban Diagnostics (P) Pvt. Ltd.
301 & 302, 3rd Floor, V. K. Chavan
Above Tarisq Jeweller, Borivali (West), Mumbai - 400092.

CID# : 2308808565
Name : MR.MAHENDRA GANGARAM PAWAR
Age / Gender : 45 Years/Male
Consulting Dr. :
Reg.Location : Borivali West (Main Centre)
Collected : 29-Mar-2023 / 08:02
Reported : 29-Mar-2023 / 12:16

PHYSICAL EXAMINATION REPORT

History and Complaints:

NIL

EXAMINATION FINDINGS:

Height (cms):	169	Weight (kg):	65
Temp (0c):	Afebrile	Skin:	NAD
Blood Pressure (mm/hg):	120/80	Nails:	NAD
Pulse:	72/per min.	Lymph Node:	Not palpable

Systems

Cardiovascular: S1S2-NORMAL
Respiratory: CHEST CLEAR
Genitourinary: NAD
GI System: NAD
CNS:

IMPRESSION:

TSH
HDL ↓ | physician set

ADVICE:

CHIEF COMPLAINTS:

- | | |
|----------------------|----|
| 1) Hypertension: | NO |
| 2) IHD | NO |
| 3) Arrhythmia | NO |
| 4) Diabetes Mellitus | NO |
| 5) Tuberculosis | NO |

CID# : 2308808565

Name : MR.MAHENDRA GANGARAM PAWAR

Age / Gender : 45 Years/Male

Consulting Dr. :

Reg.Location : Borivali West (Main Centre)

Collected : 29-Mar-2023 / 08:02

Reported : 29-Mar-2023 / 12:16

- | | |
|--|----|
| 6) Asthama | NO |
| 7) Pulmonary Disease | NO |
| 8) Thyroid/ Endocrine disorders | NO |
| 9) Nervous disorders | NO |
| 10) GI system | NO |
| 11) Genital urinary disorder | NO |
| 12) Rheumatic joint diseases or symptoms | NO |
| 13) Blood disease or disorder | NO |
| 14) Cancer/lump growth/cyst | NO |
| 15) Congenital disease | NO |
| 16) Surgeries | NO |
| 17) Musculoskeletal System | NO |

PERSONAL HISTORY:

- | | |
|---------------|-----|
| 1) Alcohol | NO |
| 2) Smoking | NO |
| 3) Diet | MIX |
| 4) Medication | NO |

*** End Of Report ***

DR. NITIN SONAVANE Dr.NITIN SONAVANE
M.B.B.S.AFLH, D.DIAB, D.CARD. PHYSICIAN
CONSULTANT-CARDIOLOGIST
REGD. NO. : 87714

Suburban Diagnostics (I) Pvt. Ltd.
3018-3021 2nd Floor, Vini Elegance,
Above Taurus Jeweller, L. T. Road,
Borivali (West), Mumbai - 400 092.



CID : 2308808565
Name : Mr Mahendra Gangaram Pawar
Age / Sex : 45 Years/Male
Ref. Dr :
Reg. Location : Borivali West

Reg. Date : 29-Mar-2023
Reported : 29-Mar-2023 / 13:18

X-RAY CHEST PA VIEW

Both lung fields are clear.

Both costo-phrenic angles are clear.

The cardiac size and shape are within normal limits.

The domes of diaphragm are normal in position and outlines.

The skeleton under review appears normal.

IMPRESSION:

NO SIGNIFICANT ABNORMALITY IS DETECTED.

-----End of Report-----

DR.SUDHANSHU SAXENA
Consultant Radiologist
M.B.B.S DMRE (RadioDiagnosis)
RegNo .MMC 2016061376.

Click here to view images <http://3.111.232.119/iRISViewer/NeoradViewer?AccessionNo=2023032908031237>

CID NO: 2308808565	
PATIENT'S NAME: MR.MAHENDRA GANGARAM PAWAR	AGE/SEX: 45 Y/M
REF BY: -----	DATE: 29/03/2023

2-D ECHOCARDIOGRAPHY

1. RA, LA RV is Normal Size.
2. No LV Hypertrophy.
3. Normal LV systolic function. LVEF 60 % by bi-plane
4. No RWMA at rest.
5. Aortic, Pulmonary, Mitral, Tricuspid valves normal.
6. Great arteries: Aorta: Normal
 - a. No mitral valve prolaps.
7. Inter-ventricular septum is intact and normal.
8. Intra Atrial Septum intact.
9. Pulmonary vein, IVC, hepatic are normal.
- 10.No LV clot.
- 11.No Pericardial Effusion
- 12.No Diastolic disfunction. No Doppler evidence of raised LVEDP.


PATIENT'S NAME: MR.MAHENDRA GANGARAM PAWAR	AGE/SEX: 45 Y/M
REF BY: -----	DATE: 29/03/2023

1. AO root diameter	3.0 cm
2. IVSd	1.2 cm
3. LVIDd	4.1 cm
4. LVIDs	2.1 cm
5. LVPWd	1.2 cm
6. LA dimension	3.6 cm
7. RA dimension	3.7 cm
8. RV dimension	3.0 cm
9. Pulmonary flow vel:	0.9 m/s
10. Pulmonary Gradient	3.4 m/s
11. Tricuspid flow vel	1.6 m/s
12. Tricuspid Gradient	10 m/s
13. PASP by TR Jet	20 mm Hg
14. TAPSE	2.9 cm
15. Aortic flow vel	1.0 m/s
16. Aortic Gradient	4.0 m/s
17. MV:E	0.7 m/s
18. A vel	0.5 m/s
19. IVC	16 mm
20. E/E'	8

Impression:**Normal 2d echo study.****Disclaimer**

Echo may have inter/Intra observer variations in measurements as the study is observer dependent and changes with Pt's hemodynamics. Please co-relate findings with patients clinical status.

*****End of Report*****


DR. S. NITIN
Consultant Cardiologist
Reg. No. 87714



CID : 2308808565
Name : Mr Mahendra Gangaram Pawar
Age / Sex : 45 Years/Male
Ref. Dr :
Reg. Location : Borivali West

Reg. Date : 29-Mar-2023
Reported : 29-Mar-2023 / 11:47

USG WHOLE ABDOMEN

LIVER: Liver is normal in size, shape and echotexture. There is no intra-hepatic biliary radical dilatation. No evidence of any obvious focal lesion.

GALL BLADDER: Gall bladder is distended and appears normal. No obvious wall thickening is noted. There is no evidence of any calculus.

PORTAL VEIN: Portal vein is normal. **CBD:** CBD is normal.

PANCREAS: Pancreas appears normal in echotexture. There is no evidence of any focal lesion or calcification.

KIDNEYS: Right kidney measures 9.8 x 3.8 cm. Left kidney measures 10.6 x 5.2 cm. Both kidneys are normal in shape and echotexture. Corticomedullary differentiation is maintained. There is no evidence of any hydronephrosis, hydroureter or calculus.

SPLEEN: Spleen is normal in size, shape and echotexture. No focal lesion is seen.

URINARY BLADDER: Urinary bladder is distended and normal. Wall thickness is within normal limits.

PROSTATE: Prostate is normal in size and echotexture. Prostate measures 3.5 x 2.8 x 3.7 cm and prostatic weight is 20 gm. No evidence of any obvious focal lesion.

No free fluid or size significant lymphadenopathy is seen.

Click here to view images <http://3.111.232.119/iRISViewer/NeoradViewer?AccessionNo=2023032908031249>



CID : 2308808565
Name : Mr Mahendra Gangaram Pawar
Age / Sex : 45 Years/Male
Ref. Dr :
Reg. Location : Borivali West

Reg. Date : 29-Mar-2023
Reported : 29-Mar-2023 / 11:47

Opinion:

- No significant abnormality is detected.

For clinical correlation and follow up.

Investigations have their limitations. They only help in diagnosing the disease in correlation to clinical symptoms and other related tests. Please interpret accordingly.

-----End of Report-----

DR.SUDHANSHU SAXENA
Consultant Radiologist
M.B.B.S DMRE (RadioDiagnosis)
RegNo .MMC 2016061376.

Click here to view images <http://3.111.232.119/iRISViewer/NeoradViewer?AccessionNo=2023032908031249>

Date:- 29/03/2023

CID: 2308808565

Name:- Mahendra Gangara

Sex / Age: /

EYE CHECK UP

Chief complaints:

| Nil

Systemic Diseases:

Past history:

| Nil

Unaided Vision:

Aided Vision:

R/E

L/E

Refraction:

6/6

6/6

N12

N12

(Right Eye)

(Left Eye)

	Sph	Cyl	Axis	Vn	Sph	Cyl	Axis	Vn
Distance								
Near								

Colour Vision: Normal / Abnormal

Remark:

Normal
g

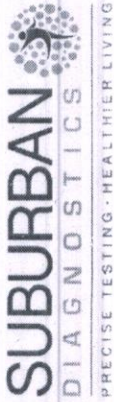Suburban Diagnostics (I) Pvt. Ltd.
301 to 302, 3rd Floor, Building Excellence,
Above Tanishq, Vigneshwari Road,
Borivali (West), Mumbai - 400 092.

SUBURBAN DIAGNOSTICS - BORIVALI WEST

Patient Name: MAHENDRA GANGARAM PAWAR

Date and Time: 29th Mar 23 9:58 AM

Patient ID: 2308808565



Age 45 years 11 months 28 days

Gender Male

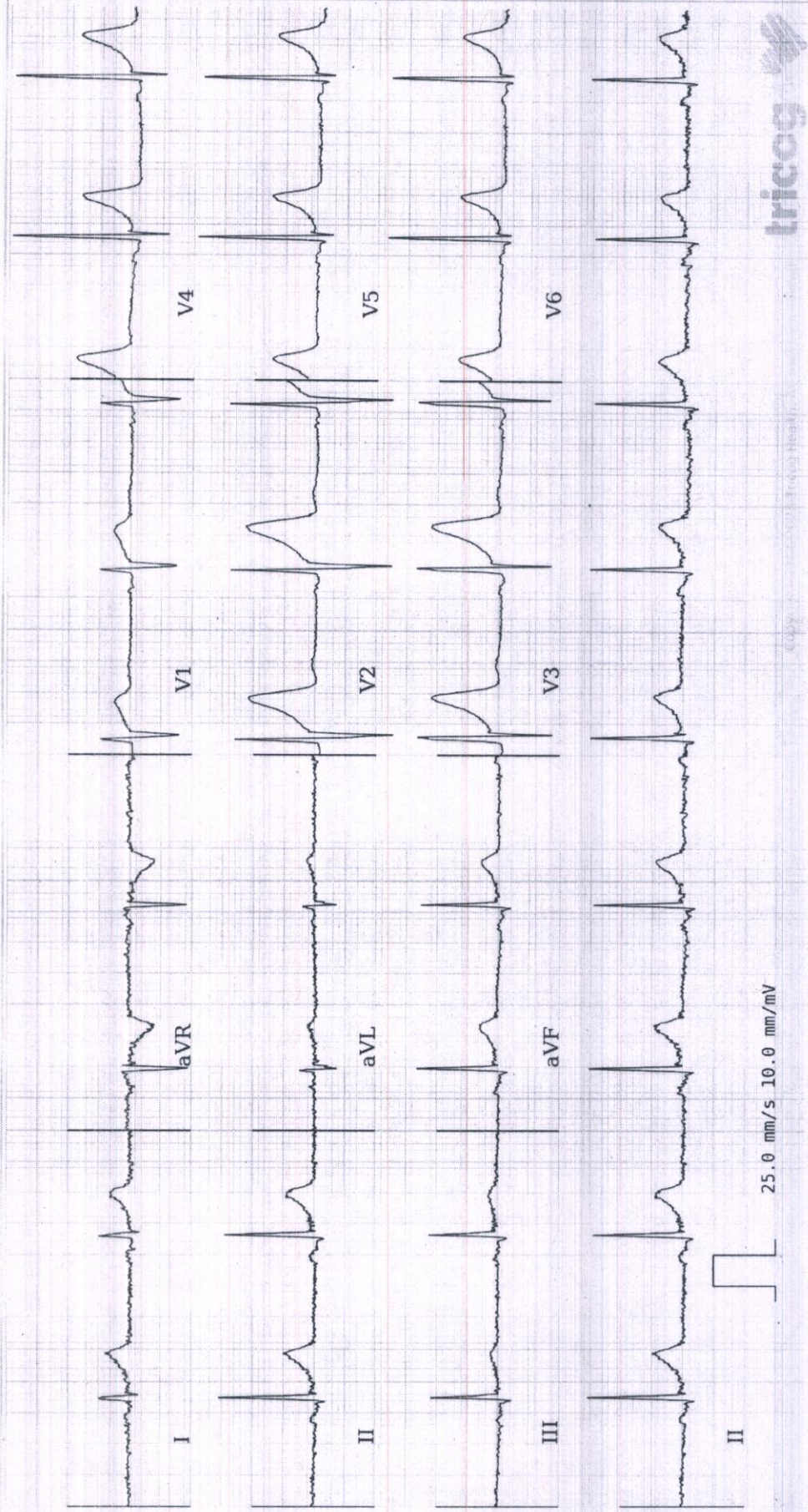
Heart Rate 57bpm

Patient Vitals

BP: NA
 Weight: NA
 Height: NA
 Pulse: NA
 Spo2: NA
 Resp: NA
 Others:

Measurements

QRSD: 72ms
 QT: 402ms
 QTc: 391ms
 PR: 142ms
 P-R-T: 46° 73° 52°



ECG Within Normal Limits: Sinus Bradycardia, Early repolarization. Please correlate clinically.

REPORTED BY

[Signature]

Dr Nitin Sonawane
 M.B.B.S., F.I.C.C., D.D.IAB, D.C.A.R.D.
 Consultant Cardiologist
 87114

Disclaimer: All Analyses in this report are based on the data provided above and should be used as an adjunct to clinical history, symptoms, and results of other imaging and laboratory tests. These analyses and results must be interpreted by a qualified physician. All other reports are the property of the company and are not to be distributed outside the company.

UE642424262IN



आपला आधार क्रमांक / Your Aadhaar No. :

4639 1092 9911

आधार – सामान्य माणसाचा अधिकार



भारत सरकार
GOVERNMENT OF INDIA

महेंद्र गंगाराम पवार
Mahendra Gangaram Pawar
जन्म वर्ष / Year of Birth : 1977
पुरुष / Male



4639 1092 9911

आधार – सामान्य माणसाचा अधिकार

Mypaw
29/03/23

Suburban Diagnostics (P) Pvt. Ltd.
301 & 302, 3rd Floor, V. K. Chavan
Above Tarisq Jeweller, Borivali (West), Mumbai - 400092.

CID# : 2308808565
Name : MR.MAHENDRA GANGARAM PAWAR
Age / Gender : 45 Years/Male
Consulting Dr. :
Reg.Location : Borivali West (Main Centre)
Collected : 29-Mar-2023 / 08:02
Reported : 29-Mar-2023 / 12:16

PHYSICAL EXAMINATION REPORT

History and Complaints:

NIL

EXAMINATION FINDINGS:

Height (cms):	169	Weight (kg):	65
Temp (0c):	Afebrile	Skin:	NAD
Blood Pressure (mm/hg):	120/80	Nails:	NAD
Pulse:	72/per min.	Lymph Node:	Not palpable

Systems

Cardiovascular: S1S2-NORMAL
Respiratory: CHEST CLEAR
Genitourinary: NAD
GI System: NAD
CNS:

IMPRESSION:

TSH
HDL ↓ | physician set

ADVICE:

CHIEF COMPLAINTS:

- | | |
|----------------------|----|
| 1) Hypertension: | NO |
| 2) IHD | NO |
| 3) Arrhythmia | NO |
| 4) Diabetes Mellitus | NO |
| 5) Tuberculosis | NO |

CID# : 2308808565

Name : MR.MAHENDRA GANGARAM PAWAR

Age / Gender : 45 Years/Male

Consulting Dr. :

Reg.Location : Borivali West (Main Centre)

Collected : 29-Mar-2023 / 08:02

Reported : 29-Mar-2023 / 12:16

- | | |
|--|----|
| 6) Asthama | NO |
| 7) Pulmonary Disease | NO |
| 8) Thyroid/ Endocrine disorders | NO |
| 9) Nervous disorders | NO |
| 10) GI system | NO |
| 11) Genital urinary disorder | NO |
| 12) Rheumatic joint diseases or symptoms | NO |
| 13) Blood disease or disorder | NO |
| 14) Cancer/lump growth/cyst | NO |
| 15) Congenital disease | NO |
| 16) Surgeries | NO |
| 17) Musculoskeletal System | NO |

PERSONAL HISTORY:

- | | |
|---------------|-----|
| 1) Alcohol | NO |
| 2) Smoking | NO |
| 3) Diet | MIX |
| 4) Medication | NO |

*** End Of Report ***

DR. NITIN SONAVANE Dr.NITIN SONAVANE
M.B.B.S.AFLH, D.DIAB, D.CARD. PHYSICIAN
CONSULTANT-CARDIOLOGIST
REGD. NO. : 87714

Suburban Diagnostics (I) Pvt. Ltd.
3018-3021 2nd Floor, Vini Elegance,
Above Taurus Jeweller, L. T. Road,
Borivali (West), Mumbai - 400 092.



CID : 2308808565
Name : Mr Mahendra Gangaram Pawar
Age / Sex : 45 Years/Male
Ref. Dr :
Reg. Location : Borivali West

Reg. Date : 29-Mar-2023
Reported : 29-Mar-2023 / 13:18

X-RAY CHEST PA VIEW

Both lung fields are clear.

Both costo-phrenic angles are clear.

The cardiac size and shape are within normal limits.

The domes of diaphragm are normal in position and outlines.

The skeleton under review appears normal.

IMPRESSION:

NO SIGNIFICANT ABNORMALITY IS DETECTED.

-----End of Report-----

DR.SUDHANSHU SAXENA
Consultant Radiologist
M.B.B.S DMRE (RadioDiagnosis)
RegNo .MMC 2016061376.

Click here to view images <http://3.111.232.119/iRISViewer/NeoradViewer?AccessionNo=2023032908031237>

CID NO: 2308808565	
PATIENT'S NAME: MR.MAHENDRA GANGARAM PAWAR	AGE/SEX: 45 Y/M
REF BY: -----	DATE: 29/03/2023

2-D ECHOCARDIOGRAPHY

1. RA, LA RV is Normal Size.
2. No LV Hypertrophy.
3. Normal LV systolic function. LVEF 60 % by bi-plane
4. No RWMA at rest.
5. Aortic, Pulmonary, Mitral, Tricuspid valves normal.
6. Great arteries: Aorta: Normal
 - a. No mitral valve prolaps.
7. Inter-ventricular septum is intact and normal.
8. Intra Atrial Septum intact.
9. Pulmonary vein, IVC, hepatic are normal.
- 10.No LV clot.
- 11.No Pericardial Effusion
- 12.No Diastolic disfunction. No Doppler evidence of raised LVEDP.

PATIENT'S NAME: MR.MAHENDRA GANGARAM PAWAR	AGE/SEX: 45 Y/M
REF BY: -----	DATE: 29/03/2023

1. AO root diameter	3.0 cm
2. IVSd	1.2 cm
3. LVIDd	4.1 cm
4. LVIDs	2.1 cm
5. LVPWd	1.2 cm
6. LA dimension	3.6 cm
7. RA dimension	3.7 cm
8. RV dimension	3.0 cm
9. Pulmonary flow vel:	0.9 m/s
10. Pulmonary Gradient	3.4 m/s
11. Tricuspid flow vel	1.6 m/s
12. Tricuspid Gradient	10 m/s
13. PASP by TR Jet	20 mm Hg
14. TAPSE	2.9 cm
15. Aortic flow vel	1.0 m/s
16. Aortic Gradient	4.0 m/s
17. MV:E	0.7 m/s
18. A vel	0.5 m/s
19. IVC	16 mm
20. E/E'	8

Impression:**Normal 2d echo study.****Disclaimer**

Echo may have inter/Intra observer variations in measurements as the study is observer dependent and changes with Pt's hemodynamics. Please co-relate findings with patients clinical status.

*****End of Report*****

DR. S. NITIN
Consultant Cardiologist
Reg. No. 87714



CID : 2308808565
Name : Mr Mahendra Gangaram Pawar
Age / Sex : 45 Years/Male
Ref. Dr :
Reg. Location : Borivali West

Reg. Date : 29-Mar-2023
Reported : 29-Mar-2023 / 11:47

USG WHOLE ABDOMEN

LIVER: Liver is normal in size, shape and echotexture. There is no intra-hepatic biliary radical dilatation. No evidence of any obvious focal lesion.

GALL BLADDER: Gall bladder is distended and appears normal. No obvious wall thickening is noted. There is no evidence of any calculus.

PORTAL VEIN: Portal vein is normal. **CBD:** CBD is normal.

PANCREAS: Pancreas appears normal in echotexture. There is no evidence of any focal lesion or calcification.

KIDNEYS: Right kidney measures 9.8 x 3.8 cm. Left kidney measures 10.6 x 5.2 cm. Both kidneys are normal in shape and echotexture. Corticomedullary differentiation is maintained. There is no evidence of any hydronephrosis, hydroureter or calculus.

SPLEEN: Spleen is normal in size, shape and echotexture. No focal lesion is seen.

URINARY BLADDER: Urinary bladder is distended and normal. Wall thickness is within normal limits.

PROSTATE: Prostate is normal in size and echotexture. Prostate measures 3.5 x 2.8 x 3.7 cm and prostatic weight is 20 gm. No evidence of any obvious focal lesion.

No free fluid or size significant lymphadenopathy is seen.

Click here to view images <http://3.111.232.119/iRISViewer/NeoradViewer?AccessionNo=2023032908031249>



CID : 2308808565
Name : Mr Mahendra Gangaram Pawar
Age / Sex : 45 Years/Male
Ref. Dr :
Reg. Location : Borivali West

Reg. Date : 29-Mar-2023
Reported : 29-Mar-2023 / 11:47

Opinion:

- No significant abnormality is detected.

For clinical correlation and follow up.

Investigations have their limitations. They only help in diagnosing the disease in correlation to clinical symptoms and other related tests. Please interpret accordingly.

-----End of Report-----

DR.SUDHANSHU SAXENA
Consultant Radiologist
M.B.B.S DMRE (RadioDiagnosis)
RegNo .MMC 2016061376.

Click here to view images <http://3.111.232.119/iRISViewer/NeoradViewer?AccessionNo=2023032908031249>

Date:- 29/03/2023

CID: 2308808565

Name:- Mahendra Gangara

Sex / Age: /

EYE CHECK UP

Chief complaints: Nil

Systemic Diseases:

Past history: Nil

Unaided Vision:

Aided Vision:
Refraction: R/E
 6/6
 N12

L/E
6/6
N12

(Right Eye)

(Left Eye)

	Sph	Cyl	Axis	Vn	Sph	Cyl	Axis	Vn
Distance								
Near								

Colour Vision: Normal / Abnormal

Remark: Normal

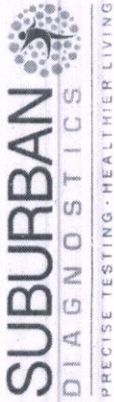
Suburban Diagnostics (I) Pvt. Ltd.
301 & 302, 3rd Floor, Building Excellence,
Above Tanishq, Vashi Road,
Borivali (West), Mumbai - 400 092.

SUBURBAN DIAGNOSTICS - BORIVALI WEST

Patient Name: MAHENDRA GANGARAM PAWAR

Date and Time: 29th Mar 23 9:58 AM

Patient ID: 2308808565



Age 45 years 11 months 28 days

Gender Male

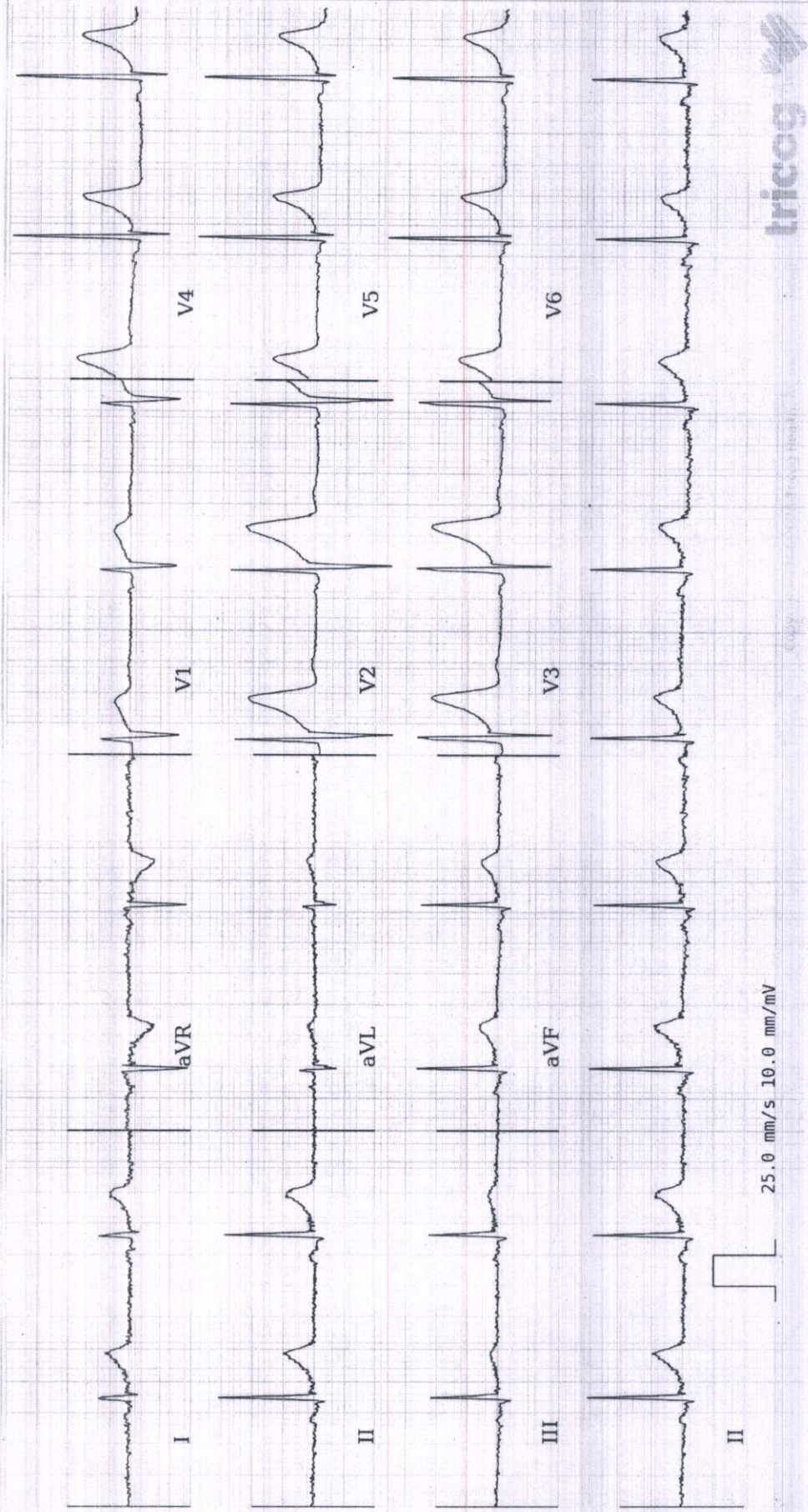
Heart Rate 57bpm

Patient Vitals

BP: NA
 Weight: NA
 Height: NA
 Pulse: NA
 Spo2: NA
 Resp: NA
 Others:

Measurements

QRSD: 72ms
 QT: 402ms
 QTc: 391ms
 PR: 142ms
 P-R-T: 46° 73° 52°



ECG Within Normal Limits: Sinus Bradycardia, Early repolarization. Please correlate clinically.

REPORTED BY

[Signature]

Dr Nitin Sonawane
 M.B.B.S., F.I.C.C., D.D.IAB, D.C.A.R.D.
 Consultant Cardiologist
 87114

Disclaimer: All Analyses in this report are based on the ECG alone and should be used in conjunction with clinical history, symptoms, and results of other imaging and laboratory tests. ECGs and other data must be interpreted by a qualified physician. All other data are for informational purposes only and should not be used for clinical decision making.



CID : 2308808565
Name : Mr Mahendra Gangaram Pawar
Age / Sex : 45 Years/Male
Ref. Dr :
Reg. Location : Borivali West

Reg. Date : 29-Mar-2023
Reported : 29-Mar-2023/13:18

X-RAY CHEST PA VIEW

Both lung fields are clear.

Both costo-phrenic angles are clear.

The cardiac size and shape are within normal limits.

The domes of diaphragm are normal in position and outlines.

The skeleton under review appears normal.

IMPRESSION:

NO SIGNIFICANT ABNORMALITY IS DETECTED.

-----End of Report-----

DR.SUDHANSHU SAXENA
Consultant Radiologist
M.B.B.S DMRE (RadioDiagnosis)
RegNo .MMC 2016061376.



Use a QR Code Scanner
Application To Scan the Code

CID : 2308808565
Name : Mr Mahendra Gangaram Pawar
Age / Sex : 45 Years/Male
Ref. Dr :
Reg. Location : Borivali West

Reg. Date : 29-Mar-2023
Reported : 29-Mar-2023/13:18