

# REVIVAL DIAGNOSTICS



## HEALTH CHECK-UP SUMMARY

Name: Ayush Singh

Date: 10/12/2022

Email ID:

Sex: M      Age: 33 Years      Contact No: 9662080403      Remarks:

Under-weight	<u>-</u>
Normal	<u>-</u>
Over-weight	<u>✓</u>

i> BMI

Height (in Cm): <u>181</u>	Weight (in Kg): <u>88</u>	BMI: <u>26.9</u>
----------------------------	---------------------------	------------------

ii> Blood Pressure & Pulse

114/74 mmHg  
78 /min.

If high or low, whether the person is on medication: YES / NO

iii> Blood Tests & Lung Function Remarks

RS  
CVC  
CNS } ⊙

If abnormal, whether the person is on medication: YES / NO

iv> Eye Test Remarks

Eye Test: ⊙ 6/6      ⊙ 6/6 - with specs.  
Color Vision: ⊙

v> Heart Disease

Whether any specific heart ailment detected (ECG findings):  
normal

vi> Any other problems needing attention / Overall Assessment:

DM - last 5 years.

**Dr. Chirag Patel**  
M.B.B.S. G-49432

Signature of the Doctor

**Revival Diagnostic**

401, Aqua Corridor,  
B/s. Star Bazar. Surat-395009  
No. 91062 2001

Laboratory Test Result are Subject to technical limitation and should be clinically correlate for final diagnosis

4th Floor, Aqua Corridor, Hazira Road, Adajan Paal, Surat-395009.

0261 2747788

revivaldiagnostics.surat@gmail.com

www.revivaldiagnostics.com

This medical report is not intended for medico-legal purposes.



NAME: Ayubh Singh SEX: M  
BIRTHDATE: 29/11/1989 AGE: 33

## DEPARTMENT OF OPHTHALMOLOGY

### EYE TEST:

#### 1. VISION:

RIGHT EYE - 6/6  
LEFT EYE - 6/6 } with specs.

#### 2. COLOR VISION:

RIGHT EYE - (2)  
LEFT EYE - (2)

#### 3. FUNDUS:

RIGHT EYE - (2)  
LEFT EYE - (2)

### REMARKS:

*(Handwritten signature)*

**Revival Diagnostic**

401, Aqua Corridor,  
B/s. Star Bazar, Surat-395009  
Mo. 91062-28601

**Ophthalmologist/Optomtrist**

Laboratory Test Result are Subject to technical limitation and should be clinically correlate for final diagnosis



## Dental Assessment Form

NAME

Ayush Singh

DATE

10/12/2022

AGE

33

SEX

M

### \* CHIEF COMPLAINT

A CLINICAL FEATURES :- normal

1 CAVIES :-

2 MISSING TOOTH :-

3 MALOCCLUSION :-

4 FILLING :-

} ⊙

B DIAGNOSIS :- normal

C PERSONAL HISTORY :- Hygienic

D PROVISIONAL D/G :- ⊙

E MEDICAL HISTORY :- NO

F FINAL D/G :- ⊙

G TREATMENT PLAN :- NO

CLINT SIGN

**Revival Diagnostic**

401 Aqua Corridor,  
DOCTOR SIGN B/s. Star Bar, Surat-395009  
Mo. 91062-28601

Laboratory Test Result are Subject to technical limitation and should be clinically correlate for final diagnosis

4th Floor, Aqua Corridor, Hazira Road, Adajan Pal, Surat-395009.

0261 2747788, 9825947712 revivaldiagnostics.surat@gmail.com www.revivaldiagnostics.com

This medical report is not intended for medico-legal purposes.



Name	<b>AYUSH SINGH</b>	Age/Gender	<b>33Yrs/Male</b>
Reg No.	<b>3887/22</b>	Receipt No	<b>3587</b>
Referred By	<b>BOB - MEDI WHEEL(PKG10000240)</b>	Mode of Payment	<b>CREDIT</b>
Collection Type	<b>CENTER</b>	Collection DateTime	<b>10-Dec-2022 08:41 AM</b>

**BLOOD GROUP** - 10122241 Released at 10-Dec-2022 11:20 AM

Parameter	Result	Biological Ref.Range	Method
-Blood Group	"O"		
-Rh Factor	POSITIVE		

**CBC** - 10122239 Released at 10-Dec-2022 12:09 PM

Parameter	Result	Biological Ref.Range	Method
-Haemoglobin	16.1 gm/dL	(13.5 - 18 gm/dL)	Auto
-RBC Count	6.20 mill/cumm	(4.6 - 6.2 mill/cumm)	Auto
-Total WBC Count	9000 /cumm	(4000 - 10000 /cumm)	Auto
-Platelet Count	2.36 lakh/cumm	(1.5 - 4.5 lakh/cumm)	Auto

**Blood Indices**

-HCT	51.6 %	(40 - 55 %)	Auto
-MCV	83.2 fl	(80 - 92 fl)	Auto
-MCH	<b>26.0 pg</b>	<b>L (27 - 31 pg)</b>	Auto
-MCHC	<b>31.3 gm/dL</b>	<b>L (32 - 36 gm/dL)</b>	Auto
-RDW	14.9 %	(11 - 15 %)	Auto

**Diff WBC Count**

-Polymorphs	70 %	(40 - 80 %)	Microscopiclly
-Lymphocytes	25 %	(20 - 40 %)	Microscopiclly
-Eosinophils	03 %	(1 - 6 %)	Microscopiclly
-Monocytes	02 %	(2 - 7 %)	Microscopiclly
-Basophils	00 %	(0 - 1 %)	Microscopiclly
-PLATELET ON SMEAR	Adequate		Microscopiclly
-MALARIAL PARASITES	Malarial Parasites Not Detected		Microscopiclly

[Test performed on Fully Automated Hematology Analyzer ERBA H-360]

**Revival Diagnostics**  
401-Aqua Corridor,  
Beside Star Bazar, Adajan,  
Surat-395009. Mo. 9825947712

Dr. Shivangi Gandhi  
M.B.B.S, M.D (Pathology)

Laboratory Test Result are Subject to technical limitation and should be clinically correlate for final diagnosis

📍 4th Floor, Aqua Corridor, Hazira Road, Adajan Pal, Surat-395009.

☎ 0261 2747788, 9825947712 ✉ revivaldiagnostics.surat@gmail.com 🌐 www.revivaldiagnostics.com

This medical report is not intended for medico-legal purposes.

# REVIVAL DIAGNOSTICS



Name	<b>AYUSH SINGH</b>	Age/Gender	<b>33Yrs/Male</b>
Reg No.	<b>3887/22</b>	Receipt No	<b>3587</b>
Referred By	<b>BOB - MEDI WHEEL(PKG10000240)</b>	Mode of Payment	<b>CREDIT</b>
Collection Type	<b>CENTER</b>	Collection DateTime	<b>10-Dec-2022 08:41 AM</b>

**ESR** - 10122239 Released at 10-Dec-2022 11:27 AM

Parameter	Result	Biological Ref.Range	Method
-E.S.R	02 mm/hr	(1 - 10 mm/hr)	



## Revival Diagnostics

401-Aqua Corridor,  
Beside Star Bazar, Adajan,  
Surat-395009. Mo. 9825947712

Dr. Shivangi Gandhi  
M.B.B.S, M.D (Pathology)

Laboratory Test Result are Subject to technical limitation and should be clinically correlate for final diagnosis

4th Floor, Aqua Corridor, Hazira Road, Adajan Pal, Surat-395009.

0261 2747788, 9825947712 revivaldiagnostics.surat@gmail.com www.revivaldiagnostics.com

This medical report is not intended for medico-legal purposes.



Name	<b>AYUSH SINGH</b>	Age/Gender	<b>33Yrs/Male</b>
Reg No.	<b>3887/22</b>	Receipt No	<b>3587</b>
Referred By	<b>BOB - MEDI WHEEL(PKG10000240)</b>	Mode of Payment	<b>CREDIT</b>
Collection Type	<b>CENTER</b>	Collection DateTime	<b>10-Dec-2022 08:41 AM</b>

**FBS & PPBS** - 10122240 Released at 10-Dec-2022 02:27 PM

Parameter	Result	Biological Ref.Range	Method
-Fasting Blood Sugar (FBS)	98 mg/dL	70-100 mg/dl Impaired Tolerance:100-125 Diabetes Mellitus:>=126 (On more than one occasion) (American diabetes association guidelines 2022)	
-Fasting Urine Sugar	Absent		
-Fasting Urine Acetone	Absent		
-PPBS	120 mg/dL	(90 - 140 mg/dL)	
-PP2BS URINE SUGAR	Absent		
-PP2BS URINE ACETONE	Absent		

**HBA1C** - 10122239 Released at 10-Dec-2022 01:23 PM

Parameter	Result	Biological Ref.Range	Method
-HBA1C	5.5 %	HbA1C Degree of Glucose Control <5.6 % Non Diabetics 5.7 - 6.4 % Prediabetics > =6.5 % Diabetics (REF:Wallace, 11th Edition ) REMARKS: 6 - 7 % Excellent Control 7 - 8 % Good Control 8 - 10 % Unsatisfactory Control >10 % Poor Control	Boronate Affinity
-Method[]	High Performance Liquid Chromatography (HPLC)		

## Revival Diagnostics

401-Aqua Corridor,  
Beside Star Bazar, Adajan,  
Surat-395009. Mo. 9825947712  
Dr. Shivangi Gandhi  
M.B.B.S, M.D (Pathology)

Laboratory Test Result are Subject to technical limitation and should be clinically correlate for final diagnosis



Name	<b>AYUSH SINGH</b>	Age/Gender	<b>33Yrs/Male</b>
Reg No.	<b>3887/22</b>	Receipt No	<b>3587</b>
Referred By	<b>BOB - MEDI WHEEL(PKG1000240)</b>	Mode of Payment	<b>CREDIT</b>
Collection Type	<b>CENTER</b>	Collection DateTime	<b>10-Dec-2022 08:41 AM</b>

**Lipid Profile** - 10122241 Released at 10-Dec-2022 12:51 PM

Parameter	Result	Biological Ref.Range	Method
-Serum Cholesterol	214 mg/dL	Desirable < 200 mg/dl Borderline High : 200-239 mg/dl High : > 240 mg/dl	CHOD-PAP
-Serum Triglyceride	109 mg/dL	Normal < 150 mg/dl Borderline High : 150 - 159 mg/dl High : 200 - 499 mg/dl Very High : 500 mg/dl	GPO-POD Method
-Serum HDLD(Direct)	46 mg/dL	Normal :> 55 mg/dl Borderline : 35-55 mg/dl Undesirable: < 35 mg/dl	PVS-PEGME CHOD-POD Precipitation with
-Serum VLDL	22 mg/dL	(5 - 30 mg/dL)	Calculated
-Serum LDL(Direct)	146 mg/dL	Optimal:< 100 mg/dl Above Optimal : 100- 129 mg/dl Borderline High : 130-159 mg/dl High : > 160-189mg/dl Very High : >190 mg/dl	Calculated
-Chol/HDL	4.65	Low risk: <3.8 Medium Risk: 3.8 to 5.9 High Risk: > 6	Calculated
-LDL/Chol	1.46	Low risk: <3.55 Medium Risk: 3.55 to 4.0 High Risk: > 6	Calculated

[Test performed on Fully Automated Biochemistry Analyzer ERBA EM200]

**Revival Diagnostics**

401-Aqua Corridor,  
Beside Star Bazar, Adajan,  
Surat-395009. Mo. 9825947712

Dr. Shivangi Gandhi  
M.B.B.S, M.D (Pathology)

Laboratory Test Result are Subject to technical limitation and should be clinically correlate for final diagnosis

4th Floor, Aqua Corridor, Hazira Road, Adajan Pal, Surat-395009.

0261 2747788, 9825947712 revivaldiagnostics.surat@gmail.com www.revivaldiagnostics.com

This medical report is not intended for medico-legal purposes.



Name	AYUSH SINGH	Age/Gender	33Yrs/Male
Reg No.	3887/22	Receipt No	3587
Referred By	BOB - MEDI WHEEL(PKG10000240)	Mode of Payment	CREDIT
Collection Type	CENTER	Collection DateTime	10-Dec-2022 08:41 AM

### LIVER FUNCTION TEST (LFT) - 10122241 Released at 10-Dec-2022 12:50 PM

Parameter	Result	Biological Ref.Range	Method
-Serum Total Bilirubin	0.5 mg/dL	(0 - 1.3 mg/dL)	Diazo
-Serum Direct Bilirubin	0.2 mg/dL	(0 - 0.4 mg/dL)	Diazo
-Serum InDirect Bilirubin	0.3 mg/dL	(0.1 - 1.3 mg/dL)	Calculated
-Total Protein (TP)	6.4 gm/dL	(6.4 - 8.3 gm/dL)	Biuret
-Albumin (ALB)	3.5 gm/dL	(3.5 - 5.2 gm/dL)	BCG
-Globulin	2.9 gm/dL	(2.3 - 3.6 gm/dL)	Calculated
-A/G Ratio	1.21 gm/dL	(1 - 2.3 gm/dL)	Calculated
-SGPT(ALT)	28 U/L	(5 - 45 U/L)	IFCC, Kinetic Phosphate without Pyridoxal
-SGOT (AST)	21 U/L	(0 - 35 U/L)	IFCC, Without Pyridoxal Phosphate
-Alkaline Phosph.	82 U/L	(42 - 128 U/L)	ALP-AMP : P
-GGT	24 U/L	(5 - 50 U/L)	Glupa-C

[Test performed on Fully Automated Biochemistry Analyzer ERBA EM200]



## Revival Diagnostics

401-Aqua Corridor,  
Beside Star Bazar, Adajan,  
Surat-395009. Mo. 9825947712

Dr. Shivangi Gandhi  
M.B.B.S, M.D (Pathology)

Laboratory Test Result are Subject to technical limitation and should be clinically correlate for final diagnosis





Name	AYUSH SINGH	Age/Gender	33Yrs/Male
Reg No.	3887/22	Receipt No	3587
Referred By	BOB - MEDI WHEEL(PKG10000240)	Mode of Payment	CREDIT
Collection Type	CENTER	Collection DateTime	10-Dec-2022 08:41 AM

**Creatinine** - 10122241 Released at 10-Dec-2022 12:50 PM

Parameter	Result	Biological Ref.Range	Method
-Creatinine	1.1 mg/dL	(0.6 - 1.4 mg/dL)	ENZYMATIC

**BUN** - 10122241 Released at 10-Dec-2022 12:50 PM

Parameter	Result	Biological Ref.Range	Method
-Blood Urea Nitrogen (BUN)	14 mg/dL	(6 - 20 mg/dL)	Calculated

**Uric Acid** - 10122238 Released at 10-Dec-2022 12:50 PM

Parameter	Result	Biological Ref.Range	Method
-Uric Acid	6.7 mg/dL	(3.5 - 7.2 mg/dL)	Uricase-POD

**Revival Diagnostics**  
401-Aqua Corridor,  
Beside Star Bazar, Adajan,  
Surat-395009. Mo. 9825947712

Dr. Shivangi Gandhi  
M.B.B.S, M.D (Pathology)

Laboratory Test Result are Subject to technical limitation and should be clinically correlate for final diagnosis



Name	<b>AYUSH SINGH</b>	Age/Gender	<b>33Yrs/Male</b>
Reg No.	<b>3887/22</b>	Receipt No	<b>3587</b>
Referred By	<b>BOB - MEDI WHEEL(PKG10000240)</b>	Mode of Payment	<b>CREDIT</b>
Collection Type	<b>CENTER</b>	Collection DateTime	<b>10-Dec-2022 08:41 AM</b>

**Total T3 T4 TSH** - 10122241 Released at 10-Dec-2022 01:51 PM

Parameter	Result	Biological Ref.Range	Method
-Total T3	1.01 ng/ml	(0.87 - 1.78 ng/ml)	Fluorescence Immunoassay Enzyme
-Total T4	5.91 ug/dl	(4.6 - 11 ug/dl)	Fluorescence Immunoassay Enzyme
-TSH	2.02 uIU/ml	0.50 - 5.50 uIU/ml 5.5 to 15 ul U/ml - Suggested Clinical co-relation or Repeat test with new sample as physiological factors can give falsely high TSH Above 15uIU/ml Hypothyroid PREGNANT WOMEN normal ranges for TSH: 1st Trimester : 0.0878 - 2.8293 uIU/ml 2nd Trimester : 0.1998 - 2.7915 uIU/ml 3rd Trimester : 0.307 - 2.9028 uIU/ml Ref: TIETZ Fundamentals of Clinical Chemistry	Fluorescence Immunoassay Enzyme

[Test performed on Fully Automated Immunology Analyzer Maglumi-600]

**Revival Diagnostics**  
401-Aqua Corridor,  
Beside Star Bazar, Adajan,  
Surat-395009. Mo. 9825947712

Dr. Shivangi Gandhi  
M.B.B.S, M.D (Pathology)

Laboratory Test Result are Subject to technical limitation and should be clinically correlate for final diagnosis



Name	<b>AYUSH SINGH</b>	Age/Gender	<b>33Yrs/Male</b>
Reg No.	<b>3887/22</b>	Receipt No	<b>3587</b>
Referred By	<b>BOB - MEDI WHEEL(PKG10000240)</b>	Mode of Payment	<b>CREDIT</b>
Collection Type	<b>CENTER</b>	Collection DateTime	<b>10-Dec-2022 08:41 AM</b>

**Urine Routine & Micro Examination** - 10122243 Released at 10-Dec-2022 02:27 PM

Parameter	Result	Biological Ref.Range	Method:
<b>Physical Examination</b>			
-Quantity	20		Manual
-Colour	Pale Yellow	Pale Yellow	Manual
-Appearance	Clear	Clear	Manual
-Reaction (pH)	Acidic		Dipstick
-Specific Gravity	1.020		Dipstick
<b>Chemical Examination</b>			
-Proteins.	Absent		Dipstick
-Sugar	Absent		Dipstick
-Acetone.	Absent		Dipstick
-Bile Salts	Absent	Absent	Dipstick
-Bile Pigments	Absent	Absent	Dipstick
-Occult Blood Test (OBT).	Negative		Dipstick
<b>Microscopic Examination</b>			
-Pus Cells	Occasional		Microscopically
-Red Blood Cells	Absent		Microscopically
-Epithelial Cells	1-2		Microscopically
-Bacteria.	Absent		Microscopically
-Crystals	Absent	Absent	Microscopically
-Others	NIL	Absent	Microscopic Examination

**Revival Diagnostics**  
401-Aqua Corridor,  
Beside Star Bazar, Adajan,  
Surat-395009. Mo-9825947712

Dr. Shivangi Gandhi  
M.B.B.S, M.D (Pathology)

Laboratory Test Result are Subject to technical limitation and should be clinically correlate for final diagnosis



## 2D-ECHOCARDIOGRAPHY & COLOR DOPPLER REPORT

Name:	AYUSH SINGH	Age/Gender	33Yrs /Male
Referred by.	MEDI WHEEL	Date	10/12/2022


**INDICATION:** Preventive Health check up

- **CARDIAC CHAMBERS:** Left Ventricle: Normal size, Left Atrium: Normal size.
- No e/o thrombus in LA/LV.
- **Right Atrium:** Normal size. **Right Ventricle:** Normal size,
- **Normal Right Ventricular function.** (TAPSE=20mm)
- **Normal Left Ventricular systolic function. LVEF = 60% ,**  
No regional wall abnormality. No thinning / scarring / dyskinesia of LV wall.
- **No Concentric Left Ventricular Hypertrophy.** (IVSd= 10 mm),
- **LV Compliance :**  
**NO Left Ventricular Diastolic Dysfunction [LVDD].**
- **VALVES:**
- Structurally Normal Mitral valve/ Aortic valve/Tricuspid valve/ Pulmonary valve .  
No significant Valvular Stenosis.
- **Doppler findings:** AV max = 1.22 m/s, PV max = 0.91 m/s.  
Trivial MR, Trivial Tricuspid regurgitation.
- **No Pulmonary Arterial Hypertension.** PASP by TRjet vel.method = 23 mmHg.
- **SEPTAE:** IAS / IVS Appear Intact.
- **IVC :** Normal in dimension and shows good inspiratory 15mm collapse.
- **OTHERS:** No e/o Pericardial effusion / vegetation.

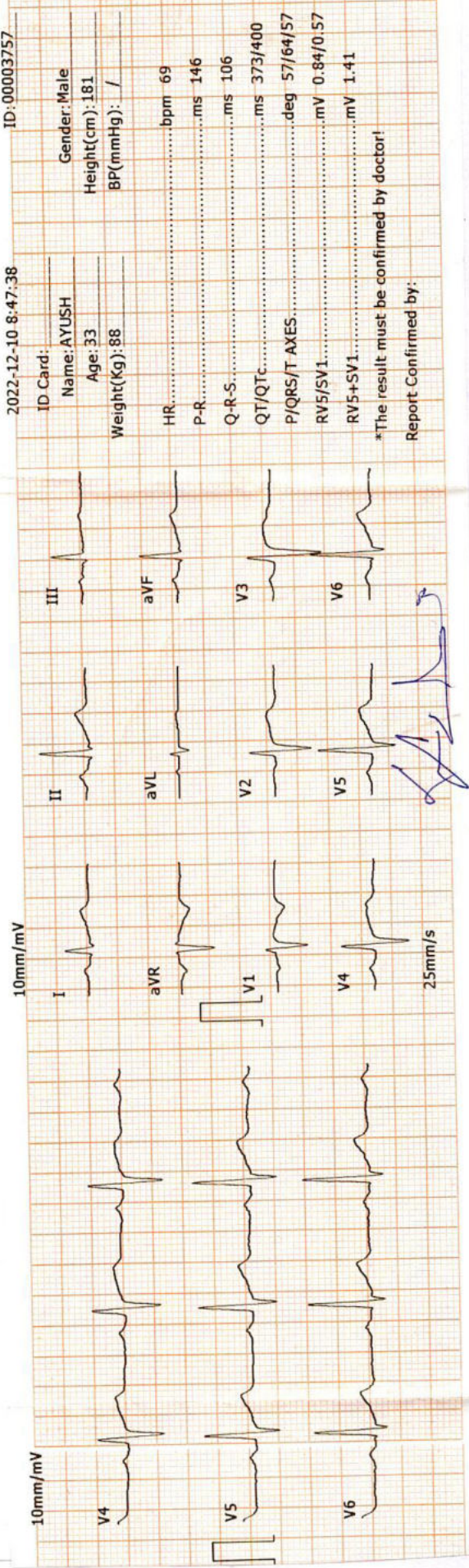
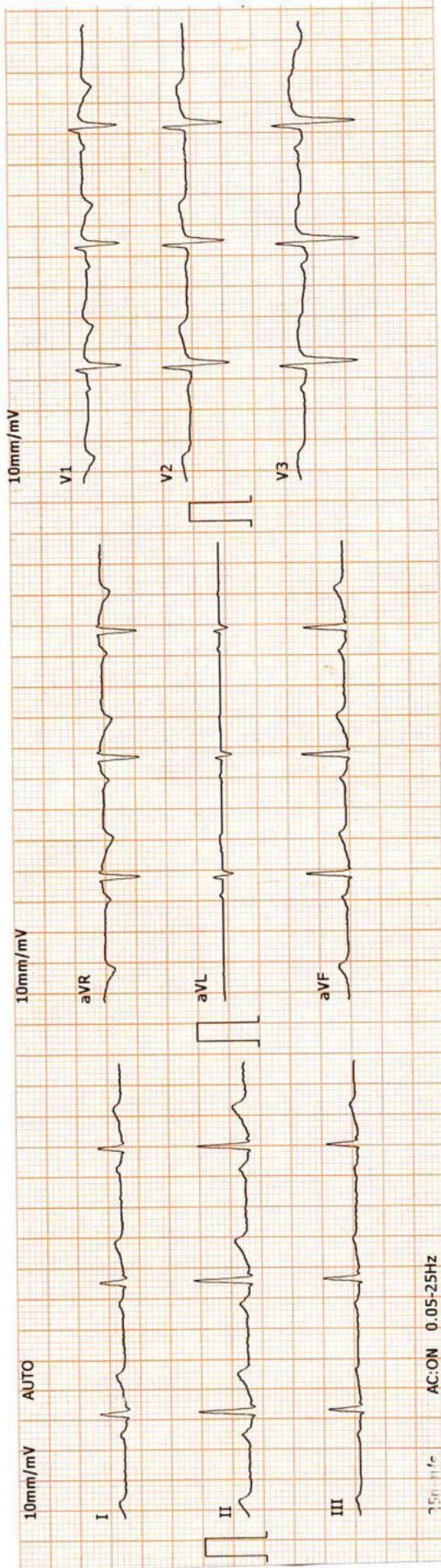
### IMPRESSION:

**NORMAL LV SYSTOLIC FUNCTION, LVEF= 60 %, NO RWMA,  
NO LVH , NO LVDD , NO PAH.**

**Revival Diagnostic**  
401, Aqua Corridor,  
B/s. Star Bazar, Surat-395009  
Mo. 91062-28601

  
**DR. ADITYA BORA**  
MBBS,DNB,PGDCC  
**PHYSICIAN & CLINICAL  
CARDIOLOGIST**

Laboratory Test Result are Subject to technical limitation and should be clinically correlate for final diagnosis



2022-12-10 8:47:38 ID: 00003757

ID Card: \_\_\_\_\_ Gender: Male  
 Name: AYUSH Height(cm): 181  
 Age: 33 BP(mmHg): /  
 Weight(Kg): 88

HR.....bpm 69  
 P-R.....ms 146  
 Q-R-S.....ms 106  
 QT/QTc.....ms 373/400  
 P/QRS/T AXES.....deg 57/64/57  
 RV5/SV1.....mV 0.84/0.57  
 RV5+SV1.....mV 1.41

\*The result must be confirmed by doctor!  
 Report Confirmed by: \_\_\_\_\_

**Revival Diagnostic**  
 401, Aqua Center  
 B/s. Star Bazar, Surat-395009  
 Mo. 91062-28601

**DR. ADITI PATEL**  
 M.B.B.S., D. CARD (MUM)  
 CLINICAL CARDIOLOGIST  
 REG.NO.G-42905

# REVIVAL

## DIAGNOSTICS



Name	AYUSH SINGH	Age/Gender	33Yrs/Male
Reg No.	3887/22	Receipt No	3587
Referred By	BOB - MEDI WHEEL(PKG10000240)	Mode of Payment	CREDIT
Collection Type	CENTER	Collection DateTime	10-Dec-2022 08:40 AM

### ECG

- REPORT :

1. The rhythm is sinus.
2. Heart rate is 69 beats per minute.
3. Normal P,QRS,T wave axis.
4. Normal PR,QRS,Q.T. Duration.
5. No pathological q wave or ST-T changes seen.
6. No evidence of chamber hypertrophy or enlargement seen.

**IMPRESSION : ECG WITHIN NORMAL LIMITS**

**Revival Diagnostic**  
401, Aqua Corridor,  
B/s. Star Bazar, Surat-395009  
Mo. 91062-28601

**DR. ADITI PATEL**  
M.B.B.S., D. CARD (MUM)  
CLINICAL CARDIOLOGIST  
REG.NO.G-42901

Signature

Laboratory Test Result are Subject to technical limitation and should be clinically correlate for final diagnosis

📍 4th Floor, Aqua Corridor, Hazira Road, Adajan Pal, Surat-395009.  
☎ 0261 2747788, 9825947712 ✉ revivaldiagnostics.surat@gmail.com 🌐 www.revivaldiagnostics.com

This medical report is not intended for medico-legal purposes.



Name	<b>AYUSH SINGH</b>	Age/Gender	<b>33Yrs/Male</b>
Reg No.	<b>3887/22</b>	Receipt No	<b>3587</b>
Referred By	<b>BOB - MEDI WHEEL(PKG10000240)</b>	Mode of Payment	<b>CREDIT</b>
Collection Type	<b>CENTER</b>	Collection DateTime	<b>10-Dec-2022 08:41 AM</b>

## USG OF ABDOMEN & PELVIS

### **LIVER:**

Liver is normal in size and increased echotexture.  
No evidence of focal SOL or dilatation of IHBR seen.  
Portahepatis appear normal.

### **GALLBLADDER:**

Gallbladder is not visualized. h/o cholecystectomy.

### **PANCREAS:**

Pancreas appears normal in size and echotexture.  
No focal lesion, mass or pancreatitis.

### **SPLEEN:**

Spleen appears normal in size and echotexture.

### **PARAAORTIC REGION:**

Aorta grossly appears normal.  
No paraaortic lymphnodes seen.

### **KIDNEYS:**

Both kidneys appear normal in size, shape and in position.  
Cortex and collecting system of both kidneys appears normal.  
No evidence of calculus or obstructive uropathy on either side.

### **URINARY BLADDER:**

Bladder appears normal. No calculus or mass lesion is seen.

### **PROSTATE:**

Prostate appears normal in size and echotexture.  
No evidence of free fluid in pelvis.

### **COMMENTS:**

**fatty liver**

**Dr. Chirag K. Patel**  
MBBS-DNB  
Revival Diagnostics  
Radiologist  
4th Floor, Aqua Corridor,  
Nr. Star Bazar, Hazira Main Road,  
Adajan, Surat-395009.  
No. 9726572003

Laboratory Test Result are Subject to technical limitation and should be clinically correlate for final diagnosis



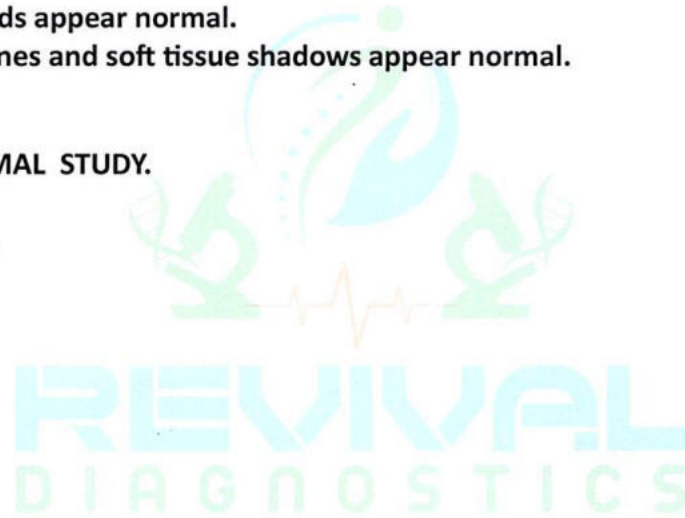
Name	<b>AYUSH SINGH</b>	Age/Gender	<b>33Yrs/Male</b>
Reg No.	<b>3887/22</b>	Receipt No	<b>3587</b>
Referred By	<b>BOB - MEDI WHEEL(PKG10000240)</b>	Mode of Payment	<b>CREDIT</b>
Collection Type	<b>CENTER</b>	Collection DateTime	<b>10-Dec-2022 08:41 AM</b>

### CHEST RADIOGRAPH (PA VIEW)

- Hilar shadows are within normal limits.
- Pulmonary vasculature appears normal.
- Cardiac appears normal in size.
- Both domeh of the diaphragm are smooth.
- Both costophrenic recesses are clear.
- Both lung fields appear normal.
- Visualized bones and soft tissue shadows appear normal.

IMPRESSION: NORMAL STUDY.

DR.CHIRAG K PATEL  
RADIOLOGIST



**Dr. Chirag K. Patel**  
MBBS-DMPD  
Reg. No. G-23509  
**Revival Diagnostic**  
4th Floor, Aqua Corridor,  
Nr. Star Bazar, Hazira Main Road,  
Adajan, Surat-395009.  
Mo. 97266 726683

Laboratory Test Result are Subject to technical limitation and should be clinically correlate for final diagnosis





NAME : AYUSH SINGH  
AGE : 33 YRS/MALE  
REF. BY : MEDI WHEEL

12