



भारत सरकार
Government of India



सिमा कुमारी
Seema Kumari
जन्म तिथि/ DOB: 02/01/1982
महिला / FEMALE



4528 9417 5215

मेरा आधार, मेरी पहचान



भारतीय पहचान आधिकारण
Unique Identification Authority of India

पता:
अर्धागिनी: प्रशांत रंजन, कुर्था,
सेमुआरा, अरवल,
बिहार - 804421

Address:
W/O: Prashant Ranjan, Kurtha,
Semuara, Arwal,
Bihar - 804421

4528 9417 5215



help @ uidai.gov.in

www
www.uidai.gov.in

ID: 414
SEEMA KUMARI
Female Years

28-07-2021 10:18:20 AM

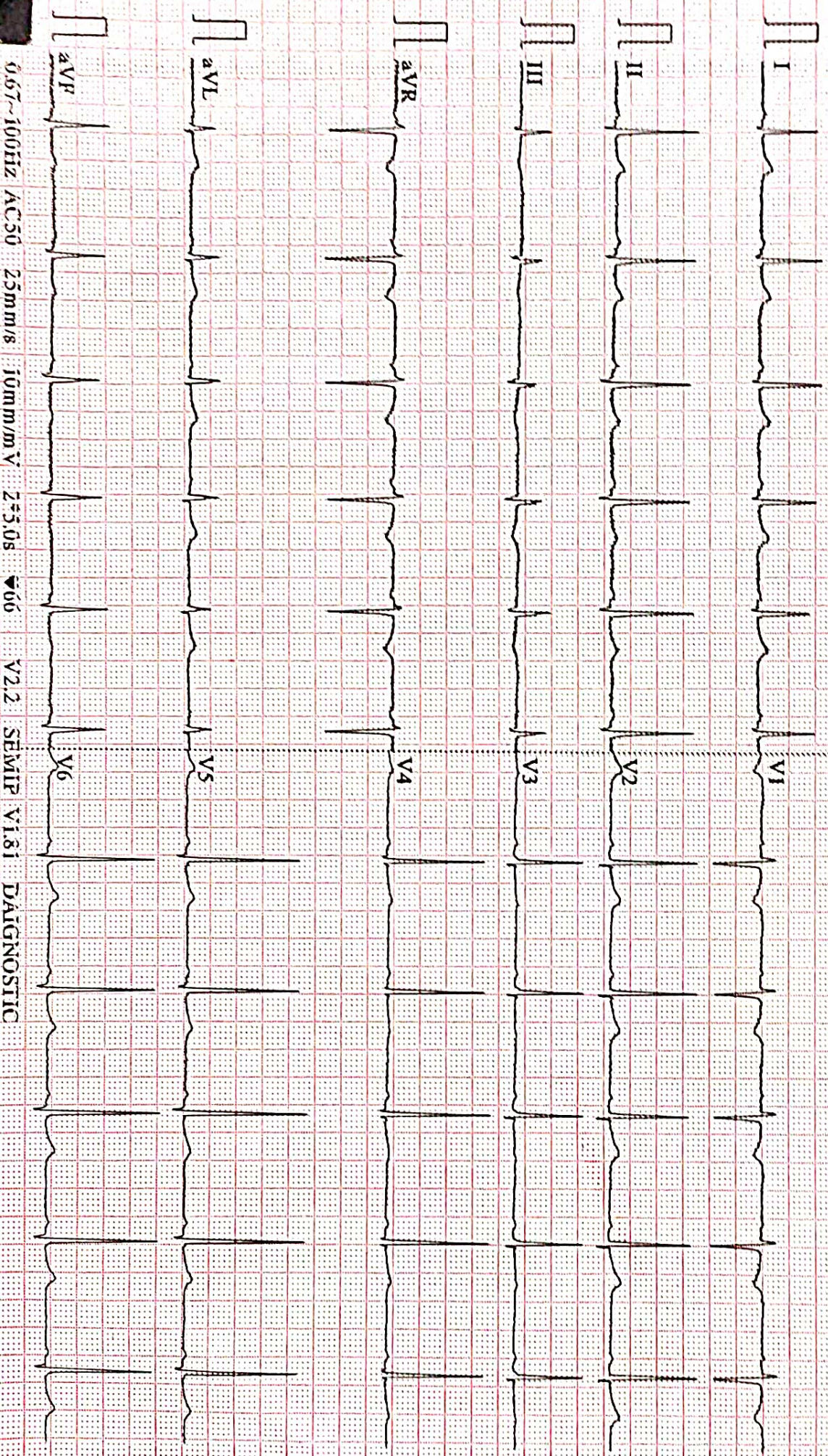
BPL

Diagnosis Information:

Sinus Arrhythmia
Low T Wave(V3,V4,V5,V6)

HR : 66 bpm
P : 91 ms
PR : 134 ms
QRS : 83 ms
QT/QTc : 389/408 ms
P/QRS/T : 38/44/13 °
RV5/SV1 : 2.22/40.891 mV

Report Confirmed by:



0.67~100Hz AC50 25mm/s 10mm/mV Z=5.0s 66 V2.2 SEMIP V1.81 DIAGNOSTIC



SUBHAM IMAGING & A.L.C. DIAGNOSTICS CENTRE

H.O. : Ajay Market, Dena Bank Building, East Ashok Nagar, Kankarbagh, Patna - 20

B.O. : Khanpura Road (Below Gyan Sharowar School), Paliganj, Patna.

e-mail : shubham.pat.usg@gmail.com # website : www.alchealthcheckup.in

OPINION MUST BE CORRELATES WITH CLINICAL & OTHER INVESTIGATION FOR DIAGNOSIS NOT FOR MEDICO LEGAL PURPOSE

Pt. Name :- SEEMA KUMARI

Ref. By :- DR. B O B

Date:- 28-Jul-21

Age / Sex 39 Yrs. F.

REAL TIME U.S.G. OF LOWER ABDOMEN

Thanks for your kind referral

(Report.)

U.BLADDER:- Shows normal in outline with echo free lumen. No calculi or mass seen.
Pre void - 340 ml. Post void - is in significant

UTERUS :- Is Enlarged and bulky in size measures 9.60 X 5.30 cm and
Aneverted in Position Echogenicity of Myometeriam is increased
Endometrial thickness is 8.2 mm
No focal mass lesion seen cervix appear normal .

ADNEXA :- Both ovary appears normal in size and shape.

P.O.D :- Mild collection seen in P.O.D.

R.I.F. :- Son graphically no appendicular mass or collection seen.

OTHERS :- No ascites , lymph adenopathy. No pleural effusion seen on either side

IMPRESSION

➤ *Enlarged Bulky Uterus With Mild Collection Seen In POD -?PID*

Otherwise son graphically normal scan. of rest organs .

↓
e
28/7/21

ESTB BY:-

Dr. P. K. Tiwari

MD, BRIT (Radio Imaging)

Consultant Imagonologist & Sonologist

A.L.C. Diagnostics & Research Centre, Patna

Dr. S. Kumar

MD. (Pat)

Consultant Pathologist

Dr. A. K. Singh

MBBS, PGDMCH

Consultant Radiologist & Sonologist