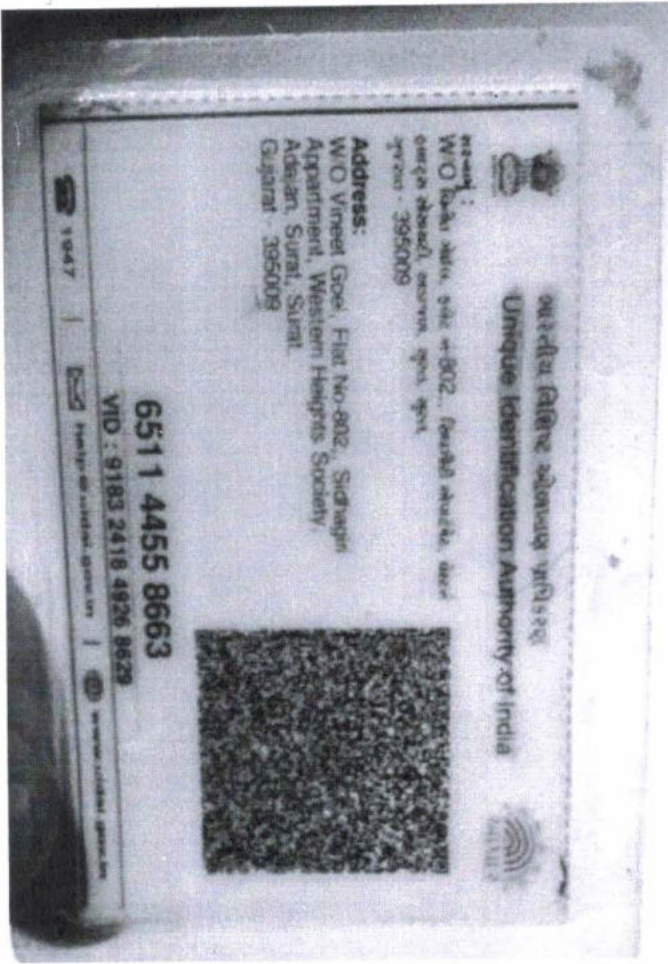


**Dr. NITIN AGARWAL**  
 MBBS, MD  
 Regn. No. DMC-R-1436

**ONEPLUS ULTRASOUND LAB**  
 47, Harsh Vihar, Pitam Pura,  
 Delhi-110034  
 Ph. 011-42480101, 9599913051  
 E-mail: oneplusul@gmail.com





2

Dr. NITIN AGARWAL  
MBBS, MD  
Regn. No. DMC-R-1435

ONEPLUS ULTRASOUND LAB  
47, Harsh Vihar, Pitam Pura,  
Delhi-110034  
Ph. 011-42480101, 9599913051  
E-mail: oneplusul@gmail.com



**OnePLUS**  
Ultrasound Lab  
— QUALITY FIRST... ALWAYS! —


**Dr. Nitin Agarwal**


Pathologist & Director  
Ex. Sr. Res. MAMC  
& Lok Nayak Hospital  
Ex. Chief of Lab Dr. Lal Path Labs.

**Dr. Pooja (Garg) Agarwal**

Radiologist & Director  
MAMC & Lok Nayak Hospital

I, Tanvi Aged 32 have come for full body check-up.  
since I am on my periods, I will get URINE, STOOL &  
PAP SMEAR test later on.

  
21/4/23

  
Dr. NITIN AGARWAL  
MBBS, MD  
Regn. No. DMC-R-1436

47, Harsh Vihar, Pitampura, New Delhi-110034 | Ph.: 011-42480101, 9599913051  
E-mail: [oneplusul@gmail.com](mailto:oneplusul@gmail.com) | Web.: [www.oneplusul.in](http://www.oneplusul.in)

Clinical correlation is essential for final diagnosis. • If test results are unsatisfactory please contact personally or on phone. • This report is for perusal of doctors only.  
• All disputes Subject to Delhi Jurisdiction only. • Not for medicolegal purposes. • All congenital anomalies in a foetus may not be diagnosed in routine obstetric ultrasound.

# ONEPLUS ULTRASOUND LAB

47, HARSH VIHAR, PITAMPURA, DELHI- 110034

Ms. TANVI

Age : 32/F

Ref. by : MEDIWHEEL

Indication1 :

Indication2 :

Indication3 :

COMMENTS : Moderate Right Axis Deviation. Sinus Rhythm.

ID : 2216

HI/WI : 150/58

Recorded : 22-4-2023 9:48

Medication1 :

Medication2 :

Medication3 :

BPM : 97

BP : 120/80

P Axis : 63 deg

QRS Axis : 93 deg

T Axis : 21 deg

P duration : 80 msec

PR duration : 113 msec

QRS duration : 103 msec

QT interval : 303 msec

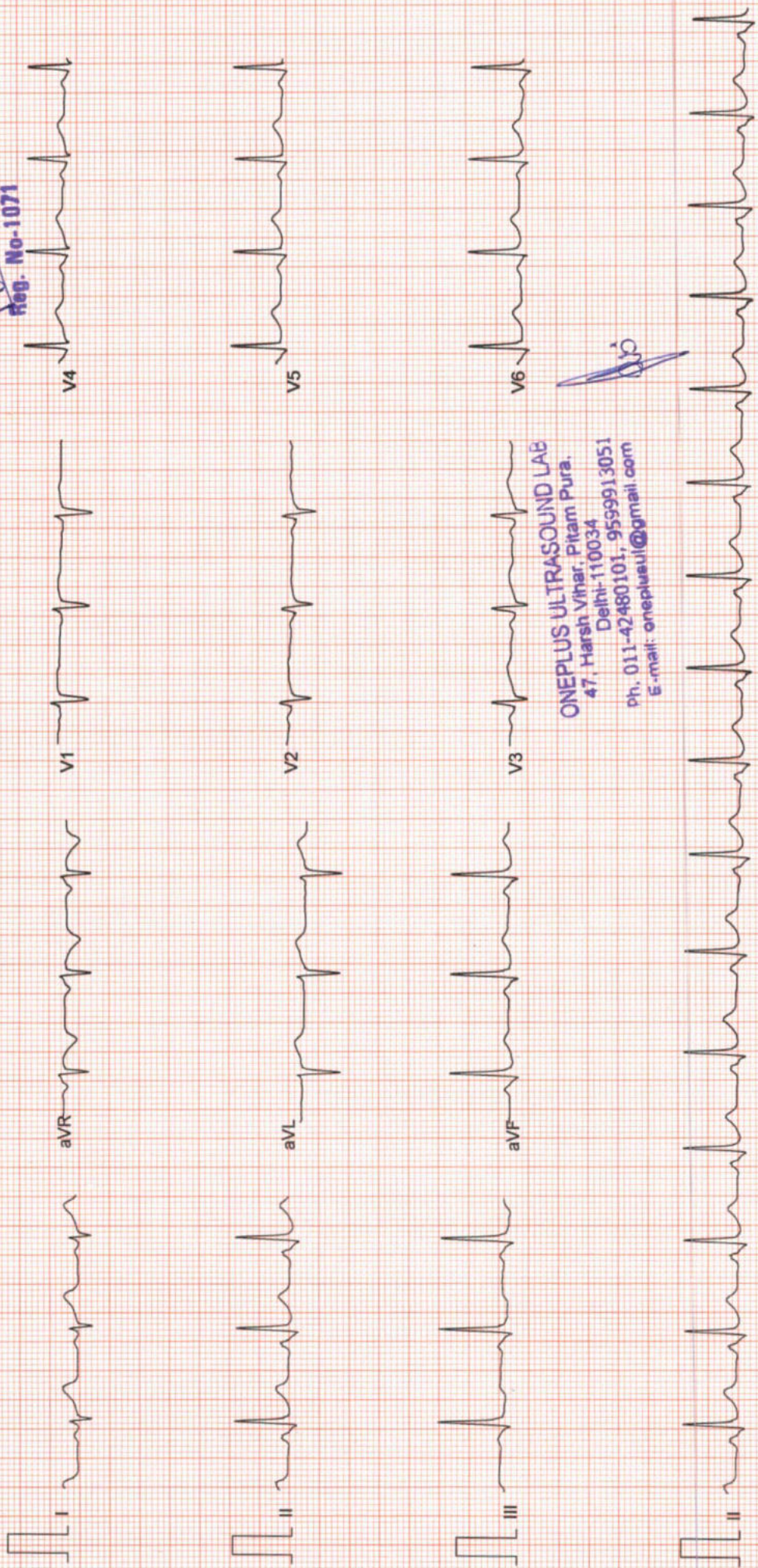
QTc interval : 367 msec

Raw E.C.G. (Seq)

Unconfirmed Report Reviewed By:

Cardiologist

**Dr. P.K. GUPTA**  
**MBBS, MD**  
**Reg. No-1071**



**ONEPLUS ULTRASOUND LAB**  
47, Harsh Vihar, Pitam Pura,  
Delhi-110034  
Ph. 011-42480101, 9599913051  
E-mail: [oneplusul@gmail.com](mailto:oneplusul@gmail.com)

# ONEPLUS ULTRASOUND LAB

47, HARSH VIHAR PITAMPURA DELHI 110034

## TREADMILL TEST SUMMARY REPORT

ID : 999

HIWT : 150/58

Recorded : 22-4-2023 9:57

Ms. TANVI

Age : 32/F

Ref. by : MEDIWHEEL

Indication1 :

Indication2 :

Indication3 :

Protocol: BRUCE

History:

Medication1 :

Medication2 :

Medication3 :

PHASE	PHASE TIME	STAGE TIME	SPEED (Km./Hr.)	GRADE (%)	H.R. (BPM)	B.P. (mmHg)	RPP X100	II	ST LEVEL (mm) V2	V5	METS
SUPINE STANDING					106 104	120/80 120/80	127 124	0.3 0.5	0.4 0.5	0.3 0.4	
STAGE 1	2:59	2:59	2.70	10.00	113	130/82	146	-0.2	0.4	0.2	4.80
STAGE 2	5:59	2:59	4.00	12.00	134	142/86	190	-0.5	0.2	0.1	7.10
STAGE 3	8:59	2:59	5.40	14.00	148	154/88	227	-0.1	0.0	-0.1	10.00
STAGE 4	9:29	0:29	6.70	16.00	159	166/90	263	-0.3	-0.1	-0.7	10.65
PEAK EXER	9:31	0:31			160	166/90	265	-0.3	-0.1	-0.7	10.69
RECOVERY	2:59	2:59	0.00	0.00	107	126/82	134	-0.5	0.2	-0.1	

### RESULTS

Exercise Duration : 9:31 Minutes  
 Max Heart Rate : 160 bpm - 85 % of target heart rate 188 bpm  
 Max Blood Pressure : 166/90 mmHg  
 Max Work Load : 10.69 METS

*Negative for ischemic change*



**Dr. P.K. GUPTA**  
**MBSBS, MD**

**Reg. No-1071**  
 Cardiologist

ONEPLUS ULTRASOUND LAB

47, Harsh Vihar, Pitam Pura,  
 Delhi-110034

Ph. 011-42480101, 9599913051

E-mail: oneplusul@gmail.com

# ONEPLUS ULTRASOUND LAB

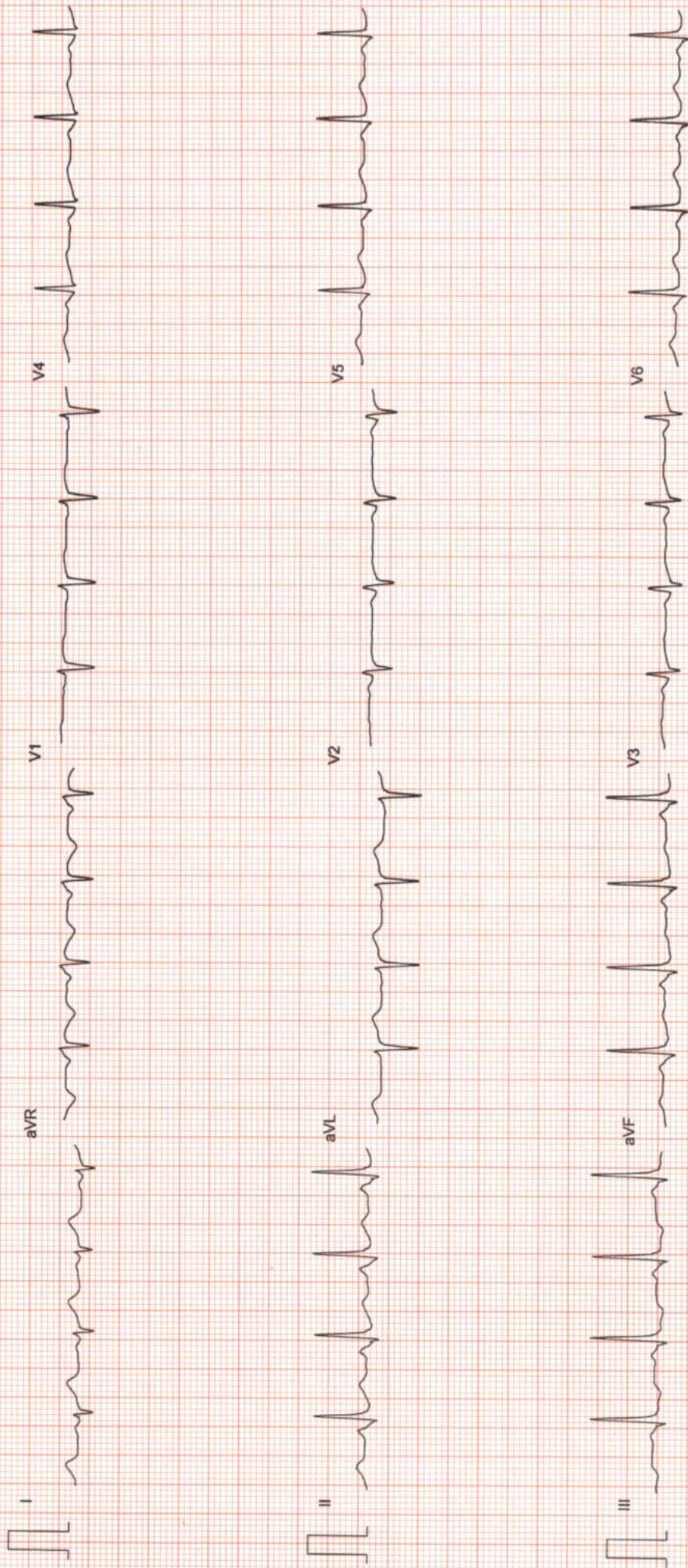
Ms. TANVI  
I.D. : 999  
AGE/SEX : 32/F  
RECORDED : 22-4-2023 9:57

SUPINE  
PRETEST

RATE : 106 BPM  
B.P. : 120/80 mmHg

ST @ 10mm/mV  
80ms PostJ

RAW E.C.G.



ONEPLUS ULTRASOUND LAB  
47, Harsh Vihar, Pitam Pura,  
Delhi-110034  
Ph. 011-42480101, 9599913051  
E-mail: oneplusul@gmail.com

# ONEPLUS ULTRASOUND LAB

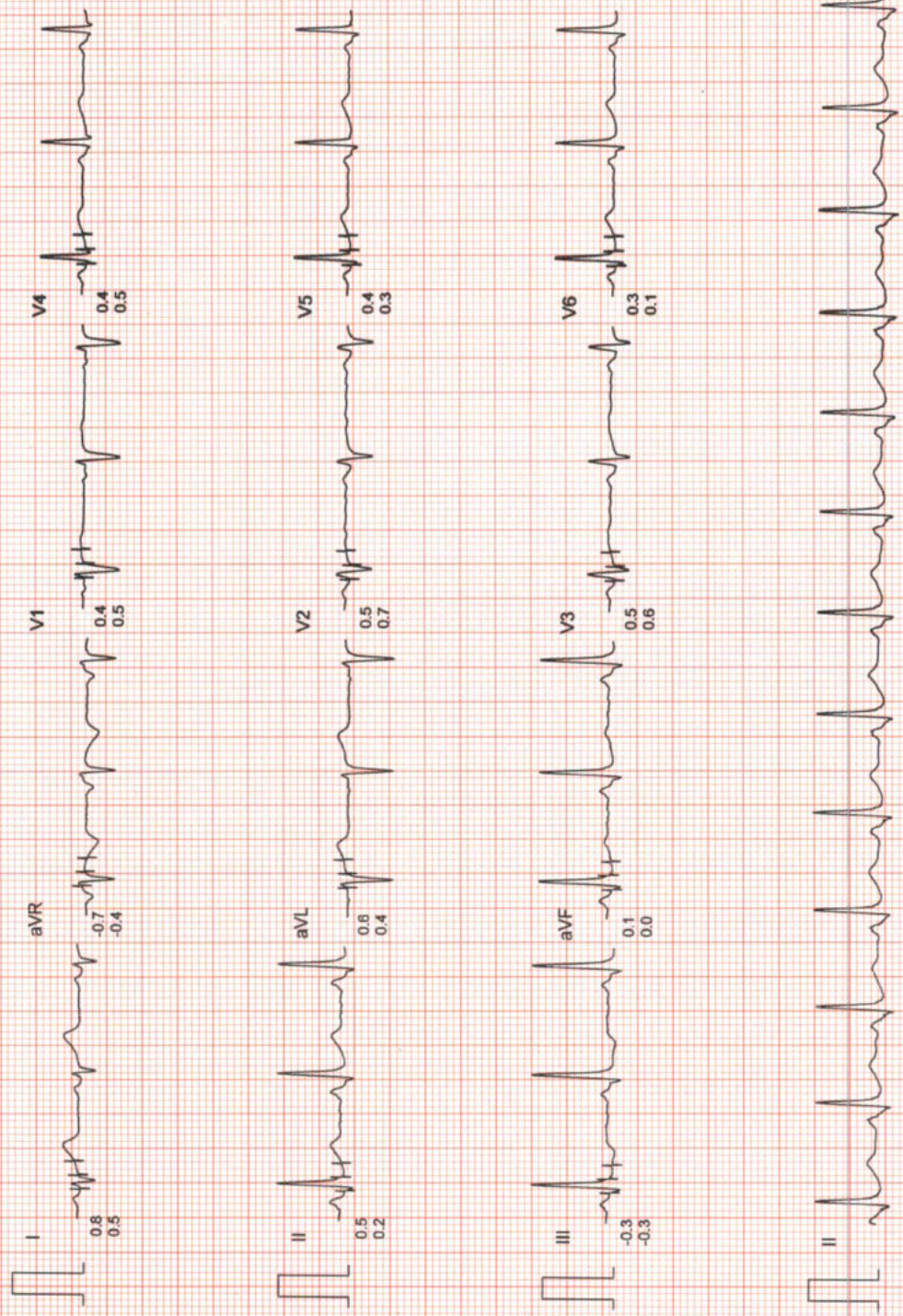
STANDING  
PRETEST

ST @ 10mm/mV  
80ms PostJ

Ms. TANVI  
I.D. : 999  
AGE/SEX : 32/F  
RECORDED : 22-4-2023 9:57

RATE : 104 BPM  
B.P. : 120/80 mmHg

LINKED MEDIAN



50mm/sec 20mm/mV

ONEPLUS ULTRASOUND LAB  
47, Harsh Vihar, Pitam Pura,  
Delhi-110034  
Ph. 011-42480101, 9599913051  
E-mail: [oneplusul@gmail.com](mailto:oneplusul@gmail.com)

# ONEPLUS ULTRASOUND LAB

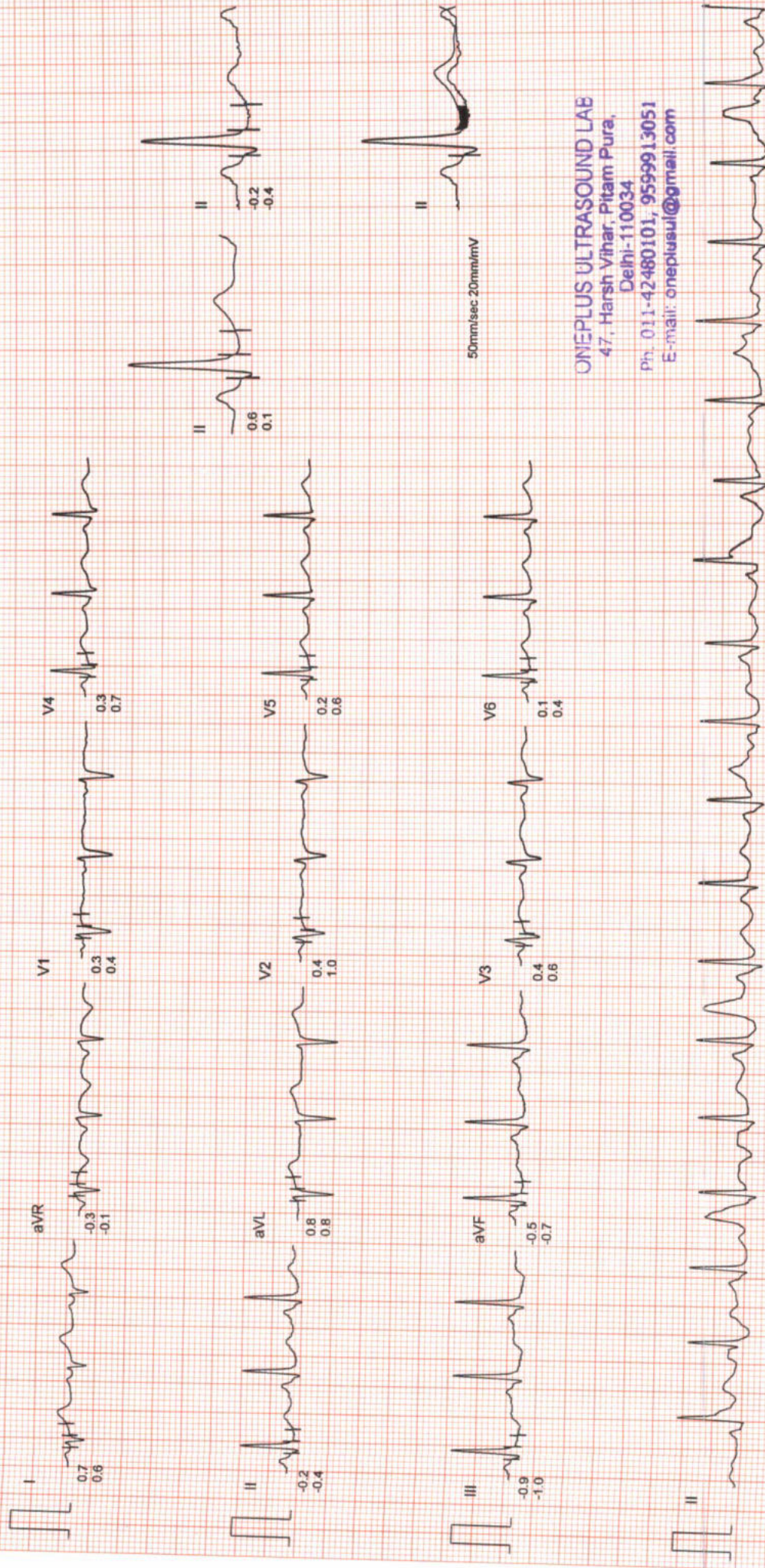
Ms. TANVI  
I.D. : 999  
AGE/SEX : 32/F  
RECORDED : 22-4-2023 9:57

RATE : 113 BPM  
B.P. : 130/82 mmHg

BRUCE  
EXERCISE 1  
PHASE TIME : 2:59  
STAGE TIME : 2:59

ST @ 10mm/mV  
80ms PostJ  
SPEED : 2.7 Km./Hr.  
GRADE : 10.0 %

LINKED MEDIAN



50mm/sec 20mm/mV

ONEPLUS ULTRASOUND LAB  
47, Harsh Vihar, Pitam Pura,  
Delhi-110034  
Ph: 011-42480101, 9599913051  
E-mail: [oneplusul@gmail.com](mailto:oneplusul@gmail.com)



# ONEPLUS ULTRASOUND LAB

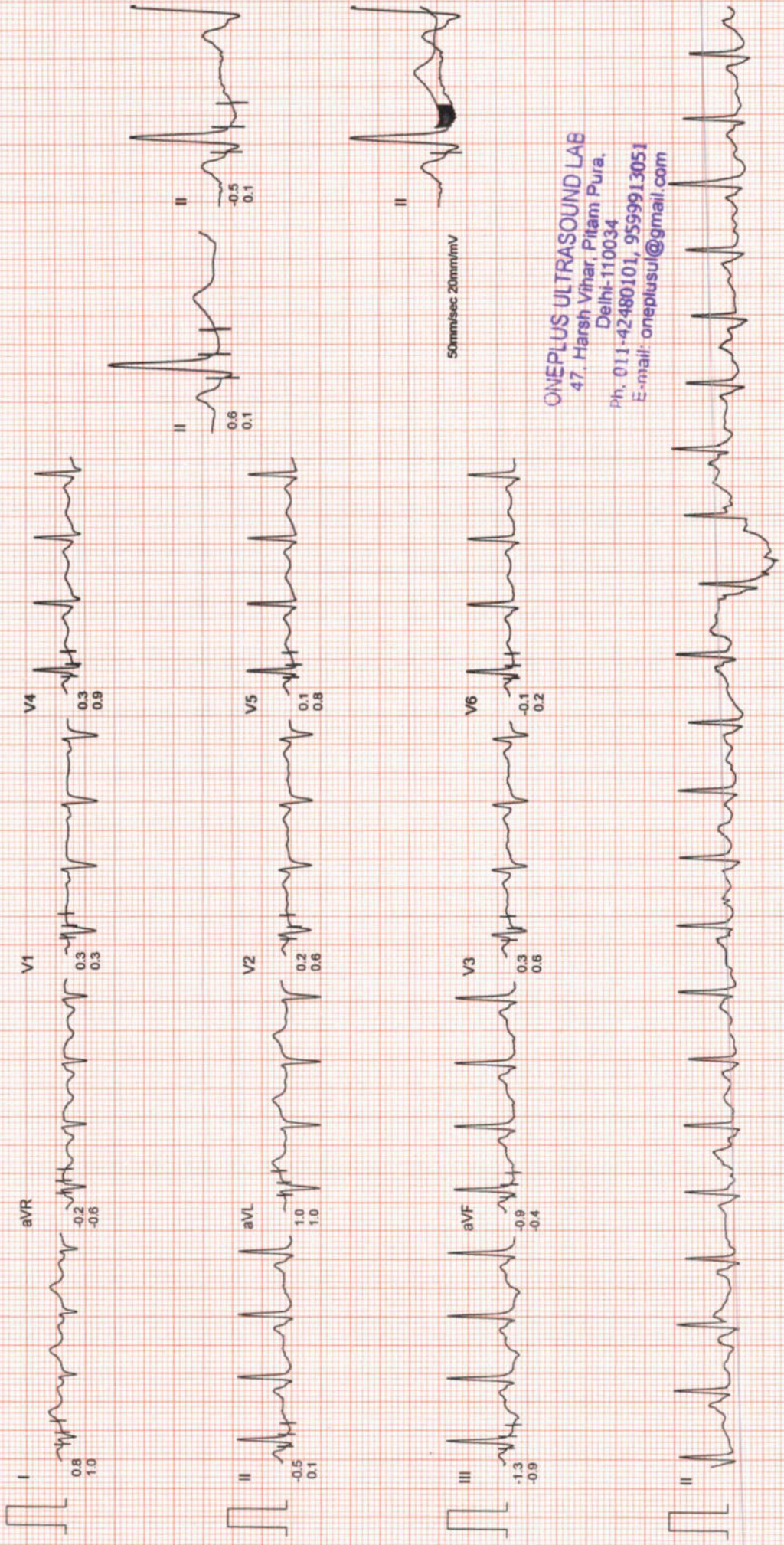
Ms. TANVI  
I.D. : 999  
AGE/SEX : 32/F  
RECORDED : 22-4-2023 9:57

RATE : 134 BPM  
B.P. : 142/86 mmHg

BRUCE  
EXERCISE 2  
PHASE TIME : 5:59  
STAGE TIME : 2:59

ST @ 10mm/mV  
80ms Post.J  
SPEED : 4.0 Km./Hr.  
GRADE : 12.0 %

LINKED MEDIAN



50mm/sec 20mm/mV

ONEPLUS ULTRASOUND LAB  
47, Harsh Vihar, Pitam Pura,  
Delhi-110034  
Ph. 011-42480101, 9599913051  
E-mail: oneplusul@gmail.com

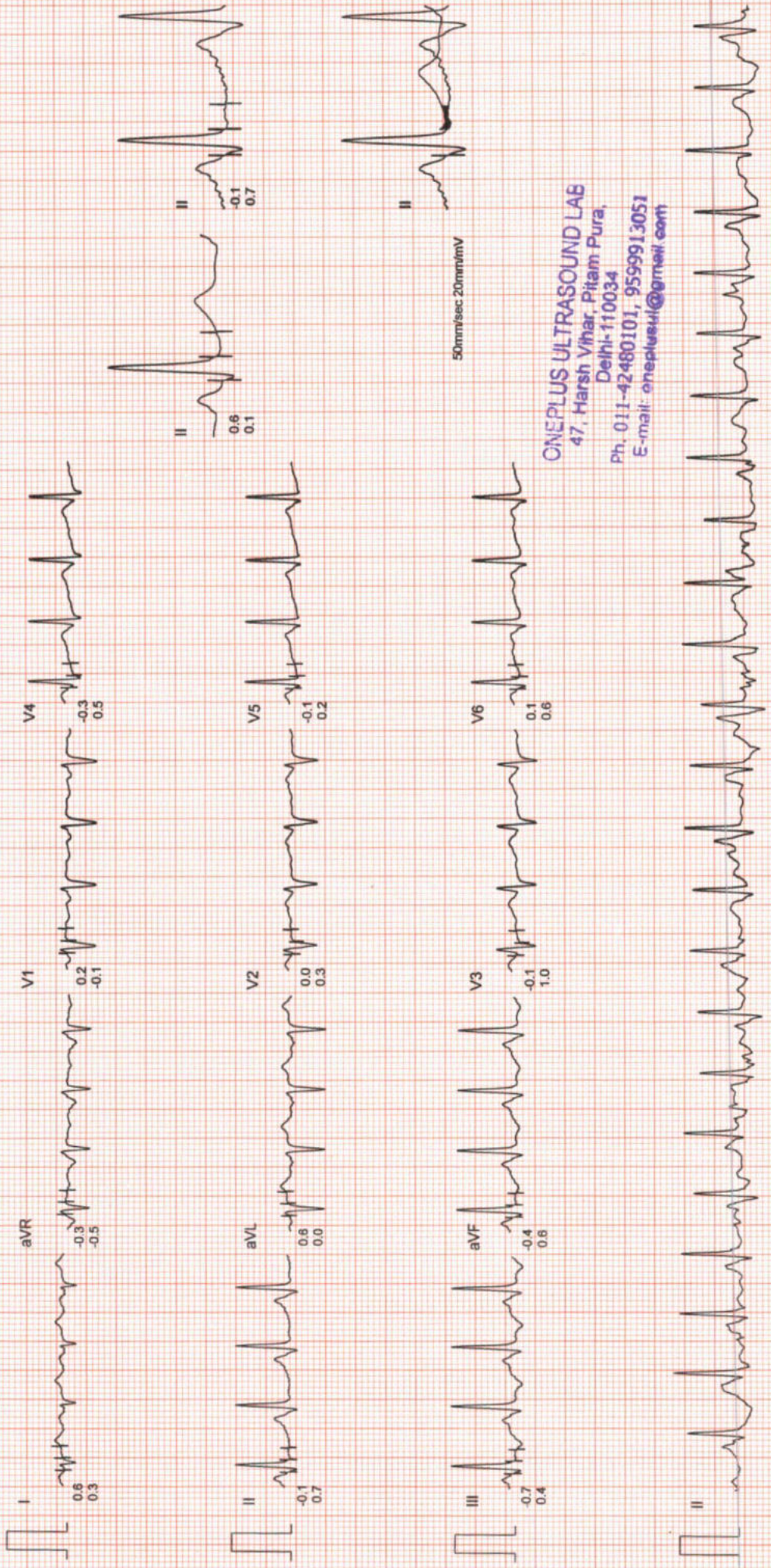
# ONEPLUS ULTRASOUND LAB

Ms. TANVI  
I.D. : 999  
AGE/SEX : 32/F  
RECORDED : 22-4-2023 9:57

RATE : 148 BPM  
B.P. : 154/88 mmHg

ST @ 10mm/mV  
80ms PostJ  
SPEED : 5.4 Km./Hr.  
GRADE : 14.0 %

LINKED MEDIAN



ONEPLUS ULTRASOUND LAB  
47, Harsh Vihar, Pitam Pura,  
Delhi-110034  
Ph. 011-42480101, 9599913051  
E-mail: [oneplusul@gmail.com](mailto:oneplusul@gmail.com)

# ONEPLUS ULTRASOUND LAB

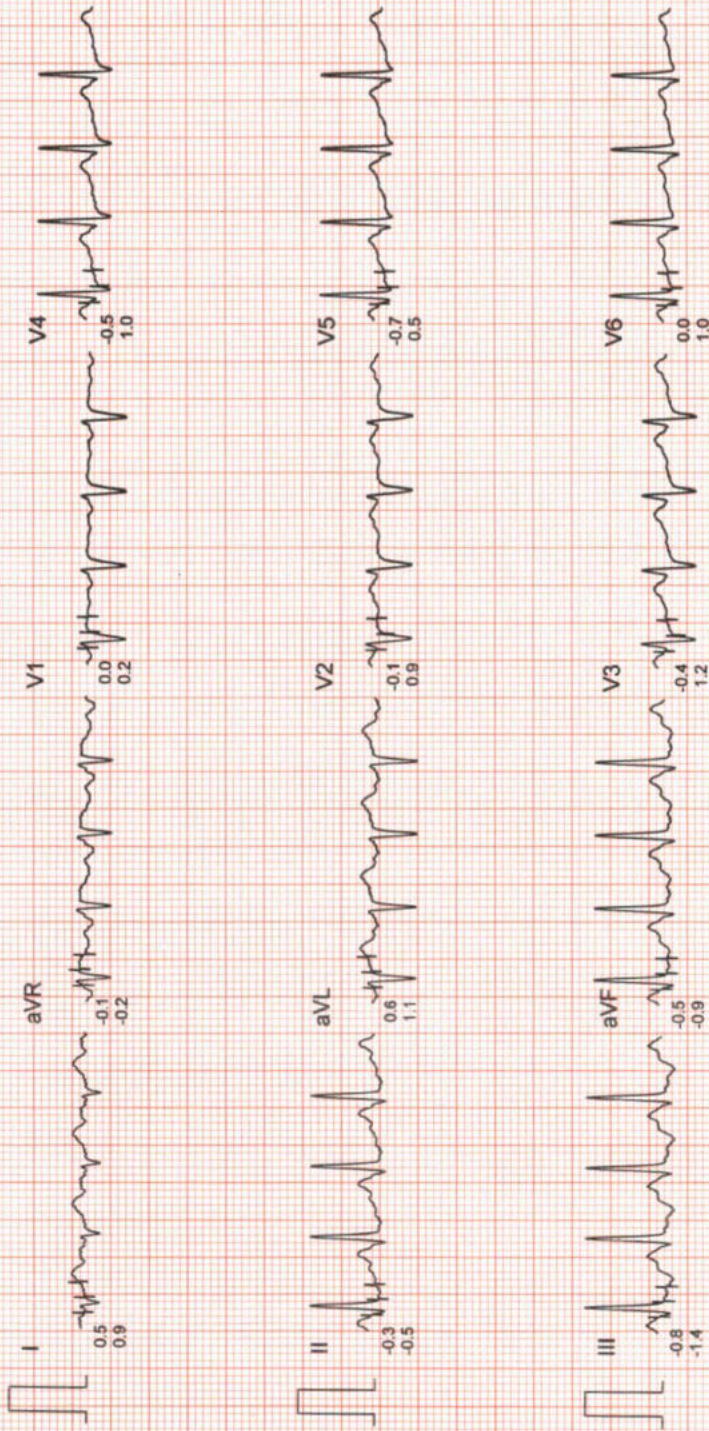
Ms. TANVI  
I.D. : 999  
AGE/SEX : 32/F  
RECORDED : 22-4-2023 9:57

RATE : 159 BPM  
B.P. : 166/90 mmHg

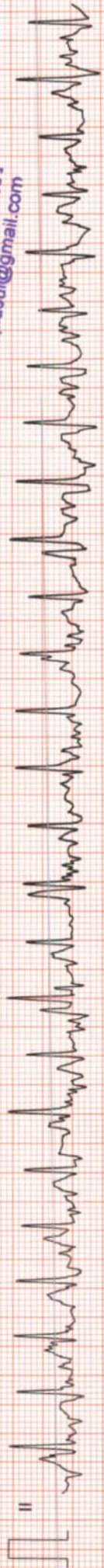BRUCE  
EXERCISE 4  
PHASE TIME : 9:29  
STAGE TIME : 0:29

ST @ 10mm/mV  
80ms PostJ  
SPEED : 6.7 Km./Hr.  
GRADE : 16.0 %

LINKED MEDIAN



ONEPLUS ULTRASOUND LAB  
47, Harsh Vihar, Pitam Pura,  
Delhi-110034  
Ph. 011-42480101, 9599913051  
E-mail: onepusul@gmail.com



# ONEPLUS ULTRASOUND LAB

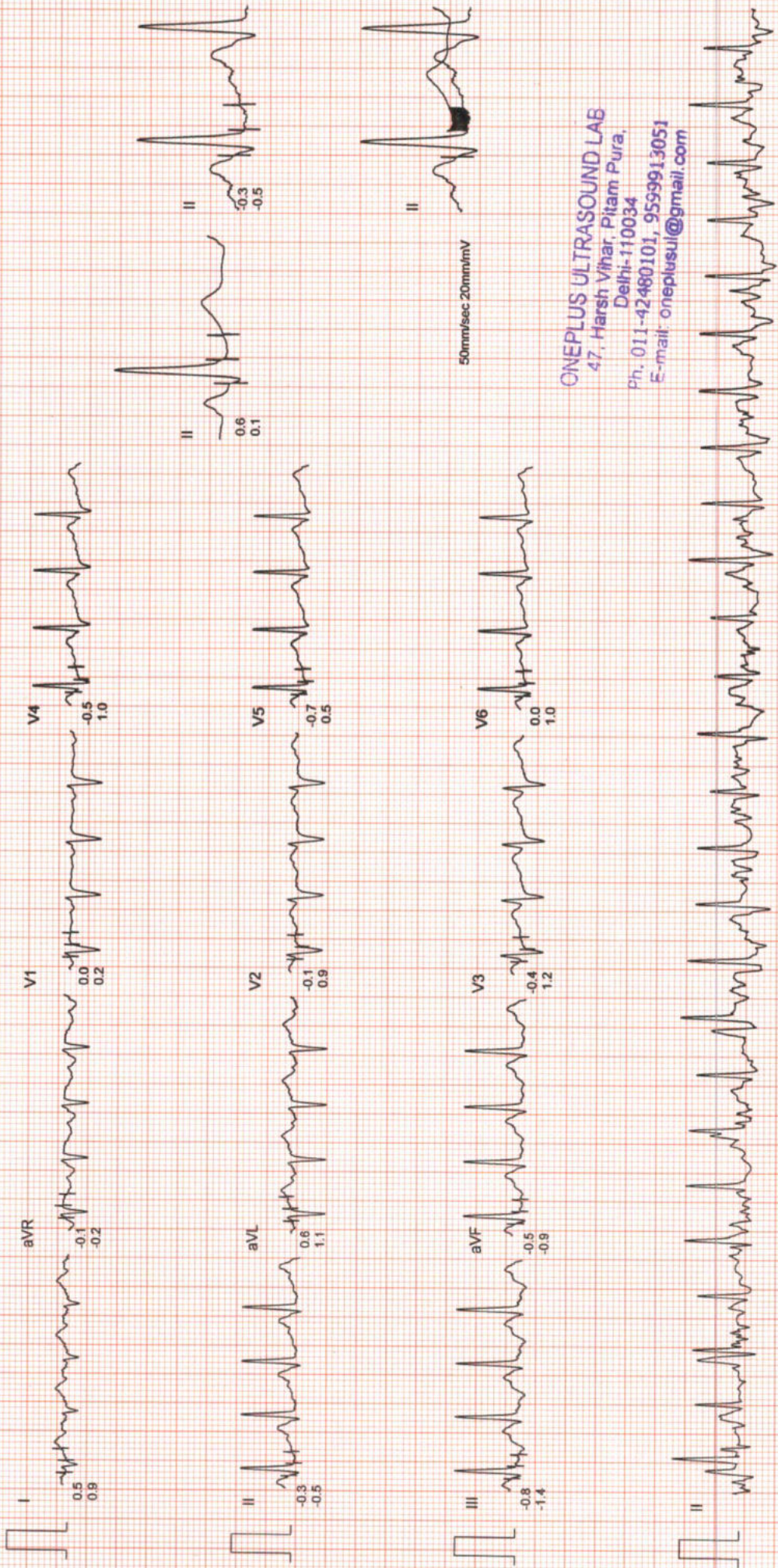
Ms. TANVI  
I.D. : 999  
AGE/SEX : 32/F  
RECORDED : 22-4-2023 9:57

RATE : 160 BPM  
B.P. : 166/90 mmHg

BRUCE  
PEAK EXER  
PHASE TIME : 9:31  
STAGE TIME : 0:31

ST @ 10mm/mV  
80ms PostJ  
SPEED : 6.7 Km./Hr.  
GRADE : 16.0 %

LINKED MEDIAN



50mm/sec 20mm/mV

ONEPLUS ULTRASOUND LAB  
47, Harsh Vihar, Pitam Pura,  
Delhi-110034  
Ph. 011-42480101, 9599913051  
E-mail: oneplusul@gmail.com

# ONEPLUS ULTRASOUND LAB

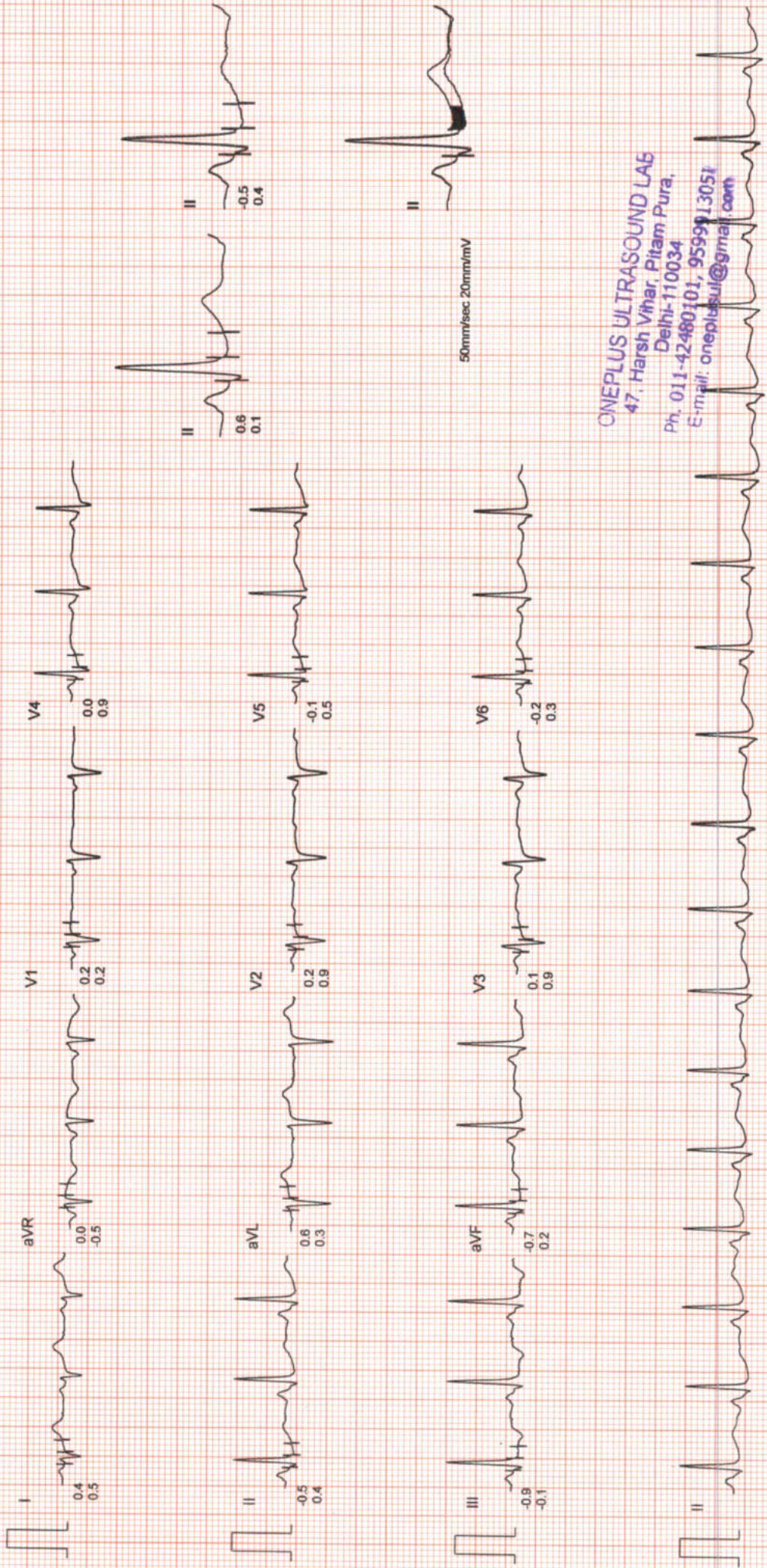
Ms. TANVI  
I.D. : 999  
AGE/SEX : 32/F  
RECORDED : 22-4-2023 9:57

RATE : 107 BPM  
B.P. : 126/82 mmHg

BRUCE  
RECOVERY  
PHASE TIME : 2:59

ST @ 10mm/mV  
80ms PostJ  
SPEED : 0.0 Km./Hr.  
GRADE : 0.0 %

LINKED MEDIAN



ONEPLUS ULTRASOUND LAB  
47, Harsh Vihar, Pitam Pura,  
Delhi-110034  
Ph. 011-42480101, 9599113051  
E-mail: [oneplusul@gmail.com](mailto:oneplusul@gmail.com)

# ONEPLUS ULTRASOUND LAB

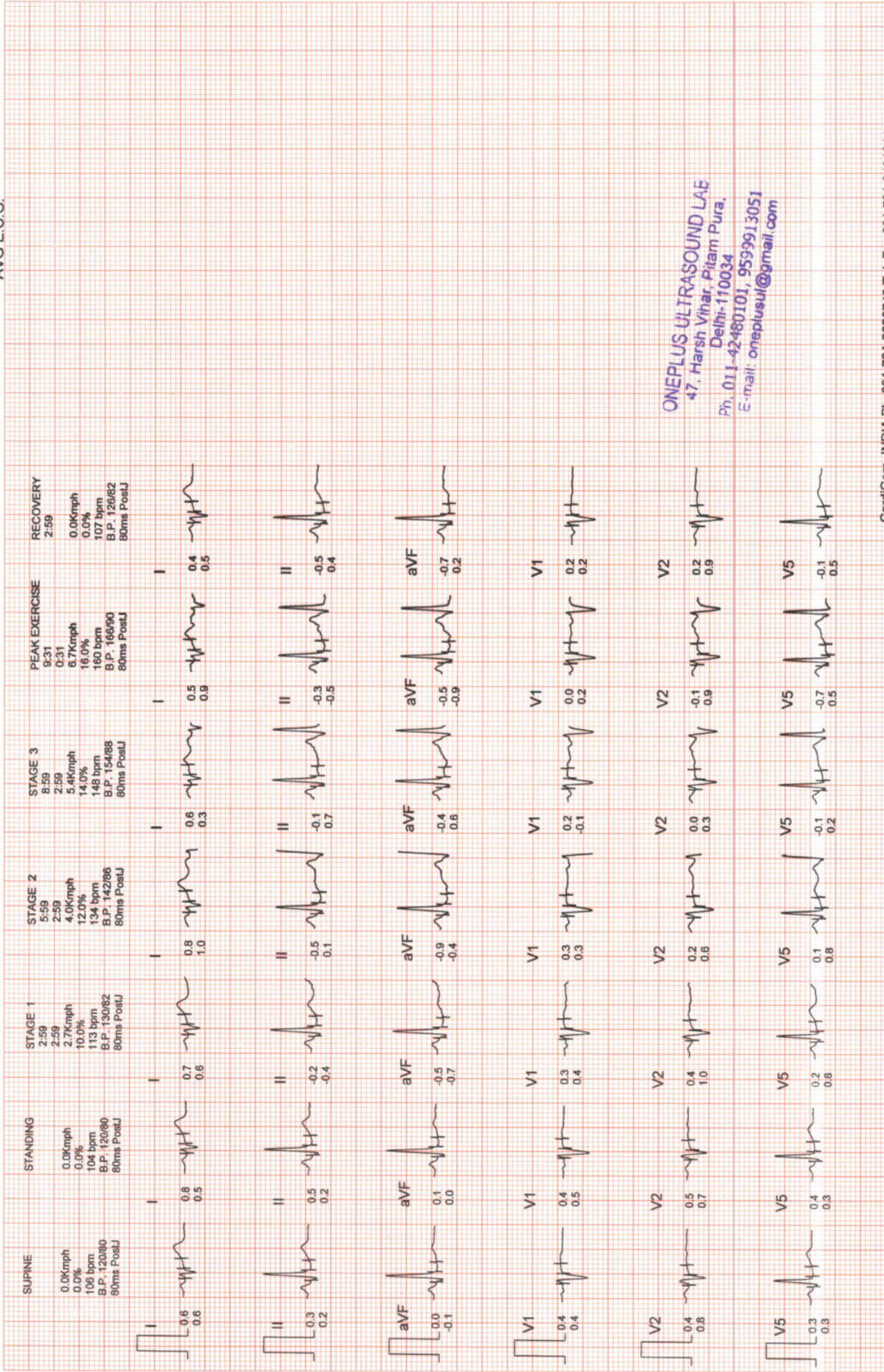
Ms. TANVI

I.D. : 999

AGE/SEX : 32/F

RECORDED : 22-4-2023 9:57

AVG E.C.G.



ONEPLUS ULTRASOUND LAB  
47, Harsh Vihar, Pitam Pura,  
Delhi-110034  
Ph. 011-42480101, 9599913051  
E-mail: [oneplusul@gmail.com](mailto:oneplusul@gmail.com)

# ONEPLUS ULTRASOUND LAB

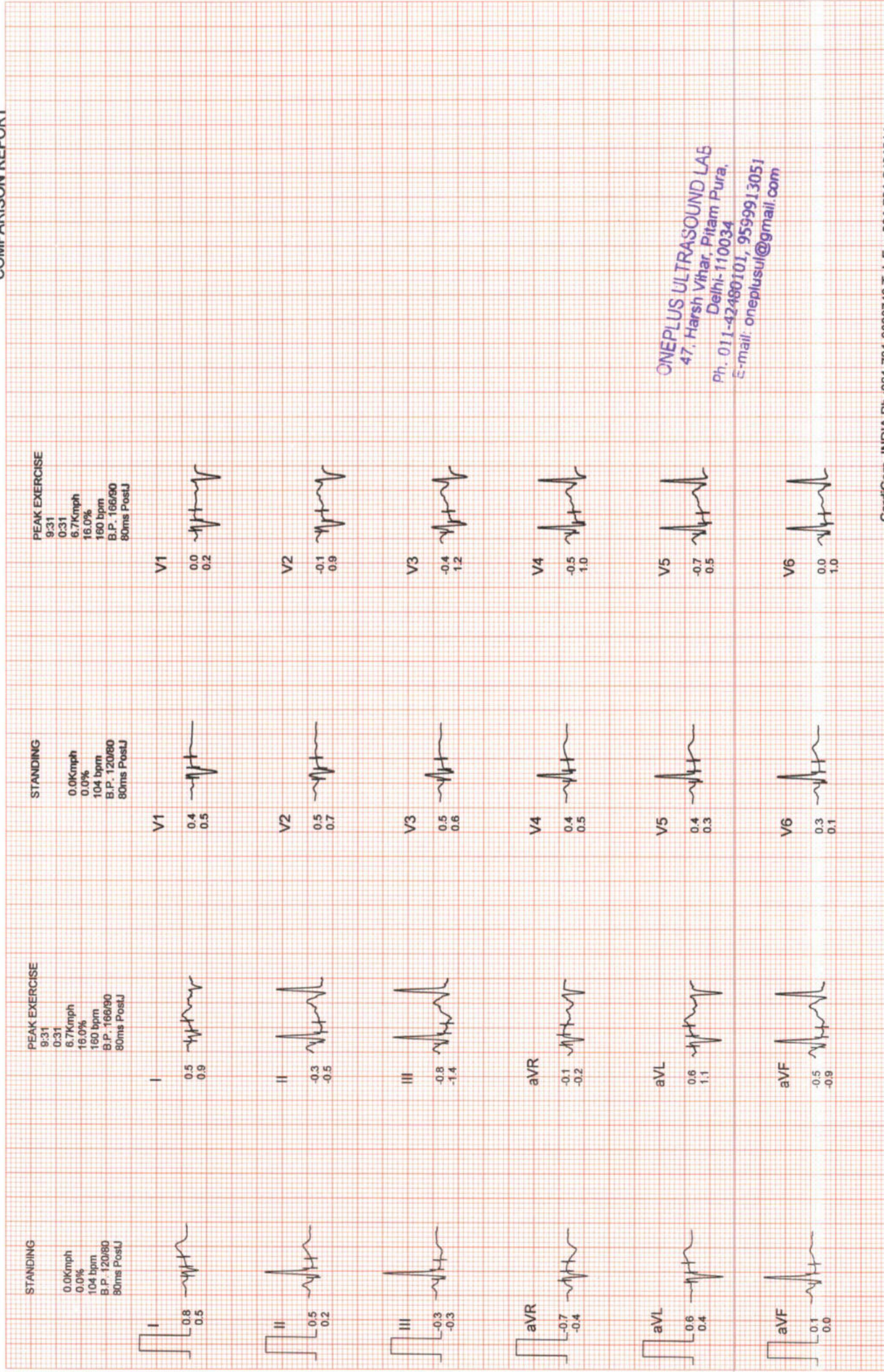
AGE/SEX : 32/F

I.D. : 999

Ms. TANVI

RECORDED : 22-4-2023 9:57

## COMPARISON REPORT



ONEPLUS ULTRASOUND LAB  
47, Harsh Vihar, Pitam Pura,  
Delhi-110034  
Ph. 011-42460101, 9599913051  
E-mail: oneplusul@gmail.com



# OnePLUS Ultrasound Lab

— QUALITY FIRST... ALWAYS! —

**Dr. Nitin Agarwal**  
Pathologist & Director  
Ex. Sr. Res. MAMC  
& Lok Nayak Hospital  
Ex. Chief of Lab Dr. Lal Path Labs.

**Dr. Pooja (Garg) Agarwal**  
Radiologist & Director  
MAMC & Lok Nayak Hospital



NAME	:Mrs. TANVI	Barcode No	:10143125
AGE/GENDER	:32 YRS/Female	SPECIMEN DATE	:22/Apr/2023 09:26AM
PATIENT ID	:113021	SPECIMEN RECEIVED	:22/Apr/2023 09:47AM
REFERRED BY	:Dr. MEDIWHEEL	REPORT DATE	:22/Apr/2023 05:07PM
CENTRE NAME	:ONEPLUS ULTRASOUND LAB	LAB NO.	:012304220016

Test Name	Result	Unit	Ref. Range
-----------	--------	------	------------

## HAEMATOLOGY

### Medi Wheel Health Checkup >40 Female

<b>Glycosylated Hemoglobin (HbA1c)</b>	5.1	%	Non Diabetic adults <5.7 Prediabetic (at risk) 5.7-6.4 Diabetes >6.4
--	-----	---	--

**Estimated average blood glucose (eag)** 100

Reference range (mg/dl):

90 - 120:Excellent control, 121 - 150:Good Control, 151 - 180:Average Control, 181 - 210:Action Suggested

>211:Panic value

**BLOOD GROUP (ABO)** A


**Rh typing** POSITIVE

#### NOTE :

- \* Apart from major A,B,H antigens which are used for ABO grouping and Rh typing, many minor blood group antigens exist. Agglutination may also vary according to titre of antigen and antibody.
- \* So before transfusion, reconfirmation of blood group as well as cross-matching is needed.
- \* Presence of maternal antibodies in newborns, may interfere with blood grouping.
- \* Auto agglutination (due to cold antibody, falciparum malaria, sepsis, internal malignancy etc.) may also cause erroneous result.

Checked By.

Dr. NITIN AGARWAL  
M.B.B.S., MD (Path)  
DMC/R/01436

  
DR. NITIN AGARWAL  
MBBS, MD (PATHOLOGIST)

47, Harsh Vihar, Pitampura, New Delhi-110034 | Ph.: 011-42480101, 9599913051

E-mail: [oneplusul@gmail.com](mailto:oneplusul@gmail.com) | Web.: [www.oneplusul.in](http://www.oneplusul.in)

Page 1 of 5





# OnePLUS Ultrasound Lab

QUALITY FIRST... ALWAYS!

**Dr. Nitin Agarwal**  
Pathologist & Director  
Ex. Sr. Res. MAMC  
& Lok Nayak Hospital  
Ex. Chief of Lab Dr. Lal Path Labs.

**Dr. Pooja (Garg) Agarwal**  
Radiologist & Director  
MAMC & Lok Nayak Hospital



NAME	:Mrs. TANVI	Barcode No	:10143125
AGE/GENDER	:32 YRS/Female	SPECIMEN DATE	:22/Apr/2023 09:26AM
PATIENT ID	:113021	SPECIMEN RECEIVED	:22/Apr/2023 09:47AM
REFERRED BY	:Dr. MEDIWHEEL	REPORT DATE	:22/Apr/2023 11:54AM
CENTRE NAME	:ONEPLUS ULTRASOUND LAB	LAB NO.	:012304220016

Test Name	Result	Unit	Ref. Range
<b>HAEMATOLOGY</b>			
<b>CBC</b>			
Haemoglobin	13.2	g/dl	11.5-15.0
Total Leucocyte Count	8100	/cumm	4000-10000
<b>Differential leucocyte count</b>			
Neutrophils	64.9	%	40-80
Lymphocyte	30.30	%	20-40
Monocytes	2.00	%	2-10
Eosinophils	2.0	%	1-6
Basophils	0.8	%	0-2
RBC Count	4.70	million/cumm	3.8-4.8
PCV(Hematocrit)	43.6	%	36-46
MCV	91.9	fL	83-101
MCH	27.7	Pg	27-32
MCHC	<b>30.2</b>	G/dL	32-35
RDW-CV	13.6	%	11.4-14.0
Platelet count	429000	/cumm	150000-450000
<b>BIOCHEMISTRY</b>			
<b>Blood sugar fasting</b>	83	mg/dL	70-110

Checked By.

Dr. NITIN AGARWAL  
MBBS, MD (Path)  
DMC/R/01436  
DR. NITIN AGARWAL  
MBBS, MD (PATHOLOGIST)

47, Harsh Vihar, Pitampura, New Delhi-110034 | Ph.: 011-42480101, 9599913051

E-mail: [oneplusul@gmail.com](mailto:oneplusul@gmail.com) | Web.: [www.oneplusul.in](http://www.oneplusul.in)

Page 2 of 5

Clinical correlation is essential for final diagnosis. • If test results are unsatisfactory please contact personally or on phone. • This report is for perusal of doctors only. • All disputes Subject to Delhi Jurisdiction only. • Not for medicolegal purposes. • All congenital anomalies in a foetus may not be diagnosed in routine obstetric ultrasound.



# OnePLUS Ultrasound Lab

QUALITY FIRST... ALWAYS!

**Dr. Nitin Agarwal**  
Pathologist & Director  
Ex. Sr. Res. MAMC  
& Lok Nayak Hospital  
Ex. Chief of Lab Dr. Lal Path Labs.

**Dr. Pooja (Garg) Agarwal**  
Radiologist & Director  
MAMC & Lok Nayak Hospital



NAME	:Mrs. TANVI	Barcode No	:10143125
AGE/GENDER	:32 YRS/Female	SPECIMEN DATE	:22/Apr/2023 09:26AM
PATIENT ID	:113021	SPECIMEN RECEIVED	:22/Apr/2023 09:47AM
REFERRED BY	:Dr. MEDIWHEEL	REPORT DATE	:22/Apr/2023 05:07PM
CENTRE NAME	:ONEPLUS ULTRASOUND LAB	LAB NO.	:012304220016

Test Name	Result	Unit	Ref. Range
<b>BIOCHEMISTRY</b>			
<u>Blood sugar pp</u>	114	mg/dL	70.0-140.0
<u>Bun (blood urea nitrogen )</u>	12.60	mg/dl	7-18.7
<u>Uric acid, serum</u>	4.6	mg/dl	2.6-6.0
<u>Creatinine, serum</u>	0.6	mg/dl	0.50-1.0
<b>LFT(LIVER FUNCTION TEST)</b>			
Bilirubin Total	0.65	mg/dl	0.1-1.2
Bilirubin Conjugated	0.25	mg/dl	0-0.4
Bilirubin Unconjugated	0.4	mg/dl	up to 0.7
SGCT (AST)	24	U/L	0-46
SGPT (ALT)	18	U/L	0-49
Alkaline phosphatase	95	U/L	35-104
Gamma glutamyl transpeptidase	28	U/L	5.0-32.0
Total Protein	6.9	gm/dl	6.60 - 8.70
Albumin serum	3.9	g/dL	3.0-5.2
Globulin	3.00	gm/dl	1.8-3.4
Albumin/Globulin Ratio	1.30		1.10 - 2.50
<b>LIPID PROFILE</b>			
Cholesterol	<b>238</b>	mg/dl	50-200
Triglycerides	134	mg/dL	25-150
HDL Cholesterol	45	mg/dL	40 - 60
LDL cholesterol	<b>166</b>	mg/dL	< 130
VLDL cholesterol	26.8	mg/dL	5-40
Cholesterol/HDL Ratio	5.3		Low Risk 3.3-4.97 Average Risk 4.4-7.1 Moderate Risk 7.1-11.0 High Risk >11.0
LDL/HDL Ratio	3.7		0 - 3.55

Checked By.

Dr. NITIN AGARWAL  
MBBS, MD (Path)  
DMC/R/01137  
DR. NITIN AGARWAL  
MBBS, MD (PATHOLOGIST)

47, Harsh Vihar, Pitampura, New Delhi-110034 | Ph.: 011-42480101, 9599913051  
E-mail: oneplusul@gmail.com | Web.: www.oneplusul.in

Page 3 of 5

Clinical correlation is essential for final diagnosis. • If test results are unsatisfactory please contact personally or on phone. • This report is for perusal of doctors only.  
• All disputes Subject to Delhi Jurisdiction only. • Not for medicolegal purposes. • All congenital anomalies in a foetus may not be diagnosed in routine obstetric ultrasound.



# OnePLUS Ultrasound Lab

QUALITY FIRST... ALWAYS!

**Dr. Nitin Agarwal**  
Pathologist & Director  
Ex. Sr. Res. MAMC  
& Lok Nayak Hospital  
Ex. Chief of Lab Dr. Lal Path Labs.

**Dr. Pooja (Garg) Agarwal**  
Radiologist & Director  
MAMC & Lok Nayak Hospital



NAME	:Mrs. TANVI	Barcode No	:10143125
AGE/GENDER	:32 YRS/Female	SPECIMEN DATE	:22/Apr/2023 09:26AM
PATIENT ID	:113021	SPECIMEN RECEIVED	:22/Apr/2023 09:47AM
REFERRED BY	:Dr. MEDIWHEEL	REPORT DATE	:22/Apr/2023 05:07PM
CENTRE NAME	:ONEPLUS ULTRASOUND LAB	LAB NO.	:012304220016

Test Name	Result	Unit	Ref. Range
-----------	--------	------	------------

According to ATP III and NCEP guidelines

Parameter	Normal	Desirable	Borderline	High
Total cholesterol	<200		200-239	240
Triglycerides	<150	150-199	200-499	500
LDL	Optimal <100 Near Optimal 100-129	130-159	160-180	190
HDL	<40 : LOW 60 : HIGH			

### BUN/Creatinine ratio

Bun (blood urea nitrogen )	12.60	mg/dl	7-18.7
CREATININE	0.60	mg/dl	0.30-1.10
BUN/Creatinine ratio	<b>21.00</b>		10.0 - 20.0

### ENDOCRINOLOGY

#### THYROID PROFILE(T3,T4,TSH)

Triiodothyronine total [t3]	0.95	ng/dl	0.52-1.9
Thyroxine total [t4]	7.60	µg/dl	4.8-11.6
TSH (Thyroid Stimulating Hormone)	2.70	µIU/ml	0.25-5.0

#### AGE WISE VARIATION IN TSH

AGE	TSH(µIU/ml)	AGE	TSH(µIU/ml)
1-4 weeks	1.00 - 19.0	16-20 yrs	0.25 - 5.0
1-12 mths	1.70 - 9.1	21 - 80 yrs	0.25 - 5.0
1-5 yrs	0.80 - 8.2	I <sup>st</sup> trimester	0.25 - 5.0
6-10 yrs	0.25 - 5.0	II <sup>nd</sup> trimester	0.50 - 5.0
11-15 yrs	0.25 - 5.0	II <sup>rd</sup> trimester	0.4 - 6.0

Reference ranges - Interpretation of Diagnostic tests - (Jacques Wallach)

Checked By.

Dr. NITIN AGARWAL  
MBBS, MD (Path)  
DMC/R/01436  
DR. NITIN AGARWAL  
MBBS, MD (PATHOLOGIST)

47, Harsh Vihar, Pitampura, New Delhi-110034 | Ph.: 011-42480101, 9599913051  
E-mail: oneplusul@gmail.com | Web.: www.oneplusul.in

Page 4 of 5

Clinical correlation is essential for final diagnosis. \* If test results are unsatisfactory please contact personally or on phone. \* This report is for perusal of doctors only. \* All disputes Subject to Delhi Jurisdiction only. \* Not for medicolegal purposes. \* All congenital anomalies in a foetus may not be diagnosed in routine obstetric ultrasound.



# OnePLUS Ultrasound Lab

QUALITY FIRST... ALWAYS!

**Dr. Nitin Agarwal**

Pathologist & Director  
Ex. Sr. Res. MAMC  
& Lok Nayak Hospital  
Ex. Chief of Lab Dr. Lal Path Labs.

**Dr. Pooja (Garg) Agarwal**

Radiologist & Director  
MAMC & Lok Nayak Hospital



NAME	:Mrs. TANVI	Barcode No	:10143125
AGE/GENDER	:32 YRS/Female	SPECIMEN DATE	:22/Apr/2023 09:26AM
PATIENT ID	:113021	SPECIMEN RECEIVED	:22/Apr/2023 09:47AM
REFERRED BY	:Dr. MEDIWHEEL	REPORT DATE	:22/Apr/2023 05:07PM
CENTRE NAME	:ONEPLUS ULTRASOUND LAB	LAB NO.	:012304220016

Test Name	Result	Unit	Ref. Range
1. Primary hypothyroidism is accompanied by depressed serum T3 and T4 values and elevated serum TSH level.			
2. Primary hyperthyroidism is accompanied by elevated serum T3 and T4 levels along with depressed TSH values.			
3. Slightly elevated T3 levels may be found in pregnancy and estrogen therapy, while depressed levels may be encountered in severe illness, renal failure and during therapy with drugs like propranolol and propyl thiouracil.			
4. Although elevated TSH levels are nearly always indicative of primary hypothyroidism, and may be seen in secondary thyrotoxicosis			

\*\*\* End Of Report \*\*\*

Checked By.

Dr NITIN AGARWAL  
MBBS, MD (Path)  
DR. NITIN AGARWAL  
MBBS, MD (PATHOLOGIST)

47, Harsh Vihar, Pitampura, New Delhi-110034 | Ph.: 011-42480101, 9599913051

E-mail: [oneplusul@gmail.com](mailto:oneplusul@gmail.com) | Web.: [www.oneplusul.in](http://www.oneplusul.in)

Page 5 of 5

Clinical correlation is essential for final diagnosis. • If test results are unsatisfactory please contact personally or on phone. • This report is for perusal of doctors only.  
• All disputes Subject to Delhi Jurisdiction only. • Not for medicolegal purposes. • All congenital anomalies in a foetus may not be diagnosed in routine obstetric ultrasound.



**OnePLUS**  
Ultrasound Lab  
— QUALITY FIRST... ALWAYS! —

**Dr. Nitin Agarwal**  
Pathologist & Director  
Ex. Sr. Res. MAMC  
& Lok Nayak Hospital  
Ex. Chief of Lab Dr. Lal Path Labs.

**Dr. Pooja (Garg) Agarwal**  
Radiologist & Director  
MAMC & Lok Nayak Hospital

<b>Name</b>	: Mrs. TANVI	<b>Age/Sex</b>	: 32 YRS/Female
<b>Ref. By</b>	: Dr. MEDIWHEEL	<b>Lab No</b>	: 012304220016
<b>Date</b>	: 22-Apr-2023	<b>Patient ID</b>	: LSHHI113021

### ULTRASOUND EXAMINATION----WHOLE ABDOMEN

**Liver** is normal in size (13.0 cm) and outline with normal echopattern. Intrahepatic biliary radicles are not dilated. No abscess or mass lesion seen. Hepatic veins, portal vein, IVC and aorta are normal. CBD is normal ( 5.1 mm) in caliber.

**Gall bladder** is well distended with anechoic lumen .Wall thickness is normal.

**Both kidneys** are normal in size, shape, position, outline and echopattern. Corticomedullary differentiation is maintained. No pelvicalyceal dilation or mass lesion is seen.

**Spleen** is normal in size and echotexture. No mass lesion seen.

**Pancreas** is normal in size, outline and echotexture .

**Urinary bladder** is normal in shape and position. No evidence of intravesical stone or mass seen.

**Uterus** is normal in size (measures 7.8 x 3.9 x 4.7 cm), shape, position and echopattern. No mass seen

**Uterine cavity** is empty. Endometrial thickness is 4.7 mm.

**Both ovaries** appear normal in size, shape and echopattern. No tubo-ovarian mass seen.

No abnormal bowel wall thickening seen in right iliac fossa.  
No free fluid seen anywhere in abdomen.

#### **IMPRESSION:**

- Normal study.

**Dr. POOJA GARG**  
M.B.B.S., D.M.R.D.  
Reg No. DM/REG/NO. DMC/R/03398  
Radiologist

Type By : darshita

47, Harsh Vihar, Pitampura, New Delhi-110034 | Ph.: 011-42480101, 9599913051  
E-mail: oneplusul@gmail.com | Web.: www.oneplusul.in

WYENKA MRS TANVI 32W  
 QdPus Ultrasound Lab MI 1.4 22-04-2023  
 CA-7A / Abdomen / FR 20Hz Th 0.1 11:00:08 AM  
 20 Qd3 DR135 F48 P90 Frq Gen: 18.0cm  
 01 0.81 cm

WYENKA MRS TANVI 32W  
 QdPus Ultrasound Lab MI 1.4 22-04-2023  
 CA-7A / Abdomen / FR 20Hz Th 0.1 11:00:12 AM  
 20 Qd3 DR135 F48 P90 Frq Gen: 18.0cm

WYENKA MRS TANVI 32W  
 QdPus Ultrasound Lab MI 1.4 22-04-2023  
 CA-7A / Abdomen / FR 20Hz Th 0.1 11:00:24 AM  
 20 Qd3 DR135 F48 P90 Frq Gen: 18.0cm  
 01 7.78 cm  
 02 3.93 cm  
 03 4.88 cm

WYENKA MRS TANVI 32W  
 QdPus Ultrasound Lab MI 1.4 22-04-2023  
 CA-7A / Abdomen / FR 20Hz Th 0.1 11:00:35 AM  
 20 Qd3 DR135 F48 P90 Frq Gen: 18.0cm  
 01 0.47 cm

WYENKA MRS TANVI 32W  
 QdPus Ultrasound Lab MI 1.4 22-04-2023  
 CA-7A / Abdomen / FR 20Hz Th 0.1 11:00:49 AM  
 20 Qd3 DR135 F48 P90 Frq Gen: 18.0cm

WYENKA MRS TANVI 32W  
 QdPus Ultrasound Lab MI 1.4 22-04-2023  
 CA-7A / Abdomen / FR 20Hz Th 0.1 11:00:54 AM  
 20 Qd3 DR135 F48 P90 Frq Gen: 18.0cm

WYENKA MRS TANVI 32W  
 QdPus Ultrasound Lab MI 1.4 22-04-2023  
 CA-7A / Abdomen / FR 20Hz Th 0.1 11:01:11 AM  
 20 Qd3 DR135 F48 P90 Frq Gen: 18.0cm  
 01 33.03 cm

WYENKA MRS TANVI 32W  
 QdPus Ultrasound Lab MI 1.4 22-04-2023  
 CA-7A / Abdomen / FR 20Hz Th 0.1 11:01:18 AM

WYENKA MRS TANVI 32W  
 QdPus Ultrasound Lab MI 1.4 22-04-2023  
 CA-7A / Abdomen / FR 20Hz Th 0.1 11:01:28 AM  
 20 Qd3 DR135 F48 P90 Frq Gen: 18.0cm



Fig. 1. *Phlox subulata* L. (1) - leaf; (2) - petal; (3) - sepal; (4) - stamen; (5) - pistil; (6) - fruit.



Fig. 2. *Phlox subulata* L. (1) - leaf; (2) - petal; (3) - sepal; (4) - stamen; (5) - pistil; (6) - fruit.



Fig. 3. *Phlox subulata* L. (1) - leaf; (2) - petal; (3) - sepal; (4) - stamen; (5) - pistil; (6) - fruit.



Fig. 4. *Phlox subulata* L. (1) - leaf; (2) - petal; (3) - sepal; (4) - stamen; (5) - pistil; (6) - fruit.



Fig. 5. *Phlox subulata* L. (1) - leaf; (2) - petal; (3) - sepal; (4) - stamen; (5) - pistil; (6) - fruit.



Fig. 6. *Phlox subulata* L. (1) - leaf; (2) - petal; (3) - sepal; (4) - stamen; (5) - pistil; (6) - fruit.



Fig. 7. *Phlox subulata* L. (1) - leaf; (2) - petal; (3) - sepal; (4) - stamen; (5) - pistil; (6) - fruit.




Fig. 8. *Phlox subulata* L. (1) - leaf; (2) - petal; (3) - sepal; (4) - stamen; (5) - pistil; (6) - fruit.



Fig. 9. *Phlox subulata* L. (1) - leaf; (2) - petal; (3) - sepal; (4) - stamen; (5) - pistil; (6) - fruit.

ИЗДАТЕЛЬСТВО «НАУКА»



**OnePLUS**  
Ultrasound Lab

— QUALITY FIRST... ALWAYS! —

**Dr. Nitin Agarwal**

Pathologist & Director  
Ex. Sr. Res. MAMC  
& Lok Nayak Hospital  
Ex. Chief of Lab Dr. Lal Path Labs.

**Dr. Pooja (Garg) Agarwal**

Radiologist & Director  
MAMC & Lok Nayak Hospital

Name	: Mrs. TANVI	Age/Sex	: 32 YRS/Female
Ref. By	: Dr. MEDIWHEEL	Lab No	: 012304220016
Date	: 22-Apr-2023	Patient ID	: LSHHI113021

### X-ray-Chest PA view

Note is made of bilateral cervical ribs.

Bony cage and soft tissues are normal.

Cardiothoracic ratio is normal.

Mediastinum is normal.

Both hila are normal.

Both costophrenic angles are clear.

Both domes of diaphragm are normal.

Lung fields are clear. No parenchymal lesion seen.

Please correlate clinically

Dr. POOJA GARG  
M.B.B.S. D.M.R.D.  
Reg No. DMC/RADIOLOGIST  
REG NO. DMC/R/03398

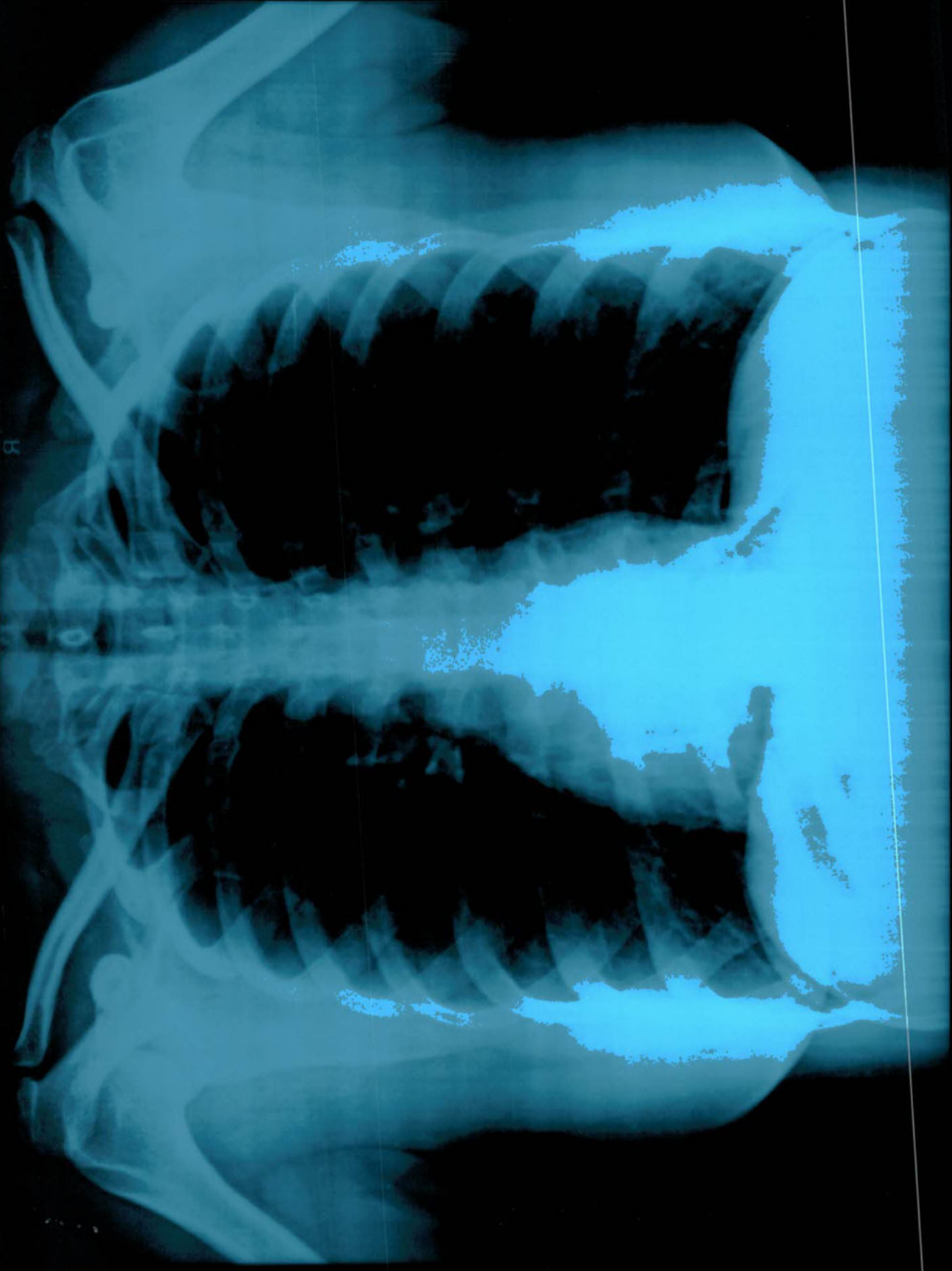
Type By : darshita

47, Harsh Vihar, Pitampura, New Delhi-110034 | Ph.: 011-42480101, 9599913051  
E-mail: oneplusul@gmail.com | Web.: www.oneplusul.in

Clinical correlation is essential for final diagnosis. • If test results are unsatisfactory please contact personally or on phone. • This report is for perusal of doctors only.  
• All disputes Subject to Delhi Jurisdiction only. • Not for medicolegal purposes. • All congenital anomalies in a foetus may not be diagnosed in routine obstetric ultrasound.

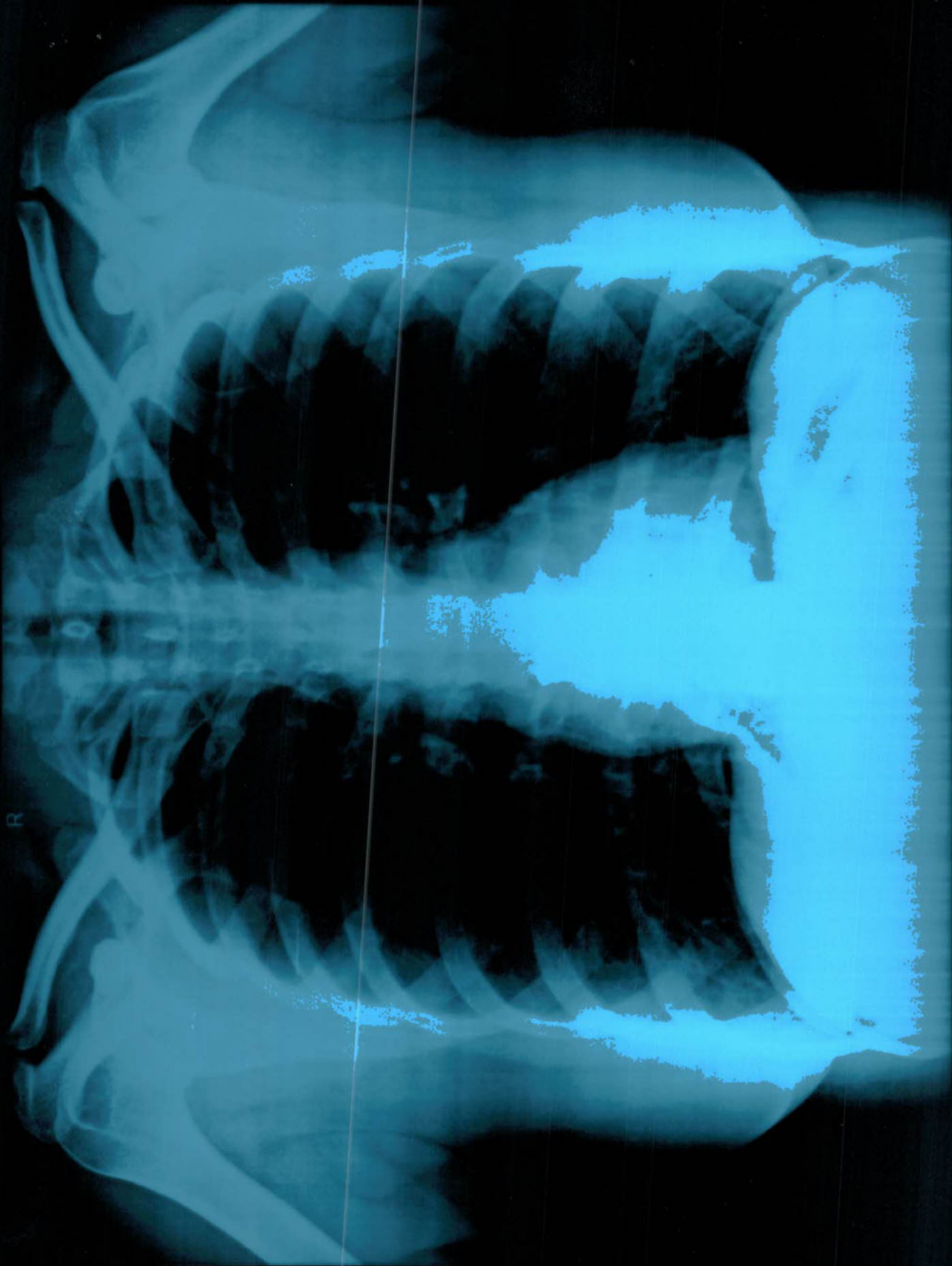


CHEST PA VIEW  
MRS TANVI 35 YRS 5510415053 F CHEST PA VIEW 415515053



R

R



MRS TANVI 32 YRS 22/04/2023 F CHEST PA VIEW 4/22/2023

ONEPLUS UI TRASOUND LAB 47 HARSH VIHAR PITAMPURA