



MAHARAJA SPECIALITY HOSPITAL

Diabetes Multi Speciality, Dialysis, Emergency & Critical Care Centre

78-C, Mohanur Main Road, Namakkal - 637 001.

Phone : 04286-234620 / 234640

E-mail : maharajadiacare@gmail.com

MAHARAJA SCAN CENTRE

ULTRASOUND REPORT

PATIENT NAME : MR. DHINESH BABU AGE / SEX : 39 / M

REFEERED BY : DR. A.P. SUABRAMANIAM, M.D.FCCP. FRSH (Lon), PG. DIP. DIA CARE (AUS),

DATE : 14.08.2021

LIVER : Normal in size and echo pattern normal. Intrahepatic biliary radicles are not dilated.
No mass or abscess seen. CBD and Portal vein normal.

GALL BLADDER : Normal.

PANCREAS : Normal in thickness and echo pattern. No fluid collection seen around the pancreas.
main pancreatic duct normal.

SPLEEN : Size 9.4 cm. Normal in size and echo pattern. No mass or cyst seen.

RIGHT KIDNEY : Size 11.2x4.8 cm. Normal in size and echo pattern. No mass or calculus seen.
Cortico medullary differentiation clearly made out.

LEFT KIDNEY : Size 11.2x4.8 cm. Normal in size and echo pattern. No mass or calculus seen.
Cortico medullary differentiation clearly made out.

PERITONEUM : No mass or fluid collection seen.

PLEURAL CAVITY : No fluid collection seen.

PROSTATE : Normal in size and echoes.

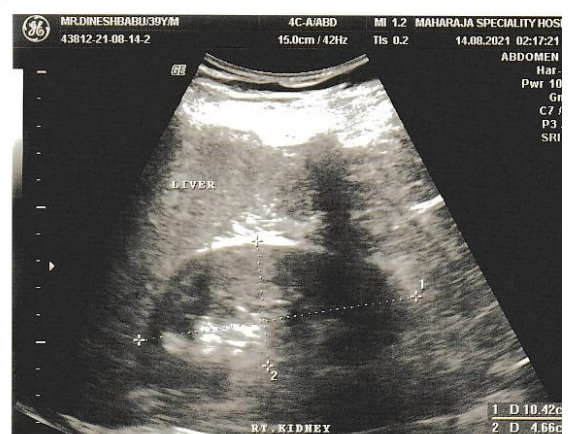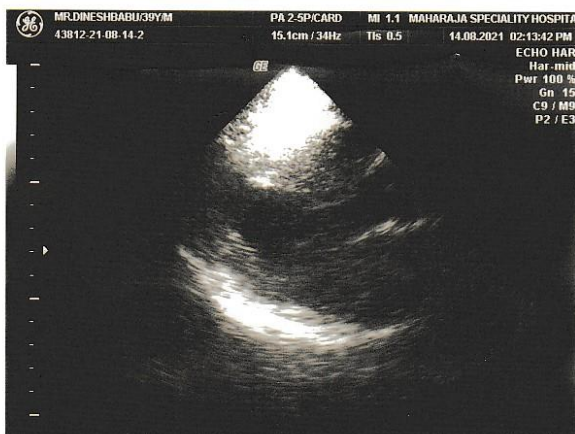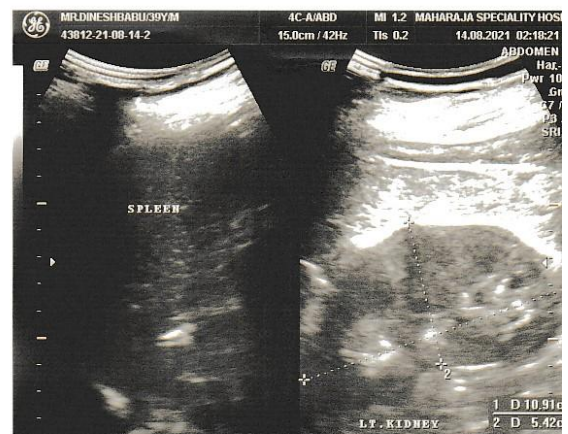
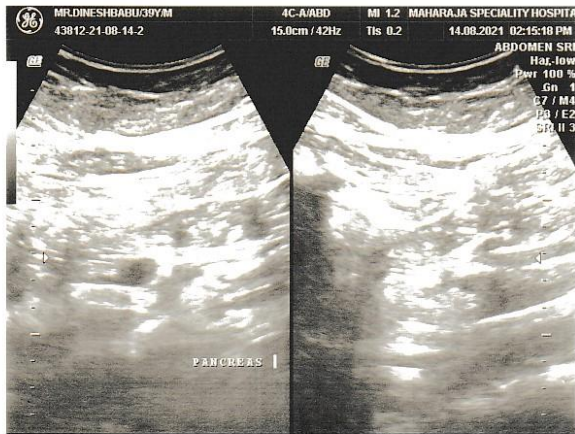
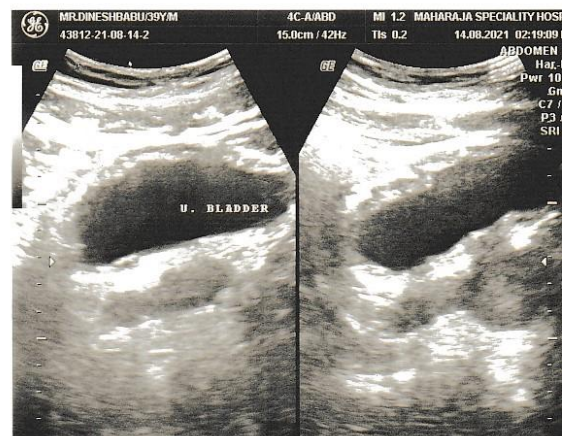
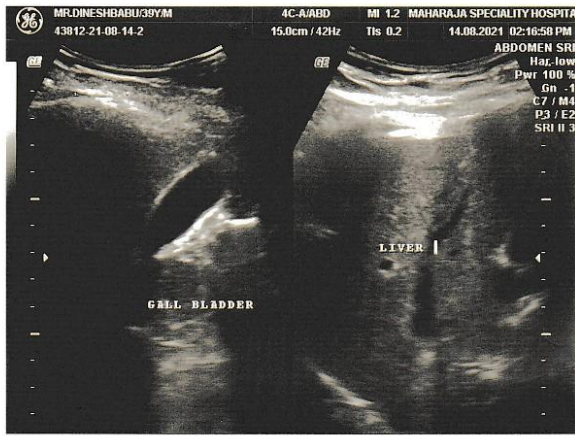
BLADDER : Normal in contour. No mass or calculus seen.

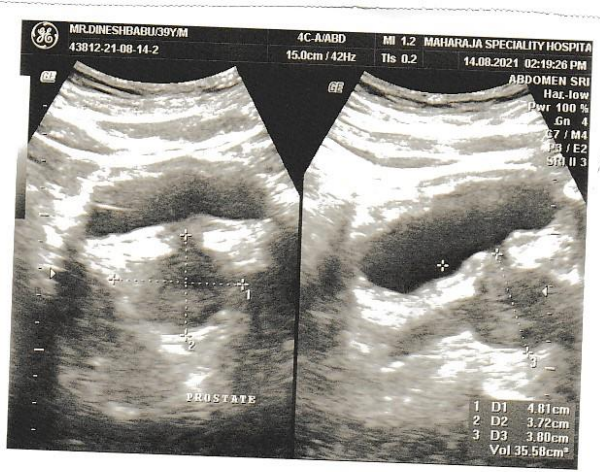
IMPRESSION : NORMAL STUDY


DR.A.P. SUBRAMANIAM, M.D., FCCP, FRSH (LON), PG. DIP. DIA CARE (AUS),

Consultant Physician & Gastrodiabetologist.

DR. A.P. SUBRAMANIAM, M.D. (GEN. MED.)
FCCP, FRSH (LON), PG. DIP. DIACARE (AUSTRALIA)
MAHARAJA SPECIALITY HOSPITAL
Diabetes Multi Speciality, Dialysis, Emergency & Critical Care Centre
Regd. No. 47815
CONSULTANT PHYSICIAN AND GASTRO DIABETOLOGIST
78-C, Mohanur Main Road,
Namakkal - 637 001
Ph : 04286-234620, 234640







MAHARAJA SPECIALITY HOSPITAL

Diabetes Multi Speciality, Dialysis, Emergency & Critical Care Centre

78-C, Mohanur Main Road, Namakkal - 637 001.

Phone : 04286-234620 / 234640

E-mail : maharajadiacare@gmail.com

MAHARAJA SCAN CENTRE

Patient Name : MR. DINESH BABU Age : 39 yrs/Male Date : 14.08.2021

Ref.by : DR. A.P. SUBRAMANIAM. MD., FCCP. FRSH (LON) ., PG. DIP. DIA CARE (AUS),.

ECHOCARDIOGRAM

M-MODE ECHO

LVID d : 44 mm
LVID s : 32 mm
Ejection fraction : >70 %
IVS d : 08 mm
Left Atrium : 36 mm
Aortic root : 23 mm

2D ECHO COLOR FLOW INTERPRETATION

CHAMBERS

Right Atrium : Normal
Left Atrium : Dilated
Right Ventricle : Normal
Left Ventricle : Normal size of LV / Good LV function
No Regional wall motion abnormalities present EF >70%

SEPTUM

IVS : Intact
IAS : Intact
Mitral : Normal
Aortic : Normal
Tricuspid : Normal
GREAT VESSELS : Normal
PERICARDIUM : Normal

DOPPLER ECHO MEASUREMENTS

Mitral valve Velocity : Normal
E/A Ratio : Normal
Pulmonary valve velocity : Normal
Pulmonary Hypertension : Nil
LV Diastolic dysfunction : Normal

IMPRESSION

Normal size of LV / Good Lv Function

No Regional wall motion abnormalities present

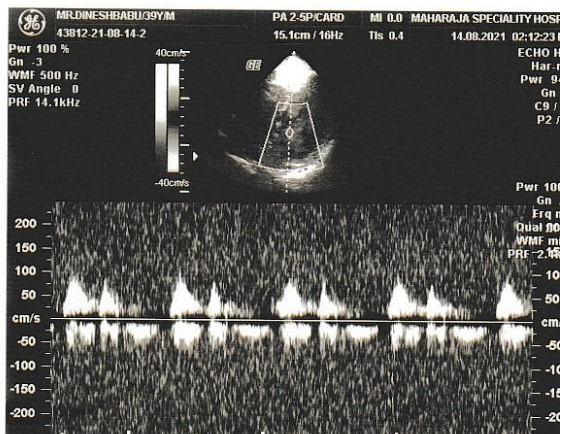
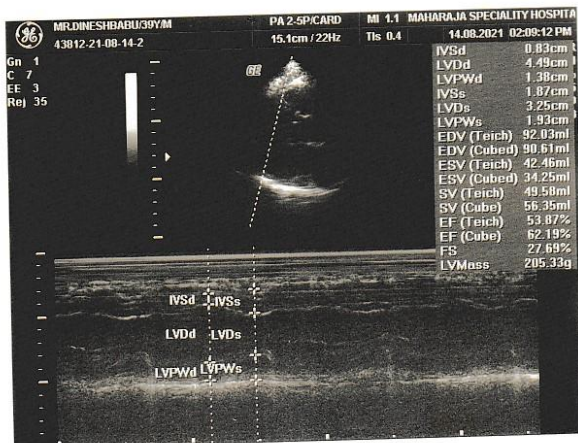
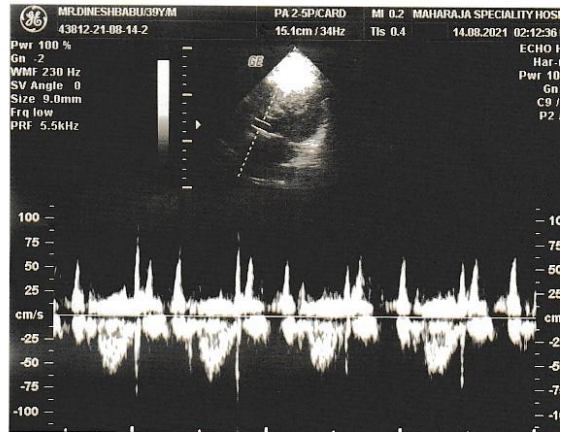
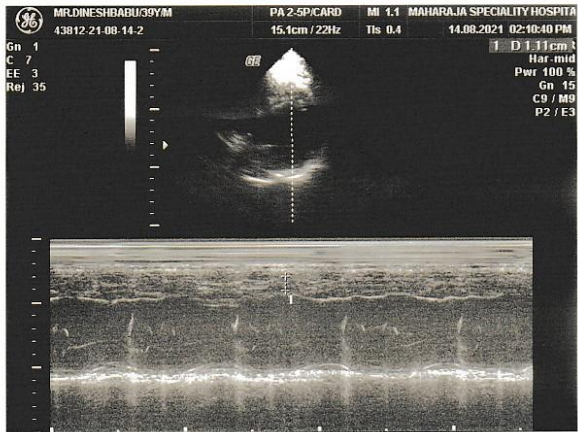
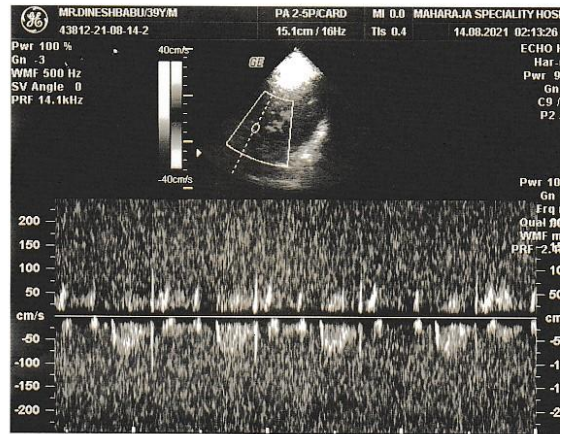
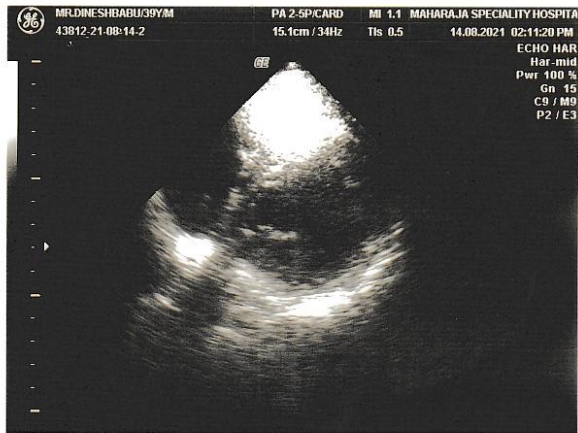Ejection Fraction > 70 %

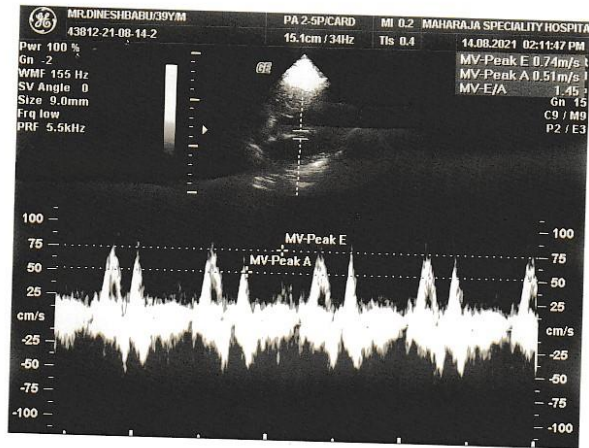
No Thrombus
No Pericardial Effusion
No Pulmonary Hypertension
Normal Chambers

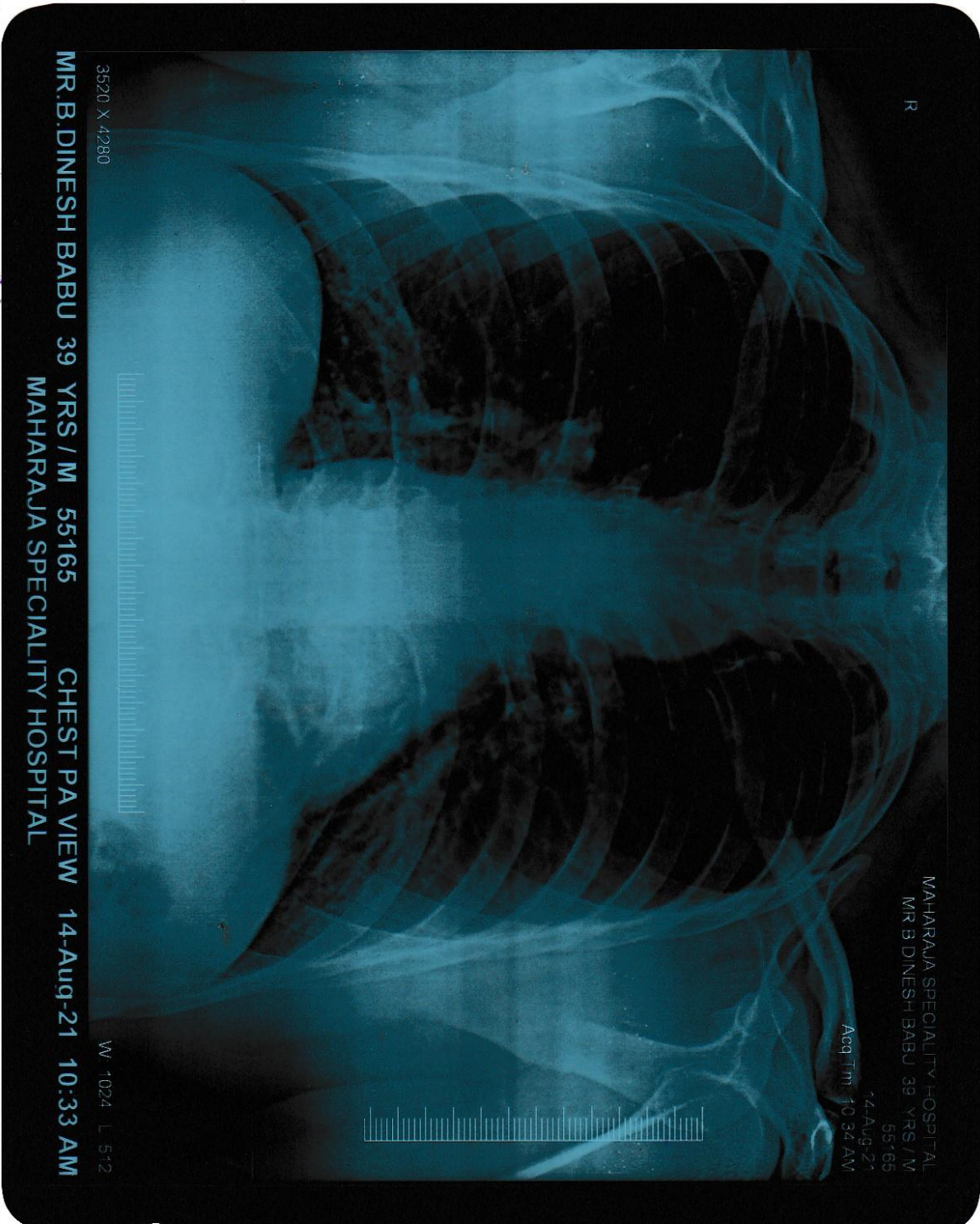
NORMAL STUDY

**DR.A.P.SUBRAMANIAM M.D., (gen.Med) F.C.CP.,F.R.S.H.,(London),PG Dip.dia care
(Australia) CONSULTANT PHYSICIAN AND CARDI DIABETOLOGIST**

Dr.A.P. SUBRAMANIAM, M.D.(GEN.MED)
FCCP, FRSH(LOND), PG.DIP DIABETE (AUSTRALIA)
MAHARAJA SPECIALITY HOSPITAL,
Diabetes & Endocrinology, Diabetes, Endocrinology & Nutrition Centre
Regd.No. 47401,
CONSULTANT PHYSICIAN AND CARDI DIABETOLOGIST
76-C Mohanur Mem Road,
Namakkal - 637 001
Ph : 04286-234620, 234640







R

MAHARAJA SPECIALITY HOSPITAL
MR B DINESH BABU 39 YRS / M
55-65
14-AUG-21
Acq Tm: 10:34 AM

3520 X 4280

MR.B.DINESH BABU 39 YRS / M 55165 CHEST PA VIEW 14-AUG-21 10:33 AM
MAHARAJA SPECIALITY HOSPITAL

W 1024 L 512