



# PARKLINE DIAGNOSTICS PVT. LTD.

L.G. 3, 4 & 5, Bhuvana Towers, S.D. Road, Secunderabad - 500 003.

Tel : +91 40-2784 5852, 6649 1787, 7995421787, 7093445852, Fax : +91 40 2784 7864

Email parklinediagnostics@gmail.com www.parklinediagnostics.com



NABL Accredited  
Certificate No.MC-2566

## MEDICAL EXAMINATION REPORT

Name	MS. Nair Bukya pranjna		Date :	26/03/2022		
Company	clo: mediwheel		Reg. No. :	1907297		
Contact No.	7625024984		Sex	<input type="checkbox"/> M <input checked="" type="checkbox"/> F	Age :	<input type="checkbox"/> 25 <input checked="" type="checkbox"/> 26
Type	Pre-Emp		Emp. No.:	166565		
	Overseas		Height	157 cm		
	Annual	<input checked="" type="checkbox"/>	Weight	80 kgs.		
Remarks	<p>HbA<sub>1c</sub> - 6.4% - Advice follow up on prediabetic state.</p> <p>- Rest all clinical &amp; Lab parameters within (N) limits.</p> <p>DR. PRIYANKA SANNIDHI MBBS Regn. No : 11351</p>					
Fitness Status	Medically Fit / Unfit		Physician's Signature			

# COMPREHENSIVE MEDICAL EXAMINATION REPORT

NAME Ms. Naik Buby Pravithe  
 AGE 36 yrs / Female  
 MARITAL STATUS Married CHILDREN : M  F   
 IDENTIFICATION (IF ANY) A mole on the Rt upper lip

## PAST HISTORY

Any family H/o : High Blood Pressure, Heart Disease, Tuberculosis, Diabetes, Asthma, Cancer

Both parents  Father  Mother  Both parents

Any personal H/o Major illness like : Typhoid..... NIL Jaundice..... NIL Etc.

Any H/o STD..... NIL Skin infection..... NIL  
 H/o Blood Transfusion..... NIL Recent Vaccination..... COVASHIELD 2 Doses ✓  
 H/o Epilepsy..... NIL Giddiness..... NIL  
 H/o Surgery..... 2 CSES Fracture in the past..... NIL  
2013, 2016

### Any Personal H/O.

High Blood Pressure, Heart Disease Tuberculosis, Diabetes, Asthma, Cancer

Drug Abuse, Drug Allergy, Micturition, Bowels, Alcohol, Smoking, Sleep, MC, Wt. Loss/Wt. Gain

Present illness / Medication T. METFORMIN 0.5/800mg

## GENERAL EXAMINATION

Conjunctiva :  
 Skin :  
 Ears :  
 Nose :  
 Throat & Oral Cavity :

Bone, Joints : (N)  
 Nutritional Status : well Nourished  
 Lymph Nodes : NPD  
 Edema Feet : NIL  
 Varicose Veins : NIL

**Distant Vision : Near Vision :**

Right Eye: 6/6

With glasses / Without glasses

left Eye : 6/6

with glasses / without glasses

Colour Vision : normal

**Right Ear**

Hearing : (N)

Rinne's Test ;

Weber Test :

Discharge : NIL

Right Eye: NG

With glasses / Without glasses

left Eye : NG

with glasses / without glasses

**Ophthalmologist's Signature**

**Left Ear**

(N)

NIL

**SYSTEMIC EXAMINATION**

Pulse :

B.P. :

Lungs : A. Shape of Chest  
B. Breath Sounds  
C. Adventitious Sounds

Bl symmetrical  
Bl clear ⊕

Heart : A. Sounds  
B. Murmurs

Bl S<sub>1</sub> S<sub>2</sub> ⊕  
N. murmur

**Nervous System**

Abdomen : A. Liver NPD  
B. Spleen NPD  
C. Piles NIL  
D. Any Lump NIL

A. Higher Function :  
B. Cranial Nerves :  
C. Sensory System :  
D. Motor System :  
E. Jerks :

(N)

General : A. Hernia  
B. Hydrocele  
C. Varicocele

(NPD)

Breast :

Rt

(N)

Lt.


(N)

## CANDIDATE'S DECLARATION

I hereby solemnly declare that I am not suffering from Asthma, Hypertension, Diabetes, Occult Psychological disorders or any other ailment which can be suppressed without my voluntary declaration.

Date :

Signature



Place :

Note : General Physical Examination and Investigation included in the health check-up Have certain limitations and may not be able to detect all latent and asymptomatic diseases. Any new symptoms developing after the health check-up or persisting thereafter should be brought to the attention of the treating physician.



# PARKLINE DIAGNOSTICS PVT. LTD.

L.G. 3, 4 & 5, Bhuvana Towers, S.D. Road, Secunderabad - 500 003. Tel : +91 40-2784 5852, 6649 1787, 7995421787,  
7093445852, Fax : +91 40 2784 7864 Email parklinediagnostics@gmail.com www.parklinediagnostics.com



NABL Accredited  
Certificate No.MC-2566

## ENT CONSULTATION

S.No. 1907297      Emp.No. 166565      Date 26/3/22  
 Name MS. Nair Bukya      Age 36 Yrs      Sex M/F ✓  
 pranita

**EARS :**

	Right	Left
EAC	: patent no Cerumen	- do.
TM	: Patent, pearly white Cone of light (+)	- do.
TFT	: Rinne's +ve	: Rinne's +ve, Weber's - central

**NOSE :** Septum (+). Bil. T's superior (+). Pns (+). non-tender

**THROAT :** Oropharynx (+). Bil. v. c's (+) moving  
Arytenoid bil.

**NECK :** (+)

**IMPRESSION:** ENT clinically NAD.


Dr. D. Anil Krishna Reddy  
 MS (ENT)  
 Head & Neck Surgeon  
 Reg. No: 88379

7799686970


Name : Pranitha ..... Sex : F ..... Age : 36 .....

Date : 26/3/22 .....

OPD No : 535 .....

occlusal pits in 

to

Adler. Rest in 

  
**Smilesss**   
MULTI SPECIALITY DENTAL CLINIC  
*Smile Confidentially... Not Confidentially...*  
B.D.S. IMPLANTOLOGIST (USA)  
Bajamudali, K. V. Subbanna

--	--	--	--	--	--

--	--	--	--	--	--



# PARKLINE DIAGNOSTICS PVT. LTD.

L.G 3, 4 & 5, Bhuvana Towers, Sarojini Devi Road, Secunderabad - 500 003.  
Tel. +91 40 2784 5852, 6649 1787, 77995421787, 7093445852, Fax : + 91 40 2784 7864  
Email : parklinediagnostics@gmail.com, www.parklinediagnostics.com



NABL Accredited  
Certificate No.: MC-2566

## TEST REPORT

Name : Ms . NAIK BUKYA PRANITHA [166565]  
Age / Gender : 36 Years / Female  
Ref.By : Medi Wheel  
Req. No : BIL1907297

TID : UMR0752990  
Registered on : 26-Mar-2022 08:36 AM  
Reported On : 26-Mar-2022 01:19 PM

### ABDOMINO-PELVIC ULTRASONOGRAPHY

**LIVER** is normal shape, size ( 15.5 cms) and has uniform echopattern.  
No evidence of focal lesion or intrahepatic biliary ductal dilatation.  
Hepatic and portal vein radicals are normal.

**GALL BLADDER** shows normal shape and has clear contents.  
Gall bladder wall is of normal thickness. CBD is of normal calibre.

**PANCREAS** has normal shape, size and uniform echopattern.  
No evidence of ductal dilatation or calcification.

**SPLEEN** shows normal shape, size and echopattern.

**KIDNEYS** move well with respiration and have normal shape, size and echopattern.  
Cortico- medullary differentiations are well madeout.  
No evidence of calculus or hydronephrosis.  
Right kidney measures: 10.3 x 4.7 cms, Left kidney measures: 10.4 x 5.3 cms.

**URINARY BLADDER** shows normal shape and wall thickness.  
It has clear contents. No evidence of diverticula.

**UTERUS** is anteverted has normal shape and size.  
It has uniform myometrial echopattern.  
Endometrial echo is of normal thickness 7.2 mm.  
Uterus measures 8.8 x 4.5 x 5.1 cms.

**OVARIES** are normal in size, shape and echotexture.  
Right ovary: 2.4 x 2.3 cms, Left ovary: 2.7 x 1.5 cms.

No evidence of free fluid in the abdomen and pelvis.

**IMPRESSION:** \* Grade I Fatty liver.

Suggested clinical correlation and follow up

*for Dr. Abid Yazden*  
Dr. Abid Yazden  
Consultant Radiologist

The Test marked with\*are not accredited by NABL

Lab Timings (Weekdays) : 7.00 am to 8.30 pm  
Sundays & Holidays : 7.00 am to 1.00 pm

Radiologists Timings (Weekdays) : 7.30 am to 1.30 pm  
& 5.30 pm to 7.45 pm  
Sundays & Holidays : 7.30 am to 9.30 am



# PARKLINE DIAGNOSTICS PVT. LTD.

L.G 3, 4 & 5, Bhuvana Towers, Sarojini Devi Road, Secunderabad - 500 003.  
Tel. +91 40 2784 5852, 6649 1787, 77995421787, 7093445852, Fax : + 91 40 2784 7864  
Email : parklinediagnostics@gmail.com, www.parklinediagnostics.com



NABL Accredited  
Certificate No.: MC-2566

## TEST REPORT

Name	: Ms . NAIK BUKYA PRANITHA [166565]	TID	: UMR0752990
Age / Gender	: 36 Years / Female	Registered on	: 26-Mar-2022 08:36 AM
Ref.By	: Medi Wheel	Reported On	: 26-Mar-2022 10:10 AM
Req. No	: BIL1907297		

### X-RAY CHEST PA VIEW

Lung fields are clear.

Cardia is normal.

Hila are normal.


C P angles are free.

Bony cage is normal.

Soft tissues are normal.

IMPRESSION : NORMAL CHEST X-RAY



  
Dr. D.J. MOHAN  
MD DMRD  
(Reg No. 8995)  
Consultant Radiologist

The Test marked with\*are not accredited by NABL

Lab Timings (Weekdays) : 7.00 am to 8.30 pm  
Sundays & Holidays : 7.00 am to 1.00 pm

Radiologists Timings (Weekdays) : 7.30 am to 1.30 pm  
& 5.30 pm to 7.45 pm  
Sundays & Holidays : 7.30 am to 9.30 am



ID: 190/29/

26-03-2022 09:15:50 AM

CARDIART

MS.NAIK BUKYA PRANITHA

Female 36Years

HR : 74 bpm  
P : 120 ms  
PR : 176 ms  
QRS : 96 ms  
QT/QTc : 384/429 ms  
P/QRS/T : 49/26/20 °  
RV5/SV1 : 0.985/0.654 mV

Diagnosis Information:  
Sinus Rhythm  
Flattened T Wave(V4)

TUV-V3

WNL

Dr. NAVEEN KUMAR .C

M.D., D.M.

Consultant Cardiologist

Reg. No. 52291

Report Confirmed by:

**REAL TIME ECG REPORT**

**PATIENT SUMMARY REPORT**

022, 10:11:

**RKLINE DIAGNOSTICS PVT.LTD**

: 1907297  
ME : **MS NAIK BUKYA PRANITHA**  
E / SEX : 36 / FEMALE

HEIGHT (cm) : 157  
WEIGHT (kg) : 80  
PROTOCOL : BRUCE

REF. BY : MEDIWHEEL  
DONE BY : DR NAVEEN KUMAR C  
TECHNICIAN : G.M.SURESH

SE HISTORY

ICATION

ECT OF TEST : Routine Check Up.

CFACTOR : Diabetes.

IVITY : Very Active.

ER INVESTIGATION : ECG

SON FOR TERMINATION : THR ACHIEVED

RCISE TOLERANCE : Good (> 10 METS).

RCISE INDUCED ARRHYTHMIAS : No.

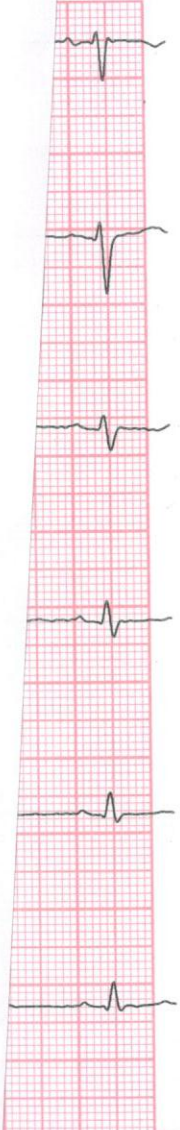
MO RESPONSE : Normal.

NO RESPONSE : Normal.

- IMPRESSION

*Negative for inducible ischemia*

COMMENTS



**Dr. NAVEEN KUMAR .C**  
M.D., D.M.  
Consultant Cardiologist  
Reg. No. 52291

Confirmed By :

Sec