



Bangalore Diagnostics & Multi-Speciality Centre

Quality Assurance : EQAP from AIIMS & CMC- Vellore


Quality. Trust. Since 1982.

198, 12th Main, 3rd Block, (Above Namma MTR, Next to SBI), Rajajinagar, Bangalore- 560 010.
Ph. : 080-23505407, 9448079978 e-mail : bangalore.d.s@gmail.com

SUMMARY REPORT

NAME ::	mes. Puttarangamma. G
EMPLOYEE ID::	PKL-10000251
REF.BY::	Banra J. Baroda.
AGE::	51/years
GENDER::	Female
DATE::	25/12/2021
HEIGHT (in mts)::	1.41
WEIGHT (in kgs)::	82
BMI::	41.2
WAIST CIRCUMFERENCE (in cms)::	110
HIP CIRCUMFERENCE (in cms)::	115
WAIST TO HIP RATIO::	0.95:1.0
BLOOD PRESSURE (mm hg)::	140/90 mmHg

BANGALORE DIAGNOSTICS &
MULTI-SPECIALITY CENTRE
198, 12th Main, 3rd Block
Rajajinagar, Bangalore-560 010


Dr. MAHADEVA. K.C.
M.D., (Path)
KMC. No.: 17647



ಭಾರತೀಯ ವಿಶಿಷ್ಟ ಗುರುತು ಪ್ರಾಧಿಕಾರ

ಭಾರತ ಸರ್ಕಾರ

Government of India


ನೋಂದಾವಣೆ ಕ್ರಮ ಸಂಖ್ಯೆ / Enrollment No. : 2017/78213/80217

To
Puttarangamma G
ಪುತ್ತರಂಗಮ್ಮ, ಜಿ
C/O S Nagaraj
No 38
5th Cross
Opposite Mannapuram Gold Loan
Srinivasa Nagar, Pattengarapalya
Bangalore North
Nagarbhavi, Bangalore North, Bengaluru,
Karnataka - 560072
9972972918

06/12/2011
80819252



KA808192524FH



ನಿಮ್ಮ ಆಧಾರ್ ಸಂಖ್ಯೆ / Your Aadhaar No. :

5149 0470 8219

ನನ್ನ ಆಧಾರ್, ನನ್ನ ಗುರುತು



ಭಾರತ ಸರ್ಕಾರ
Government of India



ಪುತ್ತರಂಗಮ್ಮ, ಜಿ
Puttarangamma G
ಜನ್ಮ ದಿನಾಂಕ / DOB: 05/11/1970
ಸ್ತ್ರೀ / Female



5149 0470 8219

ನನ್ನ ಆಧಾರ್, ನನ್ನ ಗುರುತು

BANGALORE DIAGNOSTICS &
MULTI-SPECIALITY CENTRE
193, 12th Main, 3rd Block
Rajajinagar, Bangalore-560 010



Bangalore Diagnostics & Multi-Speciality Centre

Quality Assurance : EQAP from AIIMS & CMC- Vellore

Quality Trust. Since 1982.

198, 12th Main, 3rd Block, (Above Namma MTR, Next to SBI), Rajajinagar, Bangalore- 560 010.
Ph. : 080-23505407, 9448079978 e-mail : bangalore.d.s@gmail.com

Name : MRS. PUTTARANGAMMA G

Reg. No : C6553

Age/Sex: 51 Year(s) / Female

Date : 25/12/2021

Ref. by : DR. BANK OF BARODA

Corporate: NON CORPORATE

Test Name

Result

Reference Range

Page 1 of 3

HAEMATOLOGY REPORT

COMPLETE BLOOD COUNT

Haemoglobin	14.7 gms %	Male : 13.0 - 18.0 gms % Female: 11.0 - 15.0 gms %
Red Blood Cell Count	5.20 million/cumm	Male : 4.5-6.5 millions/cumm Female : 3.7-5.5 million/cumr

Packed Cell Volume	45.0 %	Females: 32 - 45 % Males: 39 - 54%
Total Count	9,200 cells /cumm	4000-11000 cells /cumm

Differential Count

Neutrophils	62.4 %	40 - 75%
Lymphocytes	30.4 %	20 - 45%
Monocytes	4.5 %	01 - 10%
Eosinophils	2.5 %	01 - 06 %
Basophils	0.2 %	00 to 01 %

COMPLETE BLOOD COUNT

Platelet count	2,69,000 cells/cumm	150000-400000 cells/cumm
Mean Corpuscular Volume	87 fL	78 - 98 fL
Mean Corpuscular Haemoglobin	28.3 pg	27 - 32 pg
Mean Corpuscular Haemoglobin Concentration	32.8 g/dl	31 - 36 g/dl
ESR	07 mm/hour	Male: 0 - 10 mm/ hour Female: 0 - 20 mm/hour

ABSOLUTE EOSINOPHIL COUNT	231 cells/cumm	40 - 440 cells/cumm
---------------------------	----------------	---------------------

BLOOD GROUP(ABO)	"O"
Rh Type (D)	POSITIVE

BIOCHEMISTRY REPORT

FASTING BLOOD SUGAR	337 mg/dl	70 to 100 mg/dl
FASTING URINE SUGAR	2.0%	NIL

Dr. MAHADEVA. K.C.
M.D., (Path)
KMC. No.: 17647



Bangalore Diagnostics & Multi-Speciality Centre

Quality Assurance : EQAP from AIIMS & CMC- Vellore

Quality. Trust. Since 1982.

198, 12th Main, 3rd Block, (Above Namma MTR, Next to SBI), Rajajinagar, Bangalore- 560 010.
Ph. : 080-23505407, 9448079978 e-mail : bangalore.d.s@gmail.com

Name : MRS. PUTTARANGAMMA G

Reg. No : C6553

Age/Sex: 51 Year(s) / Female

Date : 25/12/2021

Ref. by : DR. BANK OF BARODA

Corporate: NON CORPORATE

Test Name

Result

Reference Range

Page 2 of 3

BIOCHEMISTRY REPORT

POST PRANDIAL BLOOD SUGAR 418 mg/dl

80 to 140 mg/dl

Glycosylated Haemoglobin (HbA1c)

Glycosylated Haemoglobin (HbA1c) 10.2 %

Normal <6.0 %
Good control 6.0-7.0 %
Fair control 7.0-8.0 %
Unsatisfactory 8.0-10.0 %
Poor control >10 %

LIPID PROFILE

TOTAL CHOLESTEROL 205.8 mg/dl

up to 200 mg/dl

TRIGLYCERIDES 247.9 mg/dl

<150 : Normal

HDL Cholesterol 40.1 mg/dl

Male: >40 mg/dl
Female: > 50 mg/dl

LDL Cholesterol 116.2 mg/dl

<100 mg/dl

VLDL Cholesterol 49.5 mg/dl

<40 mg/dl

CHOLESTEROL/HDL RATIO 5.1:1.0

up to 6.0 %

LIVER FUNCTION TESTS

Total Bilirubin 0.72 mg/dl

up to 1.2 mg/dl

Direct Bilirubin 0.24 mg/dl

0 to 0.3 mg/dl

Indirect Bilirubin 0.48 mg/dl

up to 1.5 mg/dl

S.G.O.T. (AST) 23.8 U/L

0 - 46 U/L

S.G.P.T. (ALT) 43.0 U/L

0 - 49 U/L

ALKALINE PHOSPHATASE 100.6 U/L

Men : 80-306
Women : 64-306
Children upto 15 Yrs : upto 644
Children upto 17 yrs : upto 483

Gamma Glutamyl Transpeptidase (GGT) 53.8 IU/L

0 - 55 IU/L

Total Protein 7.4 gms/dl

6.6 - 8.3 gms/dl

Albumin 3.8 gms/dl

3.4 - 5.0 gms/dl

Globulin 3.6 gms/dl

2.3 - 3.5 gms/dl

A/G Ratio 1.1:1.0

1.2 : 1.0

Dr. MAHADEVA. K.C.
M.D., (Path)
KMC. No.: 17647



Bangalore Diagnostics & Multi-Speciality Centre

Quality Assurance : EQAP from AIIMS & CMC- Vellore

Quality. Trust. Since 1982.

198, 12th Main, 3rd Block, (Above Namma MTR, Next to SBI), Rajajinagar, Bangalore- 560 010.
Ph. : 080-23505407, 9448079978 e-mail : bangalore.d.s@gmail.com

Name : MRS. PUTTARANGAMMA G

Reg. No : C6553

Age/Sex: 51 Year(s) / Female

Date : 25/12/2021

Ref. by : DR. BANK OF BARODA

Corporate: NON CORPORATE

Test Name

Result

Reference Range

Page 3 of 3

BIOCHEMISTRY REPORT

SERUM CREATININE	0.82 mg/dl	Females 0.6 - 1.2 mg/dl Males 0.7 - 1.4 mg/dl
BLOOD UREA NITROGEN (BUN)	10.9 mg/dl	7-18 mg/dl
URIC ACID	3.51 mg/dl	M: 3.5 -7.2 mg/dl F: 2.6 - 6.0 mg/dl

URINE EXAMINATION REPORT

PHYSICAL EXAMINATION

COLOUR	LIGHT YELLOW
APPEARANCE	CLEAR
REACTION	ACIDIC

BIOCHEMICAL EXAMINATION

PROTEIN	NIL	
GLUCOSE	2.0%	
BILE SALT	NIL	
BILE PIGMENT	NIL	
SPECIFIC GRAVITY	1.023	1.003 - 1.035

MICROSCOPIC EXAMINATION


PUS CELLS	2-3/HPF
EP CELLS	3-4/HPF
R.B.C.s	NIL
CASTS	NIL
CRYSTALS	NIL

----- End of Report -----

Biochemist

Microbiologist

Pathologist


Dr. MAHADEVA. K.C.
M.D., (Path)
KMC. No.: 17647



Bangalore Diagnostics & Multi-Speciality Centre

Quality Assurance : EQAP from AIIMS & CMC- Vellore

Quality. Trust. Since 1982.

198, 12th Main, 3rd Block, (Above Namma MTR, Next to SBI), Rajajinagar, Bangalore- 560 010.

Ph : 080-23505407, 9448079978

e-mail : bangalore.d.s@gmail.com

Name : Mrs. 553 PUTTARANGAMMA G

Patient No. : P10123987

Visit No. : V101341268

Registered On : 25/12/2021 15:26

Age/Gender : 51 Y/Female

Collected At Lab : 25/12/2021 17:10

Referred by : BANGALORE DIAGNOSTICS & MULTI SPECIALITY CENTER

Reported On : 25/12/2021 18:27

Final Report

Test Name / Method	Results	Units	Reference Range	Sample Type
--------------------	---------	-------	-----------------	-------------

CLINICAL BIOCHEMISTRY

THYROID PROFILE

TRIODO THYRONINE-T3 TOTAL

Method : ECLIA

1.20

ng/ml

0.80 - 2.0

SERUM

THYROXINE -T4 TOTAL

Method : ECLIA

13.38

ug/dl

5.1 - 14.1

THYROID STIMULATING HORMONE -TSH

(Ultra Sensitive)

Method : ECLIA

2.13

mIU/ml

0.40 - 4.20

First Trimester:0.1-2.5*

Second & Third

Trimester:0.2-3.0*

*American Thyroid

Association

trimesterspecific

*** End Of Report ***

Outside sample to be correlated with other clinical finding.

PROCESSED BY : NAYANA

RESULT VERIFIED BY : BHARATH KUMAR C, Lab Incharge

Dr. CHETHANA CHETHAN MBBS., M.D.

KMC Reg. No.: 41296

Consultant Biochemist



Bangalore Diagnostics & Multi-Speciality Centre

Quality Assurance : EQAP from AIIMS & CMC- Vellore

Quality. Trust. Since 1982.

198, 12th Main, 3rd Block, (Above Namma MTR, Next to SBI), Rajajinagar, Bangalore- 560 010.
Ph. : 080-23505407, 9448079978 e-mail : bangalore.d.s@gmail.com

Abdomen And Pelvic Ultrasound Scan Report

Name : Mrs . Puttarangamma.G

Date: 25/12/2021

Ref By : Bank of Baroda

Age/ Gender 51 Years/Female

Liver : Normal in size, shape and increased echotexture. No focal lesion seen.

No intrahepatic biliary dilatation seen. PV & CBD is normal

Gall Bladder: GB is distended, Normal wall thickness, Clear Content.

Pancreas : Normal in size and echotexture. No focal lesion, Pancreatic duct appears normal.

Spleen : Normal in size, shape and echotexture.

Kidneys : Both Kidney's are normal in size, shape and position.

No Calculi / Hydronephrosis seen. Cortico medullary differentiation is good.

Right Kidney : 94 x 13 mm **Left Kidney : 92 x 14 mm**

Urinary Bladder: Normal in contour and wall thickness with clear contents.

Uterus : Anteverted, Measures **65 x 28 x 40 mm**, normal in size, shape and echotexture. Endometrial thickness = **3 mm**. POD is empty.

Ovaries : Both Ovaries are not visualized in adnexa.

IMPRESSION:

- Fatty Liver Grade I.
- Otherwise Normal Study.

Dr. Mohan Kumar

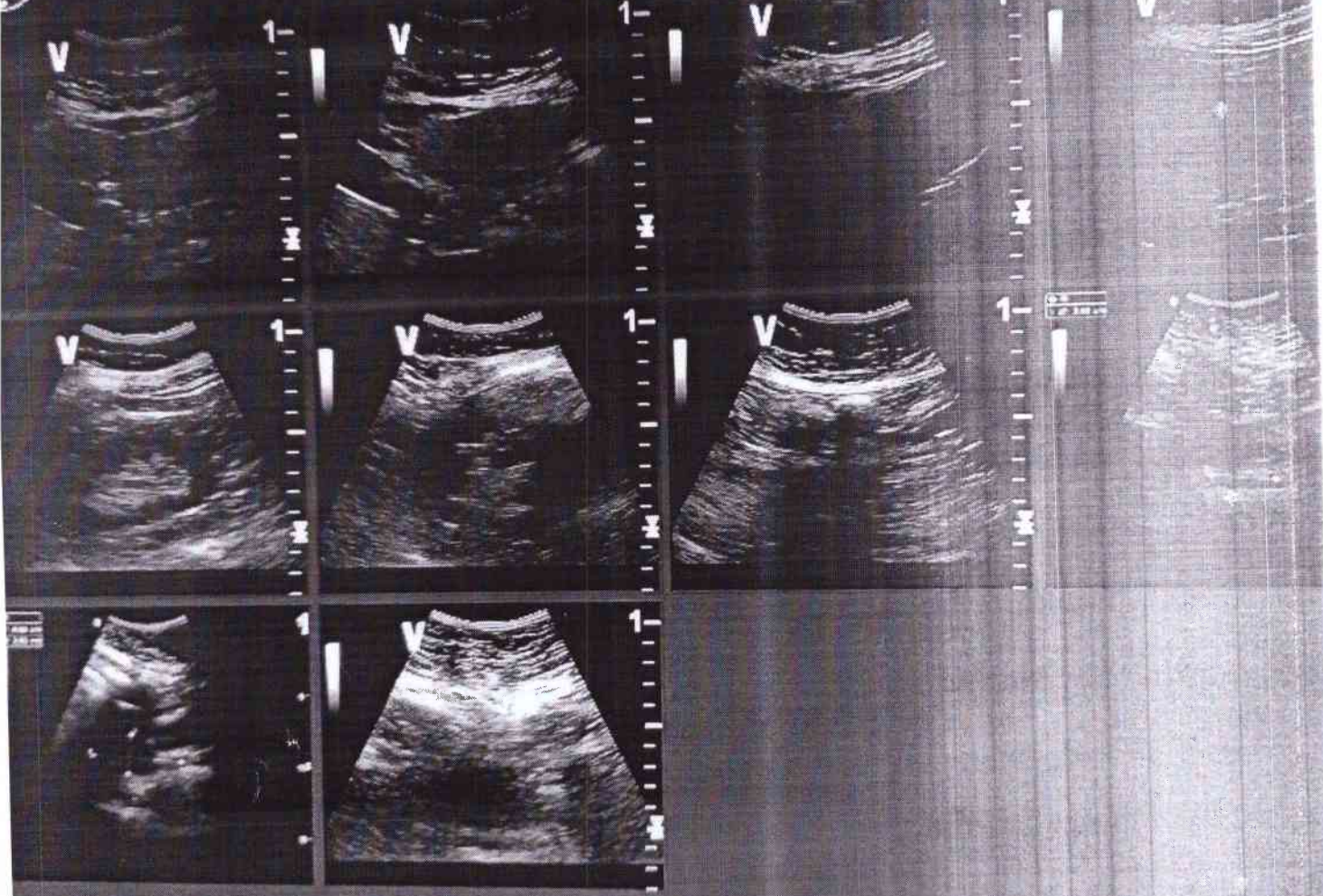
Consultant Radiologist

BANGALORE DIAGNOSTICS &
MULTI-SPECIALITY CENTRE
198, 12th Main, 3rd Block
Rajajinagar, Bangalore-560 010

GE Healthcare
25/12/21 11:26:36 AM

PUTTARANGAMMA .G51,
USR 251221-7B

MI 0.9 TIs 0.1 4C-RS
Abdom



BANGALORE DIAGNOSIS
MULTI-SPECIALITY CENTRE
198, 12th Main, 3rd Block
Rajajinagar, Bangalore-560 010



Bangalore Diagnostics & Multi-Speciality Centre

Quality Assurance : EQAP from AIIMS & CMC- Vellore

Quality. Trust. Since 1982.

198, 12th Main, 3rd Block, (Above Namma MTR, Next to SBI), Rajajinagar, Bangalore- 560 010.
Ph. : 080-23505407, 9448079978 e-mail : bangalore.d.s@gmail.com

Echocardiography Report

Name : Mrs . Puttarangamma.G

Date: 25/12/2021

Ref By : Bank of Baroda

Age/ Gender 51 Years/Female

LA : 32 mm	MV : E 0.86 A : 0.94 m/sec
AO : 17 mm	AV : 1.08 m/sec
RVID : 18 mm	TV : 0.65 m/sec
LVIDD : 37 mm	PV : 0.83 m/sec
LVIDS : 26 mm	
IVSD : 10 mm	MR : Nil
IVSS : 15 mm	AR : Nil
LVPWD: 10 mm	TR : Nil
LVPWS : 15 mm	PR : Nil
FS : 31 %	
EF : 60 %	
LV mass: 148 gm	

IMPRESSION

- Normal Chamber Dimensions.
- No RWMA.
- Normal LV Systolic Function. LVEF 60%
- LV Diastolic Dysfunction Grade I.
- Normal Valves.
- Normal Color Flow Study.
- No Thrombus / PE.

Dr.

Consultant Cardiologist

BANGALORE DIAGNOSTICS &
MULTI-SPECIALITY CENTRE
198, 12th Main, 3rd Block
Rajajinagar, Bangalore-560 010



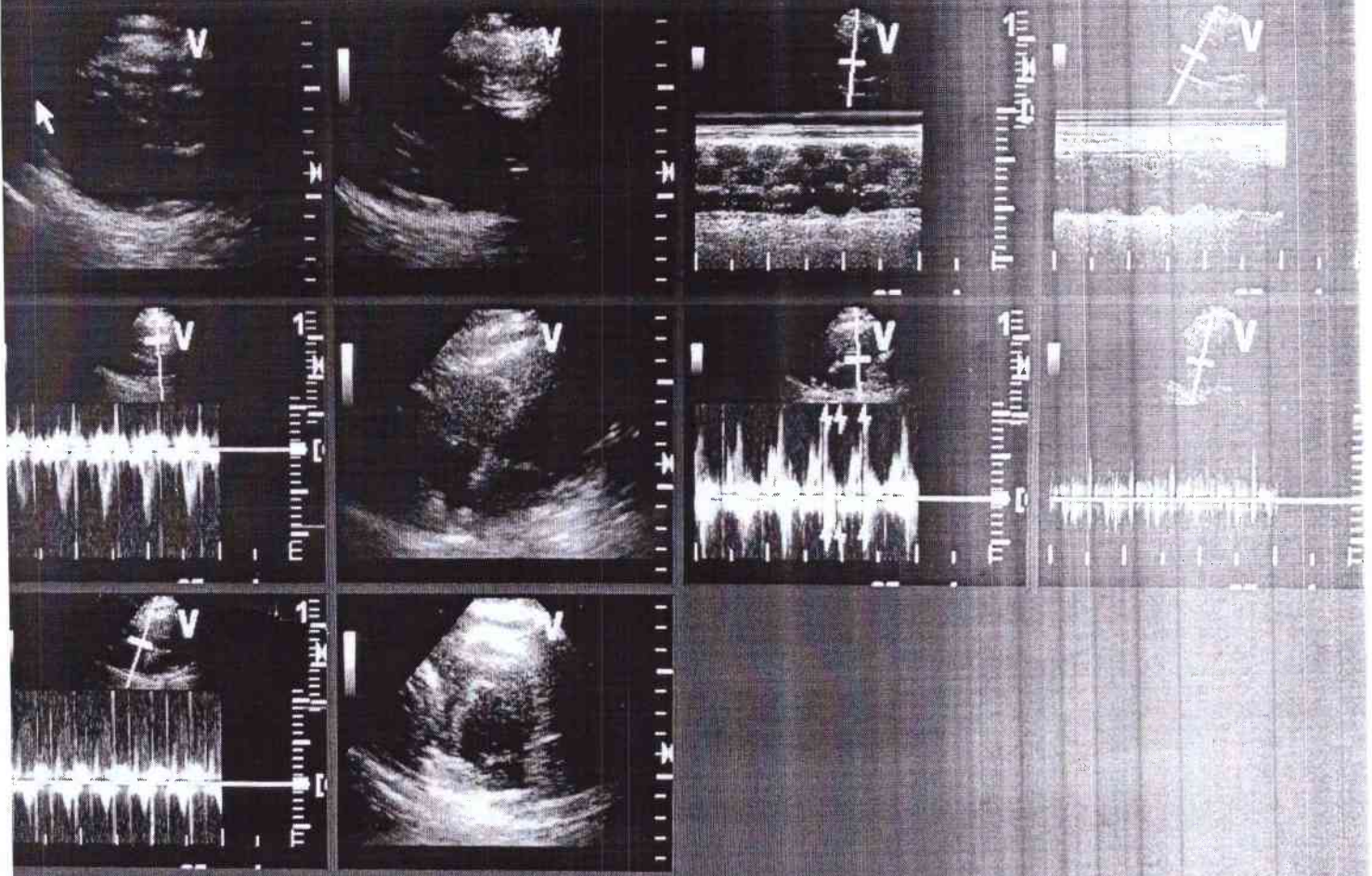
GE Healthcare

25/12/21 12:45:44 PM

USR

PUTTARANGAMMA .G51,

251221-7B



**BANGALORE DIAGNOSTICS &
MULTI-SPECIALITY CENTRE**
198, 12th Main, 3rd Block
Rajajinagar, Bangalore-560 010



Bangalore Diagnostics & Multi-Speciality Centre

Quality Assurance : EQAP from AIIMS & CMC- Vellore

Quality. Trust. Since 1982.

198, 12th Main, 3rd Block, (Above Namma MTR, Next to SBI), Rajajinagar, Bangalore- 560 010.
Ph. : 080-23505407, 9448079978 e-mail : bangalore.d.s@gmail.com

Breast Ultrasound Scan Report

Name : Mrs . Puttarangamma.G

Date: 25/12/2021

Ref By : Bank of Baroda

Age/ Gender 51 Years/Female

Right breast: Shows normal echotexture of glandular and adipose soft tissue.

No obvious focal mass lesions noted.

Nipple and retroareolar regions appear normal.

No ductal dilatation seen.

Left breast: Shows normal echotexture of glandular and adipose soft tissue.

No obvious focal lesions noted.

Nipple and retroareolar regions appear normal.

No ductal dilatation seen.

No evidence of enlarged lymphnodes seen in both axillae .

IMPRESSION:

➤ Normal Sonologic Study.

BIRAD'S SCORE: I (Routine Screening)


Dr. Mohan Kumar

Consultant Radiologist

**BANGALORE DIAGNOSTICS &
MULTI-SPECIALITY CENTRE**
198, 12th Main, 3rd Block
Rajajinagar, Bangalore-560 010

GE Healthcare

25/12/21 11:32:34 AM

USR

PUTTARANGAMMA .G51,

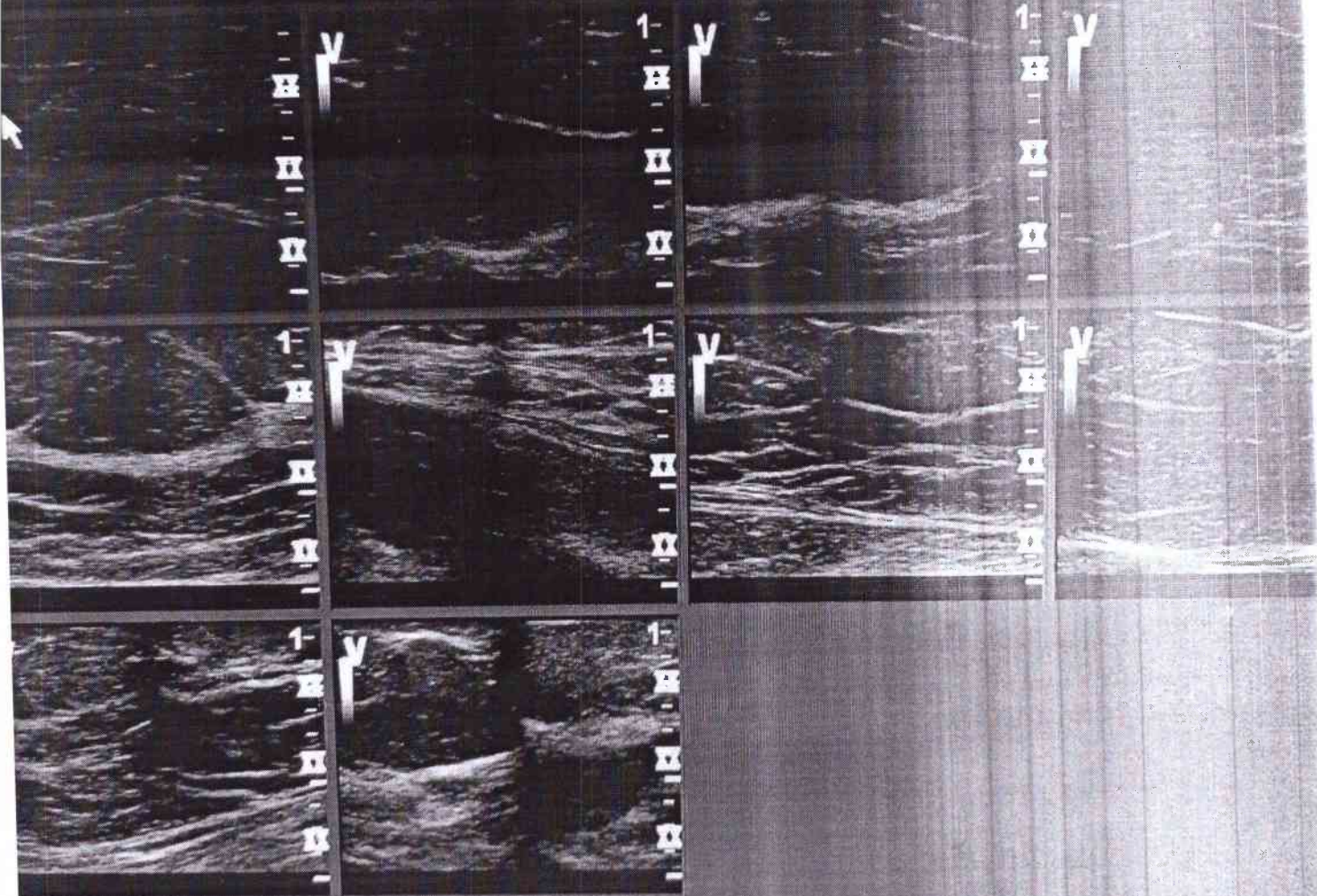
251221-7B

MI 0.6

TIs 0.6

12L-

Caro



BANGALORE DIAGNOSTICS &
MULTI-SPECIALITY CENTRE
198, 12th Main, 3rd Block
Rajajinagar, Bangalore-560 010



Bangalore Diagnostics & Multi-Speciality Centre

Quality Assurance : EQAP from AIIMS & CMC- Vellore

Quality. Trust. Since 1982.

198, 12th Main, 3rd Block, (Above Namma MTR, Next to SBI), Rajajinagar, Bangalore- 560 010.
Ph. : 080-23505407, 9448079978 e-mail : bangalore.d.s@gmail.com

Patient Name	MR.PUTTARANGAMMA	Patient Id	X-RA-165
Age/DOB	51/	Gender	M
Ref.Doctor	MEDI WHEEL	Date	25/12/2021

Thank you for referring the patient for XRay

X-RAY CHEST PA VIEW

OBSERVATION:

The trachea is central.

The mediastinal and cardiac silhouette are normal.

Cardiothoracic ratio is normal.

Cardiophrenic and costophrenic angles are normal.

Both hila are normal.

The lung fields are clear.

Bones of the thoracic cage are normal.

Soft tissues of the chest wall are normal.

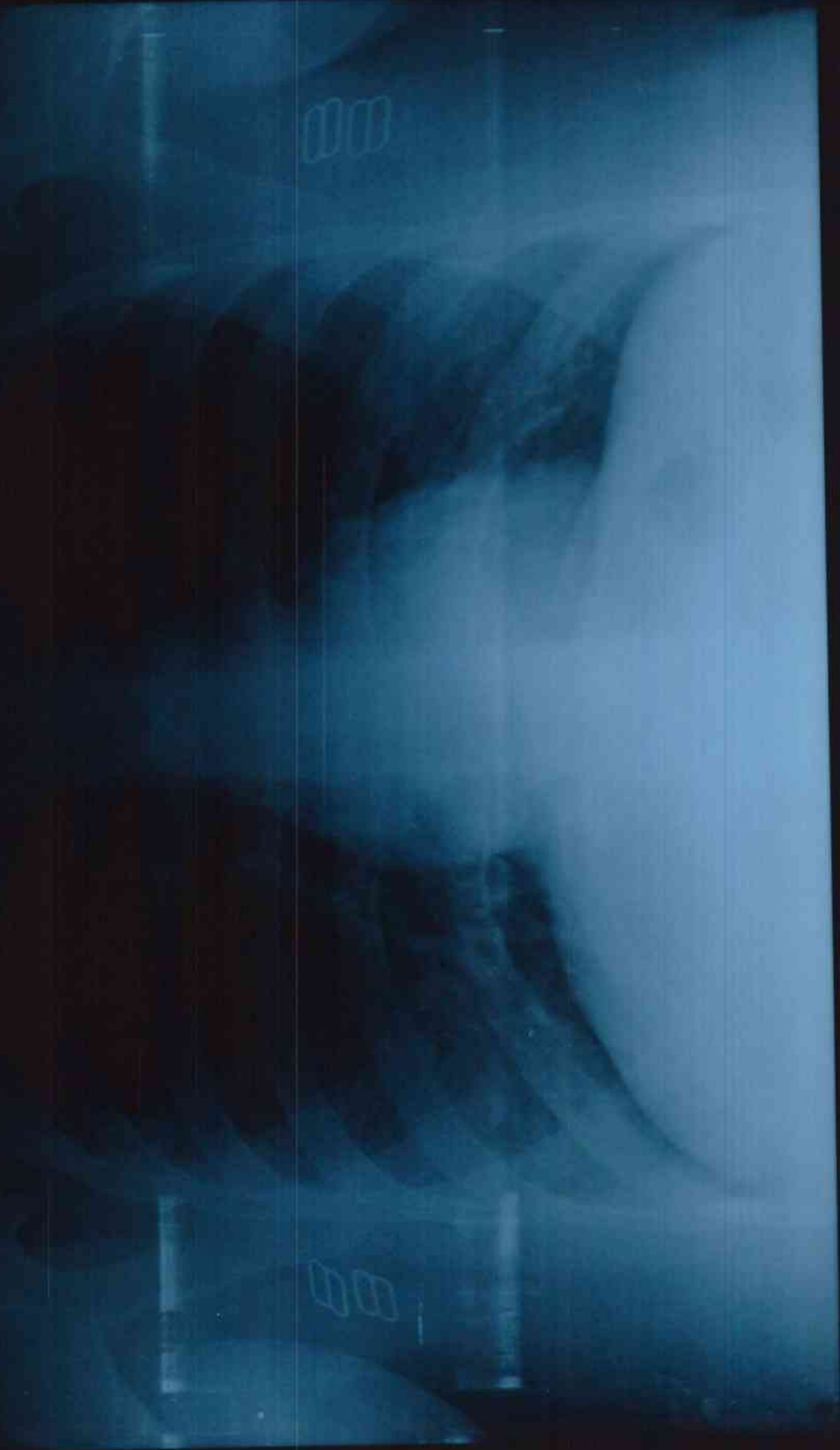
IMPRESSION:

- No significant abnormality seen.

Dr. Shankar Poudel
MD Radiodiagnosis
Consultant Radiologist

BANGALORE DIAGNOSTIC
MULTI-SPECIALITY CENTRE
198, 12th Main, 3rd Block
Rajajinagar, Bangalore-560 010

R



EXC165 MRS.PUTTARANGAMMA 51 F 25 12 2021 08 38 31
BANGALORE DIAGNOSTIC SERVICE RAJAJINAGARA -BANGALORE-560010



Bangalore Diagnostics & Multi-Speciality Centre

Quality Assurance : EQAP from AIIMS & CMC- Vellore Quality. Trust. Since 1982.

198, 12th Main, 3rd Block, (Above Namma MTR, Next to SBI), Rajajinagar, Bangalore- 560 010.
Ph. : 080-23505407, 9448079978 e-mail : bangalore.d.s@gmail.com

ELECTROCARDIOGRAM


NAME/AGE : mrs. Puttarangamma

Lab No.: Bank of Baroda DATE: 25/12/21

ECG FINDINGS

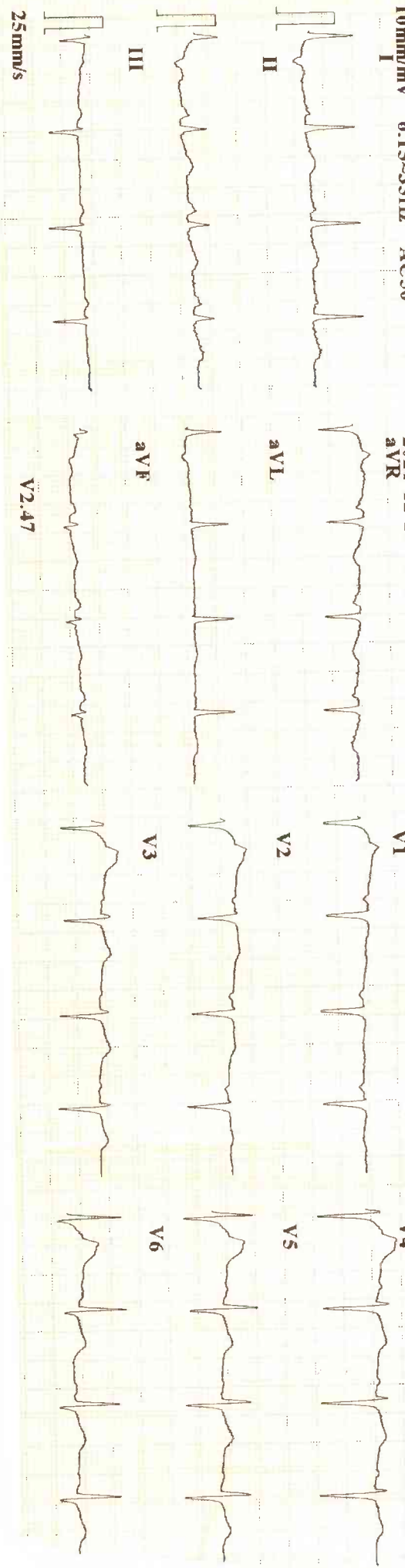
Standardization	Cal	Rate	92b
Rhythm	sin	Axis	~
P Wave	~	PR Interval	0.16m
Q Wave	~	QRS Voltage	SV 1.2V (R)
QRS Duration	0.09m	ST Segment	ST elevation
QT interval	0.30m		
U Wave		Wave	~
Recommendations			
Normal			

BANGALORE DIAGNOSTICS & MULTI-SPECIALITY CENTRE
198, 12th Main, 3rd Block
Rajajinagar, Bangalore-560 010

Dr. 
Dr. ASHOK
MD (Internal Medicine)
Reg No 13444

10mm/mV 0.15~35Hz ACS50

2021-12-25 13:18:15



ID : 211225-1318

Name : *Pulla aranganma* Minnesota Code: 1-1-2(V1)

Age : 51 yr 9-4-2(V4)

Sex : Female

BP : mmHg

Height : cm

Weight : kg

HR	:	90 bpm
P Dur	:	95 ms
PR int	:	126 ms
QRS Dur	:	92 ms
QT/QTc int	:	364/447 ms
P/QRS/T axis	:	62/2/40 °
RV5/SV1 amp	:	0.577/0.679 mV
RV3+SV1 amp	:	1.256 mV
RV6/SV2 amp	:	0.803/0.644 mV

Diagnosis Information:
 800: Sinus Rhythm
 Normal ECG

Report Confirmed by: