

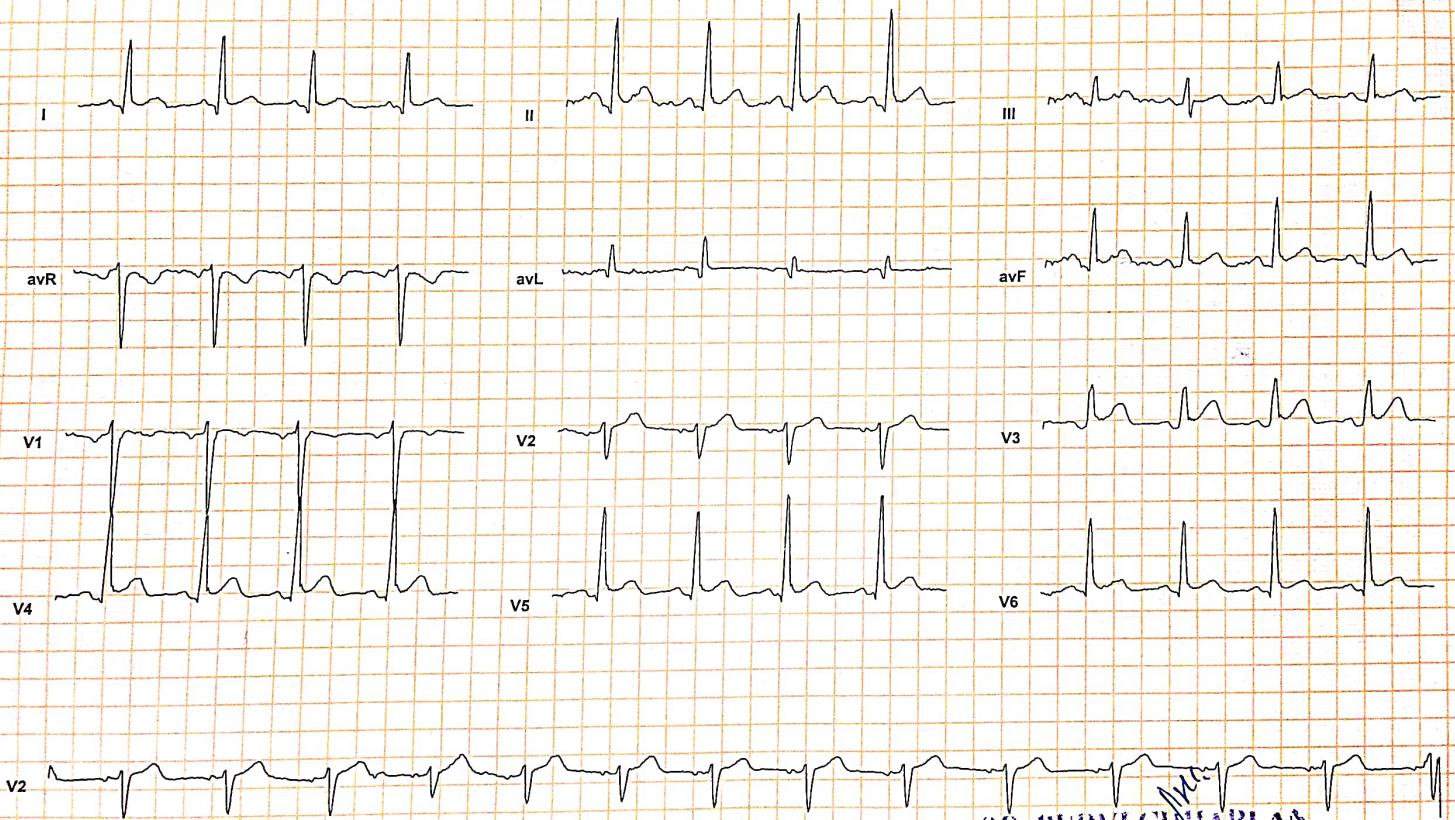
DR PLUS HEALTHCARE CENTRE- MUMBAI CENTRAL

ECG

1641 / SACHIN BORKAR / 39 Yrs / M

Heart Rate : 84 bpm / Tested On : 06-Apr-22 11:06:31 / HF 0.05 Hz - LF 100 Hz / Notch 50 Hz / Sn 1.00 Cm/mV / Sw 25 mm/s

/ Refd By.: DR. HARI CHHABLANI



DR. PLUS HEALTHCARE CENTRE
NATHANI HEIGHTS, B-WING,
42, MUMBAI CENTRAL (EAST)

WHL

DR. PURVI CHHABLANI
MBBS, DNB (Medicine)
Consultant Physician And Intensive
Reported By: DR. PURVI CHHABLANI
22/04/2022



Dr-Plus Healthcare Centre

NATHANI HEIGHTS, B-Wing, Shop No. 42, Ground Floor, Opp. Mumbai Central Station (East), Mumbai - 400 008.

Patient Name	:	SACHIN BORKAR	Sex:	MALE
Doctor's Name	:	DR. H. CHHABLANI	Age:	39 YEARS
Date	:	05/04/2022		

ULTRASONOGRAPHY OF THE ABDOMEN AND THE PELVIS:

The relevant sonographic findings include the following:

HEPATOBIILIARY APPARATUS

The liver is normal in size and echogenicity. No obvious focal parenchymal lesion is seen. Extrahepatic biliary radicals are not dilated. The portal vein and the common bile duct are normal.

GALL BLADDER

The gall bladder is adequately distended. The wall thickness is normal. No echogenic contents are noted in its lumen. There is no pericholecystic collection noted.

PANCREAS

The pancreas shows normal echogenicity and size. No focal or diffuse lesions are noted. No evidence of calcification is noted.

SPLEEN

The spleen appears normal in size and echogenicity. No focal or diffuse lesions are noted. No evidence of calcification is noted.

KIDNEYS

Right Kidney measure: 10.2 x 4.8 cm, Left kidney measure: 10.5 x 4.5 cm

Both the kidneys appear normal in size, shape and echogenicity. Both the pelvicalyceal system is normal and both corticomedullary differentiations are well maintained. There is no obvious focal or diffuse lesion noted. No evidence of any calculus seen in either kidney.

PROSTATE

The Prostate appears normal and shows a normal echogenicity.

URINARY BLADDER

The urinary bladder shows anechoic contents. Its wall thickness appears normal.

No evidence of calcification is seen.

There is no obvious evidence of abdominal or pelvic lymphadenopathy or ascites noted.

IMPRESSION: No significant abnormality is detected.

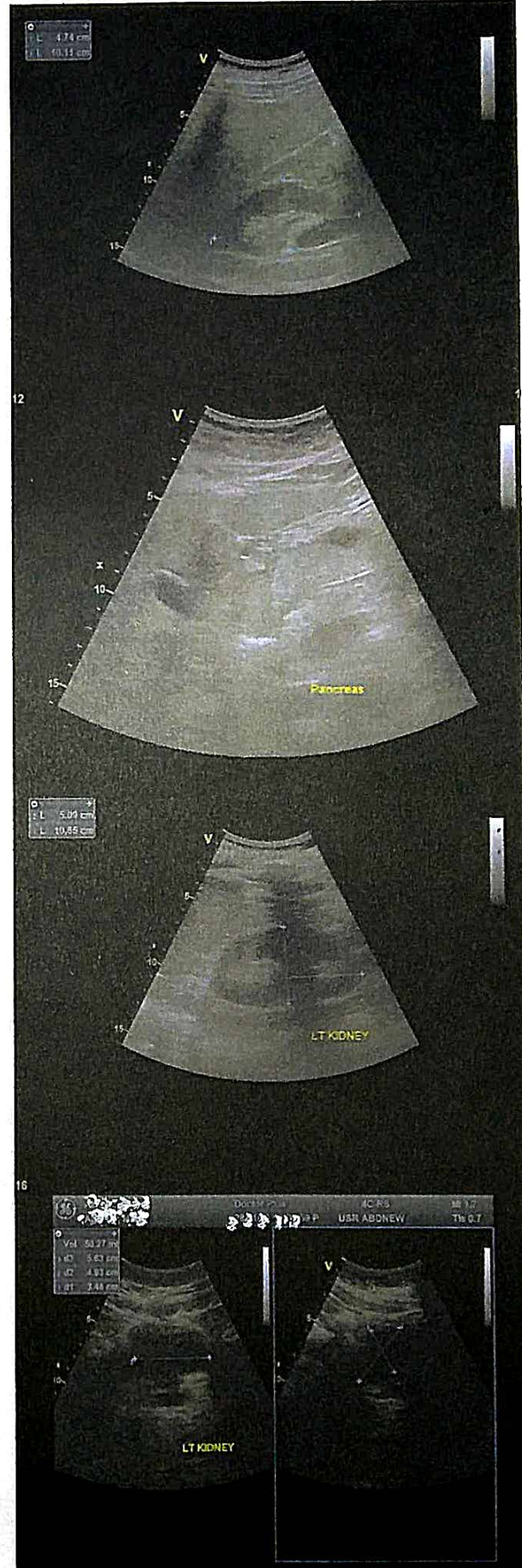
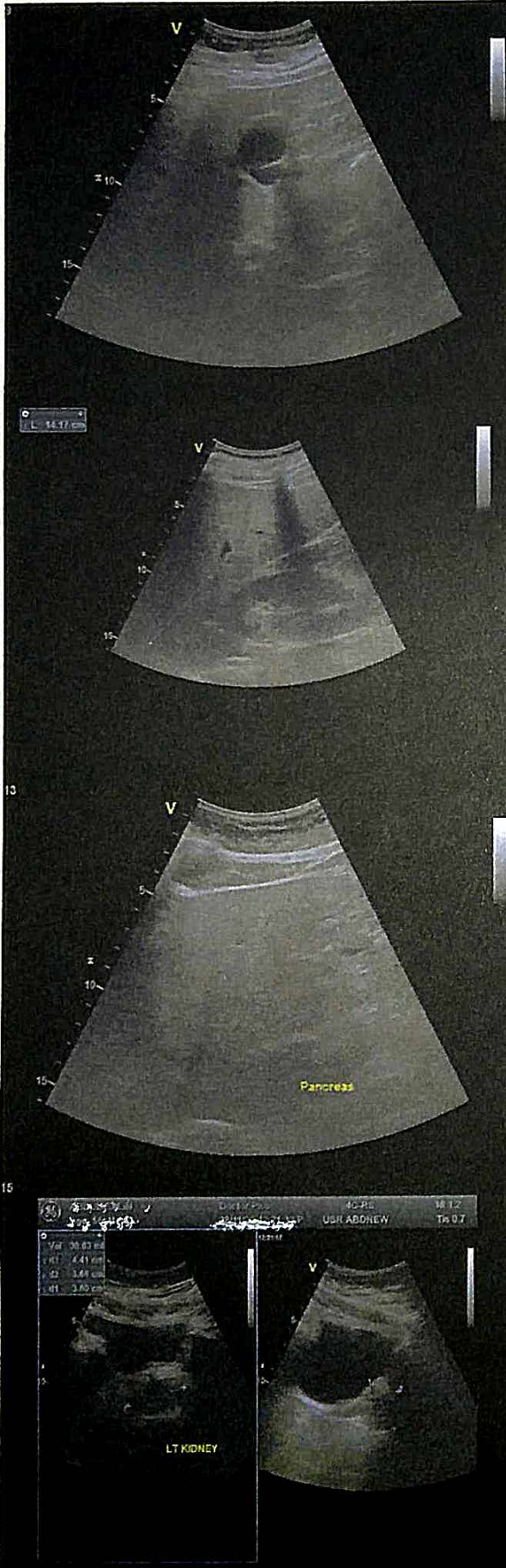

Dr. Parag Jhaveri
MBBS (BOM), DMRE(BOM)
Radio-Sonologist

**DR. PLUS HEALTHCARE CENTRE
NATHANI HEIGHTS', B-WING,
42, MUMBAI CENTRAL (EAST)**

Name **SACHIN BORKAR**

Sex **Male**

Age **39**



"DR- PLUS HEALTHCARE CENTRE"

Report



MUMBAI CENTRAL

20431 / SACHIN BORKAR / 39 Yrs / M / 0 Cms / 0 Kg Date: 06-Apr-2022 Refd By : DR PURVI CHHABLANI Examined By: DR. HARI CHHABLANI

Stage	Time	Duration	Speed(mph)	Elevation	METs	Rate	% THR	BP	RPP	PVC	Comments
Supine	00:17	0:17	00.0	00.0	01.0	076	42 %	124/78	094	00	
Standing	00:25	0:08	00.0	00.0	01.0	080	44 %	124/78	099	00	
HV	00:32	0:07	00.0	00.0	01.0	080	44 %	124/78	099	00	
Warm Up	00:46	0:14	00.0	00.0	01.0	082	45 %	124/78	101	00	
ExStart	00:51	0:05	01.7	10.0	01.1	093	51 %	134/78	124	00	
BRUCE Stage 1	03:51	3:00	01.7	10.0	04.7	111	61 %	134/78	148	00	
BRUCE Stage 2	06:51	3:00	02.5	12.0	07.1	137	76 %	146/78	200	00	
PeakEx	07:45	0:54	03.4	14.0	08.0	157	87 %	158/78	248	00	
Recovery	08:45	1:00	01.1	00.0	01.2	135	75 %	148/78	199	00	
Recovery	09:04	1:19	00.0	00.0	01.0	125	69 %	132/78	165	00	

FINDINGS :

Exercise Time : 06:54
Max HR Attained : 157 bpm 87% of Target 181
Max BP Attained : 158/78
Max WorkLoad Attained : 8 Fair response to induced stress
Test End Reasons : Test Complete

Purvi
DR. PURVI CHHABLANI
MBBS DNB (Medicine)
Consultant Physician And Intensive
Care No 7769F
Doctor : DR.PURVI CHHABLANI

REPORT



"DR- PLUS HEALTHCARE CENTRE"

MUMBAI CENTRAL

20431 / SACHIN BORKAR / 39 Yrs / M / 0 Cms / 0 Kg Date: 06-Apr-2022 Refd By : DR PURVI CHHABLANI

REPORT :

TEST OBJECTIVE	:	ROUTINE CHECK UP
RISK FACTOR	:	AGE--DM--COVID-19
ACTIVITY	:	GOOD
MEDICATION	:	OBIMET -SR
BRIEF HISTORY	:	DM
OTHER INVESTIGATION	:	NIL
REASON FOR TERMINATION	:	TARGET HEART RATE ACHIEVED
EXERCISE TOLERANCE	:	GOOD
EXERCISE INDUCED ARRHYTHMIAS	:	INSIGNIFICANT
HAEMODYNAMIC RESPONSE	:	NORMAL
CHRONOTROPIC RESPONSE	:	NORMAL
FINAL IMPRESSION	:	STRESS TEST IS NEGATIVE FOR EXERCISE INDUCED ISCHAEMIC HEART DISEASE

Purvi
DR. PURVI CHHABLANI
MBBS, DNB, Medicine
consultant Physician And Intensivist
Reg No 77896

Doctor : DR.PURVI CHHABLANI

"DR- PLUS HEALTHCARE CENTRE"

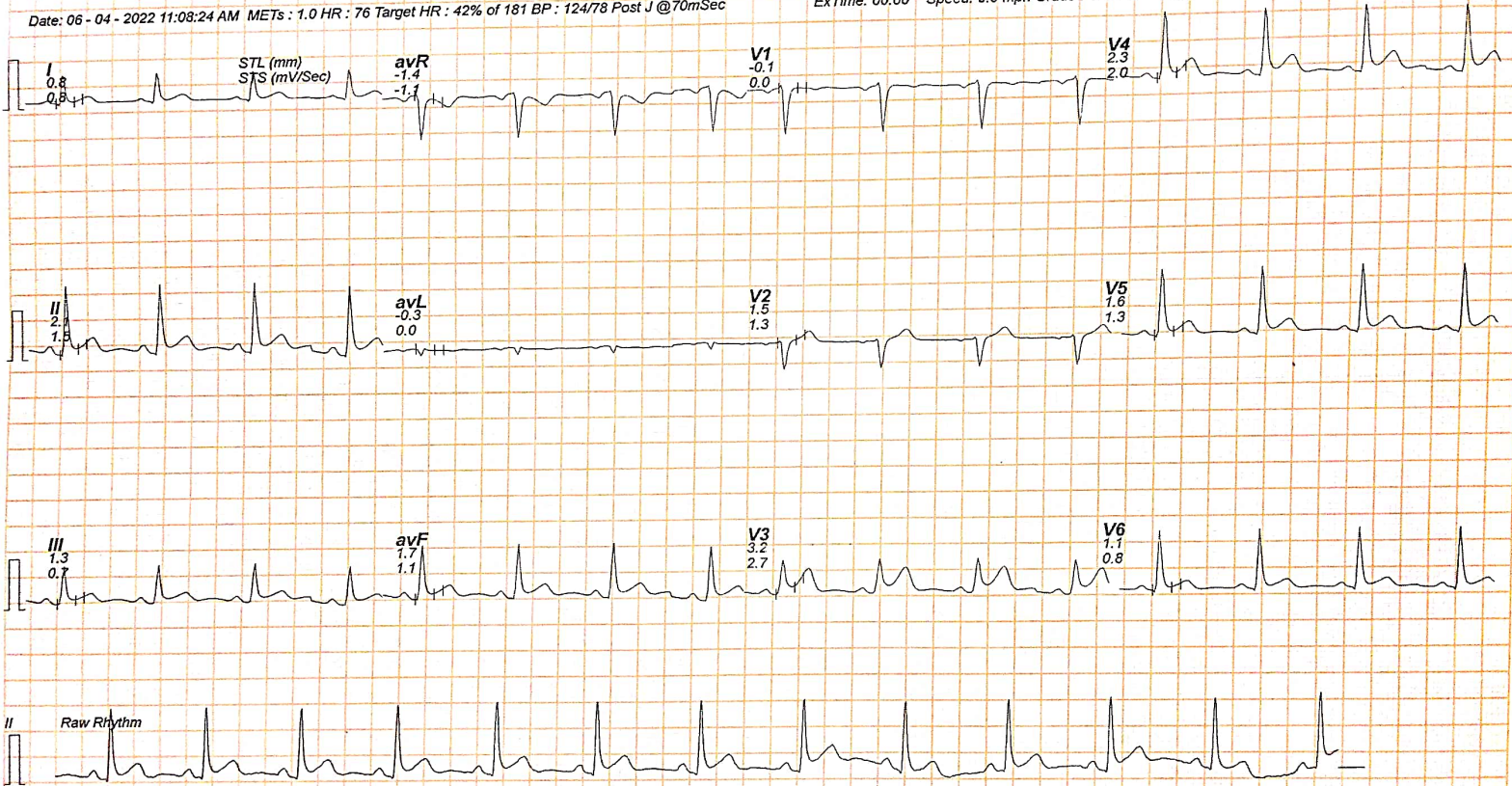
MUMBAI CENTRAL
20431 / SACHIN BORKAR / 39 Yrs / Male / 0 Cm / 0 Kg

Linked Medians Report
BRUCE:Supine(0:17)



Date: 06 - 04 - 2022 11:08:24 AM METs : 1.0 HR : 76 Target HR : 42% of 181 BP : 124/78 Post J @70mSec

ExTime: 00:00 Speed: 0.0 mph Grade : 00.00 % 25 mm/Sec. 1.0 Cm/mV



"DR- PLUS HEALTHCARE CENTRE"

MUMBAI CENTRAL
20431 / SACHIN BORKAR / 39 Yrs / Male / 0 Cm / 0 Kg

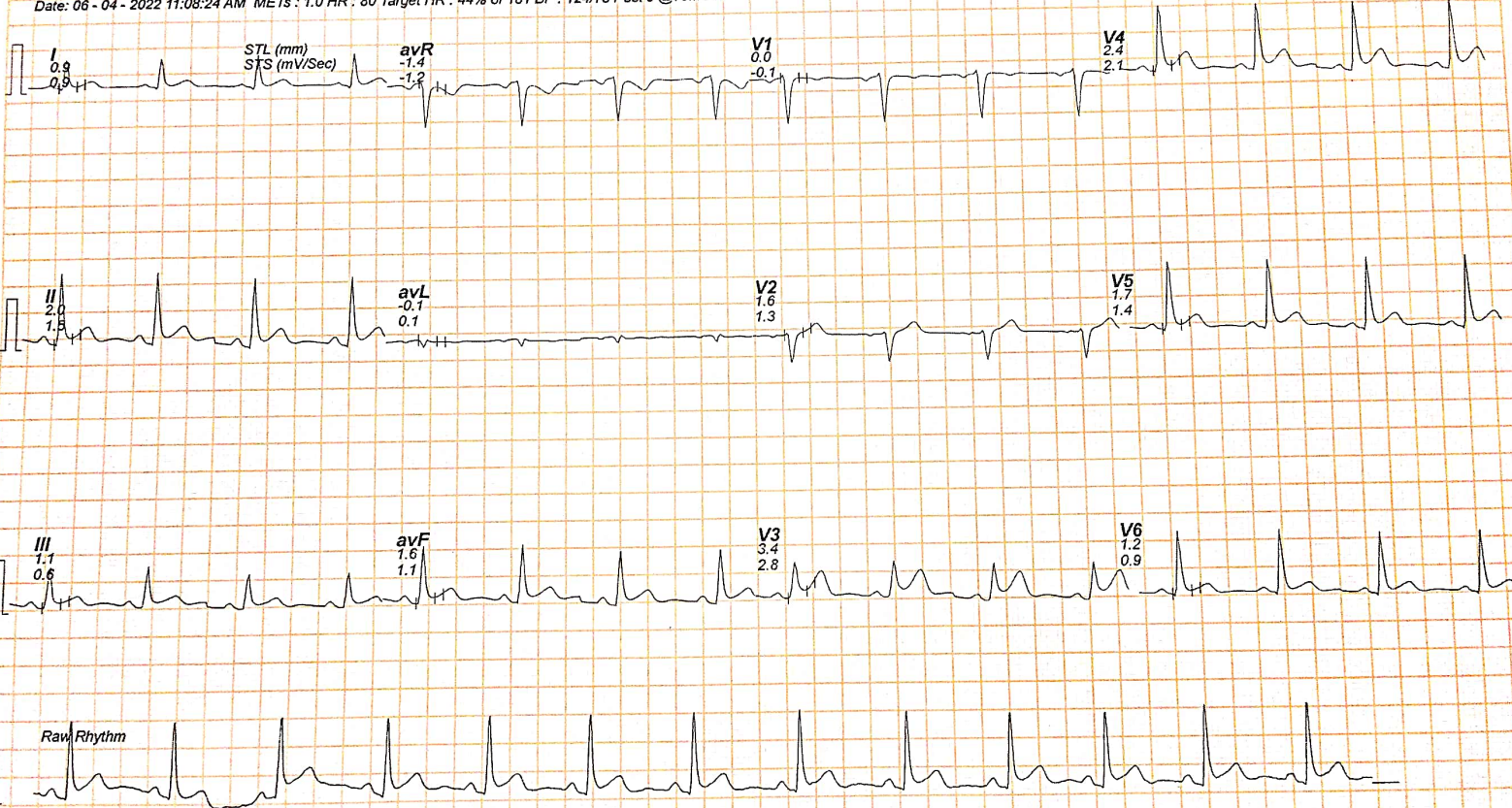
Linked Medians Report

BRUCE: Standing(0:08)



Date: 06 - 04 - 2022 11:08:24 AM METs : 1.0 HR : 80 Target HR : 44% of 181 BP : 124/78 Post J @70mSec

ExTime: 00:00 Speed: 0.0 mph Grade : 00.00 % 25 mm/Sec. 1.0 Cm/mV



"DR- PLUS HEALTHCARE CENTRE"

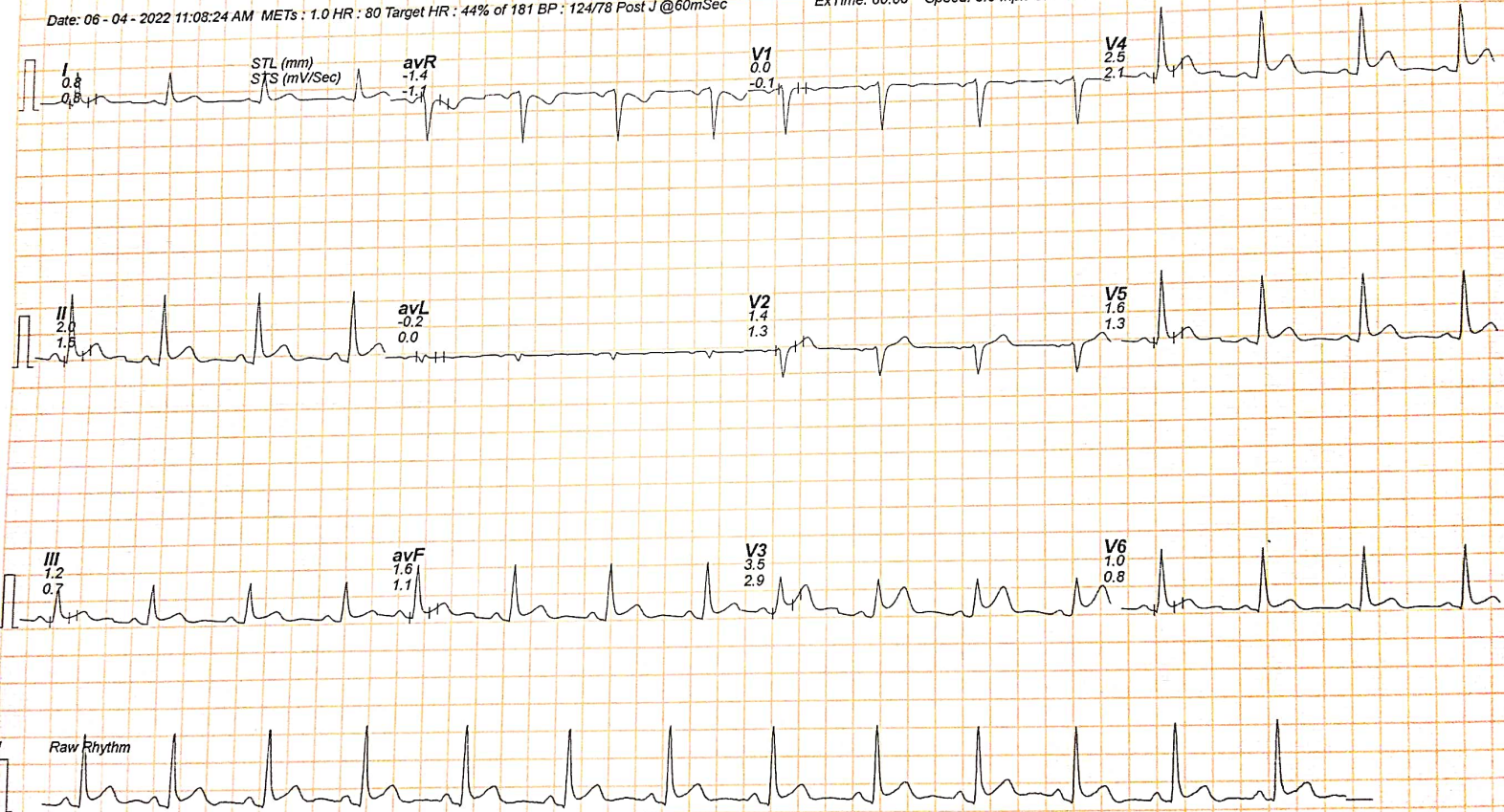
Linked Medians Report
BRUCE:HV(0:07)



MUMBAI CENTRAL
20431 / SACHIN BORKAR / 39 Yrs / Male / 0 Cm / 0 Kg

Date: 06 - 04 - 2022 11:08:24 AM METs : 1.0 HR : 80 Target HR : 44% of 181 BP : 124/78 Post J @60mSec

ExTime: 00:00 Speed: 0.0 mph Grade : 00.00 % 25 mm/Sec. 1.0 Cm/mV



"DR- PLUS HEALTHCARE CENTRE"

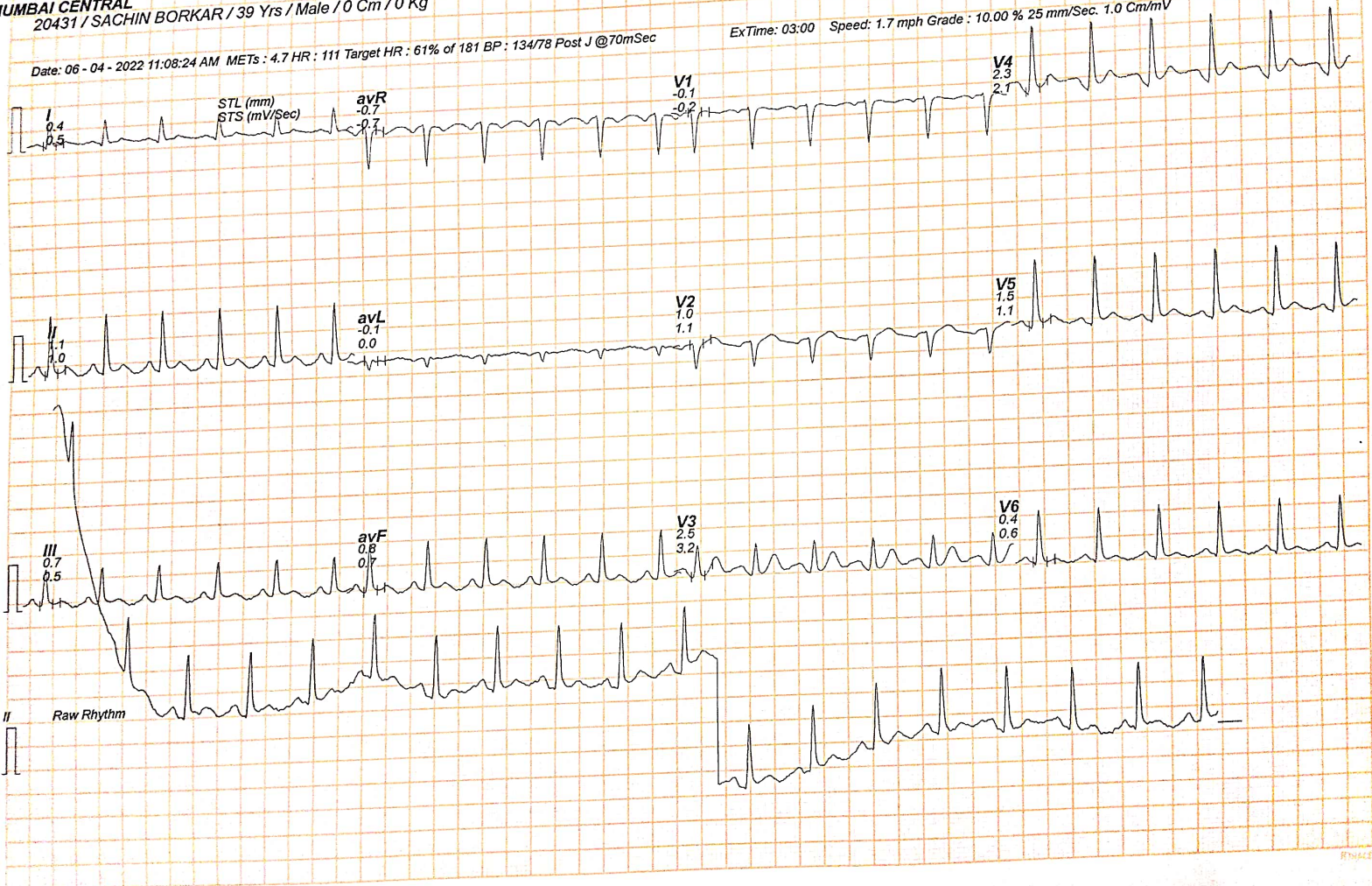
MUMBAI CENTRAL
20431 / SACHIN BORKAR / 39 Yrs / Male / 0 Cm / 0 Kg

Linked Medians Report
BRUCE: Stage 1 (3:00)



Date: 06 - 04 - 2022 11:08:24 AM METs : 4.7 HR : 111 Target HR : 61% of 181 BP : 134/78 Post J @70mSec

ExTime: 03:00 Speed: 1.7 mph Grade : 10.00 % 25 mm/Sec. 1.0 Cm/mV



"DR- PLUS HEALTHCARE CENTRE"

MUMBAI CENTRAL

20431 / SACHIN BORKAR / 39 Yrs / Male / 0 Cm / 0 Kg

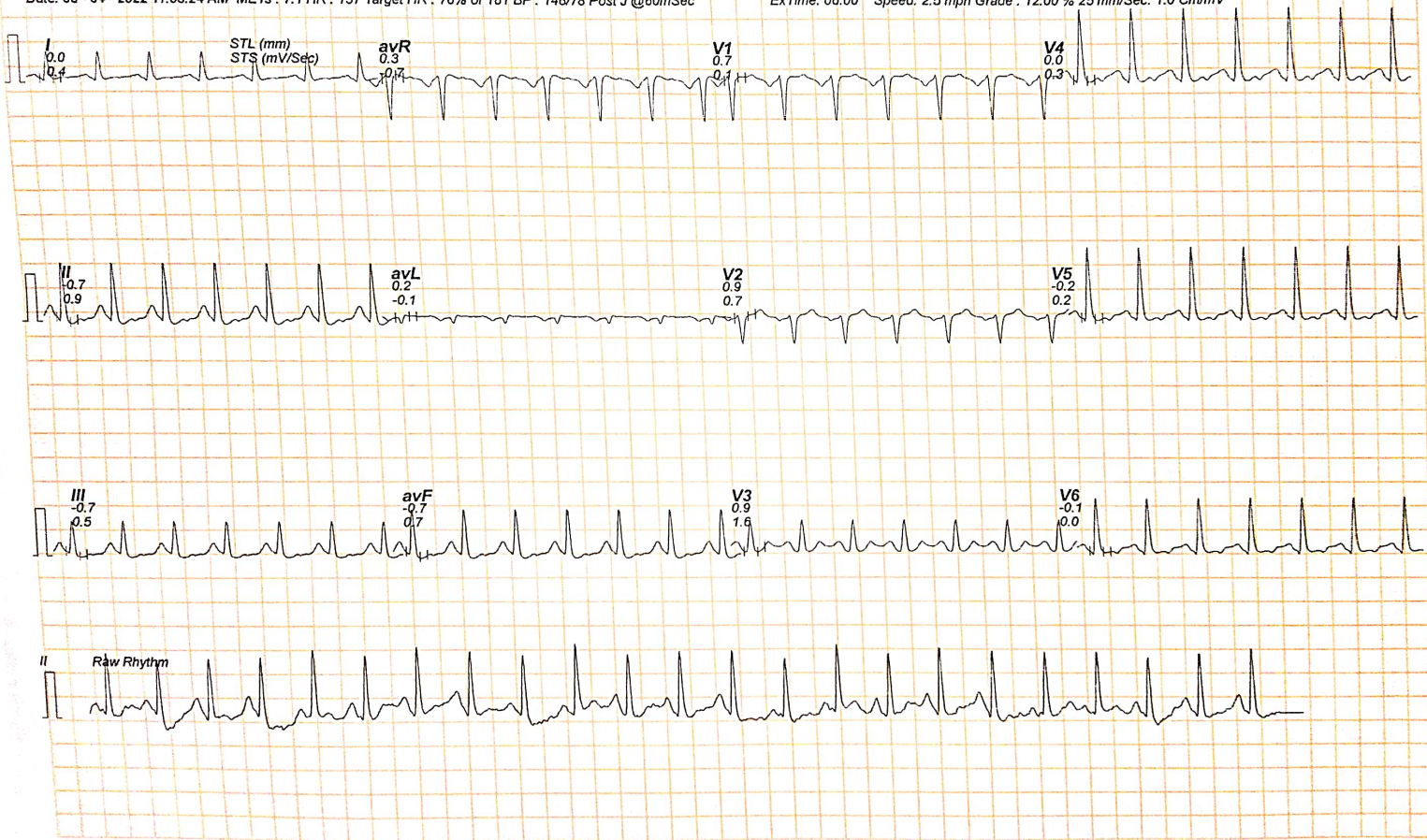Linked Medians Report

BRUCE: Stage 2(3:00)



Date: 06 - 04 - 2022 11:08:24 AM METs : 7.1 HR : 137 Target HR : 76% of 181 BP : 146/78 Post J @60mSec

ExTime: 06:00 Speed: 2.5 mph Grade : 12.00 % 25 mm/Sec. 1.0 Cm/mV



"DR- PLUS HEALTHCARE CENTRE"

Linked Medians Report

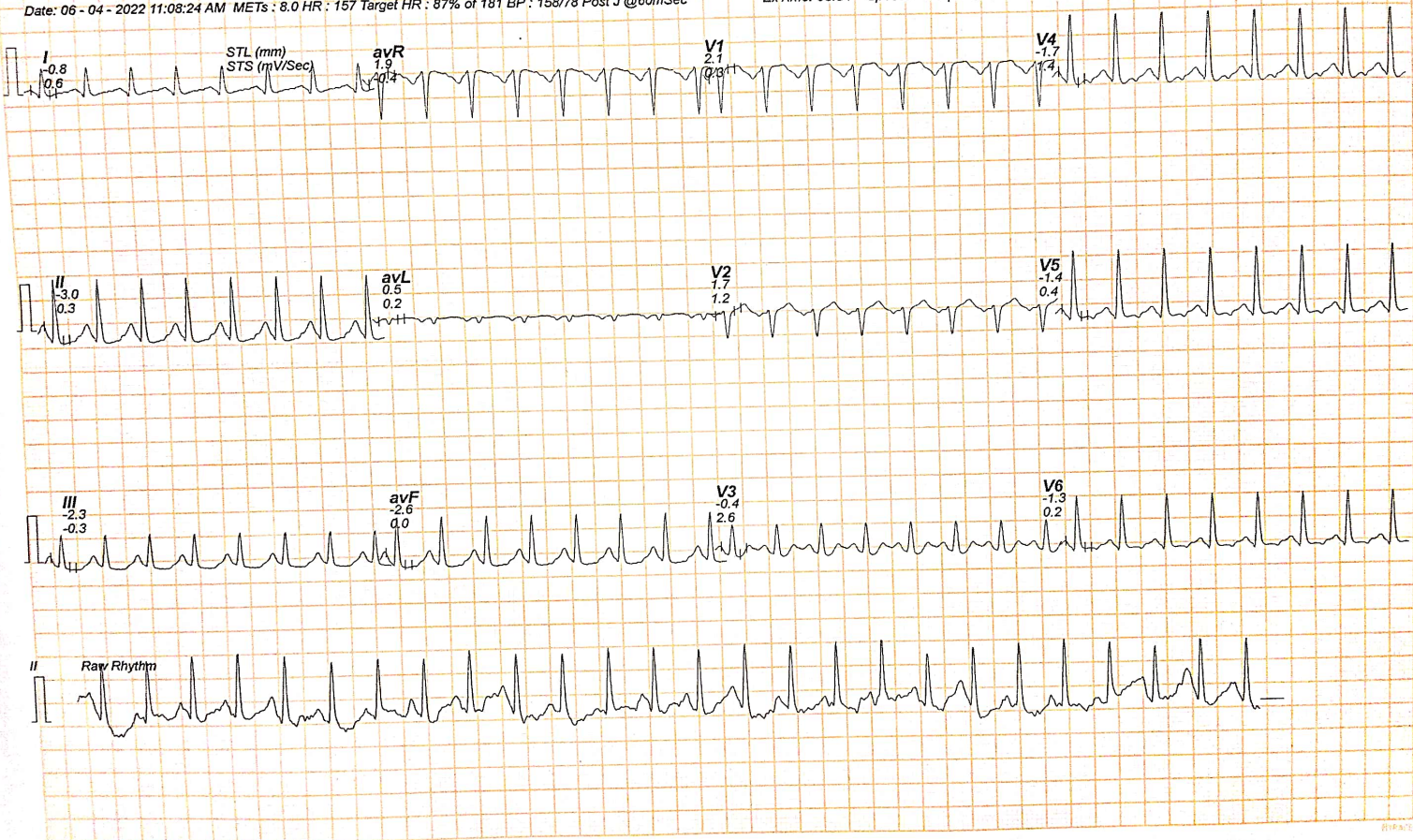


MUMBAI CENTRAL
20431 / SACHIN BORKAR / 39 Yrs / Male / 0 Cm / 0 Kg

PeakEx

Date: 06 - 04 - 2022 11:08:24 AM METs : 8.0 HR : 157 Target HR : 87% of 181 BP : 158/78 Post J @ 60mSec

ExTime: 06:54 Speed: 3.4 mph Grade : 14.00 % 25 mm/Sec. 1.0 Cm/mV



"DR- PLUS HEALTHCARE CENTRE"

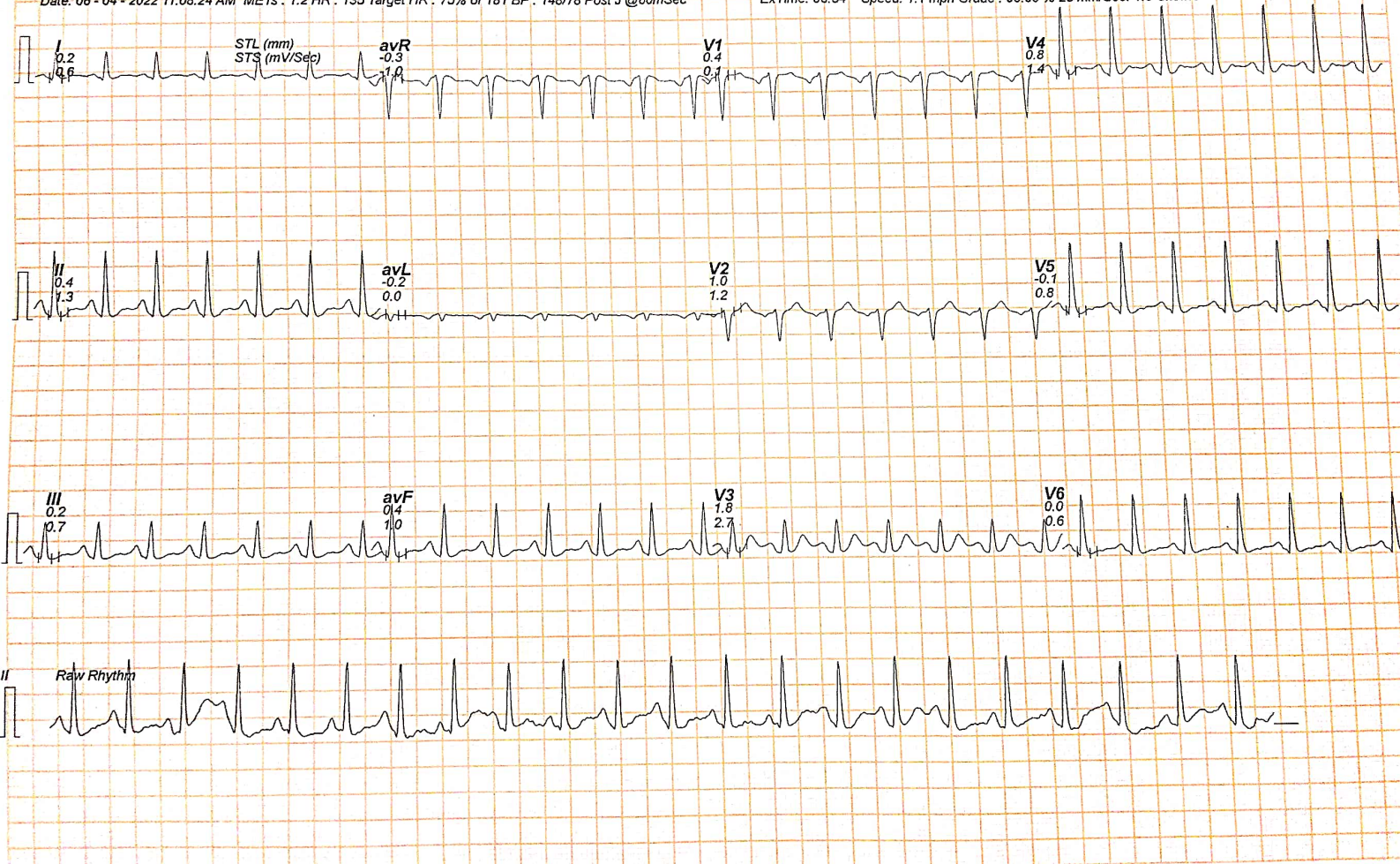
MUMBAI CENTRAL
20431 / SACHIN BORKAR / 39 Yrs / Male / 0 Cm / 0 Kg

Linked Medians Report
Recovery(1:00)



Date: 06 - 04 - 2022 11:08:24 AM METs : 1.2 HR : 135 Target HR : 75% of 181 BP : 148/78 Post J @60mSec

ExTime: 06:54 Speed: 1.1 mph Grade : 00.00 % 25 mm/Sec. 1.0 Cm/mV



"DR- PLUS HEALTHCARE CENTRE"

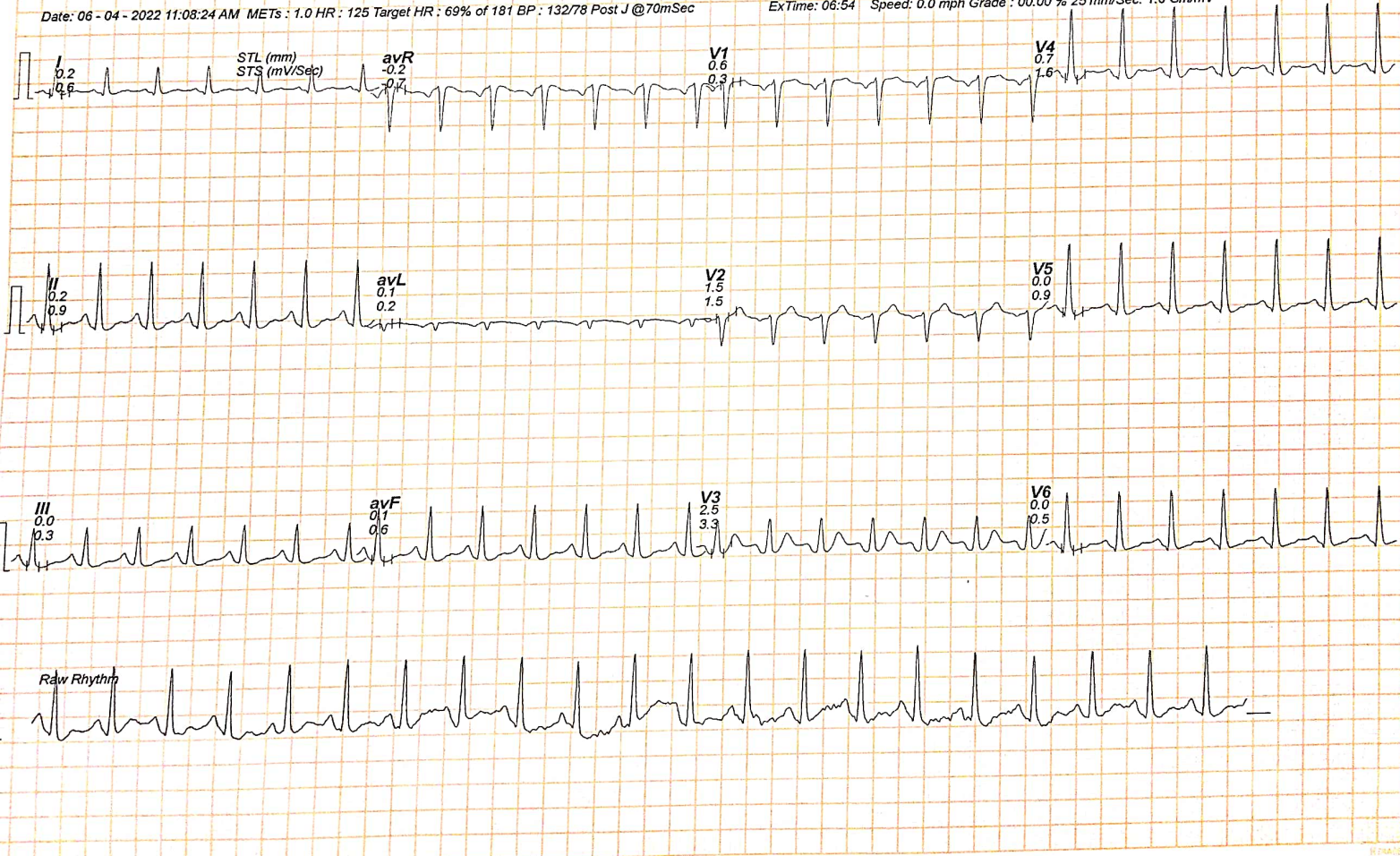MUMBAI CENTRAL
20431 / SACHIN BORKAR / 39 Yrs / Male / 0 Cm / 0 Kg

Linked Medians Report
Recovery(1:19)



Date: 06 - 04 - 2022 11:08:24 AM METs : 1.0 HR : 125 Target HR : 69% of 181 BP : 132/78 Post J @70mSec

ExTime: 06:54 Speed: 0.0 mph Grade : 00.00 % 25 mm/Sec. 1.0 Cm/mV





Dr-Plus Healthcare Centre

NATHANI HEIGHTS, B-Wing, Shop No. 42, Ground Floor, Opp. Mumbai Central Station (East), Mumbai - 400 008.

Patient's Name : SACHIN BORKAR

Report : 06/04/2022

Referred By Dr. : SELF

Age : 39 Years

Sex : MALE

Chest X-ray PA

- No active pulmonary lesion seen.
- Trachea and mediastinum are in midline .
- Cardiac size and configuration are within normal limits .
- Pleural cavities are clear .
- Domes of diaphragm are smooth in outline.
- Bony thorax is normal .

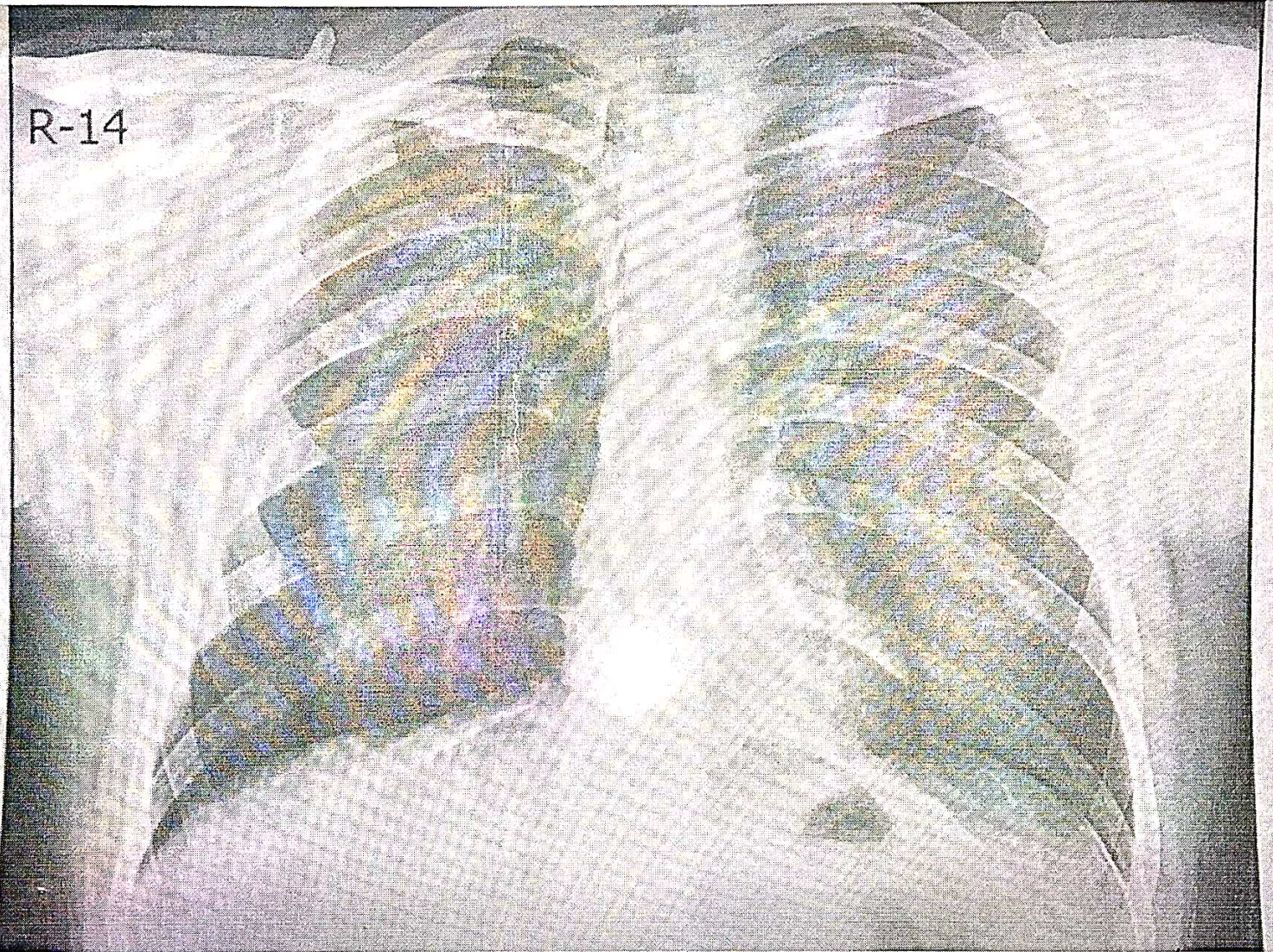

Radiologist

DR. A. J. MAZUMDAR

MD. DMRE,MDRD

DR. PLUS HEALTHCARE CENTRE
NATHANI HEIGHTS', B-WING,
42, MUMBAI CENTRAL (EAST)

R-14



SACHIN BORKAR

39/M

06/04/2022



Dr. Hari Chhablani

Cardiometabolic Physician & Intensivist
M.B.B.S., F.C.C.P. (RESP. MED.), PGDHMM,
PGDMLS, FELLOW INTENSIVE CARE MED.

ATTACHED TO: Wockhardt Hospital • Saifee Hospital • Apollo Spectra Hospital

NATHANI HEIGHTS, B-Wing, Shop No. 42, Ground Floor, Opp. Mumbai Central Station (East),
Mumbai - 400 008. • Cell : 98206 46163 • E : drharichhablani@gmail.com

PHYSICIAN REPORT

DATE : 06/04/2022

NAME : SACHIN BORKAR 39/M

PRESENTING COMPLAINS : K/C/O DM SINCE -APRIL 2021 .

K/C/O LUMBER RADICULOPATHY SINCE AUG. 2021 ON
PHYSIOTHERAPY

TREATMENT : OBIMET -SR .

PAST HISTORY : H/O COVID POSITIVE DEC. 2021 - HOSPITALIZED

FAMILY HISTORY: NOT SIGNIFICANT

HABITS : ALCOHOL

DENTAL EXAMINATION: NAD

HT.- 165 CM. WT.- 68 Kg. BMI.25

P: 84/MIN ., REGULAR

BP: 118/80

RS: CLEAR CVS: S1,S2 REGULAR

PA: SOFT

CNS: CLINICALLY NAD

EYE EXAMINATION : NEAR VISION -B/E N6 , DISTANT VISION -BE-- 6/6 , COLOUR VISION - NORMAL

LABS: ATTACHED

ECG: WNL

CHEST X-RAY :WNL

SONOGRAPHY : ATTACHED

TMT : NEGATIVE.

IMPRESSION : FIT ON CLINICAL MEDICAL EXAMINATION .

DR.HARI CHHABLANI

DR. HARI CHHABLANI
M.B.B.S., F.C.C.P. (RESP. MEDICINE) PGDHMM, PGDMLS /
FELLOW INTENSIVE CARE
MMC REG. NO. - 91702



Dr-Plus Healthcare Centre

NATHANI HEIGHTS, B-Wing, Shop No. 42, Ground Floor, Opp. Mumbai Central Station (East), Mumbai - 400 008.

Full Name: SACHIN BORKAR 39/M 06/04/2022
Life to be assured:

HAEMOGRAM Normal Range

1.	Red Blood Cell Count	4.7	[M : 4.5 – 5.6 / F : 3.5 – 5.5/cu.mm]
2.	Hb%	14.6	[M: 14-18 / F : 11-16%]
3.	Hematocrit	44.8	[M : 40-53 / F : 30-47 %]
4.	Indices:		
(a)	MCV(Mean Corpuscular Volume)	85.2	[79-101 cu.mi.]
(b)	MCH(Mean Corpuscular Hb)	29.2	[27-32 pg]
(c)	MCHC(Mean Corpuscular Hb Concentration)	32.3	[32-38%]
5.	Morphology		
	Macrocytes :	--	Microcytes: -- Hypochromia: --
	Piokilocytosis:	--	Anisocytosis: --
6.	Target cells:	--	
	Spherocytes:	--	Elliptocytes: --
7.	TOTAL W.B.C.Count	6,800	{4000-1100/cu.mm}
Differential Count 0			
a)	Neutrophils :	61	[45 -70%] c) Eosinophils: 05 [01 - 06%]
b)	Lymphocytes :	30	[20 - 45%] d) Monocytes: 04 [00 - 08%]
e)	Basophils :	00	[00 - 01%]
8.	Platelets :3.51	1.5-4.5 Lacks/cu.mm	
9.	Erythrocyte Sedimentation Rate:-12	20 mm at end of 1 hour	Method : Westergrens

ROUTINE URINE EXAMINATION (RUA)

1. Physical Examination:

(i)	Colour :	PLAN YELLOW	(ii)	Sediment:	CLEAR
(iii)	Transparency:	CLEAR	(iv)	Reaction:	ACIDIC
(v)	Specific gravity	1.010			

2. Chemical Examination:

(i)	Protein :	NIL	(ii)	Sugar:	NIL
(iii)	Bile salt:	NIL	(iv)	Bile pigment:	NIL

3. Microscopic Examination:

(i)	Red Blood Cells:	ABSENT	(ii)	Epithelial Cells:	2 TO 3/ HPF
(iii)	Crystals:	ABSENT	(iv)	Pus Cells:	2 TO 3/HPF
(v)	Casts:	ABSENT	(vi)	Deposits:	ABSENT
(vii)	Bacteria's :	ABSENT			

DR. RAKESH PATKAR
M.D., D.M.B. (Pathology)
Reg. No. 2013/05/1660



Dr-Plus Healthcare Centre

NATHANI HEIGHTS, B-Wing, Shop No. 42, Ground Floor, Opp. Mumbai Central Station (East), Mumbai - 400 008.

Full Name

SACHIN BORKAR

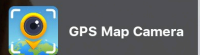
39/M

06/04/2022

Life to be assured:

	Type of Test	Actual Reading	Normal Range
1	Fasting Blood Sugar	111.3	70-100 mg%
2	PPBS	151.2	110 TO 140 mg%
3	Total Cholesterol	168.3	120-200 mg%
4	VERY LOW DENSINTY LEVEL(VLDL)	20.2	10-30 mg/dl
5	High Density Lipid (HDL)	49.0	40-60 mg%
6	Low Density Lipid (LDL)	99.1	Upto 150
7	S. Triglycerides	111.5	50-150 mg%
8	CHOL/HDL	3.4	Upto 5
9	HDL/LDL	0.4	
10	S. Creatinine	0.9	0.5-1.2 mg%
11	Blood Urea Nitrogen (BUN)	18.3	7-21 mg%
12	BUN/CREAT RATIO	20.3	
13	S. Proteins	6.8	6.0-7.9 mg%
14	(a) Albumin	3.6	3.5-5.5 mg%
15	(b) Globulin	3.2	2.0-3.5 mg%
16	A/G RATIO	1.1	
17	S. Bilirubin	0.8	0.3-1.3mg%
18	(a) Direct	0.6	0.0-0.8 mg%
19	(b) Indirect	0.2	0.0-0.5 mg%
20	SGOT (AST)	24.3	05-34 IU
21	SGPT (ALT)	30.2	05-40 IU
22	GGTP (GGT)	35.3	05-50 IU
23	SGOT/SGPT	0.8	
24	HBA1C	6.78	UPTO 6.5
25	S. Alkaline Phosphatase	98	30-115 IU
26	T3	120.3	80-180ng/dl
27	T4	6.02	4.6-12 ug/dl
28	TSH	2.84	0.4-4.0 mIU/L
29	SERUM URIC ACID	5.12	2.5-7.2mg/dl
30	URINE SUGAR PP	ABSENT	
31	URINE SUGAR FASTING	ABSENT	
32	BLOOD GROUP	" A POSITIVE "	

DR. RAKESH PATKAR
M.D. D.N.B. (Pathology)
2013/05/1660



Mumbai, Maharashtra, India

Shop No 65, Nathani Heights, Marzban Parsi Colony, Dalal Estate, Mumbai Central, Mumbai, Maharashtra 400008, India

Lat 18.968756°

Long 72.819963°

06/04/22 10:08 AM