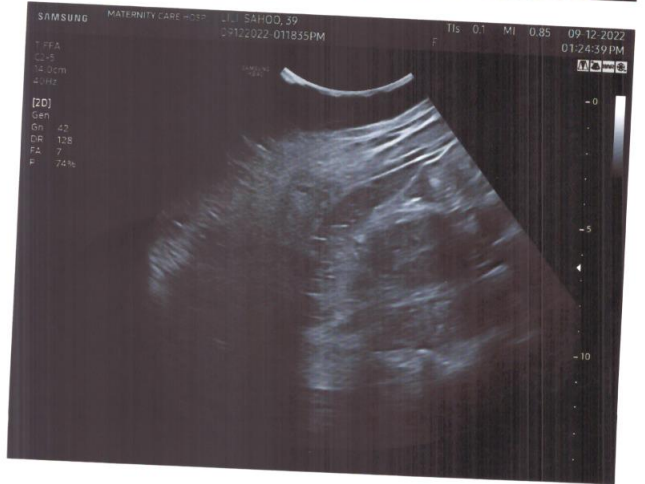
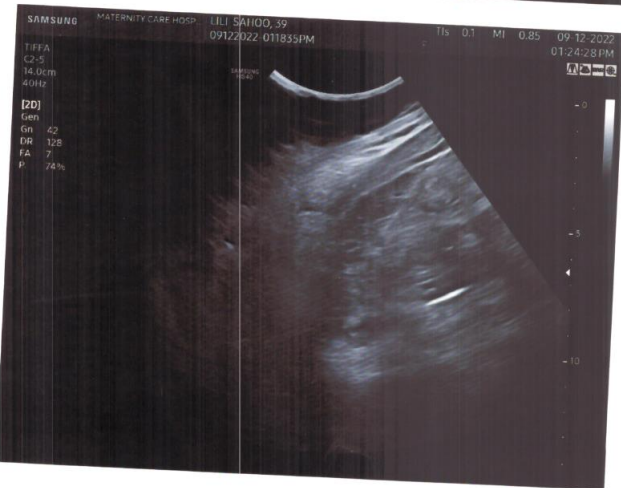
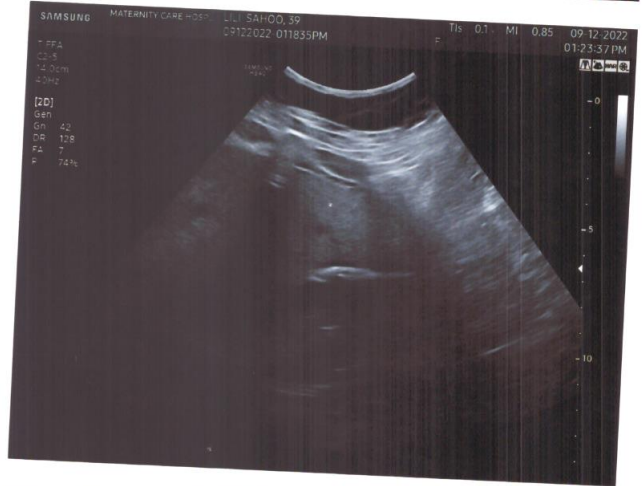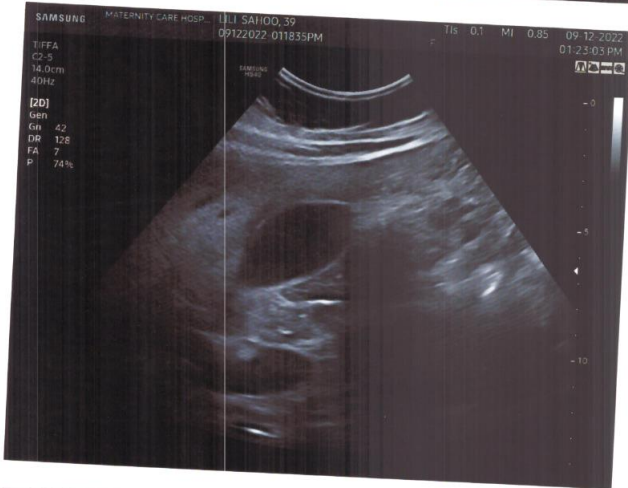
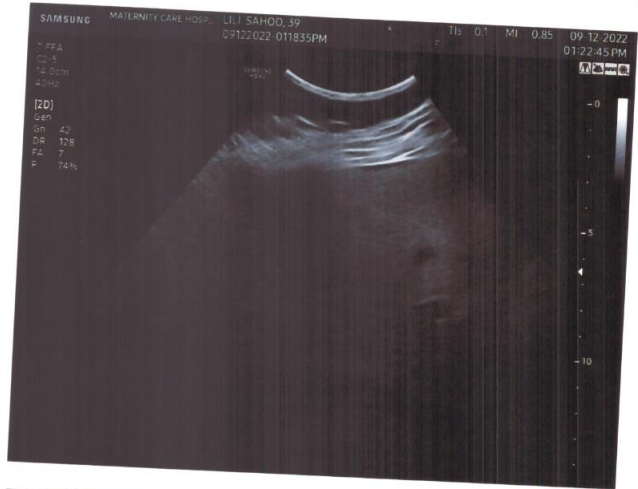
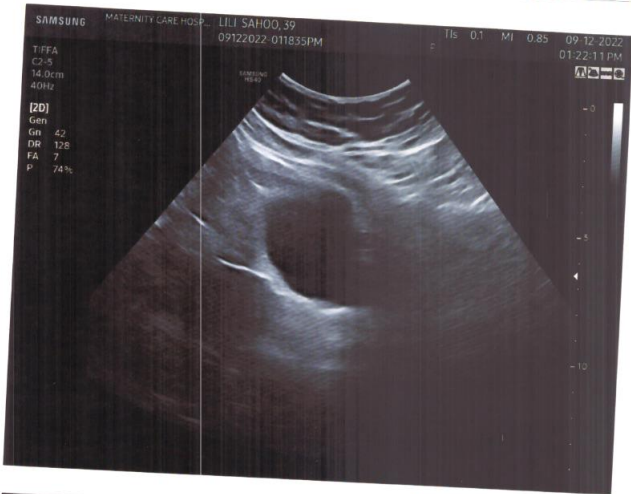


Patient

ID 09122022-011835PM
Name LILI SAHOO, 39
Birth Date
Gender Female

Exam

Accession #
Exam Date 09-12-2022
Description
Operator



MATERNITY CARE HOSPITAL

NAME:LILI SAHOO

AGE-39Y/F

SONOGRAPHER : DR. PARUL PATI

DATE:07/12/2022

USG OF WHOLE ABDOMEN

LIVER: normal in size, shape and parenchymal echotexture. No. SOL seen. Intrahepatic biliary channels normal in caliber and contains no echogenic structure. Portal and hepatic vascular systems within normal limits. P. V. measures 9.0 mm.

Gall bladder- Absent (operated)

SPLEEN : Normal in size, shape and parenchymal echotexture. Spleen measures 11.9cm.

PANCREAS: Normal in size, shape and parenchymal echotexture. Pancreatic duct not dilated.

KIDNEYS: Both the kidneys normal in size, shape and position. Renal cortical echotexture is within normal limits. Cortico medullary differentiation maintained. No evidence of any calculus or hydronephrosis on both sides. Pelvi-calyceal systems appear normal. No focal lesion seen.

- Left kidney measures: 9.4x 3.8cms.
- Right kidney measures: 9.8 x 3.7cms.

URETERS: Both ureters not visualized (normal).

Appendix- not visualized.

uterus : *uterus is normal in size shape 66.81 X48.29X42.18MM size, and normal endometrium in cavity.*

Ovary both ovary normal *in echopattern*

Cervix-cervical canal normal , cervix normal

POD- is free of fluid or sol

Impression: Normal Study of abdomen

Parul pati
DR. PARUL PATI (O&G MD)
Regd. No: 5569
MATERNITY CARE HOSPITAL & IVF CENTER
A-142/A-143, Sahio Nagar, Bhubaneswar
Khordha, Odisha
Phone No-(0674) 2542020, 2541010
TollFree: 18003132126