


भारत सरकार
Government of India

आधार



Vipin Kumar Kishore Chandra Bhatt
DOB : 26/10/1972
MALE

31/10/2012

9751 9282 9715

मेरा आधार, मेरी पहचान

Handwritten signature

Solm

DR. HARICHHABLANI

M.B.B.S., D.C.C. (NEET), MEDICINE, POSTGRADUATE
FELLOW, INTENSIVE CARE
MMC-REG. NO. 9715

1947

9751 9282 9715

DR. PLUS HEALTHCARE CENTRE
NATHANI HEIGHTS', B-WING,
42, MUMBAI CENTRAL (EAST)

Address: B 6 Matrikunj Society, Gotri,
Behind Kalprux Complex, Vadodara,
Vadodara, Gujarat, 390021

भारतीय पहचान प्राधिकरण
Unique Identification Authority of India

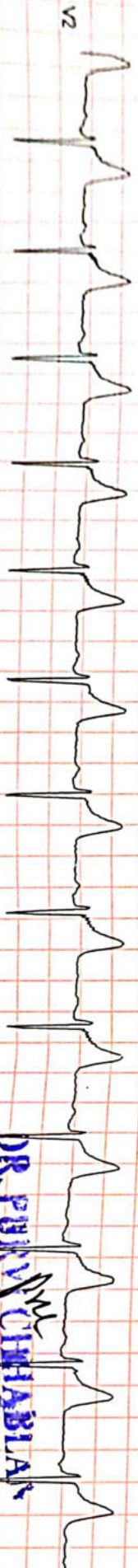
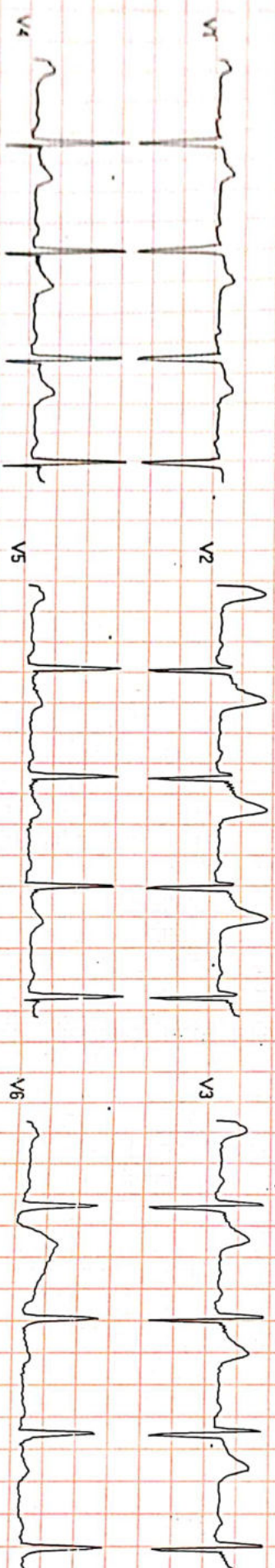
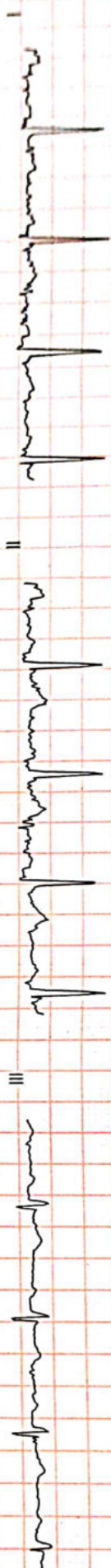आधार

DR PLUS HEALTHCARE CENTRE - MUMBAI CENTRAL

ECG

2247 / VIPIN BHATT / 50 YRS / M

Heart Rate : 83 bpm / Tested On : 08-Oct-22 09:30:35 / HF 0.05 Hz - LF 100 Hz / Notch 50 Hz / Sn 1.00 Cm/mV / Sw 25 mm/s / Ref'd By : DR HARU CHHABLANI



Normal

DR. PUNJ CHHABLANI

MBBS, DNB, (Med)

Consultant Physician And Internist

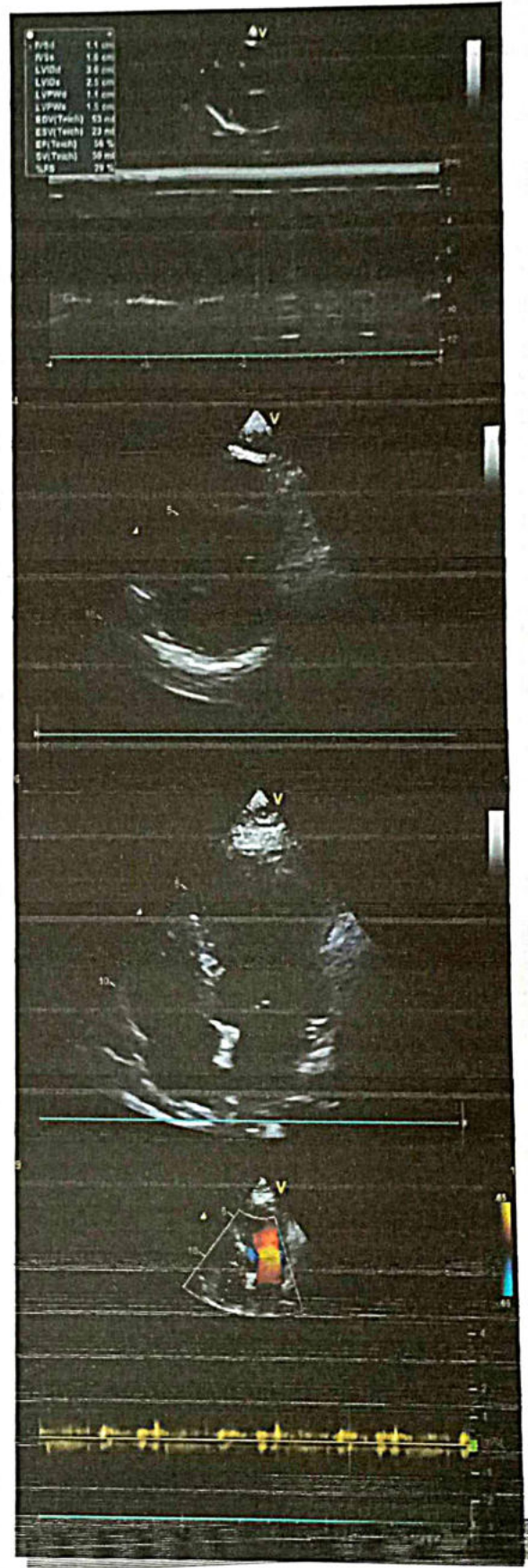
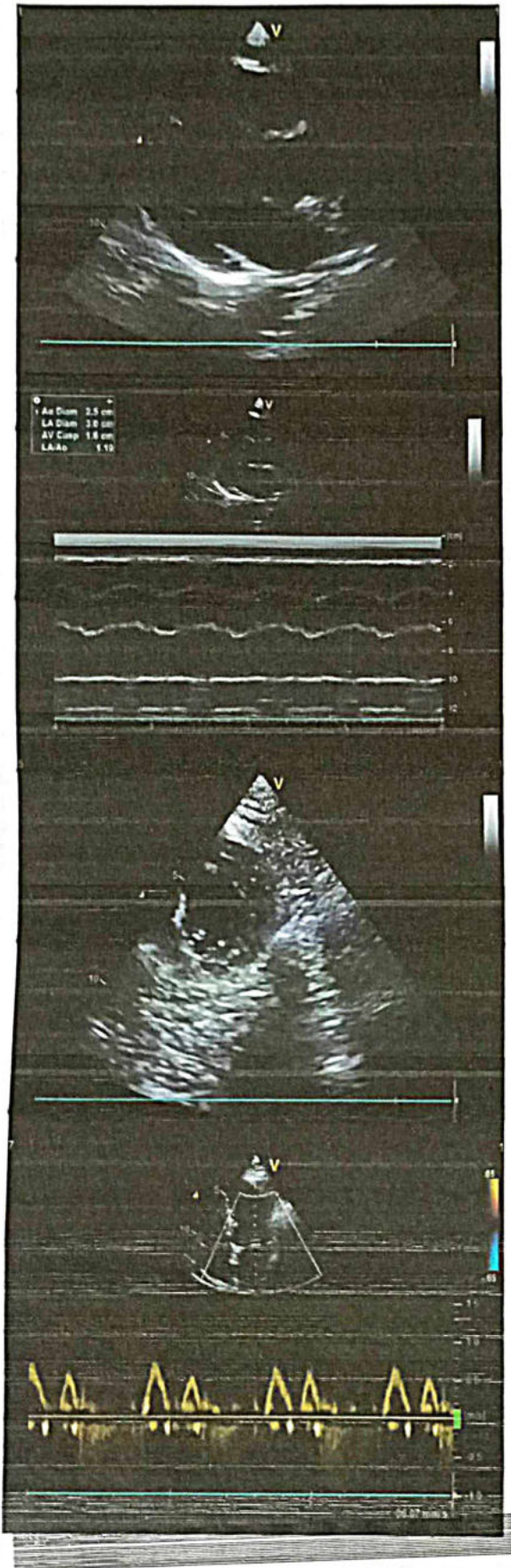
Reported By: DR. PUNJ CHHABLANI

Name VIPIN BHATT

Sex Male

Age 50

Date 08/10/2022





NAME : VIPIN BHATT

50/M

DATE:08/10/2022

REF BY: SELF

2D-ECHO. AND COLOR DOPPLER REPORT

- NORMAL CARDIAC VALVES WITH TRIVIAL TR.
- NORMAL CARDIAC CHAMBERS
- NO E/O REGIONAL WALL MOTION ABNORMALITY. WITH NORMAL LVEF OF 62 %.
- NO E/O PULMONARY HYPERTENSION .PASP 32 mmHg by TR jet.
- E/O MILD LEFT VENTRICULAR HYPERTROPHY.
- NO E/O DIASTOLIC DYSFUNCTION.
- NO E/O PERICARDIAL EFFUSION.
- NO E/O INTRACARDIAC CLOT OR VEGETATION
- INTACT IAS / IVS
- **CONVENTIONL DOPPLER :**
 - E TO A RATIO IS MORE THAN ONE IN LV INFLOW.
 - THERE IS NO GRADIENT ACROSS AV,LVOT OR RVOT
 - PASP FROM TR JET IS 30 mm OF Hg.
- **COLOUR DOPPLER:**
 - TRIVIAL TR

EF Slope	109	85-120 mm/sec		
Opening Amplitude	20			
Posterior leaflet				
E.P.S.S	02	mm		
Mitral valve prolapse				
Vegetations				
TRICUSPID VALVE	OBSERVED	NORMAL VALUES		
PULMONARY VALVE	OBSERVED	NORMAL VALUES		
EF Slope				
'A' Wave				
Midsystolic notch				
Flutter				
Other Findings				
AORTIC VALVE	OBSERVE	NORMAL VALUES		
Cuspal opening	16	mm		
Closure line	Central			
Eccentricity index	1			
Other Findings				
DIMENSIONS	OBSERVED	NORMAL VALUES		
1. Lvd (Diastolic)	36	26-52		
2. Lvd (Systolic)	25	24-42mm		
3. RVD (Diastolic)	17	7-23mm		
4. IVST (Diastolic)	11	6-11mm		
5. IVST (Systolic)	16			
6. LVPWT (Diastolic)	11	6-11mm		
7. LVPWT (Systolic)	15			
8. Aortic root	25	22-37mm		
9. left Atrium	30	19-40mm		
	STRUCTURE	REGURG GRADING	VELOCITY m/sec	STENOSIS GRADIENT mm/Hg
			Max mean	Peak mean
MITRAL VALVE	NORMAL	0/3	/	/
TRICUSPID VELVE	NORMAL	TRIVIAL	/	/
PULMONARY VELVE	NORMAL	0/4	/	/
AORTIV VALVE	NORMAL	0/4	/	/

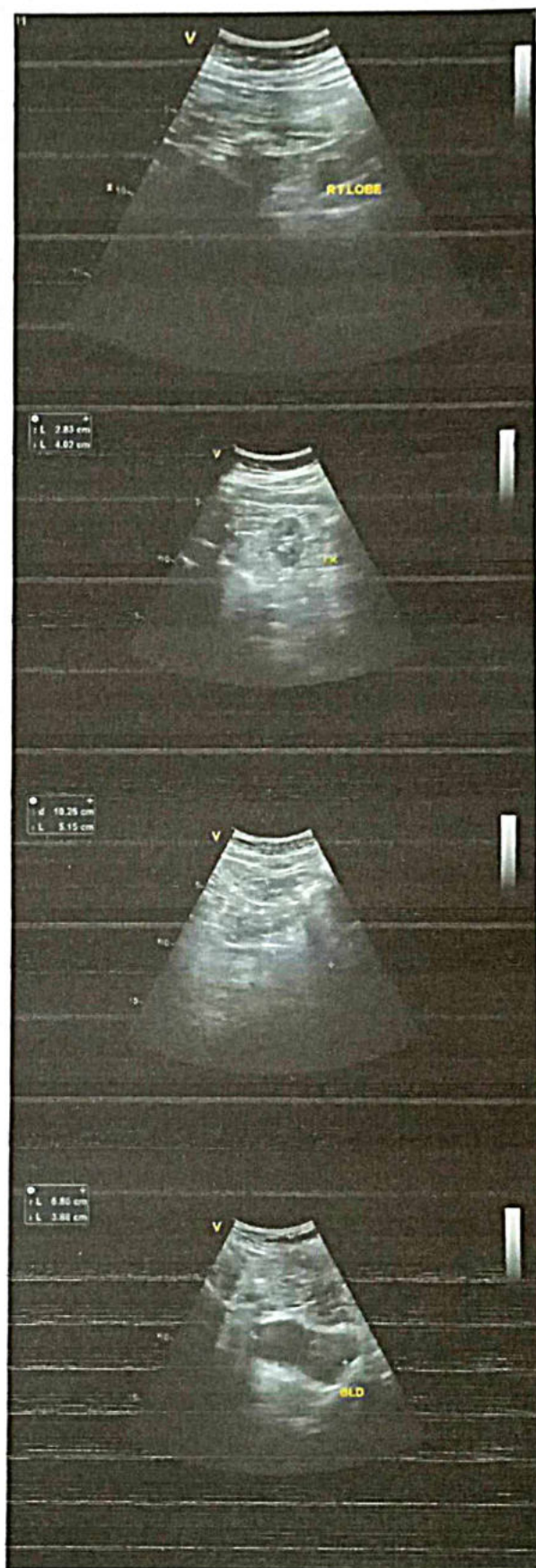
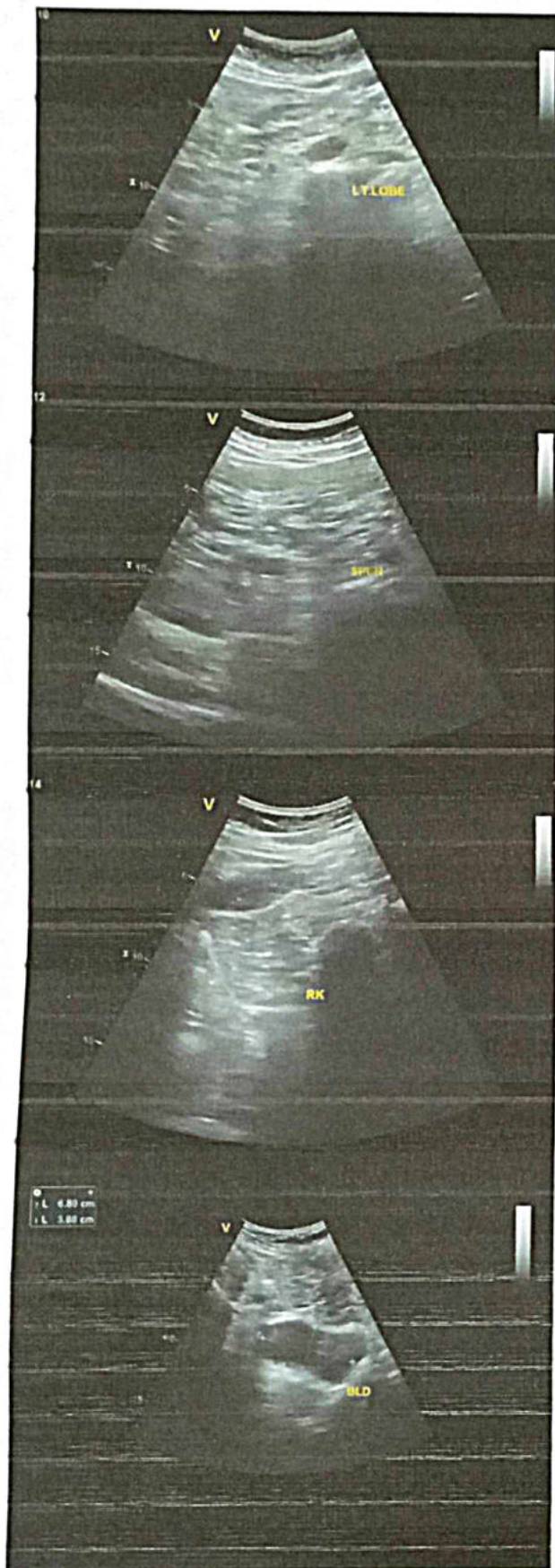
DHC
DR. P.H. CHHABLANI
 M.B.B.S, DNB.(MEDICINE)
 CONSULTANT PHYSICIAN AND CARDIOLOGIST.
DR. PURVI CHHABLANI
 MBBS, DNB. (Medicine)
 Consultant Physician And Intensivist.
 Reg No 77696

Name VIPIN BHATT

Sex Male

Age 50

Date 08/10/2022





Dr-Plus Healthcare Centre

NATHANI HEIGHTS, B-Wing, Shop No. 51, Ground Floor, Opp. Mumbai Central Station (East), Mumbai - 400 008.

Patient Name	:	VIPIN BHATT	Sex:	Male
Doctor's Name	:	SELF	Age:	50 Years
Date	:	08/10/2022		

ULTRASONOGRAPHY OF THE ABDOMEN AND THE PELVIS:

The relevant sonographic findings include the following:

HEPATOBIILIARY APPARATUS

The liver is normal in size and echogenicity. No obvious focal parenchymal lesion is seen. Extrahepatic biliary radicals are not dilated. The portal vein and the common bile duct are normal.

GALL BLADDER

The gall bladder is adequately distended. The wall thickness is normal. No echogenic contents are noted in its lumen. There is no pericholecystic collection noted.

PANCREAS

The pancreas shows normal echogenicity and size. No focal or diffuse lesions are noted. No evidence of calcification is noted.

SPLEEN

The spleen appears normal in size and echogenicity. No focal or diffuse lesions are noted. No evidence of calcification is noted.

KIDNEYS

Right Kidney measure: 10.5 x 4.7 cm, Left kidney measure: 10.1 x 3.9 cm
Both the kidneys appear normal in size, shape and echogenicity. Both the pelvicalyceal system is normal and both corticomedullary differentiations are well maintained. There is no obvious focal or diffuse lesion noted.
No evidence of any calculus seen in either kidney.

URINARY BLADDER

The urinary bladder shows anechoic contents. Its wall thickness appears normal. No significant post void residue.

PROSTATE

The Prostate appears normal and shows a normal echogenicity.

No evidence of calcification is seen.

There is no obvious evidence of abdominal or pelvic lymphadenopathy or ascites noted.

IMPRESSION: No significant abnormality is detected.

Dr. VICTOR X. COUTINHO
MBBS, DMRE
Radio-Sonologist

'DR. PLUS HEALTHCARE CENTRE'
NATHANI HEIGHTS, B-WING,
OPP. MUMBAI CENTRAL (EAST)

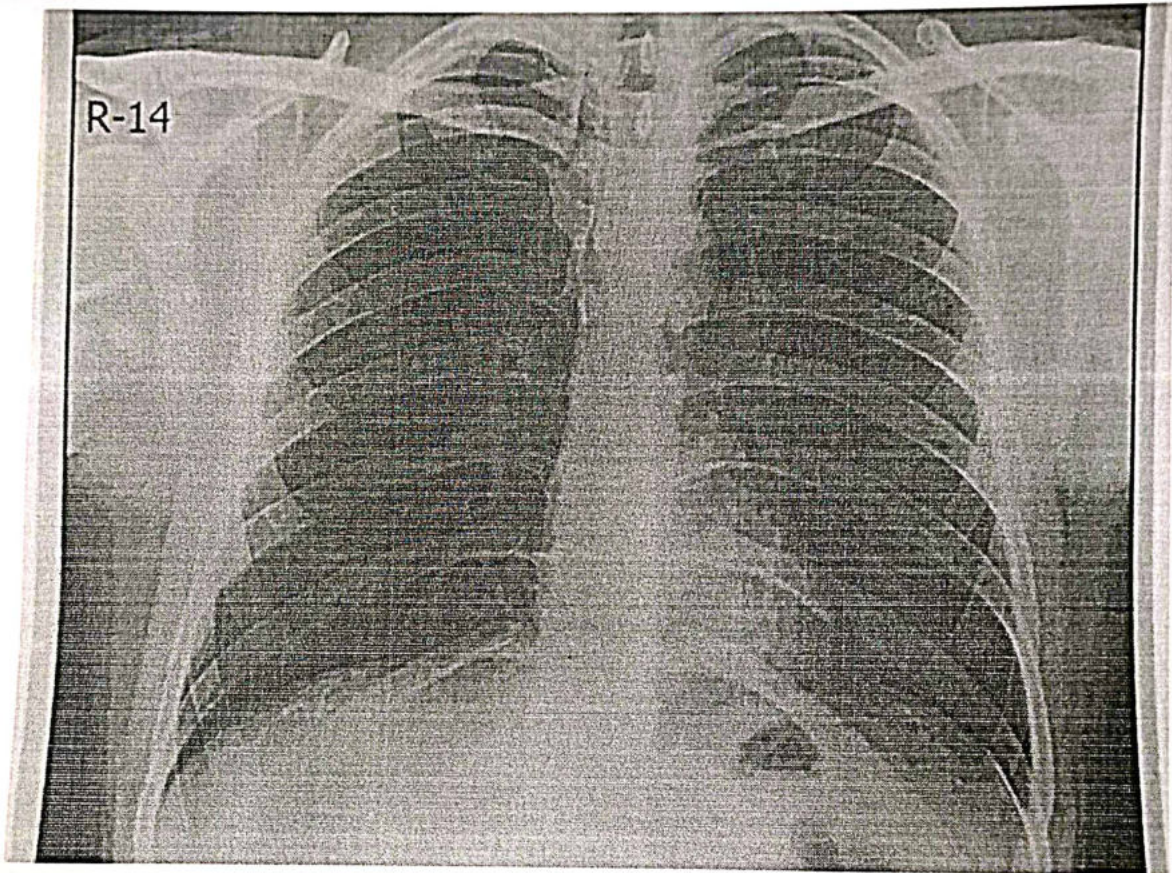
Patient's Name : VIPIN BHATT

Report Date : 08/10/2022

Referred By : SELF

Age : 50 Years

Sex : MALE



**DR. PLUS HEALTHCARE CENTRE
NATHANI HEIGHTS', B-WING,
42, MUMBAI CENTRAL (EAST)**



Dr-Plus Healthcare Centre

NATHANI HEIGHTS, B-Wing, Shop No. 51, Ground Floor, Opp. Mumbai Central Station (East), Mumbai - 400 008.

Patient's Name : VIPIN BHATT

Report Date : 08/10/2022

Referred By : SELF

Age : 50 Years

Sex : MALE

X- RAY CHEST

BOTH THE LUNG FIELED ARE CLEAR.

THE HILAR SHADOWS APPEAR NORMAL.

THE COSTO-PHRENIC ANGELS ARE CLEAR.

THE CARDIAC SHADOWS APPEAR NORMAL.

THE TRACHEAL IS CENTRAL IN POSITION.

THE BONY CAGE APPEARS NORMAL.

IMPRESSION : THE ABOVE EXAMINATION IS WITHIN NORMAL LIMITS.

DR. A. J. MAZUMDAR

MD. DMRE, MDRD

**'DR. PLUS HEALTHCARE CENTRE'
NATHANI HEIGHTS', B-WING,
42, MUMBAI CENTRAL (EAST)**



Dr. Hari Chhablani

Cardiometabolic Physician & Intensivist
M.B.B.S., F.C.C.P. (RESP. MED.), PGDHHM,
PGDMLS, FELLOW INTENSIVE CARE MED.

ATTACHED TO: Wockhardt Hospital • Salfee Hospital • Apollo Spectra Hospital

NATHANI HEIGHTS, B-Wing, Shop No. 42, Ground Floor, Opp. Mumbai Central Station (East),
Mumbai - 400 008. • Coll : 98206 46163 • E : drharichhablani@gmail.com

PHYSICIAN REPORT

08/10/2022

NAME : VIPIN BHATT

AGE: 50 SEX: M

PRESENTING COMPLAINS: K/C/O PILES SINCE 6 YEARS ON MEDICAL LINE OF TREATMENT .

PAST HISTORY:H/O LEFT RENAL STONE TREATED CONSERVATIVELY.

TREATMENT HISTORY : TAKING TREATMENT FOR PILES SOS.

FAMILY HISTORY: NOT SIGNIFICANT

ADDICTION: NIL

P: 82/MIN

BP: 120/80

RS: CLEAR

CVS: S1,S2 REGULAR

PA: SOFT

CNS: CLINICALLY NAD

DENTAL EXAMINATION : CLINICALLY NAD.

ECG: WNL

2-D-ECHO : WNL

SONOGRAPHY : WNL

CHEST X-RAY: WNL

LABS: ATTACHED

EYE EXAMINATION : NEAR VISION - B/L-N8 DISTANT VISION B/L - 6/18 COLOUR VISION - NORMAL

IMPRESSION : FIT ON CLINICAL MEDICAL EXAMINATION..

DR. HARI CHHABLANI
DR. HARI CHHABLANI
M.B.B.S.;F.C.C.P.(RESP.MEDICINE) PGDHHM, PGDMLS
FELLOW INTENSIVE CARE
MMC REG. NO. - 91702



Dr-Plus Healthcare Centre

NATHANI HEIGHTS, B Wing, Shop No. 51, Ground Floor, Opp. Mumbai Central Station (East), Mumbai - 400 008.

Full Name

VIPIN BHATT

50 /M

08/10/2022

Life to be assured:

	Type of Test	Actual Reading	Normal Range
1	Fasting Blood Sugar	86.7	70-100 mg%
2	PPBS	115.6	110 TO 140 mg%
3	Total Cholesterol	180.6	120-200 mg%
4	VERY LOW DENSITY LEVEL (VLDL)	16.3	10-30 mg/dl
5	High Density Lipid (HDL)	50.1	40-60 mg%
6	Low Density Lipid (LDL)	114.2.	Upto 150
7	S. Triglycerides	110.8	50-150 mg%
8	CHOL/HDL	3.6	Upto 5
9	HDL/LDL	0.4	
10	S. Creatinine	0.9	0.5-1.2 mg%
11	Blood Urea Nitrogen (BUN)	16.9	7-21 mg%
12	BUN/CREAT RATIO	18.7	
13	S. Proteins	6.6	6.0-7.9 mg%
14	(a) Albumin	3.7	3.5-5.5 mg%
15	(b) Globulin	2.9	2.0-3.5 mg%
16	A/G RATIO	1.2	
17	S. Bilirubin	0.8	0.3-1.3mg%
18	(a) Direct	0.5	0.0-0.8 mg%
19	(b) Indirect	0.3	0.0-0.5 mg%
20	SGOT (AST)	28.6	05-34 IU
21	SGPT (ALT)	32.1	05-40 IU
22	GGTP (GGT)	39.3	05-50 IU
23	SGOT/SGPT	0.8	
24	HBA1C	5.8	UPTO 6.5
25	S. Alkaline Phosphatase	98.4	30-115 IU
26	T3	159.2	80-180ng/dl
27	T4	5.2	4.6-12 ug/dl
28	TSH	2.5	0.4-4.0 mIU/L
29	SERUM URIC ACID	5.9	2.5-7.2mg/dl
30	URINE SUGAR PP	ABSENT	
31	URINE SUGAR FASTING	ABSENT	
32	BLOOD GROUP	" O POSITIVE "	

DR. RAVESH PATKAR
M.D., D.N.B. (Pathology)
Reg. No. 2013/05/1660



 GPS Map Camera

Mumbai, Maharashtra, India

Shop No 65, Nathani Heights, Marzban Parsi Colony, Dalal Estate, Mumbai Central, Mumbai, Maharashtra 400008, India

Lat 18.968793°

Long 72.819974°

08/10/22 09:10 AM GMT +05:30



Google